

CASE REPORT

Percutaneous Transhepatic Cholangioscopic Intervention in the Management of Complete Membranous Occlusion of Bilioenteric Anastomosis: Report of Two Cases

Dong-Hoon Yang, Sung Koo Lee, Sung-Hoon Moon, Do Hyun Park, Sang Soo Lee, Dong Wan Seo, and Myung-Hwan Kim

Department of Internal Medicine, University of Ulsan College of Medicine, Asan Medical Center, Seoul, Korea

Postoperative biliary stricture is a relatively rare but serious complication of biliary surgery. Although Roux-en-Y hepaticojejunostomy or choledochojejunostomy are well-established and fundamental therapeutic approaches, their postoperative morbidity and mortality rates have been reported to be up to 33% and 13%, respectively. Recent studies suggest that percutaneous transhepatic intervention is an effective and less invasive therapeutic modality compared with traditional surgical treatment. Compared with fluoroscopic intervention, percutaneous with cholangioscopy may be more useful in biliary strictures, as it can provide visual information regarding the stricture site. We recently experienced two cases complete membranous occlusion of the bilioenteric anastomosis and successfully treated both patients using percutaneous transhepatic cholangioscopy. (*Gut and Liver* 2009;3: 352-355)

Key Words: Bile duct obstruction; Postoperative complications

INTRODUCTION

Benign postoperative biliary stricture is one of the serious complications of biliary surgery. Although the bilioenteric anastomosis has become the traditional treatment of choice for patients with benign biliary strictures, recent studies suggested that percutaneous transhepatic therapy would be an effective and less invasive therapeutic modality.^{1,2} Both fluoroscopy and cholangioscopy

can guide the percutaneous balloon dilation with or without stent insertion. Compared with fluoroscopic intervention, percutaneous transhepatic cholangioscopy (PTCS) may be more useful in biliary strictures, as it can provide a direct vision on the stricture site and, if needed, biopsy specimens for tissue diagnosis.³ Recently, we experienced two cases with complete membranous occlusion of the bilioenteric anastomosis and successfully treated both patients using percutaneous transhepatic cholangioscopy.

CASE REPORT

1. Case 1

A 60-year-old male was admitted with fever and jaundice. He had undergone cholecystectomy 23 years prior to admission and, 1 year after this procedure, he underwent Roux-en-Y hepaticojejunostomy due to postoperative biliary stricture. He had been admitted three times during the last 4 years because of recurrent cholangitis and intrahepatic duct stones. The anastomosis site was patent on cholangiography and PTCS at each admission. Five months after the last admission, he was again admitted for fever that had developed 1 day earlier. His body temperature was 36.9°C, but he was grossly icteric. Laboratory tests revealed a white blood cell count of 27,400/mm³, aspartate aminotransferase of 199 IU/L (reference range, <40 IU/L), alanine aminotransferase of 242 IU/L (<40 IU/L), alkaline phosphatase of 269 IU/L (40-120 IU/L), gamma-glutamyl transferase of 330 IU/L (11-63 IU/L), total bilirubin of 8.0 mg/dL (0.2-1.2

Correspondence to: Sung Koo Lee

Department of Internal Medicine, University of Ulsan College of Medicine, Asan Medical Center, 388-1, Pungnap 2-dong, Songpa-gu, Seoul 138-736, Korea

Tel: +82-2-3010-3186, Fax: +82-2-476-0824, E-mail: sklee@amc.seoul.kr

Received on April 22, 2009. Accepted on June 23, 2009.

DOI: 10.5009/gnl.2009.3.4.352

mg/dL), and direct bilirubin of 3.9 mg/dL (<0.5 mg/dL).

A computed tomography (CT) scan showed that both intrahepatic ducts were diffusely dilated. Percutaneous transhepatic biliary drainage catheter insertion and subsequent PTCS were performed. The contrast medium did not pass through the anastomosis site and a dark dimpled spot was observed on the confluent portion of the two main intrahepatic bile ducts (Fig. 1A). There was no abnormal vessel or mucosal nodularity suggesting malignancy around the lesion. The dimpled spot was repeatedly tapped with the flexible end of the guidewire and the guidewire then passed through the anastomosis (Fig. 1B). After balloon dilation, an 18-Fr drainage catheter was passed through the anastomosis (Fig. 2). Repeated PTCS after 2 months and 8 months revealed suboptimal patency of the anastomosis site. Therefore, additional dilation was performed. A clamped catheter was maintained in the anastomosis site, and follow-up PTCS was scheduled to assess patency.

2. Case 2

The second case was a 26-year-old woman with postprandial right upper quadrant abdominal pain. She had

undergone an operation for removal of a hepatic mass including hepaticojejunostomy 25 years prior to admission. During the last 5 years, her blood chemistry tests repeatedly showed elevated levels of aspartate and alanine aminotransferase. Two years prior to admission, she had experienced an episode of self-limiting jaundice, and suffered from postprandial abdominal pain and jaundice for the 3 days before admission. A complete blood count showed WBC at 3,300/mm³, hemoglobin of 12.1 g/dL, and a platelet count of 102,000/mm³. Blood chemistry tests revealed aspartate aminotransferase of 54 IU/L, alanine aminotransferase of 100 IU/L, alkaline phosphatase of 381 IU/L, gamma-glutamyl transferase of 182 IU/L, total bilirubin of 2.2 mg/dL, and direct bilirubin of 0.8 mg/dL. A CT scan showed splenomegaly and cirrhotic change in the remnant liver with multiple intrahepatic stones in dilated intrahepatic ducts. No contrast medium passed through the bilioenteric anastomosis when cholangiography was performed. Cholangioscopy showed a small dimple on the anastomosis site without any finding suggestive of malignancy. Repetitive tapping on this lesion with the flexible end of the guidewire created a passage to the jejunum, and balloon dilation was performed.

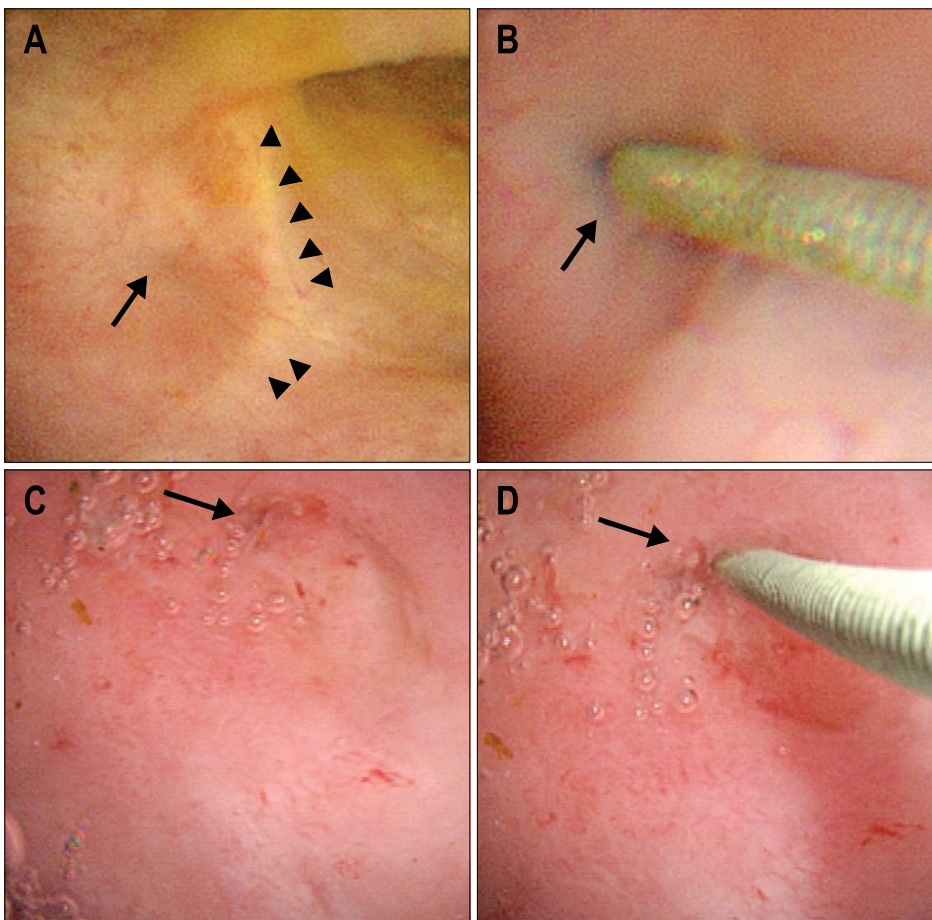


Fig. 1. (A) Case 1. The arrows indicate the small, dark, dimpled spot, and the arrowheads indicate scar changes. (B) Case 1. The dark, dimpled spot was tapped lightly and repeatedly with the flexible end of the guide wire. (C) Case 2. The arrows indicate the dimpled lesion, which appears fibrotic. (D) Case 2. The lesion was tapped lightly and repeatedly with the flexible end of the guide wire.

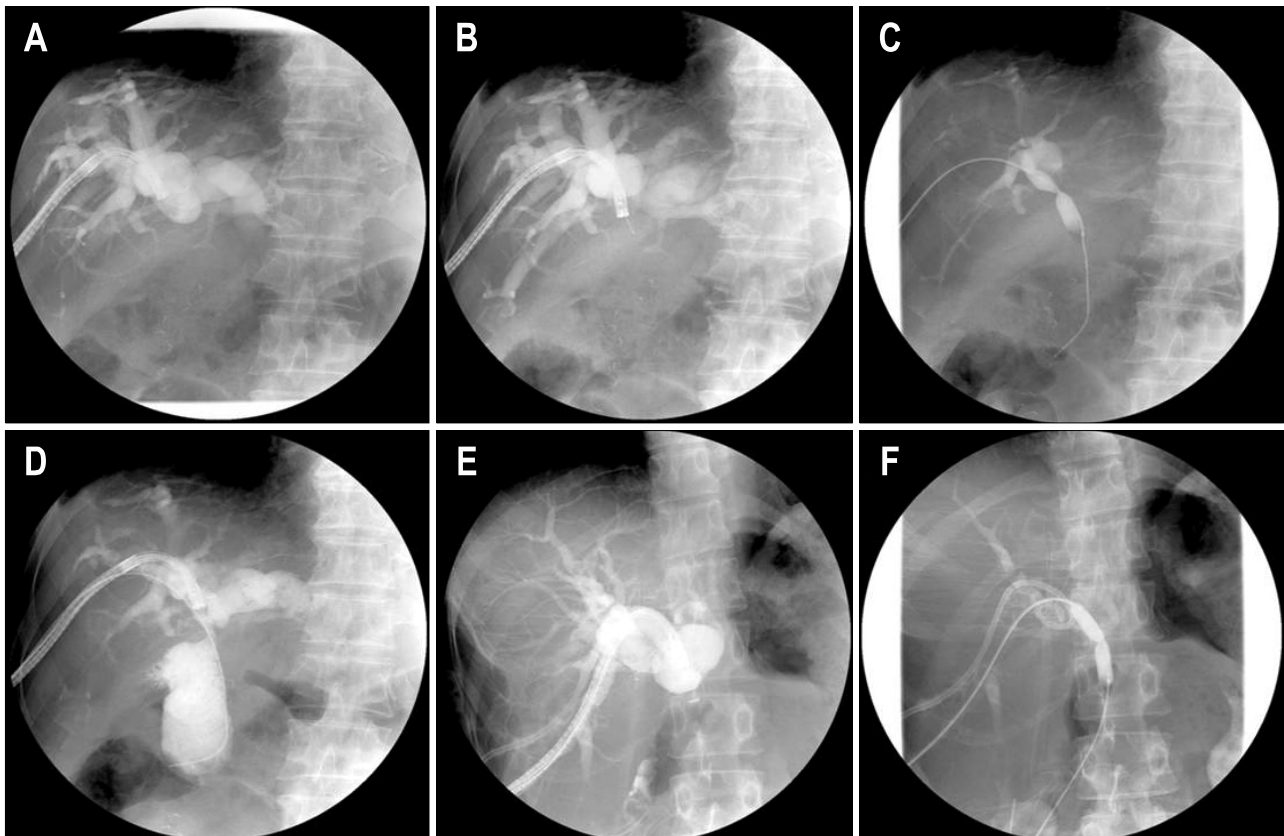


Fig. 2. Serial images of guide-wire insertion and balloon dilation (A-D, case 1; E and F, case 2). Images A and E show no contrast passage through the anastomosis sites, suggesting complete occlusion. After gentle tapping with the flexible end of the guide wire, balloon dilation was performed in each case (B-D, case 1; F, case 2).

The dilated site was well-maintained on PTCS after 2 months and our patient has experienced no significant symptoms for the last 14 months.

DISCUSSION

Postoperative benign biliary stricture is one of the serious complications of biliary surgery, and, if left untreated, can lead to recurrent cholangitis, recurrent choledocholithiasis, biliary cirrhosis, hepatic failure, and death.⁴⁻⁷ Roux-en-Y hepaticojejunostomy or choledochojejunostomy are well-established therapeutic approaches for this condition. However, because of the relatively high postoperative morbidity rate (13-33%)^{8,9} and significant postoperative mortality rate (2-13%)^{2,9-11} of these techniques, cholangioscopic intervention has become popular as a therapeutic option. Reoperation for recurrent biliary stricture after bilioenteric anastomosis is technically difficult, and surgery on patients with liver cirrhosis or portal hypertension is associated with serious morbidity and high mortality. Thus, balloon dilation via PTCS is the preferred treatment option in these difficult situations. After identi-

fying the stricture by imaging, percutaneous transhepatic biliary drainage catheter insertion, sinus tract dilation, and PTCS are sequentially performed, and, if a benign stricture is revealed, balloon dilation can be attempted. Guidewire insertion through the stricture site is necessary for balloon dilation, but, in some situations, such insertion is difficult or impossible. In our cases, the anastomosis sites were completely occluded. However, meticulous examination revealed the anastomosis sites to us, and the dimpled spots suggested the thinnest part of the occluded anastomosis sites. Guidewires could be advanced through the anastomotic lumens after gentle tapping with the flexible ends of the guidewires. To our knowledge, this is the first report on PTCS-based intervention in the treatment of the benign complete occlusion of bilioenteric anastomosis.

REFERENCES

1. Kim JH, Lee SK, Kim MH, et al. Percutaneous transhepatic cholangioscopic treatment of patients with benign bilio-enteric anastomotic strictures. *Gastrointest Endosc*

- 2003;58:733-738.
2. Schumacher B, Othman T, Jansen M, Preiss C, Neuhaus H. Long-term follow-up of percutaneous transhepatic therapy (PTT) in patients with definite benign anastomotic strictures after hepaticojejunostomy. *Endoscopy* 2001;33:409-415.
 3. Jung JY, Lee SK, Oh HC, et al. The role of percutaneous transhepatic cholangioscopy in patients with hilar strictures. *Gut Liver* 2007;1:56-62.
 4. Warren KW, Mountain JC, Midell AI. Management of strictures of the biliary tract. *Surg Clin North Am* 1971; 51:711-731.
 5. Bismuth H, Franco D, Corlette MB, Hepp J. Long term results of Roux-en-Y hepaticojejunostomy. *Surg Gynecol Obstet* 1978;146:161-167.
 6. Pellegrini CA, Thomas MJ, Way LW. Recurrent biliary stricture. Patterns of recurrence and outcome of surgical therapy. *Am J Surg* 1984;147:175-180.
 7. Csendes A, Diaz C, Burdiles P, et al. Indications and results of hepaticojejunostomy in benign strictures of the biliary tract. *Hepatogastroenterology* 1992;39:333-336.
 8. Rothlin MA, Löpfle M, Schlumpf R, Largiadèr F. Long-term results of hepaticojejunostomy for benign lesions of the bile ducts. *Am J Surg* 1998;175:22-26.
 9. Genest JF, Nanos E, Grundfest-Broniatowski S, Vogt D, Hermann RE. Benign biliary strictures: an analytic review (1970 to 1984). *Surgery* 1986;99:409-413.
 10. Tocchi A, Costa G, Lepre L, Liotta G, Mazzoni G, Sita A. The long-term outcome of hepaticojejunostomy in the treatment of benign bile duct strictures. *Ann Surg* 1996;224:162-167.
 11. Way LW, Bernhoft RA, Thomas MJ. Biliary stricture. *Surg Clin North Am* 1981;61:963-972.