

# Intractable Postoperative Wounds Caused by Self-Inflicted Trauma in a Patient with Cutaneous Munchausen Syndrome Presenting as a Pyoderma Gangrenosum-Like Lesion

Keiko Inui Takaaki Hanafusa Takeshi Namiki Makiko Ueno  
Ken Igawa Hiroo Yokozeki

Department of Dermatology, Graduate School of Medical and Dental Sciences,  
Tokyo Medical and Dental University, Tokyo, Japan

## Key Words

Pyoderma gangrenosum · Munchausen syndrome · Negative-pressure wound therapy · Self-inflicted trauma · Postoperative wounds

## Abstract

A 50-year-old Japanese woman consulted the emergency department of our hospital for bleeding due to an intractable postoperative wound on the lower abdomen; the postoperative wound was owing to a laparoscopic cholecystectomy performed 1 year previously for acute cholecystitis. She presented with a painful ulcer on her right lower abdomen. She also presented with multiple scars, skin grafts on the extremities, and a missing left lower leg, the causes for all of which were unexplained. The results of her blood test were normal, except for the hemoglobin level. Histology of the skin biopsy specimen from the ulcer did not show any specific findings. The previous surgeon who had performed the laparoscopic cholecystectomy revealed that surgical wound dehiscence had occurred during her admission. After a body restraint had been applied, the ulcer improved. Medical records indicated that she had been admitted to the department of plastic surgery at our hospital for skin grafting of a leg ulcer. During that admission, she refused to consult with the department of psychiatry, although the staff suspected mental disorders. Therefore, we diagnosed her with cutaneous Munchausen syndrome. After vacuum-assisted closure (VAC) therapy had been performed to prevent her from traumatizing the ulcer again, it rapidly became granulated and reepithelialized. Munchausen syndrome is characterized by feigning physical symptoms to seek atten-

tion. Patients self-inflict numerous lesions, keep getting admitted to different hospitals, and feign acute illness, usually spectacular diseases. VAC therapy may be effective for preventing patients with cutaneous Munchausen syndrome from traumatizing their wounds.

© 2016 The Author(s)  
Published by S. Karger AG, Basel

## Introduction

Munchausen syndrome is characterized by feigning physical symptoms to seek attention; it was first reported by Asher in 1951 [1]. Patients with this syndrome repeatedly request medical care for fabricated illnesses or conditions. We report a case of cutaneous Munchausen syndrome in a patient who self-inflicted trauma to a postoperative wound [2].

## Case Report

A 50-year-old Japanese woman consulted the emergency department of our hospital in August 2015 for bleeding due to an intractable postoperative wound on the lower abdomen; the postoperative wound was owing to a laparoscopic cholecystectomy performed 1 year previously for acute cholecystitis. The wound was sutured and the patient consulted with the dermatology department 3 days later (fig. 1a). She was admitted for a detailed examination 6 days later. On admission, she presented with a painful ulcer (diameter 6 cm) on her right lower abdomen, and its suture had disappeared (fig. 1b). She also presented with multiple scars, skin grafts on the extremities, and a missing left lower leg, the causes for all of which were unexplained (fig. 2).

Her white blood cell count, neutrophil number, platelet count, renal and liver functions, C-reactive protein level, and CH50 level were normal, except for the hemoglobin level (9.2 g/dl; normal range 12.0–15.0 g/dl). The antinuclear antibody level was normal at <1:40. Negative results were obtained for cytoplasmic antineutrophil cytoplasmic antibodies, myeloperoxidase antineutrophil cytoplasmic antibodies, and anti-SS-A antibodies.

A histology of the skin biopsy specimen from the margin of the abdominal ulcer did not show any specific findings such as pyoderma gangrenosum or vasculitis, although we had considered these as differential diagnoses. Methicillin-resistant *Staphylococcus aureus* was identified in a bacteriological culture from the wound.

She had been presenting with repeated intractable wounds since she was a child, which resulted in the amputation of her left lower leg. Although we asked her about the scar and amputation, she did not reveal any details. The previous surgeon who had performed the laparoscopic cholecystectomy 1 year before revealed that surgical wound dehiscence had occurred during her admission. After a body restraint had been applied, the ulcer improved. Her medical records indicated that she had been admitted to the department of plastic surgery at our hospital for skin grafting of a leg ulcer 10 years before. During that admission, she refused to consult with the department of psychiatry, although the staff suspected mental disorders. Therefore, we diagnosed her with cutaneous Munchausen syndrome, although we could not determine how she had traumatized the postoperative wound.

After vacuum-assisted closure (VAC) therapy had been performed to prevent her from traumatizing the ulcer again, it rapidly became granulated and reepithelialized (fig. 1c). Soon after we had told her that we had diagnosed her with cutaneous Munchausen syndrome, she discharged herself.

## Discussion

Munchausen syndrome is a disorder characterized by a triad of features: simulated illness, pathological lying, and nomadic living [3]. People with this syndrome self-inflict numerous lesions, keep getting admitted to different hospitals, and feign acute illness, usually spectacular diseases; and they willingly undergo invasive diagnostic procedures and risky therapies [3, 4]. Typical findings in cutaneous Munchausen syndrome caused by the intracutaneous presence of foreign material are erythema, swelling, necrosis, and tissue breakdown, which present as ulcerations, abscesses, nodular panniculitis, and pyoderma gangrenosum [2, 5]. Most patients with cutaneous Munchausen syndrome inject foreign materials into their skin and soft tissue; however, our patient traumatized her postoperative wound.

The diagnosis of Munchausen syndrome, which can sometimes be fatal, is often difficult to make. Previous treating physicians, family, and friends may have valuable information. Also, hospital room and personal-belonging searches can provide evidence of methods for faking symptoms, and video monitoring or a bedside sitter can be helpful, as these techniques often reduce or eliminate symptom frequency during observation. However, searches and monitoring should be performed after approval has been granted from the institution's legal counsel. Diagnostic clues include cultured organisms from cutaneous wounds that are uncommonly found on the skin, usually on the nondominant side of the body [1, 2].

Cutaneous Munchausen syndrome should be considered as a differential diagnosis when a patient's skin lesions do not heal or when they repeatedly recur despite appropriate treatment, and if routine detailed examinations show negative or normal results. VAC therapy may be effective for preventing these patients from traumatizing their wounds.

## Statement of Ethics

The authors have no ethical conflicts to disclose.

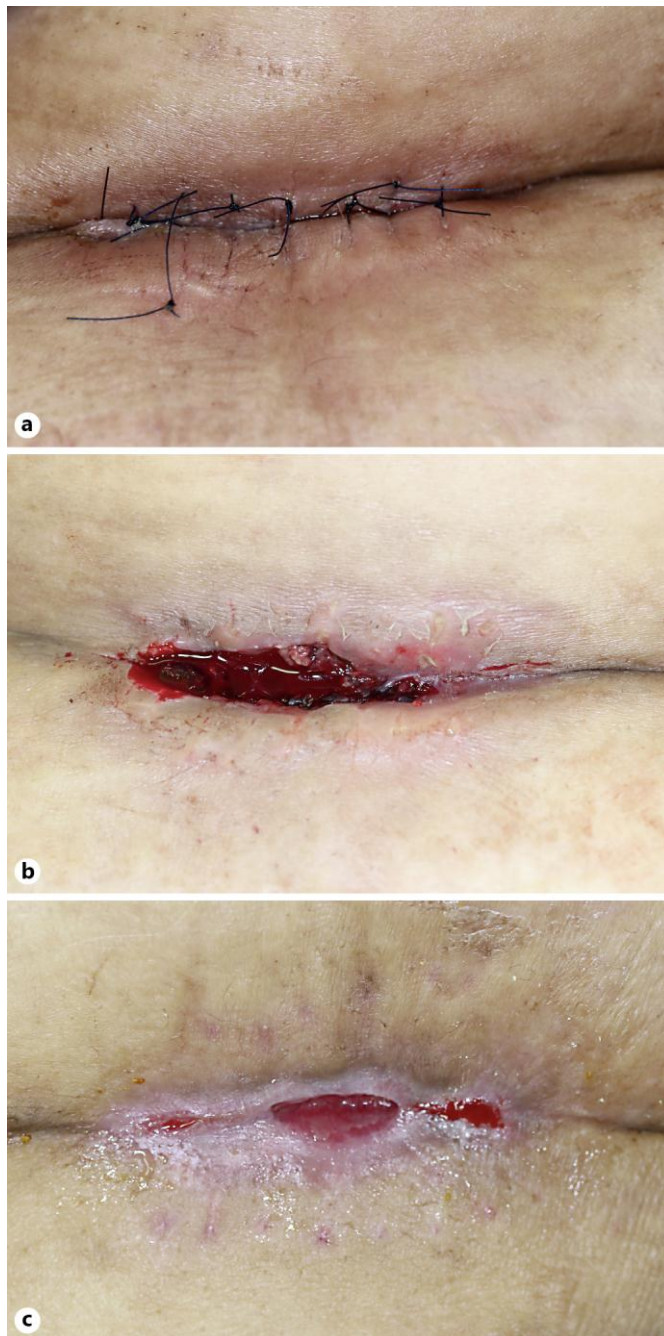## Disclosure Statement

The authors have no conflicts of interest to disclose.

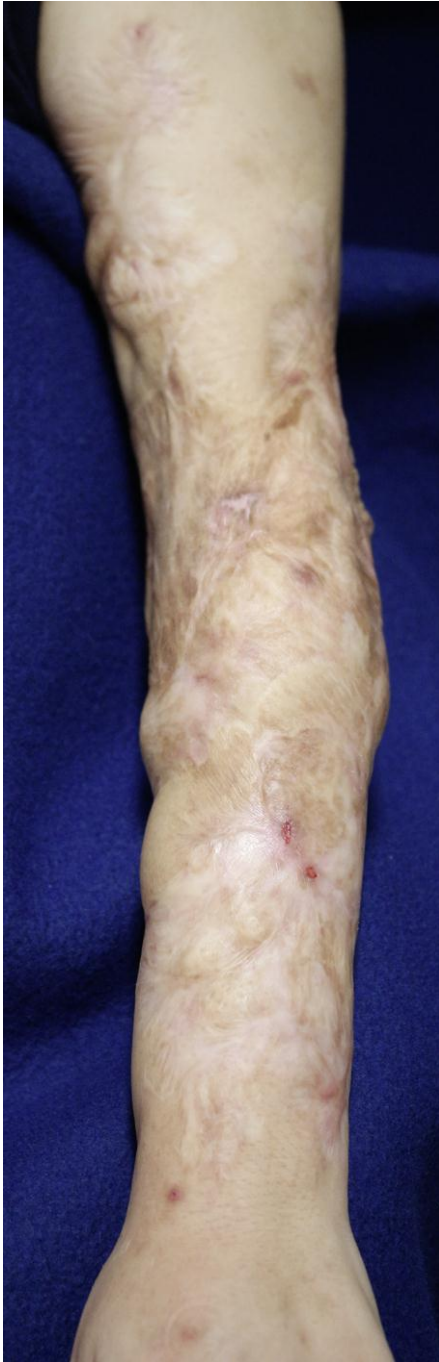
## References

- 1 Huffman JC, Stern TA: The diagnosis and treatment of Munchausen's syndrome. *Gen Hosp Psychiatry* 2003;25:358–363.
- 2 Boyd AS, Ritchie C, Likhari S: Munchausen syndrome and Munchausen syndrome by proxy in dermatology. *J Am Acad Dermatol* 2014;71:376–381.
- 3 Turner J, Reid S: Munchausen's syndrome. *Lancet* 2002;359:346–349.
- 4 Lazzeri D, Romeo G, De Rosa M, Giannotti G, Colizzi L, Stabile M, Gatti G, Lorenzetti F, Gandini D, Pantaloni M: Plastic surgery and Munchausen's syndrome: 'surgeon, beware!'. *J Plast Reconstr Aesthet Surg* 2010;63:e319–e320.
- 5 Tochigi M, Hara H, Goshima J, Kobayashi M, Shimizu H, Yokoyama A, Matsunaga A, Takemura T, Terui T: Cutaneous Munchausen's syndrome caused by self-injections of fermented beans. *J Eur Acad Dermatol Venereol* 2008;22:886–887.

Inui et al.: Intractable Postoperative Wounds Caused by Self-Inflicted Trauma in a Patient with Cutaneous Munchausen Syndrome



**Fig. 1.** Clinical appearance of the postoperative wound on the patient's lower abdomen. The ulcer had been sutured at the emergency department of our hospital 3 days before the patient's first consultation with the department of dermatology (a). On admission at the department of dermatology 6 days later, the suture had completely disappeared (b). After VAC therapy, the abdominal ulcer rapidly became granulated and reepithelialized (c).



**Fig. 2.** Clinical appearance of the patient's left arm on admission. The patient presented with multiple scars and previous skin grafts on the extremities as well as a missing left lower leg. She did not reveal details of the causes of these wounds.