

Access this article online

Quick Response Code:



Website:

www.jorthodsci.org

DOI:

10.4103/jos.JOS\_79\_20

# Evaluation of smile characteristics of skeletal Class III compared to skeletal Class I female adults

Abdallah S. Nouh, H. M. Abdel Majeed<sup>1</sup> and Essam Mohamed Nassef Selim<sup>1</sup>

## Abstract

**OBJECTIVE:** Esthetic enhancement plays an important role in orthodontic treatment. This study was conducted on females as most girls have their growth spurt at a younger age than boys do, so their demand to facial esthetics, especially those who have residual growth of mandible producing class III effect, requires full understanding to smile features helping in diagnosis and treatment planning for maximum patient satisfaction.

**MATERIALS AND METHODS:** This study was conducted on 30 skeletal Class III and Class I female adults (18–30 years old) who were divided equally into two groups comprising 15 each. Two frontal digital photographs were taken for each subject, one at rest and the other in the posed smile position. Photographs were taken for each subject in the natural head position by a Canon EOS 1200 D camera set on a tripod at a distance of 1.5 m. The incisogingival height of the right maxillary central incisor was clinically measured using a vernier caliper to the nearest 0.1 mm. Photographs were uploaded on Photoshop software for standardization and then uploaded on the Digital Smile Design software (DSD) where the actual incisogingival height of the central incisor was used for automatic calibration. Esthetic components at rest and on smiling were measured for both groups; all linear variables were measured to the nearest 0.1 mm.

**RESULTS:** Class III females tended to have wider smile widths, less gingival display, longer chin heights, shorter lower vertical dimensions, and a higher percentage of nonconsonant and flat smile arcs than Class I subjects.

**CONCLUSIONS:** The components of the smile should be considered as a guide to help in planning and designing the mechanics during comprehensive orthodontic treatment.

## Keywords:

Class III females adults, esthetics, malocclusion, smile non

*Nuclear and  
Radiological Regulatory  
Authority, (NRRA),  
P.O. 7551, Nasr  
City, <sup>1</sup>Department of  
Orthodontics, Faculty of  
Oral and Dental Medicine,  
Future University, Cairo,  
Egypt*

## Address for correspondence:

Dr. Abdallah S. Nouh,  
Atomic Energy  
Authority, Nuclear and  
Radiological Regulatory  
Authority, (NRRA),  
P.O. 7551, Nasr City,  
Cairo 11566, Egypt.  
E-mail: abdalla\_uth@  
live.com

Submitted: 02-Dec-2020

Revised: 03-Feb-2021

Accepted: 23-Feb-2021

Published: 15-Oct-2021

## Introduction

The smile has an essential responsibility in social interaction. It assigns various positive emotions like pleasure, endorsement, and humor. Esthetically pleasant smile might enhance the self-confidence in social positions.<sup>[1]</sup> Dentofacial beauty is mainly significant to a person's psychosocial well-being, where persons with a regular dental look seem

more socially nice-looking than those with malocclusions. Those with deprived dental esthetics have been related to need of self-confidence and are considered to be disadvantaged in social, educational, and occupational settings.<sup>[2]</sup> Thus, smile esthetics has become the primary focus of patients seeking orthodontic treatment. Now smile analysis represents an essential requirement in present orthodontic treatment planning that permits distinguishing positive and negative basics in a patient's smile.<sup>[3]</sup> On the other hand, Digital Smile Design (DSD) orderly procedure is dependent on definite

This is an open access journal, and articles are distributed under the terms of the Creative Commons Attribution-NonCommercial-ShareAlike 4.0 License, which allows others to remix, tweak, and build upon the work non-commercially, as long as appropriate credit is given and the new creations are licensed under the identical terms.

For reprints contact: WKHLRPMedknow\_reprints@wolterskluwer.com

**How to cite this article:** Nouh AS, Abdel Majeed HM, Nassef Selim EM. Evaluation of smile characteristics of skeletal Class III compared to skeletal Class I female adults. J Orthodont Sci 2021;10:18.

photographs and software analysis and is globally used. DSD assists the dentists in creating and developing a route of treatment, particularly in a multidisciplinary approach. Also, it supplies a virtual simulation of the concluding result. In addition, it allows communications between the dental team and the patient. An additional feature of DSD is that it enables analysis of the proportions and aesthetics of teeth, smile and face, and allows the feasibility of enhancing the certainty of concluding plan outcome.<sup>[4]</sup>

Several studies have evaluated smile features and their influences on attractiveness. Sabri<sup>[5]</sup> reviewed the main smile components and discussed their influence on orthodontic diagnosis and treatment planning. It is found that the optimum smile was distinguished by an upper lip which reaches the gingival margins, with an upward or straight curvature between the philtrum and commissures, an upper incisal line coincident with the border of the lower lip, minimal or no lateral negative space, a commissural line and occlusal frontal plane parallel to the pupillary line and harmoniously dental and gingival components. Al-Hamdany<sup>[6]</sup> investigated that Class I subjects possessed superior values of upper lip length than Class II followed by Class III. It was concluded that the upper lip length was greater in Class I subjects, whereas Class III subjects had greater lower lip lengths. The interlabial gap was larger in Class II subjects, whereas the coverage of the lower lip to incision superior was greater for Class III subjects. Rashed and Heravi<sup>[7]</sup> evaluated the impact of different malocclusions (Classes I, II, and III) on lip-tooth relationships during smiling using video images. There were no statistically major divergence in the upper central incisor display and buccal corridor ratios among the malocclusion groups. Additionally, Malhotra *et al.*<sup>[8]</sup> studied the effect of specific facial hard and soft tissues on smile characteristics. It was observed that patients with Class III showed the slightest quantity of buccal corridors and gingival display on smiling. Smile analysis and getting average for different smile components provides strategy for the construction of an esthetic smile. Thus, this study was conducted on females as most girls have their growth spurt at a younger age than boys do, so their demand to facial esthetics, especially those who have residual growth of mandible producing class III effect, requires full understanding to smile features helping in diagnosis and treatment planning for maximum patient satisfaction.

## Materials and Methods

The study was carried out on 30 skeletal Class III and Class I female adult subjects with average vertical facial patterns selected from the Orthodontic Department, Faculty of Oral and Dental Medicine, Future University, Egypt. In a previous study by Kakadiya *et al.*<sup>[9]</sup> the

response within skeletal Class I and III groups was normally distributed true difference between the study groups was 1.42.

Sample size calculation indicated that for a study with a power of 80% and an  $\alpha$  error of 0.05, the minimum estimated sample size was 9 cases per group for a total of 18 cases. 30 females were included in the current study which was equally divided into two groups which included 15 adult females for each group. Subjects included in the study had an average age of 18-30 years in order to minimize the effects of growth on facial appearance as reported by Leonardi *et al.*<sup>[10]</sup> females with skeletal class III (mandibular hyperplasia) and class I facial profiles with average vertical facial pattern, full set of permanent dentition and had not received any previous orthodontic treatment, whereas those with congenitally missing, malformed or extracted teeth, having fixed bridges or crowns visible on smiling, excessive dental attrition, lip irregularity or history of lip surgery and facial asymmetries were excluded from the study. Two frontal photographs at rest and subjects' commissure-to-commissure posed smile were taken by a Canon G11 camera set on a tripod from a fixed distance of 1.5 m where the camera was focused on the mouth showing from the nose to the chin. The camera lens was adjusted to be parallel to the floor by adjusting the mounthead of the tripod guided by the leveling indicator that is built in the tripod. Photographs were taken for each patient in the natural head position. The head was held in an upright posture and eyes were focused on a point in the distance at eye level such that the visual axis was horizontal.

For measuring smile variables the DSD software program was used. Standardization was mandatory to avoid any magnification errors where the incisogingival height of the right maxillary central incisor was clinically measured (actual height) for each case using a vernier caliper to the nearest 0.1 mm. Photographs were uploaded on Photoshop software for standardization and a reading for the incisogingival height of the right maxillary central incisor was done where a ratio of 7:5 was found to provide the most accurate image guided by the actual clinical height of the central incisor. The new standardized photos were uploaded on the DSD software to be calibrated to measure all linear variables in to the nearest 0.1 mm. The actual incisogingival height in millimeters was used for automatic calibration by the digital smile system (DSS) where twelve smile components were evaluated at rest and on smiling [Figures 1 and 2].

## Statistical analysis

Numerical data were investigated for normality by checking the distribution of data and via

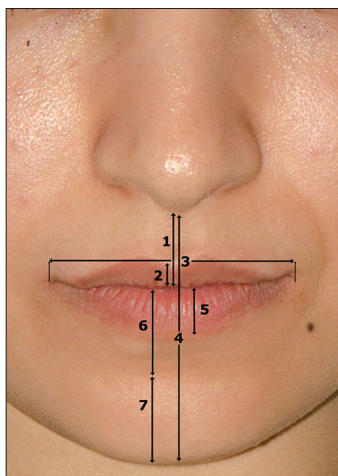
tests of normality (Kolmogorov–Smirnov and Shapiro–Wilk tests). All data showed normal (parametric) distribution except for the gingival display which showed nonnormal (nonparametric) distribution. Data are presented as means, standard deviation (SD), mean difference and 95% confidence interval (95% CI) for the difference values. For parametric data, Student’s *t* test was used to compare between the two Classes. For nonparametric data, Mann–Whitney *U* test was used to compare between females of both Classes. The significance level was set at  $P \leq 0.05$ . Statistical analysis was performed with IBM SPSS Statistics for Windows, version 23.0. Armonk, New York: IBM Corp. All measurements were repeated for 10 frontal photographs at two different occasions by the main observer

where there was good to very good intra-observer reliability (agreement) regarding all measurements with Cronbach  $\alpha$  values ranging from 0.614 to 0.862.

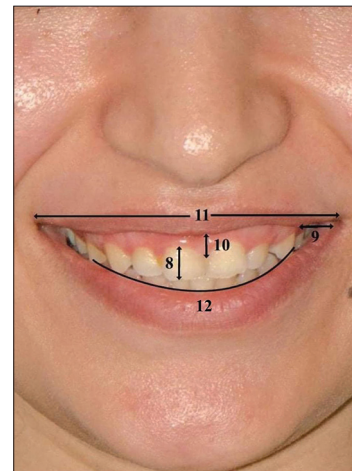
## Results

Means, SD, 95% CI and results of student’s *t*-test for comparison between esthetic soft tissue measurements for Class III and I females at rest and on smiling are presented in Tables 1 and 2. The frequencies, percentages (%) and results of Fisher’s exact test for comparison between smile arcs of Class I and Class III females on smiling are represented in Table 3.

At rest, the upper lip length (19.72 mm ± 2.03), inter-commissural distance (52.08 mm ± 6.04) and the



**Figure 1:** (1) Upper lip length, (2) Upper lip thickness, (3) Intercommissure width, (4) Lower facial height, (5) lower lip thickness, (6) Lower Lip length and (7) Chin height



**Figure 2:** (1) Incisor display, (2) Buccal corridors, (3) Gingival display, (4) Smile width and (5) Smile arc

**Table 1: Comparison between soft tissue measurements of Class III and Class I females at rest**

Measurement (mm)	Class I (n=15)		Class III (n=15)		Mean difference (mm)	95% CI for Difference		P	Effect size (d)
	Mean (mm)	SD	Mean (mm)	SD		Lower bound	Upper bound		
At rest									
Upper lip length	19.72	2.03	16.44	2.17	3.28	1.71	4.85	<0.001*	1.561
Upper lip thickness	6.29	1.18	6.14	1.49	0.15	-0.85	1.16	0.757	0.112
Inter-commissural distance	52.08	6.04	40.47	3.44	11.61	7.94	15.29	<0.001*	2.362
Lower facial height	61.65	6.31	52.31	4.88	9.34	5.13	13.56	<0.001*	1.656
Lower lip thickness	16.20	2.04	15.93	2.46	0.27	-1.43	1.96	0.749	0.118
Lower lip length	23.9	1.93	22.47	3.76	1.43	-0.8	3.67	0.199	0.480
Chin height	37.09	3.76	43.93	5.32	6.84	-10.29	-3.4	<0.001*	1.486

\*Significant at  $P \leq 0.05$

**Table 2: Comparison of soft tissue measurements between females with Class III and I on smiling**

Measurement (mm)	Class I (n=15)		Class III (n=15)		Mean difference (mm)	95% CI for Difference		P	Effect size (d)
	Mean (mm)	SD	Mean (mm)	SD		Lower bound	Upper bound		
Maxillary incisor display	9.67	1.52	9.13	2.16	0.54	-0.86	1.93	0.441	0.289
Buccal corridors	8.99	1.74	8.57	1.51	0.42	-0.8	1.63	0.492	0.258
Gingival display	3.20	2.15	1.03	2.31	2.17	0.5	3.83	0.008*	0.988†
Smile width	68.68	6.24	77.55	13.16	-8.87	-16.6	-1.17	0.026*	0.861

\*Significant at  $P \leq 0.05$ , †Mann-Whitney U test

lower facial height ( $61.65 \text{ mm} \pm 6.31$ ) were found to be significantly longer for skeletal Class I females compared to Class III females. On the other hand, the chin height ( $43.9 \pm 5.32$ ) was significantly longer for Class III females compared to Class I. There was an insignificant difference for the lower lip length, upper and lower lip thickness between both groups [Table 1 and Figure 3].

On smiling, the gingival display of Class I females was found to be significantly greater ( $3.20 \text{ mm} \pm 2.15$ ) than that for Class III females ( $1.03 \text{ mm} \pm 2.31$ ) ( $P = 0.008$ , effect size = 0.988). On the other hand, the smile width was significantly wider for skeletal Class III females ( $77.55 \text{ mm} \pm 13.16$ ) compared to Class I females ( $68.68 \text{ mm} \pm 6.24$ ) ( $P = 0.026$ , effect size = 0.861). Statistically insignificant differences were found for maxillary incisor display and buccal corridors between both groups [Table 2 and Figure 4].

Class III females had 60% consonant smile arcs, 26.7% nonconsonant and 13.3% flat smile arcs which were found to be statistically insignificant between females of both classes ( $P = 0.095$ , effect size = 0.404) [Table 3 and Figure 5].

### Discussion

This study seeks to determine the smile characteristics of skeletal Class III compared to skeletal I female adult subjects. Two full face frontal photographs were taken for each participant at rest and with posed smile which is considered to be the most reproducible smile according to Ackerman *et al.*<sup>[11]</sup> According to Mack<sup>[12]</sup> and Peck *et al.*<sup>[13]</sup> the essential characteristic of the smile that influences esthetics is the quantity of maxillary gingival display. Hulsey<sup>[14]</sup> and Mackley<sup>[15]</sup> investigated that the upper lip must be at the height of the gingival margin of the maxillary central incisors in an attractive smile. In addition, Ker *et al.*<sup>[16]</sup> stated that the ideal value for smile esthetics was 2.1 mm of gingival display. In this study, the gingival display for skeletal Class III females was (1.03 mm) which was found to be significantly less than that seen for Class I females which was (3.2 mm) which was slightly more than the ideal amount of gingival display as reported by Chiche and Pinault<sup>[17]</sup> who pointed out that the esthetically perfect quantity of visible gingiva was about 1 mm but showed that 2–3 mm of gingiva might be esthetically satisfactory.

Although the upper lip length was significantly longer for Class I compared to Class III females, the gingival display was found to be greater in Class I females which could be due to the significantly longer lower facial height shown for Class I compared to Class III females in this study. According to Singer<sup>[18]</sup> & Peck and Peck<sup>[13]</sup> those with gingival smiles were not only affected by

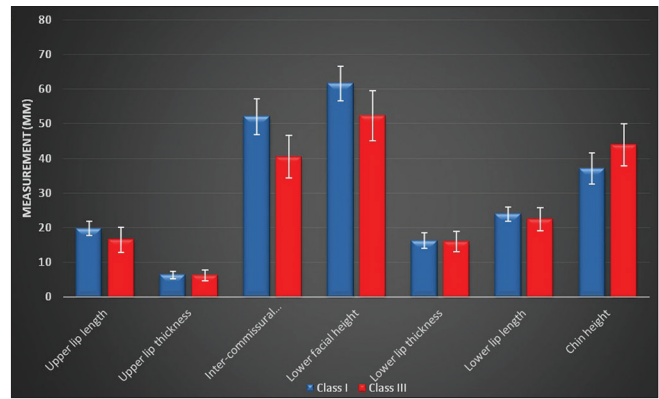


Figure 3: Bar chart representing mean values for soft tissue measurements of Class I and Class III females at rest

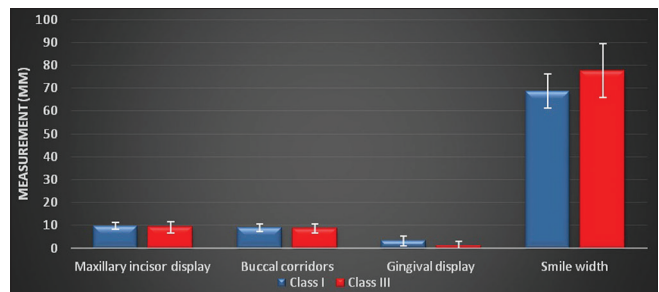


Figure 4: Bar chart representing mean values for soft tissue measurements of Class I and Class III females on smiling

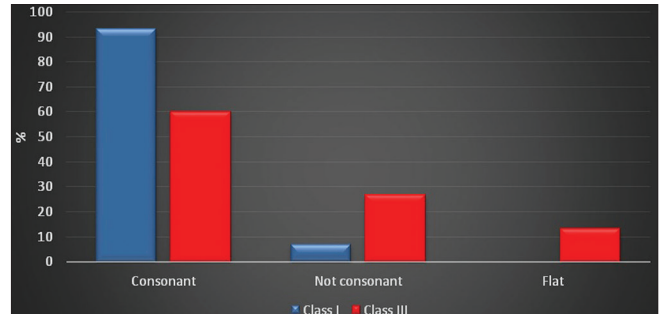


Figure 5: Bar chart representing smile arc distribution of Class I and Class III females

Table 3: Comparison between smile arcs of Class III and Class I females on smiling

	Class I (n=15)		Class III (n=15)		P	Effect size (v)
	n	%	n	%		
Consonant	14	93.3	9	60	0.095	0.404
Not consonant	1	6.7	4	26.7		
Flat	0	0	2	13.3		

\*Significant at  $P \leq 0.05$

the upper lip length however, they were influenced by vertical maxillary excess and greater muscular capacity to raise the lips. Although the intercommissure width at rest was found to be significantly wider for skeletal Class I females, the smile width was found to be significantly wider for Class III females which disagree with the results

of Malhotra *et al.*<sup>[8]</sup> who showed that subjects with Class I showed maximum smile width. Abraham *et al.*<sup>[19]</sup> reported a positive correlation between the lower facial height and smile width which was in contrast to the findings of this study where Class III females showed wider smile widths associated with reduced lower facial height. In this study, Class III females showed significantly longer chin height which could be due to the prognathic mandibular pattern found for skeletal Class III subjects. The impact of buccal corridors on smile esthetics was investigated by Gracco *et al.*,<sup>[20]</sup> Ker *et al.*,<sup>[16]</sup> and Martin *et al.*<sup>[21]</sup> who concluded that large buccal corridors were considered less attractive. On the other hand, McNamara *et al.*<sup>[22]</sup> and Roden-Johnson *et al.*<sup>[23]</sup> and Sachdeva *et al.*<sup>[24]</sup> didn't find connection between buccal corridors and smile esthetics. In this study, the buccal corridor was found to be insignificantly different between both skeletal patterns which came in agreement with Malhotra *et al.*<sup>[8]</sup> who pointed out that buccal corridors in Class III subjects did not influence the smile.

Sarver<sup>[25]</sup> focused on getting the perfect consonant smile arc which was illustrated by the curvature of the maxillary incisal edges being parallel to the curvature of the lower lip that was similar to the conception of Parekh *et al.*,<sup>[26]</sup> Yoon *et al.*<sup>[27]</sup> and Hulsey<sup>[28]</sup> who pointed out that a flat smile arc would noticeably decrease the attractiveness of smile. In this study, nonconsonant and flat smile arcs represented a higher percentage in Class III compared to Class I females however, it was statistically insignificant which was in agreement with Rashed and Heravi<sup>[7]</sup> who concluded that insignificant difference in smile arcs were found among all malocclusions. Badran and Mustafa<sup>[28]</sup> highlighted that a reverse and flat smile arc had a negative effect on smile esthetics and that the clinician should avoid flat smile arcs to achieve esthetic smiles.

## Conclusion

Class III females tended to have wider smile widths, less gingival display, longer chin heights, shorter lower vertical dimensions and a higher percentage of nonconsonant and flat smile arcs than normal Class I subjects, whereas, at rest, Class I females showed significantly longer upper lip length and wider intercommissural distance than Class III females.

## Financial support and sponsorship

Nil.

## Conflicts of interest

There are no conflicts of interest.

## References

- Toth EK, Oliver DR, Hudson JM, Kim KB. Relationships between soft tissues in a posed smile and vertical cephalometric skeletal measurements. *Am J Orthod Dentofacial Orthop* 2016;150:378-85.
- Simões D, Meyge de Brito G, Teixeira Cangussu MC, Machado AW. Does the vertical position of maxillary central incisors in men influence smile esthetics perception? *Am J Orthod Dentofacial Orthop* 2019;156:485-92.
- Springer NC, Chang C, Fields HW, *et al.* Smile esthetics from the layperson's perspective. *Am J Orthod Dentofacial Orthop* 2011;139:91-101.
- Charavet C, Bernard JC, Gaillard C, Le Gall M. Benefits of Digital Smile Design (DSD) in the conception of a complex orthodontic treatment plan: A case report-proof of concept. *Int Orthod* 2019;17:573-9.
- Sabri R. The eight components of a balanced smile. *J Clin Orthod* 2005;39:155-67.
- Al-Hamdany AKH. Integumental lips' height and separation in different Angle's classes of malocclusions. *Al-Rafidain Dent J* 2007;7:38-49.
- Rashed R, Heravi F. Lip-tooth relationships during smiling and speech: An evaluation of different malocclusion types. *Aust Orthod J* 2010;26:153-9.
- Malhotra S, Sidhu MS, Prabhakar M, Kochhar AS. Characterization of a posed smile and evaluation of facial attractiveness by panel perception and its correlation with hard and soft tissue. *Orthodontics (Chic.)* 2012;13:34-45.
- Kakadiya J, Pattnaik B, Kumari M, Vishnoi P. An evaluation of smile in different malocclusion of local population—A pilot study. *J Dental Med Sci* 2015;14:25-32.
- Leonardi R, Annunziata A, Licciardello V, Barbato E. Soft tissue changes following the extraction of premolars in nongrowing patients with bimaxillary protrusion. A systematic review. *Angle Orthod* 2010;80:211-6.
- Ackerman JL, Ackerman MB, Brensinger CM, Landis JR. A morphometric analysis of the posed smile. *Clin Orthod Res* 1998;1:2-11.
- Mack MR. Vertical dimension: A dynamic concept based on facial form and oropharyngeal function. *J Prosthet Dent* 1991;66:478-85.
- Peck S, Peck L, Kataja M. The gingival smile line. *Angle Orthod* 1992;62:91-100.
- Hulsey CM. An esthetic evaluation of lip-teeth relationships present in the smile. *Am J Orthod* 1970;57:132-44.
- Mackley RJ. An evaluation of smiles before and after orthodontic treatment. *Angle Orthod* 1993;63:183-9.
- Ker AJ, Chan R, Fields HW, Beck M, Rosenstiel S. Esthetics and smile characteristics from the layperson's perspective: A computer-based survey study. *J Am Dent Assoc* 2008;139:1318-27.
- Chiche G, Pinault A. Diagnosis and treatment planning of esthetic problems. In: *Esthetics of Anterior Prosthodontics*. Quintessence Publishing Co Inc., United States; 2004. p. 13-25.
- Singer R. A study of the morphometric, treatment and esthetic aspects of gingival display. *Am J Orthod* 1974;65:435-6.
- Abraham A, George J, Peter E, Philip K, Chankramamath R, Johns D, *et al.* Establishment of a new relationship between posed smile width and lower facial height: A cross-sectional study. *Eur J Dent* 2015;9:394-9.
- Gracco A, Cozzani M, D'Elia L, Manfrini M, Peverada CGS. The smile buccal corridors: Aesthetic value for dentists and laypersons. *Prog Orthod* 2006;7:56-65.
- Martin AJ, Buschang PH, Boley JC, Taylor RW, McKinney TW. The impact of buccal corridors on smile attractiveness. *Eur J Orthod* 2007;29:530-7.
- McNamara L, McNamar JA Jr, Ackerman MB, Baccetti T. Hard- and soft-tissue contributions to the esthetics of the posed smile in growing patients seeking orthodontic treatment. *Am J Orthod Dentofacial Orthop* 2008;133:491-9.
- Roden-Johnson D, Gallerano R, English J. The effects of buccal corridor spaces and arch form on smile esthetics. *Am J Orthod Dentofacial Orthop* 2005;127:343-50.

24. Sachdeva K, Singla A, Mahajan V, Jaj HS, Negi A. Esthetic and smile characteristics at rest and during smiling. *J Ind Orthod Soc* 2012;46:17-25.
25. Sarver DM. The importance of incisor positioning in the esthetic smile: The smile arc. *Am J Orthod Dentofacial Orthop* 2001;98:111-20.
26. Parekh SM, Fields HW, Beck M, Rosenstiel S. Attractiveness of variations in the smile arc and buccal corridor space as judged by orthodontists and laymen. *Angle Orthod* 2006;76:557-63.
27. Yoon M, Jin TH, Dong JK. A study on the smile in Korean youth. *J Korean Acad Prosthodont* 1992;30:259-70.
28. Badran SA, Mustafa M. Perception of smile attractiveness by laypeople-influence of profession and treatment experience. *Br J Med Med Res* 2014;4:3777-86.