

CASE REPORT

Poncet's disease mimicking rheumatoid arthritis in a patient with suspected Crohn's disease

Miguel Ariza-Prota, Ana Pando-Sandoval, Marta García-Clemente & Pere Casan

Hospital Universitario Central de Asturias (HUCA), Instituto Nacional de Silicosis (INS), Área del Pulmón, Facultad de Medicina, Universidad de Oviedo, Oviedo, Asturias 33011, Spain

Correspondence

Miguel Ariza Prota, Instituto Nacional de Silicosis (INS), Área del Pulmón, Hospital Universitario Central de Asturias (HUCA), Facultad de Medicina, Universidad de Oviedo, Avenida Roma s/n, Oviedo, Asturias 33011, Spain. Tel: +34 695006806; Fax: +34 985108043; E-mail: arizamiguel@hotmail.com

Funding Information

No sources of funding were declared for this study.

Received: 9 July 2015; Revised: 16 October 2015; Accepted: 28 October 2015

Clinical Case Reports 2016; 4(1): 72–75

doi: 10.1002/ccr3.455

Introduction

Polyarthritis in patients with active tuberculosis was first described by Antonin Poncet in 1897. He described a case of polyarthritis in a patient with active lung tuberculosis in which the case resolved without joint damage [1]. Unlike tuberculous arthritis, Poncet's disease is a nondestructive, transient, and migratory polyarthritis that does not include a confirmation of *Mycobacterium tuberculosis* in fluids or articular tissues. We describe a case of Poncet's disease in a patient with suspected Crohn's disease who was eventually diagnosed with pulmonary and intestinal tuberculosis.

Case Report

In June 2014, a 36-year-old female was admitted to the Central University Hospital of Asturias, after 72 h of diffuse abdominal pain and fever. She reported a dry cough, night sweats, diarrhea, asthenia, hyporexia, and an 8-kg weight loss accompanied by swelling and pain in both wrists, knees, and elbows that limited her mobility during

Key Clinical Message

Poncet's disease is a rarely reported entity with an unknown pathogenesis. However, because it has a very favorable prognosis with antituberculosis drugs, we believe it should be considered as a differential diagnosis for patients with fever and polyarthritis of unknown cause, particularly if active tuberculosis is suspected.

Keywords

Bacilloscopy, intestinal tuberculosis, joint, Poncet's disease, pulmonary.

the day for the past 3 months. She had no known toxic habits. The patient was diagnosed with Crohn's disease in May 2014. Since the diagnosis, she had been on proton pump inhibitors and a prednisone treatment without clinical improvement. She had no past surgical or medical history of interest. The physical examination was normal, except for the pulmonary auscultation. Crackles were found in the right upper lobe. A chest X-ray showed bilateral interstitial and alveolar infiltrates that were distributed predominantly in the right lung parenchyma with cavitations in the right upper lobe (Fig. 1A). It is important to mention that a chest X-ray was not performed in May when the patient was diagnosed with Crohn's disease, therefore we were not able to ascertain if the chest infiltrates were present before starting treatment with corticosteroids. Computed tomography of her chest showed bilateral pseudonodular infiltrates that were located predominantly in the right lung (Fig. 1B).

Her laboratory tests (complete blood count, biochemical, and basic coagulation) were within normal ranges, except for her C-reactive protein (CRP) levels, which were 14 mg/L. Bronchoscopy showed a 90% stenosis of the

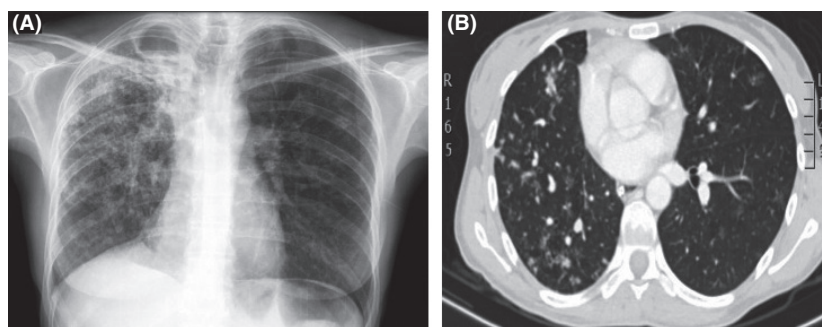


Figure 1. (A) The AP chest X-ray showed a loss of volume in the right lung with ipsilateral mediastinal shift and bilateral interstitial and alveolar infiltrates that were distributed predominantly in the right lung parenchyma with cavitations in the right upper lobe. (B) The CT showed a loss of volume in the right lung and bilateral pseudonodular infiltrates predominantly localized in the right lung.

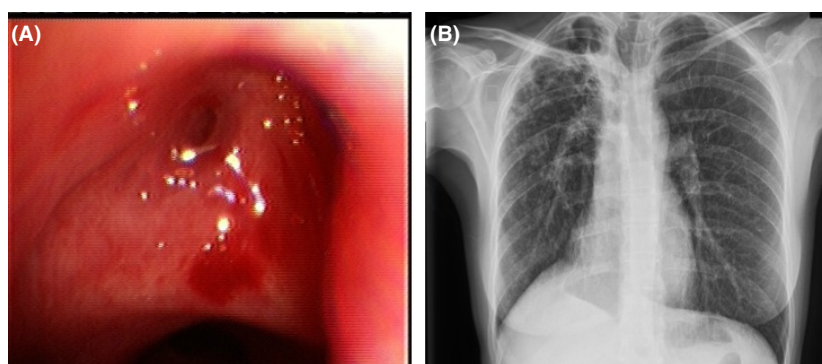


Figure 2. (A) The bronchoscopy showed a 90% stenosis of the segmental bronchi of the right upper lobe and signs of chronic inflammation. (B) The control chest X-ray showed a right lung loss of volume with ipsilateral mediastinal shift and significant improvement of the right upper lobe infiltrate and cavitations.

segmental bronchi of the right upper lobe (Fig. 2A). The bacilloscopy, PCR, and culture from the bronchoaspirate (BAS) identified *M. tuberculosis*. The isolate was sensitive to all tuberculostatic drugs. The patient was treated with oral rifampicin, isoniazid, ethambutol, pyrazinamide, and corticosteroids, all of which were well tolerated. Gastroenterologists re-evaluated the patient during admission and noted important granulomatous inflammation with granulomas localized in the submucosa and adipose serous tissue. *Mycobacterium tuberculosis* grew from a biopsy culture, and the Crohn's disease diagnosis was modified. An intestinal tuberculosis diagnosis was finally confirmed. One week after the patient was discharged, she was admitted again with a diagnosis of peritonitis because of jejunal perforation secondary to intestinal tuberculosis. A jejunal resection and anastomosis were performed without complications. The patient was discharged, and her biopsies again confirmed *M. tuberculosis* growth.

The patient was referred to the Rheumatology department because of migratory arthralgia in her elbows, wrists, and knee joints, particularly in the left knee joint,

without definitive associated synovitis. The patient reported clinical improvement immediately after the tuberculosis treatment, which had been initiated 2 weeks previously. A clinical examination revealed monoarthritis of the left knee joint. A full blood count, liver function tests, and plasma urate levels, in addition to the erythrocyte sedimentation rate and C-reactive protein levels, were normal. The patient was negative for rheumatoid factor against cyclic citrullinated peptide antibodies (ACPA), antinuclear antibodies (ANA), antineutrophil cytoplasmic antibodies (ANCA), and antistreptolysin O antibodies (ASO). Her serum levels of angiotensin-converting enzyme and calcium were normal. The microscopy of synovial fluid aspirated from the left knee joint revealed 0.1×10^9 leukocytes/L (normal range $<0.2 \times 10^9$ /L) with a predominance of lymphocytes and no crystals.

The synovial biopsy revealed a mild chronic inflammatory cell infiltrate, but no histological feature characteristics of tuberculosis were present. The results from the synovial fluid, tissue cultures, and acid-fast bacilli (AFB) smears for the presence of *M. tuberculosis* were all

negative. The patient was then diagnosed with Poncet's disease. She continued treatment with rifampicin, isoniazid, pyrazinamide, and ethambutol. Within a month of initiating this therapy, the joint pains had completely resolved. A control chest X-ray that was performed in December 2014 showed a loss of volume in the right lung. The previously observed infiltrate and cavitation in the right upper lobe had significantly improved (Fig. 2B). The patient was well at the 4-month and 6-month follow-up visits.

Discussion

Poncet's disease is a very rare entity that is characterized by nondestructive, transient, and migratory polyarthritis without confirmation of *M. tuberculosis* in fluids or articular tissues. This disease is also characterized by a complete resolution with tuberculosis treatment. Although the presence of this disease has been previously questioned, sufficient scientific evidence supports its existence [1]. Although the pathogenesis of Poncet's disease is unclear, it is thought to be mediated by immune cells without a direct bacteriological infiltration in the joint itself. It is thought to be caused by an immune hypersensitivity response to tuberculo-proteins that produces a reaction in joint spaces similar to those produced by erythema nodosum in the skin, which also occurs in active lung tuberculosis [1]. It is possible that these two conditions are different manifestations of a common immunogenic response to mycobacterial antigens [2].

Poncet's disease involves large and small joints and is associated with negative synovial fluid cultures. It is diagnosed by excluding [3] other probable causes of arthritis. Although RF and ACPA are very useful markers for rheumatoid arthritis diagnosis, it is necessary to exclude other pathogenesis before the new RA criteria can be appropriately used, since RF and ACPA are also detectable in a variety of disorders, such as connective tissue disease, mixed cryoglobulinemia, and nonrheumatic diseases such as infectious endocarditis, tuberculosis, primary biliary cirrhosis, and malignancy [4]. Tuberculosis infection, in particular, is associated with a positive result for RF and ACPA; 8–60% of tuberculosis cases are positive for RF and 7–39% of tuberculosis cases are positive for ACPA [4]. Therefore, RF- or ACPA-positive arthritis should not be considered as having RA without further investigation. Endoscopic mucosal biopsy specimens obtained through fiberoptic sigmoidoscopes or colonoscopes from the rectum, different areas of the colon, the ileocaecal valve, and the terminal ileum provide the possibility of histological confirmation of the diagnosis of TEC or Crohn's disease even in suspected early cases. Caseating granulomas and acid-fast bacilli, diagnosis tuberculosis

are, however, present only in a small proportion of patients, and several histological parameters considered characteristic of Crohn's disease such as discontinuous chronic inflammation, focal lesions, and microgranulomas have not been evaluated in biopsy specimens from patients with tuberculosis [5].

Tuberculosis treatment yields remarkable relief and disappearance of the polyarthritis [6]. Importantly, TB patients also exhibit positive results from RF and ACPA assays [7]. Therefore, it is difficult to make an accurate diagnosis based only on positivity for these antibodies in patients with suspected TB infection. Although Poncet's disease resembles other reactive arthritis conditions, it has different clinical features [8]. First, reactive arthritis tends to occur at a younger age. Second, in Poncet's disease, arthritis occurs with an initial infection of or through the reactivation of TB with extra-articular manifestations. Other reactive arthritis conditions usually occur 1–4 weeks after an infection and after the infectious symptoms are resolved [9]. Third, and most importantly, arthritis associated with Poncet's disease can be treated with anti-TB therapy and improves within several weeks to several months [10]. Other reactive arthritis conditions must be treated with anti-inflammatory agents, including glucocorticoids and disease-modifying antirheumatic drugs, and they occasionally take longer than 6 months to improve.

Poncet's disease is a rarely reported entity with an unknown pathogenesis. However, because it has a very favorable prognosis with antituberculosis drugs, we believe that Poncet's disease should be considered as a differential diagnosis of patients with fever and polyarthritis of unknown cause, particularly if active tuberculosis is suspected, never forgetting that TB may predominantly manifest in extra pulmonary sites when the diagnosis may prove challenging.

Consent

Written informed consent was obtained from the patient for the publication of this case report and the accompanying images. A copy of the written consent is available for review by the Editor of this journal.

Conflict of Interest

All authors intellectually contributed to the work. They meet the authorship conditions, have approved the manuscript, and agree with its submission to the *Clinical Case Reports* Journal. With their permission, I declare that the work is original and has not been previously submitted to another journal for publication. There are no conflicts of interest by any of the authors of this manuscript.

References

1. Bhargava, A., A. Malaviya, and A. Kumar. 1998. Tuberculous rheumatism (Poncet's disease)-A case series. *Indian J. Tuberc.* 45:215–219.
2. Simcock, D., D. Mukherjee, and N. S. Gendi. 2004. Poncet's disease – a novel cause of compliance with antituberculous drugs. *Respir. Med.* 98:795–797.
3. Dall, L., L. Long, and J. Stanford. 1989. Poncet's disease: tuberculous rheumatism. *Rev. Infect. Dis.* 11:105–107.
4. Shmerling, R. H., and T. L. Delbanco. 1991. The rheumatoid factor: an analysis of clinical utility. *Am. J. Med.* 91:528.
5. Pulimood, A. B., B. S. Ramakrishna, G. Kurian, S. Peter, S. Patra, V. I. Mathan, et al. 1999. Endoscopic mucosal biopsies are useful in distinguishing granulomatous colitis due to Crohn's disease from tuberculosis. *Gut* 45:537–541.
6. Hamed, K., M. Karim, N. Islam, and T. Gibson. 1993. The diagnosis of Poncet's Disease. *Br. J. Rheumatol.* 32:824–826.
7. Elkayam, O., R. Segal, M. Lidgi, and D. Caspi. 2006. Positive anti-cyclic citrullinated proteins and rheumatoid factor during active lung tuberculosis. *Ann. Rheum. Dis.* 65:1110–1112.
8. Sasaki, H., M. Inagaki, M. Shioda, and K. Nagasaka. 2015. Poncet's disease with high titers of rheumatoid factor and anti-citrullinated peptide antibodies mimicking rheumatoid arthritis. *J. Infect. Chemother.* 21:65–69.
9. Gaston, J. S.. 2013. Reactive arthritis and undifferentiated spondyloarthritis. Pp. 1221–1231 in G. S. Firestein, R. C. Budd, S. E. Gabriel, I. B. McInnes, J. R. O'Dell, eds. *Kelley's textbook of rheumatology*. 9th edn. Saunders Elsevier, Philadelphia.
10. Kroot, E. J., J. M. Hazes, E. M. Colin, and R. J. Dolhain. 2007. Poncet's disease: reactive arthritis accompanying tuberculosis. Two case reports and a review of the literature. *Rheumatology (Oxford)* 46:484–489.