

OPEN

Computed Tomography–Guided Interstitial Brachytherapy for Locally Advanced Cervical Cancer

Introduction of the Technique and a Comparison of Dosimetry With Conventional Intracavitary Brachytherapy

Zhong-Shan Liu, MD,* Jie Guo, MD,* Yang-Zhi Zhao, MD,† Xia Lin, BS,* Bing-Ya Zhang, MD,* Chu Zhang, BS,* Hong-Yong Wang, MD,* Lei Yu, MD,* Xiao-Jun Ren, MD,* and Tie-Jun Wang, MD, PhD*

Objective: We present a new technique of 3-dimensional computed tomography–guided interstitial (IS) brachytherapy (BT) for locally advanced cervical cancer, offering a more advantageous clinical treatment approach.

Materials/Methods: Interstitial BT was performed using an applicator combining uterine tandem and metal needles; needles were inserted freehand under real-time 3-dimensional computed tomography guidance. Twenty-eight patients with bulky tumors and/or parametrial extension (tumor size > 5 cm) after external beam radiotherapy received IS BT. Dosimetric outcomes of the IS BT including the total dose (external beam radiotherapy and high dose-rate BT) D90 for the high-risk clinical target volume (HR-CTV) and D2cc for the organs at risk (OARs) were investigated and compared with a former patient group consisting of 30 individuals who received the conventional intracavitary (IC) BT.

Results: The mean D90 values for HR-CTV in the IC BT and IS BT groups were 76.9 ± 5.7 and 88.1 ± 3.3 Gy, respectively. Moreover, 85.7% of the patients received D90 for HR-CTV of 87 Gy or greater in the IS BT group, and only 6.7% of the patients received D90 for HR-CTV of 87 Gy or greater in the IC BT group. The D2cc for the bladder, rectum, and sigmoid were 84.7 ± 6.8 , 69.2 ± 4.2 , and 67.8 ± 4.5 Gy in the IC BT group and 81.8 ± 6.5 , 66.8 ± 4.0 , and 64.8 ± 4.1 Gy in the IS BT group. The mean number of needles was 6.9 ± 1.4 , with a mean depth of 2.9 ± 0.9 mm for each IS BT. Interstitial BT was associated with only minor complications.

Conclusions: The IS BT technique resulted in better dose-volume histogram parameters for large volume tumors (>5 cm) compared with the conventional IC BT and acceptable risk of acute complications in locally advanced cervical cancer and is clinically feasible.

Key Words: Computed tomography, Interstitial brachytherapy, Cervical cancer

Abbreviations: BT-brachytherapy, 3D-3 dimensional, CT-computed tomography, EBRT-external beam radiotherapy, HR-CTV-high-risk clinical target volume, OAR-organ at risk, IBBT-image-based BT, MRI-magnetic resonance imaging, IC/IS-intracavitary/interstitial, DVH-dose-volume histogram, EQD2-the equivalent dose in 2 Gy, D90-the minimum dose delivered to 90% of the target volume

*Department of Radiation Oncology, The Second Affiliated Hospital of Jilin University; and †Cancer Center, The First Affiliated Hospital of Jilin University, Changchun, China.

Copyright © 2017 The Author(s). Published by Wolters Kluwer Health, Inc. on behalf of IGCS and ESGO. This is an open-access article distributed under the terms of the Creative Commons Attribution-

ISSN: 1048-891X

DOI: 10.1097/IGC.0000000000000929

Non Commercial-No Derivatives License 4.0 (CCBY-NC-ND), where it is permissible to download and share the work provided it is properly cited. The work cannot be changed in any way or used commercially without permission from the journal.

Address correspondence and reprint requests to Tie-Jun Wang, MD, PhD, Department of Radiation Oncology, The Second Affiliated Hospital of Jilin University, 218 Zi Qiang St, Changchun 130041, China. E-mail: wangtiejunju@163.com. The authors declare no conflicts of interest.

Received July 25, 2016, and in revised form October 26, 2016.

Accepted for publication November 13, 2016.

(*Int J Gynecol Cancer* 2017;27: 768–775)

Brachytherapy (BT) combined with external beam radiotherapy (EBRT) and concomitant cisplatin is the standard treatment approach for locally advanced cervical cancer.^{1–3} Image-based BT (IBBT), which is used to prescribe the dose to the target volume, has shown an advantage for the dose-volume histogram (DVH) parameters over the conventional 2-dimensional approach with the dose prescribed to point A.^{4,5} In 2005, 3-dimensional (3D) target concepts on the gross tumor volume, the high-risk clinical target volume (HR-CTV), and the intermediate-risk CTV based on magnetic resonance imaging (MRI) for BT were introduced according to the Group Européen de Curiothérapie-European Society for Therapeutic Radiology and Oncology guidelines.^{6,7} Three-dimensional IBBT using computed tomography (CT) or MRI is being used in some international centers and has shown an improvement in enhancing local control and decreasing toxicity rates.^{8,9}

Magnetic resonance imaging–based BT is becoming increasingly prevalent; MRI provides superior soft tissue visualization for the delineation of target volume compared with CT.^{10,11} However, the application of MRI for BT is difficult because of the absence of MRI facilities in most clinics, high cost, and increased time required. Computed tomography is more common in the radiation oncology department; as a result, CT-based BT is easier to perform, and guidelines for the delineation of target volume for CT-based BT have been published.¹² The lateral extension is usually greater on CT than on MRI; however, both CT and MRI are adequate for DVH evaluation of the organs at risk (OARs).¹³

Image-based BT could optimize the dose to the target volume while sparing the surrounding OARs.^{4,14} Nevertheless, the traditional image-based intracavitary (IC) technique is unsuitable for large-volume tumors and/or unfavorable topography.¹⁵ Interstitial (IS) BT applicators have been developed to overcome these problems. The new combined IC/IS BT applicators, such as the tandem-ring Vienna applicator and the tandem-ovoid Utrecht applicator, in which the additional needles are inserted via holes in IC applicators, are typical representatives of this group.^{15,16} There are several drawbacks to using these applicators; the plastic needles that are placed in the ring or ovoid cannot be reused, are very expensive, and can only guarantee dose coverage of the inner two thirds of the involved parametrium owing to limitation of the angle.¹⁵ Free reusable metal needles are less expensive and available at most centers. Free needles are also feasible for implantation under real-time image guidance at the appropriate angle and direction. In general, accurate implantation of conventional free hand is difficult.

We introduced a new technique of IS BT using the applicator combining uterine tandem and metal needles.

Metal needles were inserted freehand under real-time 3D CT guidance. The DVH parameters for target volume and OAR in patients who underwent IS BT were compared with those of a patient cohort that received treatment according to the conventional IC approach. Our study aimed to determine the clinical feasibility of using our IS technique for bulky tumors and/or lateral parametrial extension.

MATERIALS AND METHODS

Enrollment and Treatment for Patients

A total of 58 patients with biopsy-proven locally advanced cervical cancer were enrolled between October 2012 and July 2015. All patients had large-volume tumors and/or parametrial extension with a remnant tumor of greater than 5 cm after EBRT. The patients were divided into the IS BT group and the IC BT group; 28 patients received IS BT after September 2013, and 30 patients underwent conventional IC BT with tandem/ovoid applicator before September 2013. By then, IS BT had not been introduced into our department. The entire study and the patient treatment procedure were approved by the ethics committee of our institution, and all patients signed informed consents.

A combination of EBRT and concomitant chemotherapy were administered to all patients. External beam radiotherapy was delivered by a 4-field box technique or intensity-modulated radiation therapy (Varian) CT-based treatment planning with 45 Gy in 25 fractions. The pathological proven lymph node dose was added to 60 Gy by using sequential boost technique (4-field box radiation therapy) or simultaneous integrated boost technique (intensity-modulated radiation therapy). All patients received concurrent chemotherapy consisting of 5 or 6 cycles of weekly cisplatin (40 mg/m²). High-dose rate iridium-192 BT was administered 4 or 5 days per fraction to all patients after completing EBRT or during the last week of EBRT. We performed pelvic MRI (1.5 T) before EBRT and 1 day before each BT. The entire treatment time was constrained within 56 days.

CT-guided IS BT Implantation

Interstitial BT with the applicator combining uterine tandem and free metal needles was administered under subarachnoid anesthesia. A variable-length uterine tandem was implanted into the uterine cavity under transabdominal ultrasonography guidance. Four basic IS metal needles (length, 16 cm; diameter, 1.3 mm; Elekta) were inserted into the vaginal vault in the lateral 2-, 4-, 8-, and 10-o'clock positions of the uterine canal parallel to the vagina, and some oblique metal needles were inserted into the parametrial extension or lateral pelvic sidewall involvement at different degrees angled to the vagina, at a depth of approximately 10 mm for the

preliminary implantation. The insertion position and number of these oblique needles were decided by T2-weighted MRI and gynecological examination. Vaginal packing with gauze was used to push away the rectum and bladder and fix the uterine tandem and metal needles.

After the preliminary implantation of metal needles, bladder filling was performed with 50-mL diluted Urografin (dilution, 1:20). Then, we performed the final implantation of needles under real-time 3D CT guidance. Generally, the direction and depth of the needles were adjusted repeatedly based on multiple CT scans (Philips; 4-mm slice intervals) until satisfactory distribution was achieved. Goal parameters included symmetrical distribution of 4 basic needles in the cervical district, accurate oblique needle insertion into the parametrial extension or lateral pelvic sidewall involvement, and distribution of all the needles in the cervix and tumor at a 1-cm distance from the central axis, to provide eligible DVH parameters for the target volume and OAR in the subsequent treatment planning (Fig. 1).

Contouring and Treatment Planning

High-risk CTV, including the whole cervix and any notable tumor remnant, was delineated based on CT images in the 2 groups. Magnetic resonance imaging was not incorporated into the treatment planning for target volume delineation; however, it was used as a reference to assess whether intrauterine involvement was present. Specific borders of

HR-CTV were determined based on the recommendation of Viswanathan et al.¹³ Specifically, the top boundary of HR-CTV was confirmed according to T2-weighted MRI images if intrauterine involvement was detected, the lower boundary of HR-CTV was contoured to the lowest extent of the vaginal tumor according to the result of clinical gynecological examination, and the lateral direction of HR-CTV, including parametrial extension or lateral pelvic sidewall involvement, was contoured based on gynecological examination result and CT images.

The internal treatment plan consisted of 5 high-dose-rate BT fractions with a prescription dose of 6 Gy/fraction. The total dose combining EBRT and BT was converted to the equivalent dose in 2 Gy (EQD2) using the linear quadratic model, with an α/β of 10 for tumor and 3 for normal tissue. The final dose objective was D90 (the minimum dose delivered to 90% of the target volume) of 85-Gy EQD2 or greater for HR-CTV, and dose constraint was D2cc (the minimal dose for the most irradiated 2 cm³) of 90-Gy EQD2 or less for the bladder and D2cc of 70-Gy EQD2 or less for the rectum and sigmoid. Dose optimization in the IC BT and IS BT groups was completed respectively using inverse planning simulated annealing (Oncentra Brachytherapy Planning System; Elekta, Stockholm, Sweden), and dwell times and position of the radioactive source were adjusted manually to meet our dose requirement when the direct treatment plan from inverse planning simulated annealing was substandard. Dose-volume histogram parameters

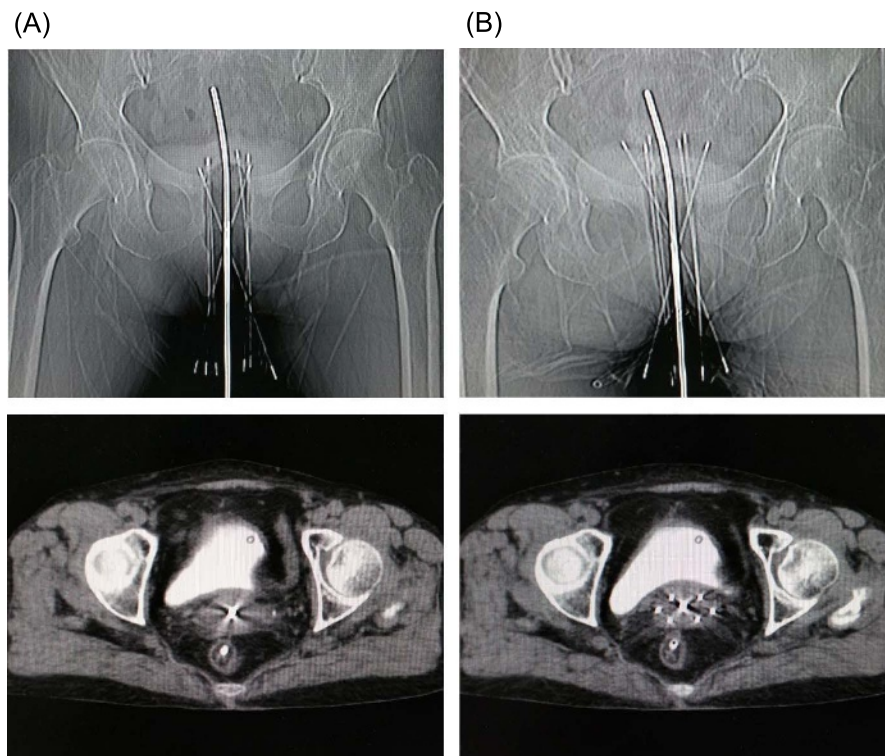


FIGURE 1. Real-time 3D CT-guided implantation of metal needles. A, Preliminary distribution of the needles' direction and depth on the posteroanterior radiograph (top) and the axial CT image (bottom) before adjustment. B, Final distribution of the needles' direction and depth on the posteroanterior radiograph (top) and axial CT image (bottom) after adjustment.

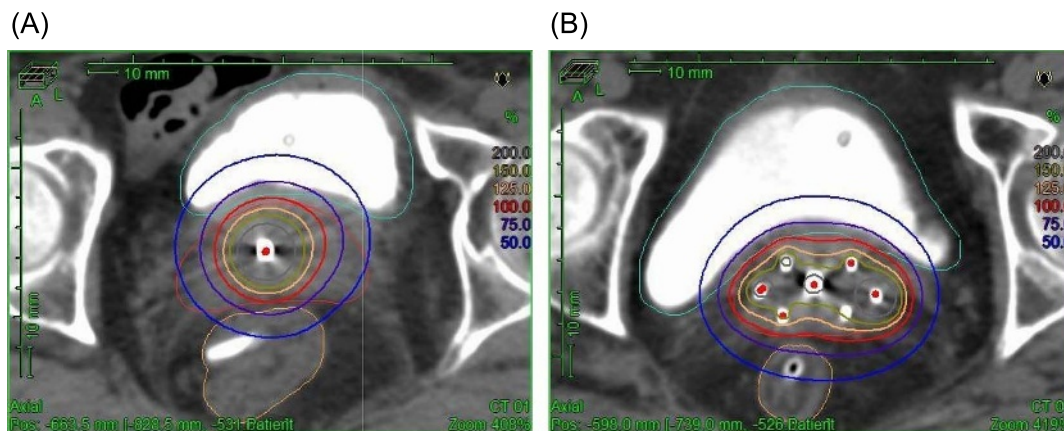


FIGURE 2. Dose distribution in a transverse plane for a conventional IC BT plan (A) and IS BT plan (B). Our IS BT method had the ability to improve the dose coverage of HR-CTV compared with conventional IC BT for patients with large-volume tumor and/or parametrial extension.

including D90 HR-CTV and D2cc for the OAR in the IC BT and IS BT groups were assessed and compared (Fig. 2).

Statistical Analysis

Statistical analysis was performed using SPSS 17.0. Two group comparisons on the clinical tumor characteristics were performed using nonparametric Wilcoxon test. The median and mean values’ comparison of the continuous variables between the 2 groups were performed using a double-sided

independent-samples *t* test. *P* < 0.05 was considered statistically significant.

RESULTS

Patients and Tumor Characteristics

Fifty-eight patients with varied clinical staging based on the International Federation of Gynecology and Obstetrics stage 2009 criteria¹⁷ were enrolled in this study. Patients and tumor

TABLE 1. Patient and tumor characteristics

Characteristics	Category	IC BT Group	IS BT Group	<i>P</i>
Patients	—	30	28	
Median age, y	—	53.6 ± 8.4	52.3 ± 9.0	0.97
Stage	IB2	1 (3.3%)	1 (3.6%)	0.63
	IIA2	2 (6.7%)	0 (0%)	
	IIB	10 (33.3%)	11 (39.3%)	
	IIIA	3 (10.0%)	1 (3.6%)	
	IIIB	14 (46.7%)	15 (53.5%)	
	Histology	Squamous cell carcinoma	27 (90.0%)	
	Adenocarcinoma	2 (6.7%)	1 (3.6%)	
	Adenosquamous carcinoma	1 (3.3%)	1 (3.6%)	
Clinical tumor size, cm	—	6.5 ± 0.9	6.6 ± 0.9	0.89
	5 ≤ tumor size < 6	8 (26.7%)	6 (21.4%)	0.79
	6 ≤ tumor size < 7	14 (46.6%)	15 (53.6%)	
	7 ≤ tumor size < 8	6 (20.0%)	4 (14.3%)	
	Tumor size ≥ 8	2 (6.7%)	3 (10.7%)	
Parametrial involvement	No	3 (10.0%)	1 (3.6%)	0.34
	Yes	27 (90.0%)	27 (96.4%)	
Vaginal involvement	No	6 (20.0%)	5 (17.8%)	0.67
	Upper one third	19 (63.3%)	17 (60.7%)	
	Lower two thirds	5 (16.7%)	6 (21.4%)	
Involvement of the uterus	No	22 (73.3%)	21 (75.0%)	0.89
	Yes	8 (26.7%)	7 (25.0%)	

TABLE 2. D90 of HR-CTV for the IC BT and IS BT groups for all patients and the patients with different tumor sizes, respectively

Subgroup, cm	D90 HR-CTV _{IC} , Gy	D90 HR-CTV _{IS} , Gy	P
Entire population	76.9 (5.7)	88.1 (3.3)	0.000
5 ≤ tumor size < 6	79.4 (6.3)	90.6 (2.8)	0.002
6 ≤ tumor size < 7	77.4 (5.1)	88.2 (2.6)	0.000
7 ≤ tumor size < 8	72.4 (4.7)	86.3 (3.4)	0.001
Tumor size ≥ 8	71.3 (2.6)	85.1 (5.2)	0.043

Dose values are expressed as mean (SD) of EQD2 fractions ($\alpha/\beta = 10$ Gy).

characteristics are described in Table 1. All patients had a large-volume tumor and/or parametrial extension after EBRT, with a mean clinical tumor size of 6.5 ± 0.9 cm in the IC BT group and 6.6 ± 0.9 cm in the IS BT group at the time of the first BT.

DVH Parameters

In total, 150 IC treatment plans and 140 IS treatment plans were performed. Table 2 showed that the mean D90 for HR-CTV in the IC BT group (D90 HR-CTV_{IC}) was less than 77 Gy and the mean D90 for HR-CTV in the IS BT group (D90 HR-CTV_{IS}) reached 88 Gy. A 2-sided *t* test was used to compare the mean values of D90 HR-CTV between the 2 groups and showed that the mean D90 HR-CTV_{IC} was significantly inferior to D90 HR-CTV_{IS} in the entire population, as well as the patients with different tumor sizes ($P < 0.05$). Table 3 showed that IS technique resulted in D90 for HR-CTV_{IS} of 87 Gy or greater in 85.7% patients; however, D90 HR-CTV_{IC} was 87 Gy or greater in only 6.7% of the cases. The results of DVH analysis for OAR are shown in Table 4. The mean D2cc for the rectum and sigmoid was significantly lower in the IS BT group than that in the IC BT group ($P < 0.05$). However, IS technique did not reduce the mean D2cc for the bladder ($P > 0.05$).

IS BT Applicator and Free Needle Implantation

The mean time was 41.2 ± 11.9 minutes for each IS implantation—this was significantly longer compared with the IC implantation time of 25.0 ± 9.5 minutes ($P < 0.01$). The

mean number of CT scans was 2.6 ± 1.3 for each needle placement in the IS BT group.

The mean number of free metal needles was 6.9 ± 1.4 for each application, and the mean implantation depth was 2.9 ± 0.9 mm. Generally, 85.1% of the needles were distributed in the lateral 2- to 5- and 7- to 10-o'clock uterine canal positions. A total of 955 needles were used for 140 IS BT applications; 92.9% of all implanted needles were effective for IS BT.

Free Needle Implantation Complications

During the implantation of needles under real-time 3D CT guidance, 26 IS needles resulted in slight perforation of the mesenterium and/or intestine. This did not require any specific treatment; however, we ensured that the radioactive source was not placed in the perforated area in the subsequent treatment planning. There was no obvious infection during implantation. No case of severe bleeding, requiring transfusion or hospitalization for prolonged periods, was observed.

DISCUSSION

We presented a new technique of IS BT with real-time 3D CT-guided free-hand placement of metal needles combining uterine tandem and compared the DVH parameters of this technique including D90 HR-CTV and D2cc for OAR with those of conventional IC BT for patients with large-volume mass and/or lateral parametrial extension after EBRT. Our IS technique resulted in a more advantageous dose distribution for the HR-CTV, as well as OAR.

TABLE 3. Dose distribution characteristics on D90 of HR-CTV for the IC BT and IS BT groups for all patients and the patients with different tumor sizes, respectively

Subgroup, cm	D90 HR-CTV _{IC}		D90 HR-CTV _{IS}	
	<87 Gy, %	≥87 Gy, %	<87 Gy, %	≥87 Gy, %
Entire population	28 (93.3)	2 (6.7)	4 (14.3)	24 (85.7)
5 ≤ tumor size < 6	6 (75.0)	2 (25.0)	0 (0)	6 (100)
6 ≤ tumor size < 7	14 (100)	0 (0)	2 (13.3)	13 (86.7)
7 ≤ tumor size < 8	6 (100)	0 (0)	1 (25.0)	3 (75.0)
Tumor size ≥ 8	2 (100)	0 (0)	1 (33.3)	2 (66.7)

Dose values are expressed as mean (SD) of EQD2 fractions ($\alpha/\beta = 10$ Gy).

TABLE 4. DVH parameters for OARs for the IC BT and IS BT groups, respectively

Subgroup, cm	Bladder D2cc			Rectum D2cc			Sigmoid D2cc		
	IC BT Group, Gy	IS BT Group, Gy	<i>P</i>	IC BT Group, Gy	IS BT Group, Gy	<i>P</i>	IC BT Group, Gy	IS BT Group, Gy	<i>P</i>
Entire population	84.7 (6.8)	81.8 (6.5)	0.11	69.2 (4.2)	66.8 (4.0)	0.03	67.8 (4.5)	64.8 (4.1)	0.01
5 ≤ tumor size < 6	81.3 (3.9)	79.3 (5.7)	0.46	69.2 (4.9)	63.2 (3.6)	0.03	67.4 (6.3)	60.7 (3.5)	0.04
6 ≤ tumor size < 7	83.1 (7.4)	80.2 (6.1)	0.26	68.3 (4.5)	67.6 (3.9)	0.65	68.4 (3.9)	64.6 (2.6)	0.01
7 ≤ tumor size < 8	91.2 (3.3)	88.1 (5.2)	0.28	70.1 (2.6)	68.5 (3.5)	0.41	66.1 (4.0)	68.4 (3.9)	0.39
Tumor size ≥ 8	90.2 (4.8)	86.5 (5.9)	0.52	72.7 (0.6)	67.5 (2.9)	0.10	69.5 (1.0)	68.9 (5.1)	0.90

Dose values are expressed as mean (SD) of EQD2 fractions ($\alpha/\beta = 3$ Gy).

With the introduction of IBBT, it has been possible to administer sufficient doses to tumors while potentially reducing the dose to OAR.^{4,14} Interstitial BT with the insertion of needles resulted in an optimized dose for large tumors, parametrial extension, or unfavorable topography; therefore, it is a more efficient technique.¹⁸ The 2 classic perineal template IS applicators are the Syed-Neblett butterfly template and Martinez Universal Perineal Template.^{14,19} Although perineal templates can ensure a high dose to lateral parametrial extension, the dose to the fundus and cervical central tumors, which is achieved mainly by intrauterine tandem, may be insufficient.^{20,21} Furthermore, the other disadvantages of perineal template IS BT include uncertainty of the needle position because of the long distance between the template and the tumor, requirement of multiple needles, and serious complications. The combined IC/IS BT using Utrecht or Vienna applicators has improved the DVH parameters and resulted in significant improvement in increasing the local tumor control rate and reducing late toxicity.^{9,22} However, disadvantages of the combined IC/IS BT include inadequate dose for residual distal parametrial tumors, high cost, technological complexity, and long procedural time. Accordingly, the template-based oblique needles, such as a modified Vienna ring applicator (Vienna type 2),²³ which allow IS needles to be inserted obliquely (at a 20° angle) to the intrauterine tandem for distal parametrial disease, were developed. However, the widespread clinical use of the modified IS/IC applicators is limited owing to high cost in most developing countries. Interstitial BT with free-hand implantation of needles was traditionally performed for large-volume tumors, distal parametrial extension, or lateral pelvic sidewall involvement for many years, suggesting that using free needles was clinically feasible.^{24,25} The limitations of using conventional free needles are primarily the difficulty of accurate positioning and low reproducibility owing to the absence of real-time image guidance.

In our department, IS BT using the applicator with free-hand placement of metal needles under real-time 3D CT guidance combining uterine tandem is usually used in the treatment of extensive tumors with poor response to EBRT. Four basic needles parallel to the vagina are used to cover the entire cervix, and oblique needles at different angles to the vagina are used to cover parametrial extension or lateral

pelvic sidewall involvement. Computed tomography plays an important role in not only guiding treatment planning but also ensuring proper needle positioning for target dose coverage; it is a very important procedure, which is performed multiple times, for adjusting the direction and depth of needles repeatedly until satisfactory results are obtained. The entire process of needle adjustment is always performed by 2 experienced gynecological radiation oncologists. The real-time 3D CT-guided implantation of needles may overcome the drawbacks of traditional free needles. Other advantages of our IS technique compared with IC/IS BT include flexibility in needle positioning and angle (especially for distal parametrial extension), procedural simplicity, and low cost. This strategy seems to be particularly useful for the departments with limited resources in most developing countries, where the application of MR and IC/IS template applicators may be unrealistic.

In this study, we delineated HR-CTV based on CT images. Although the width of HR-CTV-based CT was slightly larger than those determined via MRI, the discrepancy was minor for large-volume tumors with poor response to EBRT.¹² Furthermore, the width of HR-CTV determined using CT seems safer because it is unknown whether a relatively smaller target width based on MR omits parametrial residual micrometastases that might develop into parametrial recurrence.¹² There was no significant difference between CT and MRI regarding the delineation of HR-CTV thickness and OAR.¹³ Magnetic resonance imaging was superior to determine intrauterine involvement; however, clinical gynecological examination might be better for the evaluation of vaginal tumors compared with CT and MRI.¹³ Therefore, the delineation of HR-CTV based on CT, consulting MRI and gynecological examination, may be sufficient for large-volume tumors when MRI-based BT is unavailable.¹²

The findings of this study showed that the mean dosimetric gain for D90 HR-CTV was 11.2 Gy using IS technique. This was similar to the finding of a previous study, which showed that a 9.0-Gy benefit for D90 HR-CTV was achieved with IC/IS BT.¹⁵ In that study, the dosimetric benefit was analyzed between the clinically optimized dose plan with needles and historical data without needles.¹⁵ However, our result for dosimetric gain of D90 HR-CTV was significantly superior to that of 2 previous studies: 4.4-Gy and 4.5- to 5-Gy benefits for IC/IS BT, respectively.^{16,25}

A recent study indicated that D90 for HR-CTV of 87-Gy EQD2 or greater could result in higher local control rates.²⁶ Another study also showed that the dose for D90 HR-CTV should be 85- to 90-Gy EQD2 for tumors larger than 4 cm at BT.²² In our study, the mean D90 HR-CTV for all patients reached 88.1 Gy, and for more than 85% of patients, an excellent dosimetric result of D90 HR-CTV of 87 Gy or greater was obtained. Our study showed that the IS technique improved dose coverage of target volume for large tumors and/or distal parametrial disease, likely contributing to improved local control rates.

D2cc was customarily used as the main parameter for dose constraints to OAR because of its valuable correlation with late adverse effects for the bladder, rectum, and sigmoid. The dose constraints to OAR in our center are D2cc of 90 Gy or less for the bladder and D2cc of 70 Gy or less for the rectum and sigmoid based on the results of previous studies.^{27–29} We made an effort to stay within our institutional D2cc constraints for all patients. The IS technique significantly reduced mean D2cc for the rectum and sigmoid, which were restricted within our institutional dose constraints in most patients. However, the mean D2cc for the bladder in the IS group was not lower than that in the IC BT group. The possible reason for this finding is that we focused primarily on D90 HR-CTV, whereas the mean D2cc for the bladder with 81.8 ± 6.5 Gy in the IS group was sufficient. We are also able to reduce D2cc for the bladder further with the IS technique; however, D90 for HR-CTV should also have reduced concomitantly. Our study indicates that this technique is associated with decreasing D2cc for OAR; this may reduce late complications.

The mean number of needles for IS BT in this study was similar to those used in a previous study, wherein the mean numbers of 5.3 ± 2.9 and 5.4 ± 3.0 needles at BT1 and BT2 were used, respectively.²⁵ However, our results were significantly higher than those of the other 2 studies, in which a mean number of 2.7 (range, 1–6) and 3.5 (range, 1–8) needles were used for IC/IS applicators, respectively.^{18,30} It is especially important to determine the number and position of free needles. Generally, according to our clinical experience, 5 to 9 needles are suitable, and most needles in this study were distributed in the lateral 2- to 5- and 7- to 10-o'clock uterine canal positions, usually in the region of the cervix and parametrial extension. The mean implantation depth of free needles in our study was similar to that in a previous study: a mean insertion depth of 25 mm (range, 15–35 mm) for the IC/IS technique.³⁰ More than 92% of all inserted needles were used for BT treatment, which was similar to a former study.²⁵ This demonstrates highly efficient needle placement.

The insertion of free needles may result in inevitable complications, including perforation and bleeding. Slight perforation of the mesentery and/or intestine occurred by accident; however, severe infection owing to perforation did not occur in any of our study patients. Because the needles are thin and blunt, gauze padding was sufficient to resolve milk bleeding owing to needle insertion. In our clinical practice, the blunted needles may contribute to the decreased risk on trauma and bleeding. These results demonstrate that the free needle technique is well tolerated.

In conclusion, the current IS BT technique with real-time 3D CT-guided free-hand placement of metal needles combining uterine tandem showed a dosimetric advantage compared with conventional IC BT for large-volume tumors, distal parametrial extension, or lateral pelvic sidewall involvement (tumor size > 5 cm) and was well tolerated by all study patients. This strategy is clinically feasible and provides a practical treatment choice, in particular, for clinical facilities with limited resources.

REFERENCES

- Rose PG, Bundy BN, Watkins EB, et al. Concurrent cisplatin-based radiotherapy and chemotherapy for locally advanced cervical cancer. *N Engl J Med*. 1999;340:1144–1153.
- Morris M, Eifel PJ, Lu J, et al. Pelvic radiation with concurrent chemotherapy compared with pelvic and para-aortic radiation for high-risk cervical cancer. *N Engl J Med*. 1999;340:1137–1143.
- Tanderup K, Eifel PJ, Yashar CM, et al. Curative radiation therapy for locally advanced cervical cancer: brachytherapy is not optional. *Int J Radiat Oncol Biol Phys*. 2014;88:537–539.
- Jones ND, Rankin J, Gaffney DK. Is simulation necessary for each high-dose-rate tandem and ovoid insertion in carcinoma of the cervix? *Brachytherapy*. 2004;3:120–124.
- Shin KH, Kim TH, Cho JK, et al. CT-guided intracavitary radiotherapy for cervical cancer: comparison of conventional point a plan with clinical target volume-based three-dimensional plan using dose-volume parameters. *Int J Radiat Oncol Biol Phys*. 2006;64:197–204.
- Haie-Meder C, Pötter R, Van Limbergen E, et al. Recommendations from gynaecological (gyn) GEC-ESTRO working group (i): concepts and terms in 3D image based 3D treatment planning in cervix cancer brachytherapy with emphasis on MRI assessment of GTV and CTV. *Radiation Oncol*. 2005;74:235–245.
- Pötter R, Haie-Meder C, Van Limbergen E, et al. Recommendations from gynaecological (gyn) GEC ESTRO working group (ii): concepts and terms in 3d image-based treatment planning in cervix cancer brachytherapy-3D dose volume parameters and aspects of 3D image-based anatomy, radiation physics, radiobiology. *Radiation Oncol*. 2006;78:67–77.
- Kang HC, Shin KH, Park SY, et al. 3D CT-based high-dose-rate brachytherapy for cervical cancer: clinical impact on late rectal bleeding and local control. *Radiation Oncol*. 2010;97:507–513.
- Potter R, Georg P, Dimopoulos JC, et al. Clinical outcome of protocol based image (MRI) guided adaptive brachytherapy combined with 3D conformal radiotherapy with or without chemotherapy in patients with locally advanced cervical cancer. *Radiation Oncol*. 2011;100:116–123.
- Kim SH, Choi BI, Lee HP, et al. Uterine cervical carcinoma: comparison of CT and MR findings. *Radiology*. 1990;175:45–51.
- Brodman M, Friedman FJr, Dottino P, et al. A comparative study of computerized tomography, magnetic resonance imaging, and clinical staging for the detection of early cervix cancer. *Gynecol Oncol*. 1990;36:409–412.
- Viswanathan AN, Erickson B, Gaffney DK, et al. Comparison and consensus guidelines for delineation of clinical target volume for CT- and MR-based brachytherapy in locally advanced cervical cancer. *Int J Radiat Oncol Biol Phys*. 2014;90:320–328.

13. Viswanathan AN, Dimopoulos J, Kirisits C, et al. Computed tomography versus magnetic resonance imaging-based contouring in cervical cancer brachytherapy: results of a prospective trial and preliminary guidelines for standardized contours. *Int J Radiat Oncol Biol Phys.* 2007;68:491–498.
14. Erickson B, Albano K, Gillin M. CT-guided interstitial implantation of gynecologic malignancies. *Int J Radiat Oncol Biol Phys.* 1996;36:699–709.
15. Kirisits C, Lang S, Dimopoulos J, et al. The Vienna applicator for combined intracavitary and interstitial brachytherapy of cervical cancer: design, application, treatment planning, and dosimetric results. *Int J Radiat Oncol Biol Phys.* 2006;65:624–630.
16. Nomden CN, de Leeuw AA, Moerland MA, et al. Clinical use of the Utrecht applicator for combined intracavitary/interstitial brachytherapy treatment in locally advanced cervical cancer. *Int J Radiat Oncol Biol Phys.* 2012;82:1424–1430.
17. Pecorelli S, Zigliani L, Odicino F. Revised FIGO staging for carcinoma of the cervix. *Int J Gynaecol Obstet.* 2009;105:107–108.
18. Harkenrider MM, Alite F, Silva SR, et al. Image-based brachytherapy for the treatment of cervical cancer. *Int J Radiat Oncol Biol Phys.* 2015;92:921–934.
19. Martinez A, Cox RS, Edmundson GK. A multiple-site perineal applicator (mupit) for treatment of prostatic, anorectal, and gynecologic malignancies. *Int J Radiat Oncol Biol Phys.* 1984;10:297–305.
20. Hsu IC, Speight J, Hai J, et al. A comparison between tandem and ovoids and interstitial gynecologic template brachytherapy dosimetry using a hypothetical computer model. *Int J Radiat Oncol Biol Phys.* 2002;52:538–543.
21. Viswanathan AN, Cormack R, Rawal B, et al. Increasing brachytherapy dose predicts survival for interstitial and tandem-based radiation for stage IIIb cervical cancer. *Int J Gynecol Cancer.* 2009;19:1402–1406.
22. Dimopoulos JC, Potter R, Lang S, et al. Dose-effect relationship for local control of cervical cancer by magnetic resonance image-guided brachytherapy. *Radiother Oncol.* 2009;93:311–315.
23. Berger D PR, Dimopoulos J, Kirisits C. New Vienna applicator design for distal parametrial disease in cervical cancer. *Brachytherapy.* 2010;9:S51–S52.
24. Lindegaard JC, Tanderup K. Counterpoint: time to retire the parametrial boost. *Brachytherapy.* 2012;11:80–83.
25. Fokdal L, Tanderup K, Hokland SB, et al. Clinical feasibility of combined intracavitary/interstitial brachytherapy in locally advanced cervical cancer employing MRI with a tandem/ring applicator in situ and virtual preplanning of the interstitial component. *Radiother Oncol.* 2013;107:63–68.
26. Dimopoulos JC, Lang S, Kirisits C, et al. Dose-volume histogram parameters and local tumor control in magnetic resonance image-guided cervical cancer brachytherapy. *Int J Radiat Oncol Biol Phys.* 2009;75:56–63.
27. Fidarova EF, Berger D, Schüssler S, et al. Dose volume parameter D2cc does not correlate with vaginal side effects in individual patients with cervical cancer treated within a defined treatment protocol with very high brachytherapy doses. *Radiother Oncol.* 2010;97:76–79.
28. Georg P, Lang S, Dimopoulos JC, et al. Dose-volume histogram parameters and late side effects in magnetic resonance image-guided adaptive cervical cancer brachytherapy. *Int J Radiat Oncol Biol Phys.* 2011;79:356–362.
29. Levitchi M, Charra-Brunaud C, Quetin P, et al. Impact of dosimetric and clinical parameters on clinical side effects in cervix cancer patients treated with 3D pulse-dose-rate intracavitary brachytherapy. *Radiother Oncol.* 2012;103:314–321.
30. Dimopoulos JC, Kirisits C, Petric P, et al. The Vienna applicator for combined intracavitary and interstitial brachytherapy of cervical cancer: clinical feasibility and preliminary results. *Int J Radiat Oncol Biol Phys.* 2006;66:83–90.