

Obliteration and Contouring of Comminuted Anterior Wall Frontal Sinus Fracture Using Pericranial Flaps

Raghda E. Tallal, MD, PhD
Mina A. Estawrow, MD

Summary: One of the common postoperative complications of comminuted fractures of frontal sinus are contour deformity, hardware extrusion, adherence and/or palpability, and skin thinning. We are presenting our novel technique with pericranial flaps to decrease these complications. The study was performed from January 2019 to January 2020, on 40 cases of comminuted fractures of anterior wall of frontal sinus, 28 men and 12 women, with an average age of 41 years. Injury resulted from motor vehicle crashes (n = 25), motorcycle crashes (n = 11), and falling from heights (n = 4). Our novel technique involves the use of two anteriorly based pericranial flaps; one flap is used for obliteration of the frontal sinus and the other is used to overlay the hardware used to restore forehead contouring and to eliminate the possibility of early extrusion or late plates or mesh palpability. Two patients had postoperative minimal disruption of forehead lacerations healed with secondary intention and minimal scarring. Excellent patient compliance without any complaint of mesh palpability. No adherence occurred and no skin thinning. This technique (two anteriorly based pericranial flaps) may be more reliable to obliterate the frontal sinus also overlaying the hardware used to improve forehead contour and decrease the incidence of mesh palpability and skin adherence than using hardware without flap coverage. (*Plast Reconstr Surg Glob Open* 2021;9:e3670; doi: [10.1097/GOX.0000000000003670](https://doi.org/10.1097/GOX.0000000000003670); Published online 9 August 2021.)

INTRODUCTION

Inadequately treated frontal sinus fractures may result in malposition of fractured segments as well as subsequent distortion of the overlying soft tissue. Such anatomical disruptions could result in contour deformity and also cause recurrent sinusitis, mucocele or mucopyocele, osteomyelitis of the frontal bone, meningitis, encephalitis, brain abscess, or thrombosis of the cavernous sinus.¹

Proper management of frontal sinus fractures is all the more essential because of its proximity to a vital structure, the brain. Despite this, the management of frontal sinus fractures remains controversial because postoperative complications can occur years to decades after the intervention. The consensus on posttraumatic frontal sinus reconstruction is that immediate treatment affords the

best opportunity to restore the facial aesthetics, maintain the sinus function, and prevent many possible long-term complications.

One of the most commonly accepted management algorithms is that proposed by Rohrich and Hollier. Injury of the nasofrontal duct and cerebrospinal fluid (CSF) leak were the key determinants in deciding the treatment plan in this algorithm. Open reduction and internal fixation is commonly required with or without sinus obliteration.²

Various materials both autogenous and alloplastic have been advocated in the literature with varying degrees of success for the obliteration of the frontal sinus and the nasofrontal ducts to prevent mucocele development. These include adipose tissue, bone, temporalis fascia, gelfoam, pericranium, bio-glass, oxidized cellulose and others.³ Although each graft material has its merits and perils, autogenous grafts are favored over allogeneic materials because of their generous clinical history and positive long-term treatment results.⁴

In terms of forehead contour, patients complain of forehead contour irregularity, protrusion or depression as bad sequelae after frontal bone repair. This also causes washboard effect in the overlying soft tissue.⁵

From the Department of Plastic Surgery, Ain Shams University, Cairo, Egypt.

Received for publication March 12, 2020; accepted March 1, 2021.

Copyright © 2021 The Authors. Published by Wolters Kluwer Health, Inc. on behalf of The American Society of Plastic Surgeons. This is an open-access article distributed under the terms of the [Creative Commons Attribution-Non Commercial-No Derivatives License 4.0 \(CCBY-NC-ND\)](https://creativecommons.org/licenses/by-nc-nd/4.0/), where it is permissible to download and share the work provided it is properly cited. The work cannot be changed in any way or used commercially without permission from the journal.

DOI: [10.1097/GOX.0000000000003670](https://doi.org/10.1097/GOX.0000000000003670)

Disclosure: The authors have no financial interest to declare in relation to the content of this article.

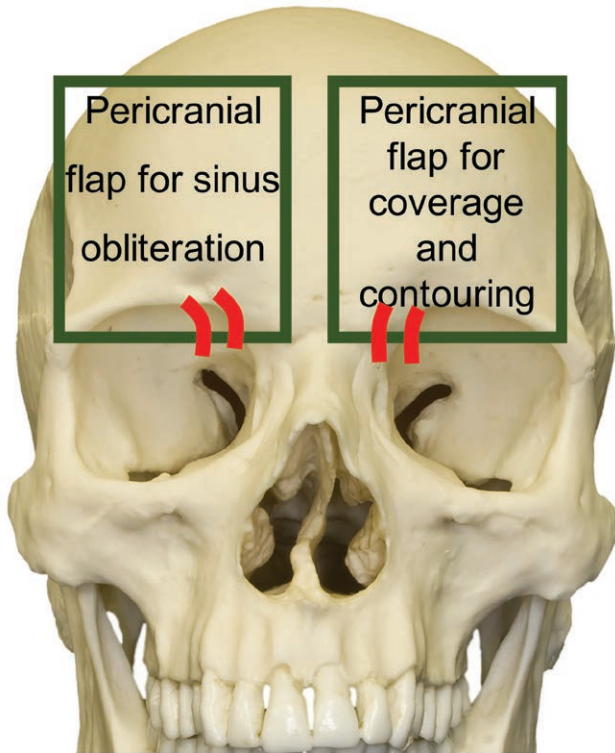


Fig. 1. Design of pericranial flaps. Based on supratrochlear and supraorbital vessels, two flaps are used. The one near the fracture is used for obliteration, and the other one is used to cover the hardware.

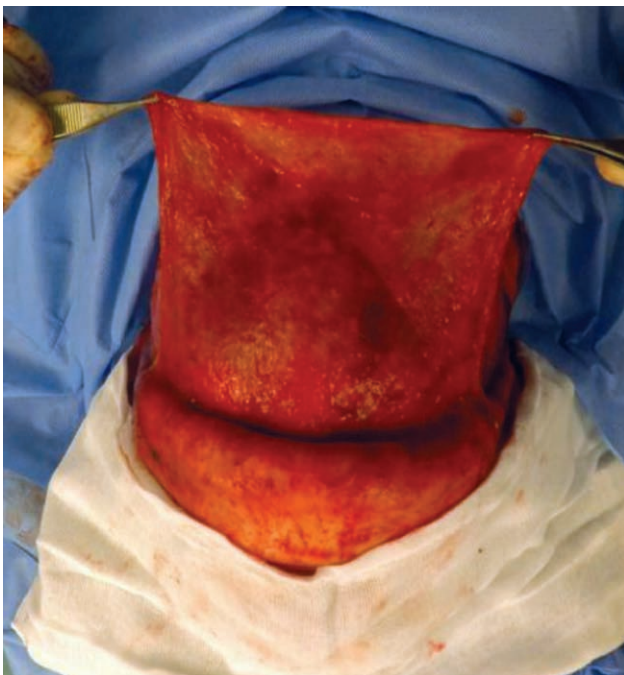


Fig. 2. Elevation of pericranial flap from the underlying calvaria.

Such deformities can occur for one or more of the following reasons: (1) failure to recognize that a displaced fragment will result in bony depression once the overlying

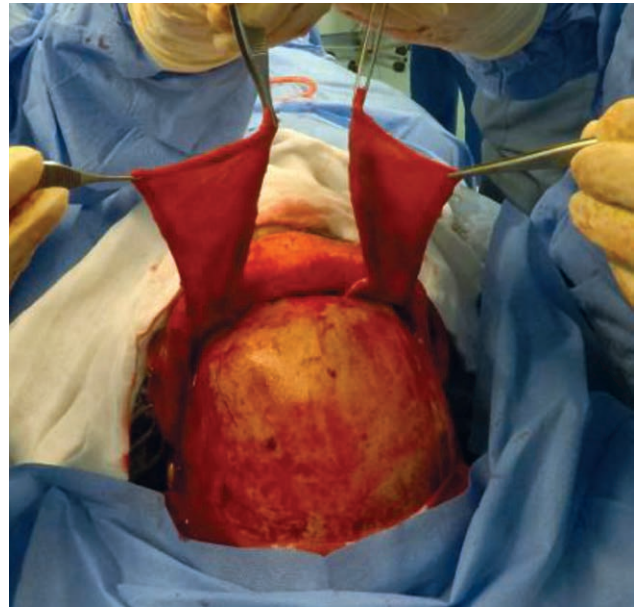


Fig. 3. Splitting into two anteriorly based pericranial flaps.

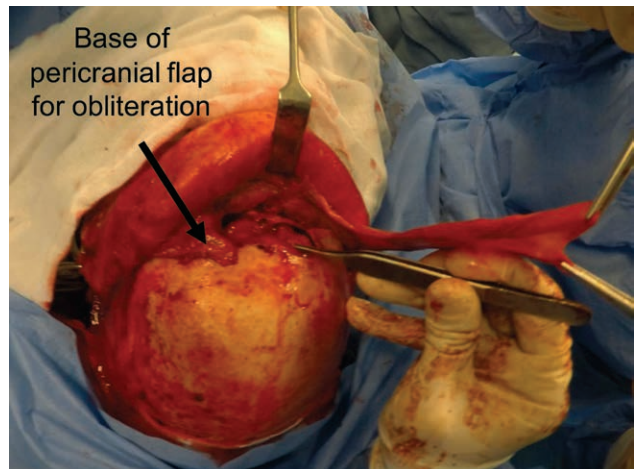


Fig. 4. Obliteration of frontal sinus with pericranial flap, nearer to the fracture

soft tissue edema resolves; (2) inadequate realignment of displaced fragments; (3) overlying soft tissue atrophy caused by high energy injury; (4) palpable metal plates/mesh and screws that were used for fixation of reduced frontal bone. It is important to note that contour deformity represents the most common cause of surgical revision.⁵ Different modalities were used to manage forehead contour deformities after frontal sinus fractures, such as open reduction of displaced fracture, autologous bone graft from calvaria, pelvic bone, or on-lay graft of alloplastic material (as hydroxyapatite cement) or a combination of both.⁶

In addition to bony depressions, patients may suffer from scars or dimples over the forehead as late sequelae. Such changes to skin texture may develop as a result of laceration, abrasion, surgical incision, or from adhesions between skin-soft tissue envelope and underlying hardware. Depressions limited to soft tissue could be treated by filler injection or fat grafting.⁷

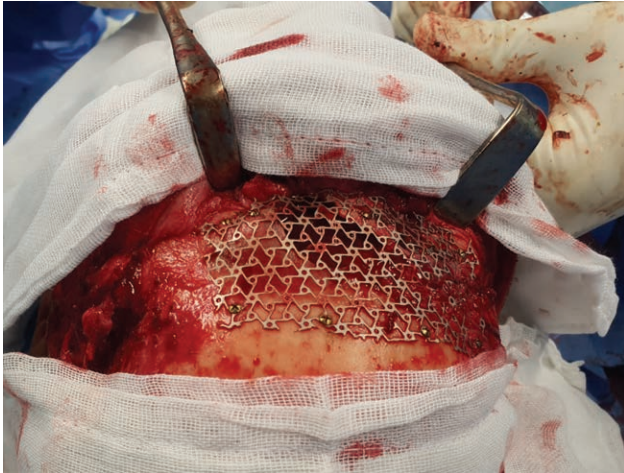


Fig. 5. Large bony fragments are reduced, and titanium mesh is applied and secured with self-drilling screws.

Fat grafting has many advantages over filler injection because it is autologous and semi-permanent. Dermo-fat graft could be an alternative to release severe depression with scarring. However, if there is no previous scar near the depression site, the use of dermo-fat is limited because the surgeon should make a new incision to inset the dermo-fat graft.⁸

It is generally accepted that well-vascularized tissues for sinus obliteration or bone coverage have greater ability to resist local soft tissue infection and prevent osteomyelitis.⁹ So, in this article, we advocate the use of a novel technique to achieve both sinus obliteration and primary restoring forehead contouring with vascularized pericranial flaps to minimize postoperative complications.

MATERIALS AND METHODS

This study was performed on 40 patients between 2015 and 2018. Approval by the institutional review board and patient consent were obtained. Patients were aged between 29 and 50 years, with average of 41 years. Injury resulted from motor vehicle crashes ($n = 25$), motorcycle crashes ($n = 11$) and falling from heights ($n = 4$). All patients had comminuted anterior wall fracture, five patients had additional posterior wall fracture, and only one case had CSF leakage. On average, all the fractures were treated 8 days post trauma. A preoperative CT scan with thin cuts and three-dimensional reconstruction was done before and after fixation. Special consideration was taken in patients with suspected nasofrontal duct. All patients received usual preoperative laboratory investigations. Ophthalmological consultation was done if needed in case of orbital roof trauma. Patients were examined thoroughly for any cerebrospinal fluid leakage. All the expected outcomes and complications were explained to the patients. Antiseptic shampoo wash for the patients' hair was done to decrease incidence of infections. Shaving of a strip of the scalp was done immediately before surgery. Follow-up is done on average 374 days after surgery for mesh palpability, and also for late complications such as mucocele, skin adherence, or thinning.

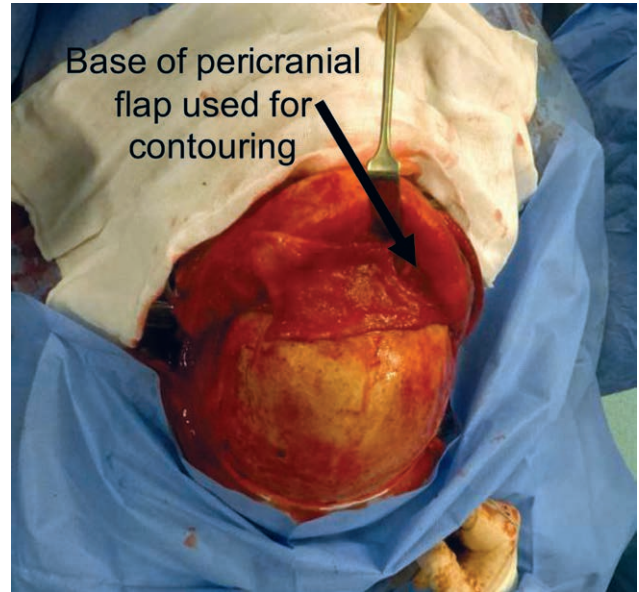


Fig. 6. In-setting of the other pericranial flap to cover the mesh applied.

OPERATIVE DETAILS

Bicoronal incision was made as a reliable, esthetically favorable, and wide exposure approach that provides excellent access to the frontonasal area and potential donor sites (temporalis fascia, muscle, pericranial flap); the conventional scalp-galea flap is dissected anteriorly in the sub-galeal plane to the level of the supra-orbital rim to adequately expose the frontal bone. A design of two pericranial flaps is done (Fig. 1). Each is based on supra-orbital and supratrochlear bundles on either side with an average width of 4–5 cm at the supraorbital rim and increasing its width to more than 6 cm at the vertex. The average length of each pericranial flap is 14 cm.

Once the anteriorly based pericranial flaps are designed, their borders are incised sharply using the superior temporal lines as lateral limits of dissection. The posterior edge of the flap is incised in the region of the vertex to provide adequate flap length 2 cm posterior to the initial scalp incision. A large pericranial flap is then gently elevated from the underlying calvaria using a blunt periosteal elevator from posterior to the level beyond the supraorbital rim (Fig. 2), and then it is divided into two anteriorly based flaps (Fig. 3).

Dealing with the comminuted anterior frontal bone ensues. Large fragments are preserved, whereas the fragmented bony parts are removed. Bony septations within the sinus are also removed. Next, the mucosa of the frontal sinus is meticulously removed with sharp periosteal elevators, and methylene blue test is performed to assess the drainage of the sinus through the naso-frontal duct. Diagnosis of naso-frontal duct injury necessitates sinus obliteration of the duct itself with temporalis muscle, which is easily harvested from the surgical site. The pericranial flap near to the fracture is used for sinus obliteration (Fig. 4). Native bony fragments are reduced. A titanium mesh is secured with self-taping screws and then placed on top, stabilizing the fracture and preserving contour of the

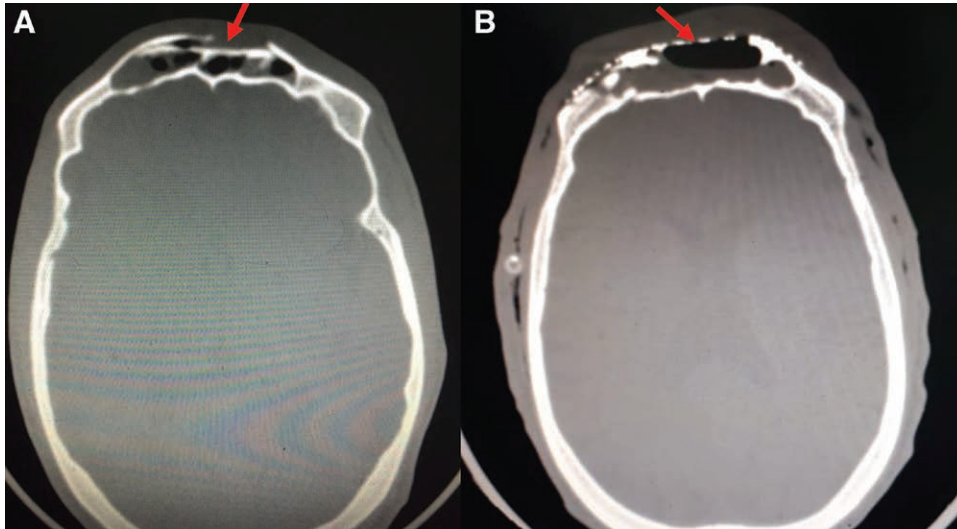


Fig. 7. Preoperative CT scan showing anterior table frontal sinus fracture (A) and post-reduction CT images (B).

forehead (Fig. 5). A small bony defect is left at the edge of the bone grafts so that the pedicle of the pericranial flap used for sinus obliteration will not be compressed.

The other pericranial flap is rotated 90 degrees, draped over, and anchored to the mesh underneath (Fig. 6). A suction drain is applied after inseting of scalp galeal flap, which is then closed in layers. A soft bandage is applied to the head. Postoperative CT scan thin cuts with 3D reconstruction are done routinely for all patients to exclude hardware failure or unjustified bone displacement (Figs. 7, 8). Patients were assessed on a weekly basis for one month to exclude postoperative complications. Any contour deformities or skin adherence were noticed and documented (Fig. 9).

RESULTS

Forty patients (28 men and 12 women) underwent obliteration and reduction of comminuted anterior wall frontal sinus. On average, all the patients were operated on 8 days post trauma. There were no intraoperative incidents. Follow-up for average 373 days after surgery was done. Parameters for follow-up were forehead contour as an aesthetic consideration and complications (hardware extrusions, sinusitis, osteomyelitis, mucopyocele, brain abscess, and cerebrospinal fluid leak), were all evaluated. All patients had good function of the superior division of cranial nerve V examined by light touch and pinprick sensation. Two patients (5%) suffered from disruption of minor forehead lacerations on days 6 and 8 respectively,

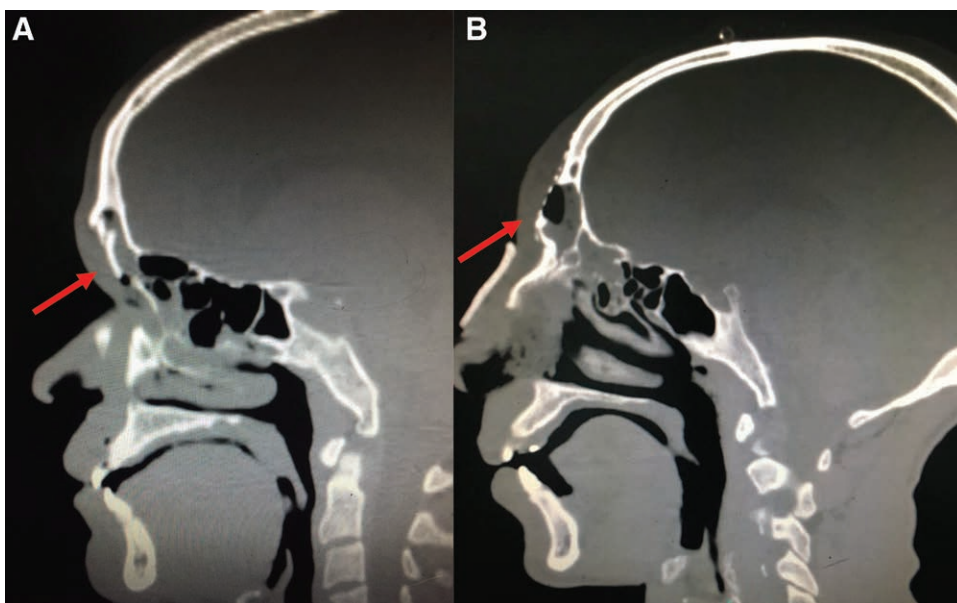


Fig. 8. A 28-year-old man with comminuted fracture anterior wall frontal sinus with contour deformity marked with a red arrow. A, Preoperative image. B, Postoperative image.

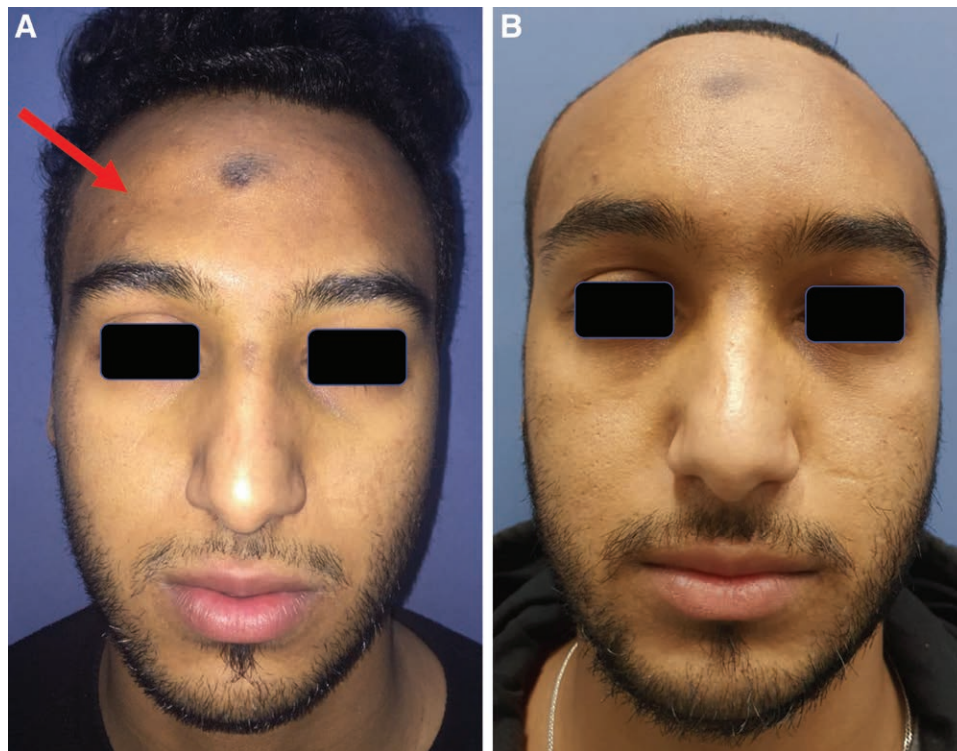


Fig. 9. Patient showing depressed forehead before reduction and fixation, and the postoperative outcome. A, Preoperative photograph. B, Postoperative photograph showing the corrected deformity.

which was allowed to heal by secondary intention and minimal scarring. All patients had excellent cosmetic results as measured by postreduction radiographs, personal and family perceptions of forehead contour, which was evaluated by a questionnaire about the final aesthetic result in comparison with the forehead contour before trauma. There was excellent patient compliance without any complaint of mesh palpability. No late complications such as mucocele, skin adherence, or thinning occurred in any of the cases.

DISCUSSION

Frontal sinus trauma is a heated topic because there are considerable controversies and dispute in the literature regarding what defines the “appropriate” management. Treatment principles aimed at restoring the preoperative frontal contour and facial aesthetics and preventing early and late postoperative complications are recommended.¹⁰

Forehead contour deformities and hardware palpability/extrusion are one of the most distressing complications after repair of fracture anterior wall frontal sinus. The optimal material for preventing this complaint has not yet been delineated. Fat grafting was most frequently used and, less often, free bone grafts and hydroxyapatite cement were used.

The interest in periosteal flaps began in the late 1800s and early 1900s with animal studies regarding the role of periosteum in bone formation. Wolfe first described the pericranial flap in 1978, when he used it for coverage of autogenous bone graft in craniofacial reconstruction.

Owing to its rich vascular supply and undeniable role in bone formation, the use of pericranial flaps has gained popularity.¹¹

This axial flap is based on the deep branches of the supra-orbital and supratrochlear arteries. Venous drainage of the flap is by means of the transverse supraorbital vein.^{12,13}

In maxillofacial trauma surgery, this flap gives the opportunity to seal a CSF leak and provides viable tissue for obliteration of the frontal sinus and the isolation of the intracranial from the para-nasal environment. Because it is locally available during the bi-coronal incision, it obviates the need for other autogenous or allogenic materials.^{14,15}

Morbidity associated with pericranial flaps is low, and few complications have been reported. It is imperative to relieve any bony impingements on the pericranial flap while replacing the bone to prevent compromising its blood supply.¹⁶

The entire flap can be elevated and used to obliterate the frontal sinus or line the anterior cranial fossa, or it can be sectioned in the midline, while maintaining the blood supply to each half of the flap, which will give the advantage of sinus obliteration and prevention of any late contour abnormality, skin thinning, hardware palpability, or extrusion.¹⁷

CONCLUSIONS

The pericranial flap is easily harvested and versatile. Using this flap can give the advantage for both sinus obliteration and coverage of hardware after reduction and fixation of anterior wall frontal sinus to prevent postoperative

complications which may necessitate reoperation. This technique is inexpensive, safe, and effective and should be considered when surgical management of anterior wall frontal sinus comminuted fractures is performed.

Radhda E. Tallal, MD, PhD
5 Abo Ghazalah Buildings
Helmeyet Elzaiton
Cairo, Egypt
E-mail: raghdatalal@med.asu.edu

PATIENT CONSENT

The patient provided written informed consent for the use of his image.

REFERENCES

- Haug RH, Adams JM, Conforti PJ, et al. Cranial fractures associated with facial fractures: a review of mechanism, type and severity of injury. *J Oral Maxillofacial Surg* 1994; 52: 729–733.
- Rohrich RJ, Hollier LH. Management of frontal sinus fractures. Changing concepts. *Clin Plast Surg*. 1992;19:219–232.
- D'Addario M, Haug RH, Talwar RM. Biomaterials for use in frontal sinus obliteration. *J Long Term Eff Med Implants*. 2004;14:455–465.
- Eppley B, Hollier L, Stal S. Hydroxyapatite cranioplasty:2. Clinical experimental with a new quick-setting material. *J Craniofacial Surg*. 2003;10:209–214.
- Kim DW, Yoon ES, Lee BI, et al. Fracture depth and delayed contour deformity in frontal sinus anterior wall fracture. *J Craniofac Surg*. 2012;23:991–994.
- Tieghi R, Consorti G, Clauser LC. Contouring of the forehead irregularities (washboard effect) with bone biomaterial. *J Craniofac Surg*. 2012;23:932–934.
- Xie Y, Li Q, Zheng D, et al. Correction of hemifacial atrophy with autologous fat transplantation. *Ann Plast Surg*. 2007;59:645–653.
- Petros K, William L. Multilayer integra dermal template for frontal bone contour deformity reconstruction: a novel technique. *Plast Reconstr Surg*. 2014;133:239e–240e.
- Kim YH, Youn SK, Kim JT, et al. Treatment of the severely infected frontal sinus with latissimus dorsi myocutaneous free flaps. *J Craniofac Surg*. 2011;22:962–966.
- Ioannides C, Freihofer HP, Vrieus J, et al. Fractures of the frontal sinus: a rationale of treatment. *Br J Plast Surg*. 1993;46:208–214.
- Wolfe SA. The utility of pericranial flaps. *Ann Plast Surg*. 1978;1:147–153.
- Potparic Z, Jackson IT, Colen LB, et al. The galeo-pericranial flaps in the forehead: a study of blood supply. *Plast Surg Forum* 1994;17:292–294.
- Yoshioka N, Kishimoto S. Anteriorly based pericranial flap: an anatomical study of feeding arteries. *Skull Base Surgery* 1991;1:161–164.27.
- Yoshioka N, Rhoton AL Jr. Vascular anatomy of the anteriorly based pericranial flap. *Neurosurgery*. 2005;57(Suppl 1):11–6; discussion 11.
- Hardy JM, Montgomery WW. Osteoplastic frontal sinusotomy: an analysis of 250 operations. *Ann Otol Rhinol Laryngol*. 1976;85(4 pt 1):523–532.
- Price JC, Loury M, Carson B, et al. The pericranial flap for reconstruction of anterior skull base defects. *Laryngoscope*. 1988;98:1159–1164.
- Fattahi T, DiPasquale J. Utility of the pericranial flap in frontal sinus and anterior cranial fossa trauma. *Int J Oral Maxillofac Surg*. 2009;38:1263–1267.