

Review Article



# A Radiological Assessment of Chronic Subdural Hematomas

Sae Min Kwon <sup>1,2,\*</sup>, Min Ho Lee <sup>1,3,\*</sup>, Youngbeom Seo <sup>1,4,\*</sup>, Young Il Kim <sup>1,5</sup>,  
Hyuk-Jin Oh <sup>1,6</sup>, Kyung Hwan Kim <sup>1,7</sup>, Kyu-Sun Choi <sup>1,8</sup>, and Kyuha Chong <sup>1,9</sup>

<sup>1</sup>Neurotrauma Clinical Practice Guidelines Committee of the Korean Neurotraumatology Society (KNTS-NCPGC), Seoul, Korea

<sup>2</sup>Department of Neurosurgery, Dongsan Medical Center, Keimyung University School of Medicine, Daegu, Korea

<sup>3</sup>Department of Neurosurgery, Uijeongbu St. Mary's Hospital, College of Medicine, The Catholic University of Korea, Seoul, Korea

<sup>4</sup>Department of Neurosurgery, Yeungnam University Hospital, Yeungnam University College of Medicine, Daegu, Korea

<sup>5</sup>Department of Neurosurgery, St. Vincent's Hospital, College of Medicine, The Catholic University of Korea, Seoul, Korea

<sup>6</sup>Department of Neurosurgery, Soonchunhyang University Cheonan Hospital, Cheonan, Korea

<sup>7</sup>Department of Neurosurgery, Chungnam National University Hospital, Chungnam National University School of Medicine, Daejeon, Korea

<sup>8</sup>Department of Neurosurgery, Hanyang University Medical Center, Hanyang University College of Medicine, Seoul, Korea

<sup>9</sup>Department of Neurosurgery, Brain Tumor Center, Samsung Medical Center, Sungkyunkwan University School of Medicine, Seoul, Korea

OPEN ACCESS

Received: Apr 5, 2022

Revised: Apr 15, 2022

Accepted: Apr 17, 2022

Published online: Apr 25, 2022

Address for correspondence:

Kyuha Chong

Department of Neurosurgery, Cancer Center, Samsung Medical Center, 81 Irwon-ro, Gangnam-gu, Seoul 06351, Korea.

Email: kyuhaj@gmail.com

k.chong@samsung.com

\*Sae Min Kwon, Min Ho Lee, and Youngbeom Seo contributed equally to this work as a first author.

Copyright © 2022 Korean Neurotraumatology Society

This is an Open Access article distributed under the terms of the Creative Commons Attribution Non-Commercial License (<https://creativecommons.org/licenses/by-nc/4.0/>) which permits unrestricted non-commercial use, distribution, and reproduction in any medium, provided the original work is properly cited.

ORCID iDs

Sae Min Kwon

<https://orcid.org/0000-0001-9720-6037>

Min Ho Lee

<https://orcid.org/0000-0001-6174-7579>

Youngbeom Seo

<https://orcid.org/0000-0001-5568-3636>

Young Il Kim

<https://orcid.org/0000-0001-6758-4344>

Hyuk-Jin Oh

<https://orcid.org/0000-0001-7189-1267>




## ABSTRACT

Chronic subdural hematoma (CSDH), which generally occurs in elderly patients, is a frequently diagnosed condition in neurosurgical departments. Computed tomography (CT) and magnetic resonance imaging (MRI) are the most preferred diagnostic modalities for CSDH assessment. With early diagnosis and adequate management, CSDH may show favorable prognosis in majority of the patients; however, recurrence after surgery can occur in a significant number of patients. The recently increasing number of CSDH studies could reveal the prognostic factors affecting CSDH recurrence. Particularly, radiological characteristics regarding the internal architecture of CSDH are considered closely associated with recurrence in surgically treated CSDH patients. In this literature review, we evaluated the various diagnostic modalities of CSDH and its radiological characteristics on CT and MRI. Furthermore, we summarized the prognostic factors of recurrence for the hematoma type based on the radiological findings.

**Keywords:** Hematoma, subdural, chronic; X-ray, computed tomography; Magnetic resonance imaging; Diagnosis; Recurrence

## INTRODUCTION

Chronic subdural hematoma (CSDH), which generally occurs in elderly patients, is a frequently diagnosed condition in the neurosurgical department.<sup>2,49)</sup> The overall incidence of CSDH is estimated as 1.72–20.6/100,000 per year, and it increases significantly in the population aged >65 years.<sup>34,42,61)</sup> The pathophysiology for formation of CSDH remains unclear, and a current concept supports the notion that prior acute subdural hematoma

Kyung Hwan Kim   
<https://orcid.org/0000-0003-1244-6969>  
Kyu-Sun Choi   
<https://orcid.org/0000-0003-2847-3822>  
Kyuha Chong   
<https://orcid.org/0000-0003-2501-0400>

#### Conflict of Interest

The authors have no financial conflicts of interest.

formation is not the only primary event.<sup>33)</sup> Recently, complex inflammatory reactions, angiogenesis, local coagulopathy, and recurrent micro-hemorrhage have been suggested to play a key role in hematoma formation, expansion, and maintenance.<sup>7,9,11,26)</sup>

The Neurotrauma Clinical Practice Guidelines Committee of the Korean Neurotraumatology Society (KNTS-NCPGC) is striving to develop clinical practice guidelines for neurotraumatic diseases with full support from the society. KNTS-NCPGC selected CSDH as the first topic for the development of clinical practice guidelines, as its prevalence is increasing with aging of the population and the research on the CSDH-associated morbidity according to the diagnosis and treatment strategies is progressing remarkably.<sup>13)</sup> While six key questions for CSDH were developed and their systematic reviews are in progress, we, the KNTS-NCPGC, established a question on the radiological assessment for CSDH diagnosis as the first question.

More specifically, the first question was whether computed tomography (CT) or magnetic resonance imaging (MRI) is useful as a diagnostic modality in CSDH patients with neurological symptoms. Although the question became more specific and narrower, it was intended to be consistent with the development process of the clinical practice guidelines. Despite the limitations in the systematic review for the first question, KNTS-NCPGC has been doing its best to review the radiologic assessment modalities for CSDH systematically, and this review is an “overview review” conducted as a step before the systematic review.

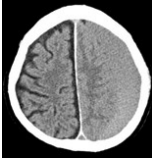
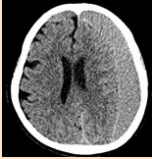
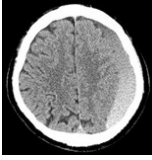
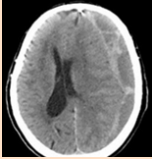
CT and MRI are the most preferred diagnostic modalities for the assessment of CSDH.<sup>39)</sup> Preoperative radiological parameters associated with CSDH recurrence include preoperative thickness and volume of the hematoma, hematoma density, unilateral or bilateral localization, and internal architectures.<sup>3,10,25,40,50,51,60,63)</sup> Particularly, radiological characteristics regarding the internal architecture of CSDH are considered closely associated with recurrence in surgically treated CSDH patients.<sup>44,56)</sup> In this review, we aimed to evaluate the radiological characteristics of CSDH on CT and MRI and summarize the prognostic factors of recurrence regarding the hematoma type based on radiological findings.

## CT SCAN FOR CSDH

Non-contrast CT remains one of the most useful tools in the evaluation of CSDH, owing to its cost effectiveness, rapid availability, and diagnostic sensitivity. CSDH presents various imaging characteristics on CT. As suggested by Nakaguchi et al.,<sup>44)</sup> the type of CSDH with respect to the internal architecture is categorized as homogeneous, laminar, separated, or trabecular (**TABLE 1**).

Several authors have presented the diversity in the rebleeding tendency with regard to the different hematoma types, which corresponds to the possible stages in the natural course of a CSDH.<sup>44,56)</sup> Based on the study by Nakaguchi et al.,<sup>44)</sup> a subdural hygroma progresses into an iso- or hyperdense homogeneous hematoma. This stage is called the homogeneous stage, in which the balance between the coagulative and fibrinolytic activities is maintained and the rebleeding rate is moderate. Sometimes, a high-density line develops during the homogeneous stage to form an indistinct hyperdense structure along the inner membrane, which is called the laminar stage. Due to the greater vascularity of the laminar stage than that of the homogeneous stage, the recurrence rate may be slightly higher in the former than in the latter. As the hematoma matures, fibrinolysis occurs, and the hematoma separates into a

**TABLE 1.** Type of chronic subdural hematoma on computed tomography by internal architecture<sup>24)</sup>

Architecture type	CT scan	Description
Homogeneous		Hematoma exhibiting complete homogeneous density (homogeneous hypo-, iso-, hyperdensity)
Laminar		Hematoma which had thin high-density layer along the inner hematoma membrane
Separated		Hematoma containing two component of different densities (lower density above higher density component) with a clear margin lying between them If the margin is indistinct, hematoma is the gradation type (subtype of separated type)
Trabecular		Hematoma with inhomogeneous density components and a high-density septum

CT: computed tomography.

low-density component lying above a high-density lesion, which is called the separated stage. This separated type hematoma has the highest postoperative rebleeding tendency because of its hyperfibrinolytic activity.<sup>47,56)</sup> After this stage, the hematoma develops trabeculae with moderately hyperdense fibrous tissue lying in a hypo- or isodense matrix.<sup>31)</sup> This trabecular type is considered as the resolution stage of the CSDH, and the risk of bleeding from the hematoma capsule is the lowest because of its fibrous components.<sup>27)</sup>

Ohba et al.<sup>47)</sup> reported recurrence in 177 patients after surgery for CSDH. The reported recurrence rates were 9.0%, 12.5%, 31.0%, and 5.1% in the homogeneous, laryngeal, separated, and trabecular types of hematoma, respectively, which were consistent with previously reported results. The results published by Chon et al.<sup>10)</sup> are also in concordance with those of other studies. They reported the outcome of 420 surgically treated CSDH patients, wherein the recurrence rate was the highest (38%) in the separated type CSDH group. In contrast, none of the 30 patients with trabecular type CSDH experienced hematoma recurrence. The recurrence rates reported in the published literature evaluated

**TABLE 2.** Reported recurrence rate evaluated by type of chronic subdural hematoma in the literature

Studies	Overall recurrence rate (%)	Homogeneous type (%)	Laminar type (%)	Separated type (%)	Trabecular type (%)
Nakaguchi et al. <sup>44)</sup>	16	15	19	36	0
Ohba et al. <sup>47)</sup>	11.3	9.0	12.5	25.0	5.1
Chon et al. <sup>10)</sup>	21.9	7.1	31.0	37.8	0
Stanisic et al. <sup>56)</sup>	14.9	6.5	26.7	29.2	18.8
Oh et al. <sup>46)</sup>	5.8	4.4	2.3	14.1	2.0
Stanišić et al. <sup>57)</sup>	15.9	17.7	37.5	12.5	5.3
Hammer et al. <sup>23)</sup>	26.0	14.3	28.6	36.4	26.3
Jung et al. <sup>29)</sup>	13.7	20.8	16.7	13.6	8.6

**TABLE 3.** Reported recurrence rate within homogeneous hematoma type

Studies	Hypodense hematoma	Isodense hematoma	Hyperdense hematoma
Jeong et al. <sup>28)</sup>	0% (0/37)	0% (0/55)	22.7% (5/22)
Song et al. <sup>55)</sup>	0% (0/15)	7.7% (2/26)	0% (0/6)
Oishi et al. <sup>46)</sup>	0% (0/15)	2.3% (1/43)	17.2% (5/29)
Ko et al. <sup>32)</sup>	1.9% (1/52)	2.5% (3/118)	27.6% (8/29)
Kwon et al. <sup>37)</sup>	0% (0/20)	1.7% (1/59)	3.1% (1/32)
Amirjamshidi et al. <sup>5)</sup>	5.1% (3/59)	7.7% (1/13)	60% (6/10)

by the predefined CSDH type are given in **TABLE 2**. Within the homogeneous type, the recurrence rates were higher in the hyperdense subtype than in the iso- or hypodense subtypes (**TABLE 3**).<sup>5,28,32,37,48,55,56)</sup> These results suggest that CSDH with rapid progression appearing as hyperdense on CT in the relatively acute phase has a high recurrence rate.

Miah et al.<sup>41)</sup> reported a radiological prognostic factor for CSDH recurrence in their meta-analysis. They reported that laminar or separated hematomas presented a higher risk of postoperative recurrence (relative risk [RR] 1.37, 95% confidence interval [CI] 1.04–1.80 and RR 1.76, 95% CI 1.38–2.16, respectively) than those without these features. There was no difference in hematoma recurrence between the trabecular type (RR, 0.88; 95% CI, 0.52–1.49) and non-trabecular type, with high study heterogeneity ( $I^2=61%$ ). Moreover, each type of CSDH seems to have different inflammatory reactions associated with different chemical compositions.<sup>21)</sup> Frati et al.<sup>18)</sup> analyzed the role of the concentration of inflammatory cytokines in the postoperative recurrence of CSDH. In the separated hematoma type group, the concentration of inflammatory cytokines was the highest, which correlated with a greater tendency for rebleeding, whereas the trabecular type showed the lowest concentration, corresponding to low postoperative recurrence. Therefore, if the situation permits, operating in the homogeneous or trabecular stage, and not in the laminar or separated stage, may reduce the recurrence rate.<sup>47)</sup> Stanisic et al.<sup>56)</sup> demonstrated high postoperative recurrence in patients who had undergone surgery within 60 days of head trauma. The authors postulated that surgery of younger hematomas with immature fibrosis of the neomembranes or trabeculae could lead to higher postoperative recurrence.

However, several published studies have described a high recurrence rate in the trabecular type, corresponding to multi-cavitary hematoma.<sup>23,45,58)</sup> The discrepancy in these results may be attributed to the discordance between the architectural categories of hematomas used in various studies (i.e., hematoma with multiplicity of cavities, loculated hematoma, and multilobular or multilayered hematoma) as well as difficulties in determining the correct categories due to intra- or interobserver variability. Although CT is considered a standard diagnostic modality for CSDH, it has several limitations, such as distinguishing between hypodense CSDH and other subdural collections, such as effusion or hygroma.<sup>16,43)</sup> Additionally, isodense hematomas of small sizes are barely recognizable on CT, whereas they are easily diagnosed on MRI.<sup>4,17)</sup> It is also difficult to discern the margin of isodense CSDH, particularly when they are bilateral.<sup>24,54)</sup>

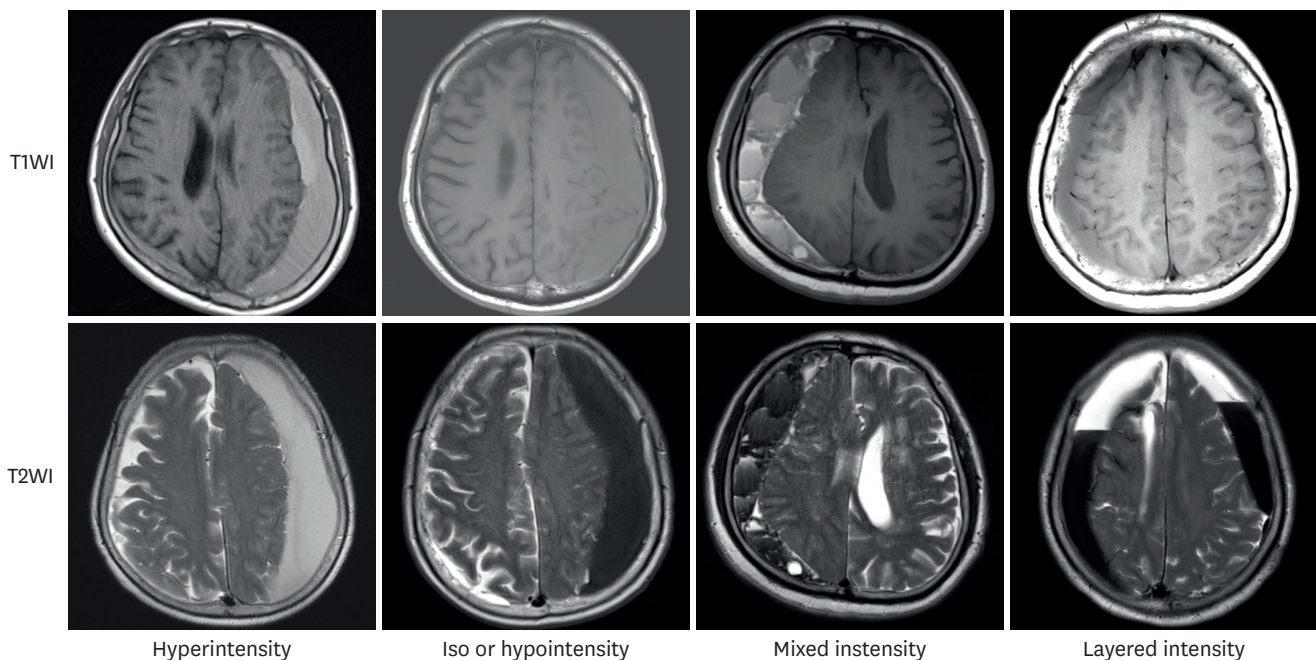
## MRI FOR CSDH

Undoubtedly, the standard diagnostic tool for CSDH is CT; however, many studies continue to report the effectiveness of MRI.<sup>8,20,22,38,59)</sup> Naturally, this is because the hematomas and their internal structures can be identified more accurately on MRI. However, considering the cost and time taken for the examination, there are doubts about its effectiveness.

In the study by Callovini et al.,<sup>8)</sup> an organized hematoma was identified in the subdural space using MRI before surgery. For multilayered or multilobulated hematomas, craniotomy with membranectomy was performed instead of burr hole trephination as the initial treatment. The authors reported a recurrence rate of 6% (2/34 patients). Based on the MRI findings, Goto et al.<sup>22)</sup> classified CSDH into hyperintensity, iso- or hypointensity, mixed intensity, and layered intensity lesions on T1-weighted imaging (WI) and T2WI (FIGURE 1). Iso- or hypointense hematomas were confirmed to have a higher postoperative recurrence rate than that of hyperintense hematomas on T1WI (18.2%, 29/159 patients). Tsutsumi et al.<sup>59)</sup> also reported that when burr hole trephination was performed, non-high signal intensity hematomas on T1WI showed a high recurrence rate of 11.6%, and the bleeding tendency was also high in them.

Fujitani et al.<sup>20)</sup> attempted to predict the growth of a contralateral hematoma after unilateral burr hole trephination in bilateral CSDH. After analysis using the T1 and T2 sequences of MRI, they reported that a significantly greater percentage of the hematomas that were iso- or hypointense on preoperative T1WI showed growth as compared to the other hematomas. In conclusion, Sherrod et al.<sup>52)</sup> conducted a meta-analysis and suggested that preoperative T1 hypo- or isointensity CSDH signals may predict an increased postoperative recurrence risk.

In addition to conventional MRI (T1WI or T2WI), there have been studies using diffusion MRI, which presents images using the movement of water molecules. Typically, a structured hematoma involves thick, fibrous, collagenous membranes, and blood clots. Calcium, hemosiderin, and cholesterol accumulate in the membranes and trabeculae. In contrast, diffusion MRI reveals a low signal intensity for the liquid component, comparable to that of normal cerebrospinal fluid.<sup>6,14,35,36)</sup> Lee et al.<sup>38)</sup> reported the utility of diffusion MRI. When burr hole trephination was performed in CSDH patients, it was reported that hematomas with homogeneous signal intensity on diffusion MRI showed a low recurrence rate. Yokoyama et al.<sup>62)</sup>



**FIGURE 1.** Type of chronic subdural hematoma on magnetic resonance imaging. Hematomas were classified as hyper-, iso-, or hypo-intensity, mixed intensity, and layered intensity lesions on T1WI and T2WI. WI: weighted imaging.

suggested that a reversible decrease in the fractional anisotropy value in the affected pyramidal tract on diffusion tractography correlated with motor weakness. Kuwahara et al.<sup>36)</sup> reported that bleeding in the outer membrane could be confirmed using diffusion MRI. Furthermore, Akgun et al.<sup>1)</sup> reported cases with slightly decreased perfusion on early postoperative perfusion MRI and suggested that it was related to postoperative neurological deterioration.

MRI can show various stages of hemoglobin degradation in the hematoma. If T1WI shows high-signal intensity, it reflects free methemoglobin, whereas low-signal intensity indicates relatively fresh bleeding with deoxyhemoglobin.<sup>30)</sup>

The growth of CSDH is related to the stability of the hematoma.<sup>19)</sup> There appears to be a complex process of inter-related mechanisms that propagates an increase in the hematoma volume, including inflammation, membrane formation, angiogenesis, and fibrinolysis.<sup>12)</sup> Contrary to existing ideas, there are various novel proposals for various the mechanisms and etiologies of CSDH.<sup>15,61)</sup> As it is quite a heterogeneous disease entity, interpretation of CT images alone is considered limited. Although CT can provide information quickly, it may show different densities, even if the time of the occurrence of hemorrhage is similar. On the other hand, compared to CT, MRI can detect hematomas in more detail, especially in cases where the exact time of the trauma is unknown.<sup>53)</sup> To obtain information about these circumstances more objectively, studies using various MRI sequences are warranted. Particularly, in the case of CSDH, which appears isodense on CT, internal architectures such as septa may not be clearly visible on CT. Hence, it is expected that MRI would be of great help in confirming the development of septa and membranes.<sup>58)</sup>

## CONCLUSION

CT and MRI are the most useful diagnostic modalities for the assessment of CSDH. Due to its ease of availability, CT remains the standard diagnostic tool. However, the characteristics and internal structure of a hematoma can be identified more accurately using MRI. As CSDH is a highly heterogeneous disease entity, it presents various imaging characteristics on CT and MRI based on the hematoma type. The reported postoperative recurrence rates vary according to the hematoma type. Predictive information regarding the postoperative recurrence through precise radiological assessment using CT and MRI can provide important guidance for patient treatment and postoperative surveillance.

## ACKNOWLEDGMENTS

We would like to thank the Korean Neurotraumatology Society and Eun-Ji Kang of Korea University College of Medicine for their sincere support and help with the literature search and review.

## REFERENCES

1. Akgun B, Cakin H, Ozturk S, Yildirim H, Okcesiz I, Kazan S, et al. Evaluation of cortical brain parenchyma by diffusion and perfusion mri before and after chronic subdural hematoma surgery. *Turk Neurosurg* 28:405-409, 2018  
[PUBMED](#)

2. Almenawer SA, Farrokhyar F, Hong C, Alhazzani W, Manoranjan B, Yarascavitch B, et al. Chronic subdural hematoma management: a systematic review and meta-analysis of 34,829 patients. *Ann Surg* 259:449-457, 2014  
[PUBMED](#) | [CROSSREF](#)
3. Altaf I, Shams S, Vohra AH. Radiological predictors of recurrence of chronic subdural hematoma. *Pak J Med Sci* 34:194-197 2018.  
[PUBMED](#)
4. Amendola MA, Ostrum BJ. Diagnosis of isodense subdural hematomas by computed tomography. *AJR Am J Roentgenol* 129:693-697, 1977  
[PUBMED](#) | [CROSSREF](#)
5. Amirjamshidi A, Abouzari M, Eftekhari B, Rashidi A, Rezaii J, Esfandiari K, et al. Outcomes and recurrence rates in chronic subdural haematoma. *Br J Neurosurg* 21:272-275, 2007  
[PUBMED](#) | [CROSSREF](#)
6. Augustin M, Bammer R, Simbrunner J, Stollberger R, Hartung HP, Fazekas F. Diffusion-weighted imaging of patients with subacute cerebral ischemia: comparison with conventional and contrast-enhanced MR imaging. *AJNR Am J Neuroradiol* 21:1596-1602, 2000  
[PUBMED](#)
7. Bosche B, Molcanyi M, Noll T, Kochanek M, Kraus B, Rieger B, et al. Occurrence and recurrence of spontaneous chronic subdural haematoma is associated with a factor XIII deficiency. *Clin Neurol Neurosurg* 115:13-18, 2013  
[PUBMED](#) | [CROSSREF](#)
8. Callovini GM, Bolognini A, Callovini G, Gammone V. Primary enlarged craniotomy in organized chronic subdural hematomas. *Neurol Med Chir (Tokyo)* 54:349-356, 2014  
[PUBMED](#) | [CROSSREF](#)
9. Chen JC, Levy ML. Causes, epidemiology, and risk factors of chronic subdural hematoma. *Neurosurg Clin N Am* 11:399-406, 2000  
[PUBMED](#) | [CROSSREF](#)
10. Chon KH, Lee JM, Koh EJ, Choi HY. Independent predictors for recurrence of chronic subdural hematoma. *Acta Neurochir (Wien)* 154:1541-1548, 2012  
[PUBMED](#) | [CROSSREF](#)
11. Drapkin AJ. Chronic subdural hematoma: pathophysiological basis for treatment. *Br J Neurosurg* 5:467-473, 1991  
[PUBMED](#) | [CROSSREF](#)
12. Edlmann E, Giorgi-Coll S, Whitfield PC, Carpenter KL, Hutchinson PJ. Pathophysiology of chronic subdural haematoma: inflammation, angiogenesis and implications for pharmacotherapy. *J Neuroinflammation* 14:108, 2017  
[PUBMED](#) | [CROSSREF](#)
13. Edlmann E, Holl DC, Lingsma HF, Bartek J Jr, Bartley A, Duerinck J, et al. Systematic review of current randomised control trials in chronic subdural haematoma and proposal for an international collaborative approach. *Acta Neurochir (Wien)* 162:763-776, 2020  
[PUBMED](#) | [CROSSREF](#)
14. Fainardi E, Borrelli M, Saletti A, Sarubbo S, Roversi G, Bernardoni A, et al. Temporal changes in perihematoma apparent diffusion coefficient values during the transition from acute to subacute phases in patients with spontaneous intracerebral hemorrhage. *Neuroradiology* 55:145-156, 2013  
[PUBMED](#) | [CROSSREF](#)
15. Feghali J, Yang W, Huang J. Updates in chronic subdural hematoma: Epidemiology, etiology, pathogenesis, treatment, and outcome. *World Neurosurg* 141:339-345, 2020  
[PUBMED](#) | [CROSSREF](#)
16. Fobben ES, Grossman RI, Atlas SW, Hackney DB, Goldberg HI, Zimmerman RA, et al. MR characteristics of subdural hematomas and hygromas at 1.5 T. *AJR Am J Roentgenol* 153:589-595, 1989  
[PUBMED](#) | [CROSSREF](#)
17. Fogelholm R, Heiskanen O, Waltimo O. Chronic subdural hematoma in adults. Influence of patient's age on symptoms, signs, and thickness of hematoma. *J Neurosurg* 42:43-46, 1975  
[PUBMED](#) | [CROSSREF](#)
18. Frati A, Salvati M, Mainiero F, Ippoliti F, Rocchi G, Raco A, et al. Inflammation markers and risk factors for recurrence in 35 patients with a posttraumatic chronic subdural hematoma: a prospective study. *J Neurosurg* 100:24-32, 2004  
[PUBMED](#) | [CROSSREF](#)

19. Fujisawa H, Nomura S, Kajiwara K, Kato S, Fujii M, Suzuki M. Various magnetic resonance imaging patterns of chronic subdural hematomas: indicators of the pathogenesis? *Neurol Med Chir (Tokyo)* 46:333-338, 2006  
[PUBMED](#) | [CROSSREF](#)
20. Fujitani S, Ishikawa O, Miura K, Takeda Y, Goto H, Maeda K. Factors predicting contralateral hematoma growth after unilateral drainage of bilateral chronic subdural hematoma. *J Neurosurg* 126:755-759, 2017  
[PUBMED](#) | [CROSSREF](#)
21. Gandhoke GS, Kaif M, Choi L, Williamson RW, Nakaji P. Histopathological features of the outer membrane of chronic subdural hematoma and correlation with clinical and radiological features. *J Clin Neurosci* 20:1398-1401, 2013  
[PUBMED](#) | [CROSSREF](#)
22. Goto H, Ishikawa O, Nomura M, Tanaka K, Nomura S, Maeda K. Magnetic resonance imaging findings predict the recurrence of chronic subdural hematoma. *Neurol Med Chir (Tokyo)* 55:173-178, 2015  
[PUBMED](#) | [CROSSREF](#)
23. Hammer A, Tregubow A, Kerry G, Schrey M, Hammer C, Steiner HH. Predictors for recurrence of chronic subdural hematoma. *Turk Neurosurg* 27:756-762, 2017  
[PUBMED](#)
24. Hosoda K, Tamaki N, Masumura M, Matsumoto S, Maeda F. Magnetic resonance images of chronic subdural hematomas. *J Neurosurg* 67:677-683, 1987  
[PUBMED](#) | [CROSSREF](#)
25. Huang YH, Yang KY, Lee TC, Liao CC. Bilateral chronic subdural hematoma: what is the clinical significance? *Int J Surg* 11:544-548, 2013  
[PUBMED](#) | [CROSSREF](#)
26. Ito H, Komai T, Yamamoto S. Fibrinolytic enzyme in the lining walls of chronic subdural hematoma. *J Neurosurg* 48:197-200, 1978  
[PUBMED](#) | [CROSSREF](#)
27. Jensen TS, Andersen-Ranberg N, Poulsen FR, Bergholt B, Hundsholt T, Fugleholm K. The Danish Chronic Subdural Hematoma Study-comparison of hematoma age to the radiological appearance at time of diagnosis. *Acta Neurochir (Wien)* 162:2007-2013, 2020  
[PUBMED](#) | [CROSSREF](#)
28. Jeong SI, Kim SO, Won YS, Kwon YJ, Choi CS. Clinical analysis of risk factors for recurrence in patients with chronic subdural hematoma undergoing burr hole trephination. *Korean J Neurotrauma* 10:15-21, 2014  
[PUBMED](#) | [CROSSREF](#)
29. Jung YG, Jung NY, Kim E. Independent predictors for recurrence of chronic subdural hematoma. *J Korean Neurosurg Soc* 57:266-270, 2015  
[PUBMED](#) | [CROSSREF](#)
30. Kara L, Bren RE, Harry B. Gray. Discovery of the magnetic behavior of hemoglobin: A beginning of bioinorganic chemistry. *Proc Natl Acad Sci U S A* 27:13123-13127, 2015
31. Kawano N, Endo M, Saito M, Yada K. Origin of the capsule of a chronic subdural hematoma--an electron microscopy study. *No Shinkei Geka* 16:747-752 1988.  
[PUBMED](#)
32. Ko BS, Lee JK, Seo BR, Moon SJ, Kim JH, Kim SH. Clinical analysis of risk factors related to recurrent chronic subdural hematoma. *J Korean Neurosurg Soc* 43:11-15, 2008  
[PUBMED](#) | [CROSSREF](#)
33. Komiyama K, Tosaka M, Shimauchi-Ohtaki H, Aihara M, Shimizu T, Yoshimoto Y. Computed tomography findings after head injury preceding chronic subdural hematoma. *Neurosurg Focus* 47:E12, 2019  
[PUBMED](#) | [CROSSREF](#)
34. Kudo H, Kuwamura K, Izawa I, Sawa H, Tamaki N. Chronic subdural hematoma in elderly people: present status on Awaji Island and epidemiological prospect. *Neurol Med Chir (Tokyo)* 32:207-209, 1992  
[PUBMED](#) | [CROSSREF](#)
35. Kuwahara S, Miyake H, Fukuoka M, Koan Y, Ono Y, Moriki A, et al. Diffusion-weighted magnetic resonance imaging of organized subdural hematoma--case report. *Neurol Med Chir (Tokyo)* 44:376-379, 2004  
[PUBMED](#) | [CROSSREF](#)
36. Kuwahara S, Fukuoka M, Koan Y, Miyake H, Ono Y, Moriki A, et al. Subdural hyperintense band on diffusion-weighted imaging of chronic subdural hematoma indicates bleeding from the outer membrane. *Neurol Med Chir (Tokyo)* 45:125-131, 2005  
[PUBMED](#) | [CROSSREF](#)
37. Kwon TH, Park YK, Lim DJ, Cho TH, Chung YG, Chung HS, et al. Chronic subdural hematoma: evaluation of the clinical significance of postoperative drainage volume. *J Neurosurg* 93:796-799, 2000  
[PUBMED](#) | [CROSSREF](#)



38. Lee SH, Choi JI, Lim DJ, Ha SK, Kim SD, Kim SH. The potential of diffusion-weighted magnetic resonance imaging for predicting the outcomes of chronic subdural hematomas. *J Korean Neurosurg Soc* 61:97-104, 2018  
[PUBMED](#) | [CROSSREF](#)
39. Markwalder TM. Chronic subdural hematomas: a review. *J Neurosurg* 54:637-645, 1981  
[PUBMED](#) | [CROSSREF](#)
40. Matsumoto K, Akagi K, Abekura M, Ryujin H, Ohkawa M, Iwasa N, et al. Recurrence factors for chronic subdural hematomas after burr-hole craniostomy and closed system drainage. *Neurol Res* 21:277-280, 1999  
[PUBMED](#) | [CROSSREF](#)
41. Miah IP, Tank Y, Rosendaal FR, Peul WC, Dammers R, Lingsma HF, et al. Radiological prognostic factors of chronic subdural hematoma recurrence: a systematic review and meta-analysis. *Neuroradiology* 63:27-40, 2021  
[PUBMED](#) | [CROSSREF](#)
42. Miranda LB, Braxton E, Hobbs J, Quigley MR. Chronic subdural hematoma in the elderly: not a benign disease. *J Neurosurg* 114:72-76, 2011  
[PUBMED](#) | [CROSSREF](#)
43. Mori K, Maeda M. Delayed magnetic resonance imaging with GdD-DTPA differentiates subdural hygroma and subdural effusion. *Surg Neurol* 53:303-310, 2000  
[PUBMED](#) | [CROSSREF](#)
44. Nakaguchi H, Tanishima T, Yoshimasu N. Factors in the natural history of chronic subdural hematomas that influence their postoperative recurrence. *J Neurosurg* 95:256-262, 2001  
[PUBMED](#) | [CROSSREF](#)
45. Nayil K, Ramzan A, Sajad A, Zahoor S, Wani A, Nizami F, et al. Subdural hematomas: an analysis of 1181 Kashmiri patients. *World Neurosurg* 77:103-110, 2012  
[PUBMED](#) | [CROSSREF](#)
46. Oh HJ, Seo Y, Choo YH, Kim YI, Kim KH, Kwon SM, et al. Clinical characteristics and current managements for patients with chronic subdural hematoma: A retrospective multicenter pilot study in the republic of Korea. *J Korean Neurosurg Soc* 65:255-268, 2022  
[PUBMED](#) | [CROSSREF](#)
47. Ohba S, Kinoshita Y, Nakagawa T, Murakami H. The risk factors for recurrence of chronic subdural hematoma. *Neurosurg Rev* 36:145-149, 2013  
[PUBMED](#) | [CROSSREF](#)
48. Oishi M, Toyama M, Tamatani S, Kitazawa T, Saito M. Clinical factors of recurrent chronic subdural hematoma. *Neurol Med Chir (Tokyo)* 41:382-386, 2001  
[PUBMED](#) | [CROSSREF](#)
49. Santarius T, Hutchinson PJ. Chronic subdural haematoma: time to rationalize treatment? *Br J Neurosurg* 18:328-332, 2004  
[PUBMED](#) | [CROSSREF](#)
50. Santarius T, Kirkpatrick PJ, Ganesan D, Chia HL, Jalloh I, Smielewski P, et al. Use of drains versus no drains after burr-hole evacuation of chronic subdural haematoma: a randomised controlled trial. *Lancet* 374:1067-1073, 2009  
[PUBMED](#) | [CROSSREF](#)
51. Shen J, Yuan L, Ge R, Wang Q, Zhou W, Jiang XC, et al. Clinical and radiological factors predicting recurrence of chronic subdural hematoma: A retrospective cohort study. *Injury* 50:1634-1640, 2019  
[PUBMED](#) | [CROSSREF](#)
52. Sherrod BA, Baker C, Gamboa N, McNally S, Grandhi R. Preoperative MRI characteristics predict chronic subdural haematoma postoperative recurrence: a meta-analysis. *Br J Neurosurg* 35:527-531, 2021  
[PUBMED](#) | [CROSSREF](#)
53. Sieswerda-Hoogendoorn T, Postema FA, Verbaan D, Majoie CB, van Rijn RR. Age determination of subdural hematomas with CT and MRI: a systematic review. *Eur J Radiol* 83:1257-1268, 2014  
[PUBMED](#) | [CROSSREF](#)
54. Sipponen JT, Sepponen RE, Sivula A. Chronic subdural hematoma: demonstration by magnetic resonance. *Radiology* 150:79-85, 1984  
[PUBMED](#) | [CROSSREF](#)
55. Song DH, Kim YS, Chun HJ, Yi HJ, Bak KH, Ko Y, et al. The predicting factors for recurrence of chronic subdural hematoma treated with burr hole and drainage. *Korean J Neurotrauma* 10:41-48, 2014  
[PUBMED](#) | [CROSSREF](#)
56. Stanic M, Lund-Johansen M, Mahesparan R. Treatment of chronic subdural hematoma by burr-hole craniostomy in adults: influence of some factors on postoperative recurrence. *Acta Neurochir (Wien)* 147:1249-1256, 2005  
[PUBMED](#) | [CROSSREF](#)

57. Stanišić M, Hald J, Rasmussen IA, Pripp AH, Ivanović J, Kolstad F, et al. Volume and densities of chronic subdural haematoma obtained from CT imaging as predictors of postoperative recurrence: a prospective study of 107 operated patients. *Acta Neurochir (Wien)* 155:323-333, 2013  
[PUBMED](#) | [CROSSREF](#)
58. Tanikawa M, Mase M, Yamada K, Yamashita N, Matsumoto T, Banno T, et al. Surgical treatment of chronic subdural hematoma based on intrahematoma membrane structure on MRI. *Acta Neurochir (Wien)* 143:613-618, 2001  
[PUBMED](#) | [CROSSREF](#)
59. Tsutsumi K, Maeda K, Iijima A, Usui M, Okada Y, Kirino T. The relationship of preoperative magnetic resonance imaging findings and closed system drainage in the recurrence of chronic subdural hematoma. *J Neurosurg* 87:870-875, 1997  
[PUBMED](#) | [CROSSREF](#)
60. Weigel R, Schmiedek P, Krauss JK. Outcome of contemporary surgery for chronic subdural haematoma: evidence based review. *J Neurol Neurosurg Psychiatry* 74:937-943, 2003  
[PUBMED](#) | [CROSSREF](#)
61. Yang W, Huang J. Chronic subdural hematoma: Epidemiology and natural history. *Neurosurg Clin N Am* 28:205-210, 2017  
[PUBMED](#) | [CROSSREF](#)
62. Yokoyama K, Matsuki M, Shimano H, Sumioka S, Ikenaga T, Hanabusa K, et al. Diffusion tensor imaging in chronic subdural hematoma: correlation between clinical signs and fractional anisotropy in the pyramidal tract. *AJNR Am J Neuroradiol* 29:1159-1163, 2008  
[PUBMED](#) | [CROSSREF](#)
63. You W, Zhu Y, Wang Y, Liu W, Wang H, Wen L, et al. Prevalence of and risk factors for recurrence of chronic subdural hematoma. *Acta Neurochir (Wien)* 160:893-899, 2018  
[PUBMED](#) | [CROSSREF](#)