

CASE REPORT

ADVANCED

CLINICAL CASE SERIES/TECHNICAL CORNER

Percutaneous Impella Mechanical Circulatory Support Delivery Using Intravascular Lithotripsy



Robert F. Riley, MD, MS,^a Brian Kolski, MD,^b Chandanreddy M. Devireddy, MD,^c Amir Kaki, MD,^d Antonious Attallah,^d Mitul B. Kadakia, MD,^e Carlo Di Mario, MD,^f Dean Kereiakes, MD^a

ABSTRACT

Intravascular lithotripsy (IVL) may be useful to deliver Impella devices in patients with peripheral arterial disease. Twelve patients were treated with peripheral IVL prior to Impella insertion. A total of 100% of patients underwent successful device implantation with no IVL complications. IVL can facilitate transfemoral access for Impella insertion. **(Level of Difficulty: Advanced.)** (J Am Coll Cardiol Case Rep 2020;2:250-4) © 2020 The Authors. Published by Elsevier on behalf of the American College of Cardiology Foundation. This is an open access article under the CC BY-NC-ND license (<http://creativecommons.org/licenses/by-nc-nd/4.0/>).

Coronary and peripheral arterial calcification increase the complexity of percutaneous treatment strategies and periprocedural complication rates (1-3). Both intimal and medial calcification contribute to arterial wall stiffness and to vessel recoil after endovascular interventions (2). The use of intravascular lithotripsy (IVL) to treat calcified vascular disease using the Shockwave IVL device (Shockwave Medical, Santa Clara, California) in femoropopliteal arteries was recently described

(4,5). Lithotripsy fragments calcified plaque using high-power acoustic sonic pressure waves that pass through soft tissue and selectively interact with calcium. The lack of hard density interface in normal, soft vascular tissue prevents interaction with IVL energy and therefore injury to the vessel wall. The Shockwave IVL device uses multiple emitters mounted on a balloon catheter to provide circumferential pulsatile energy to disrupt calcified plaque by fracturing the calcium and improving acute gain from balloon angioplasty while minimizing vessel injury. Use of the IVL device is rapidly expanding to include facilitation of transfemoral access for a broadening array of large-bore procedures in the catheterization laboratory, including delivery of percutaneous mechanical circulatory support (p-MCS) devices. A recent case report detailed the use of IVL to facilitate delivery of an Impella CP model (Abiomed, Danvers,

LEARNING OBJECTIVES

- IVL can safely facilitate the delivery of large-bore sheaths in patients with calcified PAD.
- Treatment of PAD with IVL may be considered prior to pursuing alternative vascular access for the delivery of large-bore sheaths.

From the ^aOhio Heart and Vascular, Christ Hospital Health System, Cincinnati, Ohio; ^bDivision of Cardiology, Orange County Heart Institute, Orange, California; ^cDivision of Cardiology, Emory University Hospital, Atlanta, Georgia; ^dDivision of Cardiology, St. John's Hospital, Detroit, Michigan; ^eAlta Bates Summit Medical Center, Oakland, California; and the ^fDivision of Cardiology, Careggi University Hospital, Florence, Italy. Dr. Kadakia has received research funding from Shockwave Medical. Dr. Kolski is a proctor for Abiomed. Dr. Devireddy is a consultant for Medtronic and Shockwave Medical; and is a scientific advisory board member for ReCor Medical and Vascular Dynamics. Dr. Kaki is a proctor for Abiomed and Abbott; and has received educational honoraria from Abiomed. Mr. Di Mario has received research support from Shockwave Medical. Dr. Kereiakes is a consultant for Shockwave Medical. All other authors have reported that they have no relationships relevant to the contents of this paper to disclose.

Informed consent was obtained for this case.

Manuscript received September 25, 2019; revised manuscript received November 18, 2019, accepted November 22, 2019.

Massachusetts) p-MCS device in a patient with significant peripheral arterial disease (PAD) (6). The present authors expanded upon that report by using a retrospective multicenter registry evaluating patients who required IVL to facilitate delivery of an Impella CP p-MCS device.

SUBJECTS AND METHODS

The present authors performed a retrospective analysis of data from 6 hospitals (Christ Hospital, Cincinnati, Ohio; Orange County Heart Institute, Orange, California; Emory University Hospital, Atlanta, Georgia; St. John's Hospital, Detroit, Michigan; Alta Bates Summit Medical Center, Oakland, California; and Careggi University Hospital, Florence, Italy) that routinely used MCS from February 1, 2018, to April 1, 2019. Each institution's database was queried for patients who required peripheral IVL using a Shockwave balloon in order to deliver an Impella p-MCS device. Use of p-MCS and IVL could be either planned or unplanned (i.e., elective, urgent, or emergent). Data collected included preprocedural demographics and comorbidities including any history of known PAD. Procedural details were also obtained for each patient, including angiographic characteristics of the coronary and peripheral arteries, preprocedural SYNTAX (Synergy Between Percutaneous Coronary Intervention with Taxus and Cardiac Surgery) scores, treatment strategies, technical success of the percutaneous coronary intervention (PCI) procedure, and in-house major cardiac and cerebrovascular events (MACCE). MACCE included all-cause death, stroke, vascular injury, perioperative myocardial infarction, and acute kidney injury. Death was defined as death from any cause prior to discharge from the index hospitalization. Stroke was defined clinically as a new, persistent neurologic defect that occurred in-hospital after the procedure and persisted beyond 24 h. Vascular injury was defined as access site hematoma >10 cm, access site pseudoaneurysm, and/or access site injury that required unplanned endovascular or surgical intervention. Periprocedural myocardial infarction (MI) was defined according to the European Society of Cardiology/American College of Cardiology Foundation/American Heart Association/World Health Federation task force for the redefinition of myocardial infarction, specifically type 4a, an increase in serum troponin level of more than 3 times the 99th percentile upper reference limit after PCI, along with clinical evidence of ischemia, including angina, new electrocardiography changes suggestive of ischemia, and/or new wall motion abnormalities on cardiac imaging (6). Serial

cardiac biomarkers were only obtained in instances where procedural complications occurred and/or any clinical syndrome suggestive of ischemia developed postoperatively. Acute kidney injury (AKI) was defined according to the KDIGO (Kidney Disease: Improving Global Outcomes) working group as either a 25% increase in baseline serum creatinine or a 0.5 mg/dl increase in absolute serum creatinine value within 48 h after contrast administration (7). Multiple complications could be captured for a single patient if the criteria were met for each outcome.

Categorical variables were presented as frequencies and percentages, whereas continuous variables were presented as medians (interquartile range). All analyses were performed using JMP version 13 software (JMP, Cary, North Carolina).

RESULTS

A total of 12 patients were identified during the study period who underwent IVL-assisted transfemoral p-MCS insertion using an Impella device. Treatments of 9 patients (75%) were planned for device-assisted PCI and 3 for patients (25%) presenting with cardiogenic shock. Baseline characteristics and comorbidities are shown in **Table 1**. Generally, patients in this group were older and male, had a significant burden of comorbidities including congestive heart failure, and had prior MI, diabetes, and known PAD, along with a high preprocedural SYNTAX scores (31.0, 26.0, and 34.5 respectively). Although treatments for the majority of patients (10 of 12 [83%]) had preprocedural Impella support planned, treatments for less than one-half (5 of 12 [42%]) had planned use of IVL preprocedurally. **Table 2** lists procedural characteristics of the IVL therapies and Impella insertions used in the study group. The majority of cases used an Impella CP (11 of 12 [92%]) using the longer 25-cm peel-away sheath. All devices were successfully implanted percutaneously after IVL treatment, and the majority (9 of 12 [75%]) were removed using percutaneous closure devices at the end of the case. In one-half of the cases (6 of 12), predilation delivery of the Impella sheath was unsuccessfully attempted before switching to IVL, and in the remaining 50%, IVL was used prior to any balloon angioplasty. Median reported residual stenosis after IVL was 20% (IQR: 10% to 30%), and only 1 patient required post-IVL balloon angioplasty to successfully deliver the Impella sheath, whereas all 12 patients underwent successful delivery of the Impella device after IVL. According to the physician's report, if delivery of an Impella p-MCS

ABBREVIATIONS AND ACRONYMS

- AKI** = acute kidney injury
- IVL** = intravascular lithotripsy
- MACCE** = major cardiac and cerebrovascular events
- MI** = myocardial infarction
- PAD** = peripheral arterial disease
- p-MCS** = percutaneous mechanical circulatory support

TABLE 1 Baseline Characteristics and Comorbidities for the Study Group (N = 12)	
Age, yrs	72 (63.0-78.0)
Males	9 (75.0)
Diabetes	8 (67.0)
Chronic renal insufficiency	8 (67.0)
Prior CABG	1 (8.0)
Prior MI	8 (67.0)
History of CHF	10 (83.0)
Pre-procedural SYNTAX score	31 (26.0-35.0)
Surgical turnaround	6 (50.0)
LVEF	30 (20.0-30.0)
eGFR	39 (13.0-58.0)
Known PAD	10 (83.3)
Prior PAD procedure	5 (41.6)
Primary reason for Impella	
High-risk PCI	9 (75.0)
Cardiogenic shock	3 (25.0)
Planned Impella use	10 (83.0)
Planned IVL use	5 (42.0)

Values are median (25th percentile to 75th percentile) or n (%).

CABG = coronary artery bypass graft; CHF = congestive heart failure; eGFR = estimated glomerular filtration rate; IVL = intravascular lithotripsy; LVEF = left ventricular ejection fraction; MI = myocardial infarction; PAD = peripheral artery disease; SYNTAX = Synergy Between Percutaneous Coronary Intervention with Taxus and Cardiac Surgery.

TABLE 2 Intravascular Lithotripsy-Assisted Impella Insertion Procedural Characteristics (N = 12)	
Pre-dilation attempts prior to lithotripsy	5 (42.0)
IVL catheter size	7 (6.5-7.0)
Total number of pulses	180 (120.0-180.0)
Post-dilation	3 (25.0)
Residual stenosis after IVL (range)	20 (10.0-30.0)
Post-IVL treatment to prepare vessel for Impella	1 (9.0)
Impella insertion procedure	
Sheath size, F	14 (14.0-14.0)
Sheath length, cm	25 (25.0-25.0)
Impella device used	
2.5	1 (8.0)
CP (Abiomed)	11 (92.0)
Successful Impella insertion	12 (100.0)
Total Impella support time, min	135 (83.0-241.0)
Total Impella support time, excluding cardiogenic shock patients, min	90 (70.0-141.0)
Percutaneous access	12 (100.0)
Closure	
Percutaneous	9 (75.0)
Manual	2 (16.7)
Surgical	0 (0.0)
Impella left in place at the end of the procedure	3 (25.0)

Values are n (%) or median (25th percentile to 75th percentile).
Abbreviations as in [Table 1](#).

device had not been successful using the transfemoral approach for the procedure, alternative (transcaval or transaxillary) access would have been used to deliver the Impella in 8 of 12 patients (67%); an intra-aortic balloon pump would have been used in 2 of 12 patients (17%); 1 of 12 patients (8%) would have been placed on venoarterial extracorporeal membrane oxygenation; and in 1 of 12 patients (8%), PCI would have proceeded without circulatory support. [Figure 1](#) and [Videos 1, 2, 3, 4, 5, 6, and 7](#) illustrate an IVL-assisted Impella insertion, showing successful placement of the Impella p-MCS device followed by successful high-risk PCI of the left coronary system.

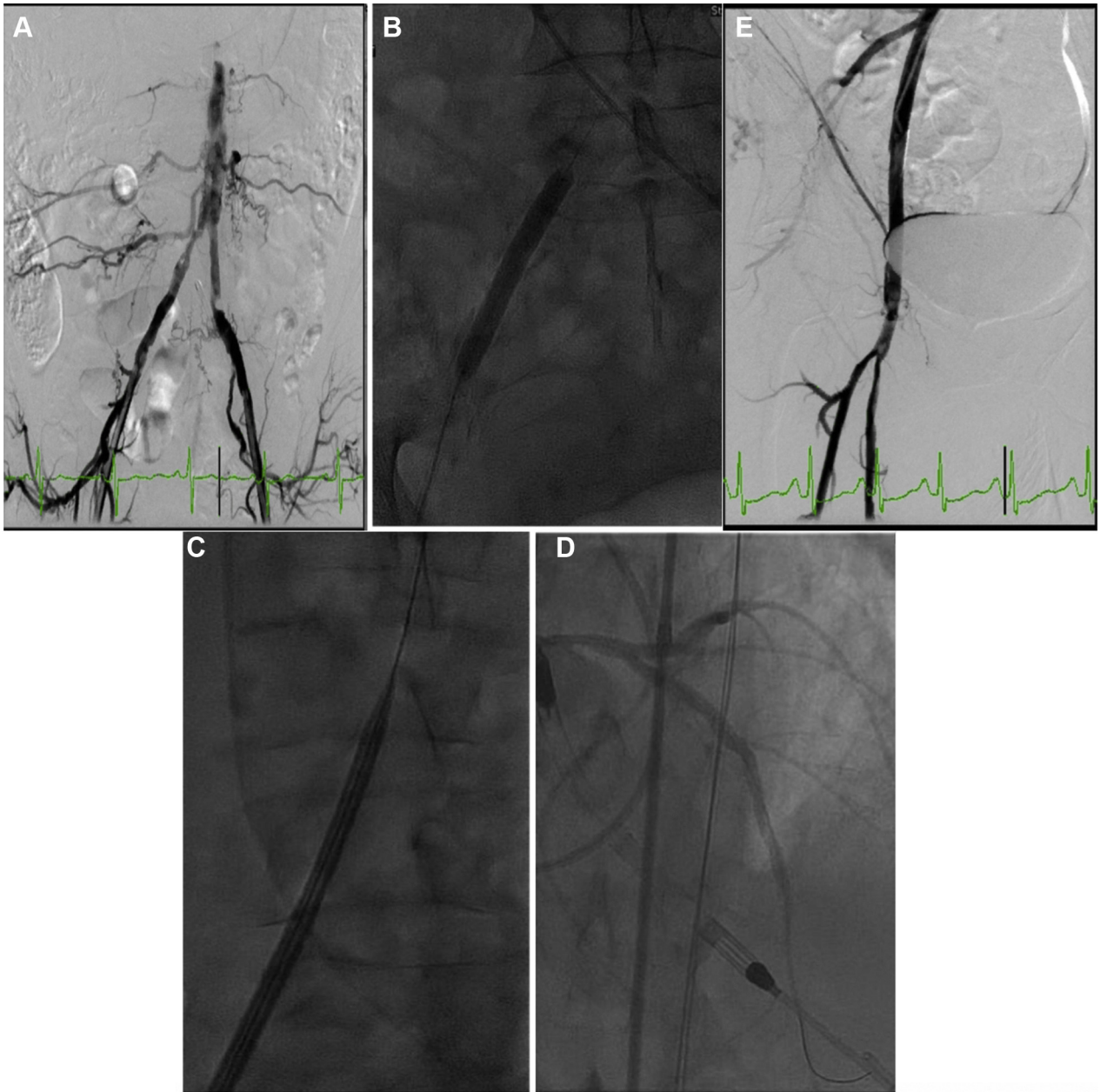
[Table 3](#) lists the procedural characteristics for the PCI procedures performed after the Impella devices were placed. Notably, the majority of patients underwent multivessel PCI requiring atherectomy, with 44% including left main PCI, and 33% including PCI of the last remaining conduit. Of the PCIs attempted, 100% (9 of 9) were successful. [Table 4](#) lists the in-hospital MACCE for the group. No patients had an IVL-related event. Procedural complications included 1 transient ischemic attack, 1 periprocedural MI, 1 instance of AKI, and 1 death, which was due to progressive cardiogenic shock despite prolonged treatment with an Impella CP device and revascularization of the culprit coronary lesion.

DISCUSSION

This paper presents a retrospective multicenter analysis of IVL-assisted transfemoral delivery of Impella p-MCS devices. The data illustrate that IVL resulted in 100% success rates of Impella delivery in the setting of no complications from IVL in patients with significant, calcific PAD. This experience suggests that IVL-assisted p-MCS delivery may be a reasonable option in patients being considered for other alternative access strategies for these devices.

Device-assisted PCI is being increasingly used in patients with stable CAD who are at risk for periprocedural hemodynamic instability, patients who present with cardiogenic shock, and patients with decompensated heart failure (8). Similar to large-bore arterial catheter access for structural heart disease, the percutaneous transfemoral approach offers improved survival, lower complication rates, and lower cost than an open surgical approach (9). However, the most common limitation to percutaneous transfemoral access has been iliofemoral calcification, often associated with significant vessel tortuosity and plaque burden. Although alternate transfemoral approaches such as in situ atherectomy or angioplasty with or without stenting may be used to overcome these challenges, they are often impeded by the extent and distribution of

FIGURE 1 Intravascular-Assisted Impella CP Insertion



(A) Significant bilateral iliofemoral disease with significant stenosis in the proximal common iliac artery that would prevent large bore access. **(B)** Treatment of the stenosis using a 7- × 60-mm Shockwave (Shockwave Medical) intravascular lithotripsy balloon over a 0.014-inch Mailman wire (Boston Scientific, Marlborough, Massachusetts). **(C)** Successful insertion of a 14-F sheath. **(D)** Successful Impella-assisted PCI of the left coronary system. **(E)** Final result from the plain old balloon angioplasty using the Shockwave device in the right iliofemoral system. PCI = percutaneous coronary intervention.

arterial calcium. Furthermore, currently available atherectomy technologies (laser, orbital, and rotational) have little or no efficacy for deep or transmural vessel wall calcification. IVL has the unique capacity to modify calcium regardless of transmural depth or extent of calcium arc by fracturing calcium

in situ, enhancing transmural arterial compliance. Equally important is the absence of atheroembolism or perforation following IVL-assisted large-bore sheath placement, as has been illustrated previously in transcatheter aortic valve replacement (10). Finally, altered transmural vessel compliance

TABLE 3 Procedural Details for PCI Procedures Performed Post-IVL-Assisted Impella Insertion (N = 9)

Number of lesions attempted	2 (1.0-3.0)
Number of stents placed	2 (1.0-4.0)
Total contrast volume, ml	130 (90.0-210.0)
Total frontal radiation to patient, Gy	2.6 (1.3-4.0)
PCI required atherectomy	7 (78.0)
Left main PCI	4 (44.0)
Last remaining conduit PCI	3 (33.0)
PCI technically successful	9 (100.0)

Values are median (25th percentile to 75th percentile) or n (%).
PCI = percutaneous coronary intervention; other abbreviations as in Table 1.

obviates the need for high-pressure balloon dilation with the consequent incremental risk of barotrauma and/or arterial dissection, as shown by the lack of complications post-IVL seen in this series.

Although this initial multicenter experience is promising, several caveats and limitations should be acknowledged. First, the number of patients evaluated was small, and the sheath/device size was limited to 14-F. Second, due to a lack of consensus regarding the use of p-MCS devices to support PCI, physician selection bias for using Impella p-MCS cannot be excluded. Third, there are no strict criteria by which transfemoral access could be seen as “technically prohibitive,” thus, it is unclear what criteria would require initial use of IVL versus peripheral plain old balloon angioplasty with or without stenting with bail-out IVL therapy in order to deliver large bore sheaths. Nevertheless, although this series appears representative of the growing complex high-risk and indicated PCI population, larger studies of IVL-assisted p-MCS devices are certainly warranted.

TABLE 4 In-House Outcomes for the Study Population (N = 12)

Flow-limiting dissection at site of IVL	0 (0.0)
Perforation at site of IVL	0 (0.0)
Stent placement at site of IVL	0 (0.0)
Hematoma >10 cm	0 (0.0)
Pseudoaneurysm	0 (0.0)
Vascular/surgical exploration	0 (0.0)
Surgical repair	0 (0.0)
Death	1 (8.3)
Neurological event	2 (17.0)
Stroke	0 (0.0)
TIA	2 (17.0)
Myocardial infarction	1 (8.0)
Acute kidney injury	1 (8.0)

Values are n (%).
TIA = transient ischemic attack; other abbreviations as in Table 1.

CONCLUSIONS

In this multicenter series, IVL successfully facilitated safe and effective transfemoral access for Impella p-MCS procedural support in patients requiring periprocedural hemodynamic support for high-risk PCI and cardiogenic shock. IVL appears to be a valuable adjunct to large-bore transfemoral arterial access in patients with significant calcific PAD and should be considered prior to obtaining alternative vascular access.

ADDRESS FOR CORRESPONDENCE: Dr. Robert F. Riley, The Christ Hospital and Lindner Center for Education and Research, Heart and Vascular Center, 2123 Auburn Avenue, Suite 136, Cincinnati, Ohio 45219. E-mail: Robert.Riley@thechristhospital.com.

REFERENCES

- Généreux P, Madhavan MV, Mintz GS, et al. Ischemic outcomes after coronary intervention of calcified vessels in acute coronary syndromes. Pooled analysis from the HORIZONS-AMI (Harmonizing Outcomes with Revascularization and Stents in Acute Myocardial Infarction) and ACUITY (Acute Catheterization and Urgent Intervention Triage Strategy) trials. *J Am Coll Cardiol* 2014;63:1845-54.
- Guzman RJ, Brinkley DM, Schumacher PM, Donahue RM, Beavers H, Qin X. Tibial artery calcification as a marker of amputation risk in patients with peripheral arterial disease. *J Am Coll Cardiol* 2008;51:1967-74.
- Huang CL, Wu IH, Wu YW, et al. Association of lower extremity arterial calcification with amputation and mortality in patients with symptomatic peripheral artery disease. *PLoS One* 2014;9:e90201.
- Brodmann M, Werner M, Brinton TJ, et al. Safety and performance of lithoplasty for treatment of calcified peripheral artery lesions. *J Am Coll Cardiol* 2017;70:908-10.
- Zeller T. Impact of lithoplasty: disrupt PAD. Abstract presented at VIVA 2016; September 18-22, 2016; Las Vegas, NV.
- Riley RF, Corl JD, Kereiakes DJ. Intravascular lithotripsy-assisted Impella insertion: a case report. *Catheter Cardiovasc Interv* 2019;93:1317-9.
- Kellum JA, Lameire N, Group KAGW. Diagnosis, evaluation, and management of acute kidney injury: a KDIGO summary (Part 1). *Crit Care* 2013;17:204.
- O'Neill WW, Kleiman NS, Moses J, et al. A prospective, randomized clinical trial of hemodynamic support with Impella 2.5 versus intra-aortic balloon pump in patients undergoing high-risk percutaneous coronary intervention: the PROTECT II study. *Circulation* 2012;126:1717-27.
- Vora AN, Rao SV. Percutaneous or surgical access for transfemoral transcatheter aortic valve implantation. *J Thorac Dis* 2018;10 Suppl 30:S3595-8.
- Di Mario C, Goodwin M, Ristalli F, et al. A prospective registry of intravascular lithotripsy-enabled vascular access for transfemoral transcatheter aortic valve replacement. *J Am Coll Cardiol Intv* 2019;12:502-4.

KEY WORDS cardiac assist devices, percutaneous coronary intervention, peripheral vascular disease

APPENDIX For supplemental videos, please see the online version of this paper.