



ORIGINAL ARTICLE

A prospective cohort study on cam morphology and its role in progression of osteoarthritis

Harbeer Ahedi^{1,2} | Tania Winzenberg^{1,3} | Sita Bierma-Zeinstra^{4,5} | Leigh Blizzard¹ |
Marienke van Middelkoop⁴ | Rintje Agricola⁴ | Jan H. Waarsing⁴ | Flavia Cicuttini⁶ |
Graeme Jones¹

¹Menzies Institute for Medical Research, University of Tasmania, Hobart, Tas, Australia

²Faculty of Medicine and Health, Institute for Musculoskeletal Health, University of Sydney, Camperdown, NSW, Australia

³Faculty of Health, University of Tasmania, Hobart, Tas, Australia

⁴Erasmus MC University Medical Centre, Rotterdam, The Netherlands

⁵Department of Orthopaedics, Rotterdam, The Netherlands

⁶DEPM, Monash University, Melbourne, Vic., Australia

Correspondence

Harbeer Ahedi, Menzies Institute for Medical Research, University of Tasmania, Private Bag 23, Hobart, Tasmania 7001, Australia.

Email: Harbeer.Ahedi@utas.edu.au

Funding information

HA was funded by an Australian Government Postgraduate Award, and this study was supported by Arthritis Australia. The TASOAC study was supported by the National Health and Medical Research Council of Australia, Tasmanian Community Fund, Masonic Centenary Medical Research Foundation, Royal Hobart Hospital Research Foundation and Arthritis Foundation of Australia.

[Correction added on 10 May 2022, after first online publication: CAUL funding statement has been added.]

Abstract

Background: Cam morphology contributes to the development of hip osteoarthritis (OA) but is less studied in the general population. This study describes its associations with clinical and imaging features of hip OA.

Methods: Anteroposterior hip radiographs of 1019 participants from the Tasmanian Older Adult Cohort (TASOAC) were scored at baseline for α angle (cam morphology) in both hips. Using the Altman's atlas, radiographic hip OA (ROA) was assessed at baseline. Hip pain and right hip structural changes were assessed on a subset of 245 magnetic resonance images (MRI) at 5 years. Joint registry data for total hip replacement (THR) was acquired 14 years from baseline.

Results: Of 1906 images, cam morphology was assessed in 1016 right and 890 left hips. Cross-sectionally, cam morphology modestly associated with age (prevalence ratio [PR]: 1.02 $P = .03$) and body mass index (BMI) (PR: 1.03-1.07, $P = .03$) and strongly related to male gender (PR: 2.96, $P < .001$). Radiographically, cam morphology was prevalent in those with decreased joint space (PR: 1.30 $P = .03$) and osteophytes (PR: 1.47, $P = .03$). Longitudinally, participants with right cam and high BMI had more hip pain (PR: 17.9, $P = .02$). At the end of 5 years of follow-up these participants were also more likely to have structural changes such as bone marrow lesions (BMLs) (PR: 1.90 $P = .04$), cartilage defects (PR: 1.26, $P = .04$) and effusion-synovitis at multiple sites (PR: 1.25 $P = .02$). Cam morphology at baseline in either hip predicted up to threefold risk of THR (PR: 3.19, $P = .003$) at the end of 14 years.

Conclusion: At baseline, cam morphology was linked with age, higher weight, male gender, early signs of radiographic OA such as joint space narrowing (JSN) and osteophytes (OST). At follow-up, cam predicted development of hip BMLs, hip effusion-synovitis, cartilage damage and THR. These findings suggest that cam morphology plays a significant role in early OA and can be a precursor or contribute to hip OA in later life.

This is an open access article under the terms of the [Creative Commons Attribution-NonCommercial-NoDerivs](https://creativecommons.org/licenses/by-nc-nd/4.0/) License, which permits use and distribution in any medium, provided the original work is properly cited, the use is non-commercial and no modifications or adaptations are made.

© 2022 The Authors. *International Journal of Rheumatic Diseases* published by Asia Pacific League of Associations for Rheumatology and John Wiley & Sons Australia, Ltd.



KEYWORDS

bone marrow lesions, cam morphology, cartilage defects, hip osteoarthritis, hip pain, total hip replacement

1 | BACKGROUND

Cam morphology assessed by α angle, is a shape variation that might influence the development and progression of hip osteoarthritis (OA).¹ It is common in active young adults and middle-aged populations.²⁻⁴ Nevertheless, recently, a few prospective studies have reported that cam morphology could be one of the causes of idiopathic hip OA in older adults.⁵ For instance, in a longitudinal study of women who were followed for 20 years, each degree increase in α angle was associated with 5% greater risk of radiographic hip OA and total hip replacement (THR).⁶ Similarly, in another longitudinal cohort study, presence of cam morphology predicted hip OA over 9 years.⁷ In the Cohort Hip and Cohort Knee (CHECK) study participants with moderate and severe cam morphology were 3 to 10 times more likely to develop hip OA.⁵ Recently, the Musculoskeletal Pain in Ullensaker (MUST) study reported that participants with cam morphology were more likely to have Kellgren-Lawrence score >2 and reduced joint space narrowing (JSN) (<2 mm).⁸

These studies show that cam morphology is prevalent in the general population and is a major cause of hip OA.^{5,8} Early detection and correction of cam morphology could reduce the prevalence of OA or improve patient-reported outcomes.⁹ However, most of the literature on cam morphology is focused on its associations with radiological findings. Moreover, cam morphology in the left and/or right hip (side-specific) has not been reported elsewhere. Over the last decade imaging biomarkers such as bone marrow lesions (BMLs),¹⁰ cartilage defects,¹¹ high cartilage signal¹⁰ and effusion-synovitis¹² have emerged as strong predictors of early OA. But their association with cam morphology remains undetermined. A community-based study which examines the links between side-specific cam morphology and several risk factors of OA could clarify its natural history. Thus, the goal of this study is to examine the cross-sectional and longitudinal associations of right-left cam morphology with clinical, magnetic resonance imaging (MRI) measures of hip structural change and radiological features of OA.

2 | METHODS

2.1 | Participants

This study was conducted as part of the Tasmanian Older Adult Cohort (TASOAC) study, a prospective, population-based study that was initiated in 2002 aiming to identify the environmental, genetic, and biochemical factors associated with the development and progression of OA at multiple sites (hand, knee, hip, and spine). Subjects between the ages of 50 and 80 years were randomly selected from the electoral roll in southern Tasmania (population

229 000), with an equal number of men and women. The overall response rate was 57%.¹³ As TASOAC was designed to examine community-dwelling older adults; institutionalized older adults were excluded. Participants also were excluded if they reported contraindications for MRI. Of all initially eligible participants a total of 1100 participants were enrolled between March 2002 and September 2004. Follow-up data from 3 clinic visits were collected for 875, 769 and 568 participants respectively. These visits were conducted approximately 3 years, 5 years and 14 years from baseline (Figure 1).¹³

Of 1100, 1099 participants attended a clinic at baseline. Of these participants' 2198 hips, 288 were excluded due to prior hip replacement, or corrupted images. Thus, 1906 radiographs were included in this study and right and left cam morphology was assessed in 1016 and 890 hips respectively. Written informed consent was obtained from all participants, and the Southern Tasmanian Health and Medical Human Research Ethics Committee approved this study.¹⁴

2.2 | Demographics

Self-administered questionnaires were used to assess demographic characteristics, medical history, and lifestyle factors. Age was recorded at baseline and at every follow-up. In this study, we stratified age into 3 groups: category 0 included participants who were 50-59 years old; category 1 included participants who were 60-69 years old and category 2 included those who were 70 years or older. Height and weight were measured by stadiometer using standard protocols, and body mass index (BMI) calculated. The data for BMI were further stratified into 3 categories: normal (BMI: 18-25 kg/m²), overweight (BMI: 25-30 kg/m²) and obese (BMI: 30+ kg/m²).

2.3 | Hip pain

At baseline hip pain was self-reported using a standardized questionnaire. The presence and severity of hip pain for all the participants at 3 and 5 years from baseline were determined using a Western Ontario and McMaster Universities Osteoarthritis (WOMAC) index pain score.¹⁵

2.4 | THR

Data for the incidence of primary (first-time) hip replacement between 1 March 2002 and 21 September 2016 were determined by data linkage to the Australian Orthopaedic Association National Joint Replacement Registry (AOANJRR).¹⁶

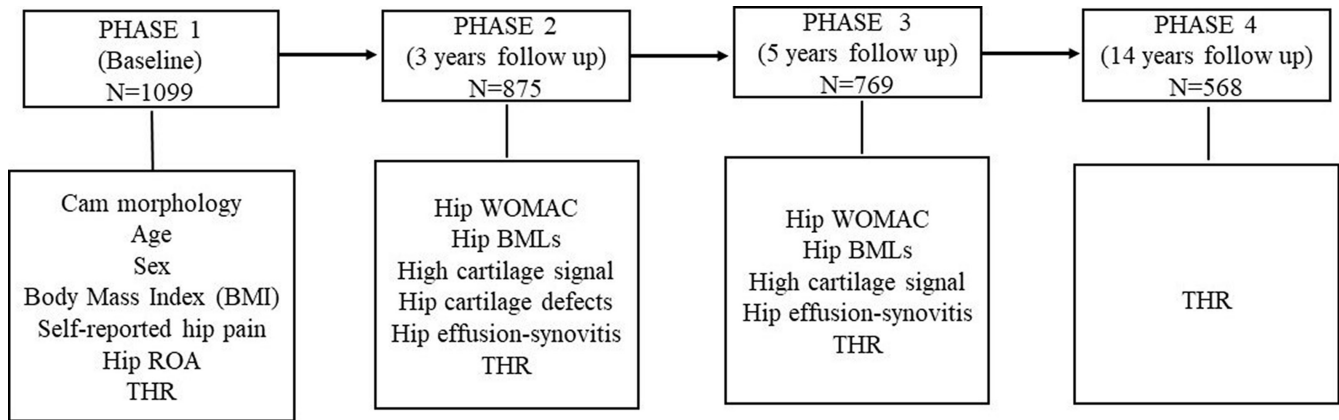


FIGURE 1 Flow chart showing the measures used in the current study at each time point BMLs, bone marrow lesions; ROA, radiographic osteoarthritis; THR, total hip replacement

2.5 | Hip MRI protocol

A hip protocol was added in the later stages of the study and MRI of the right hip was acquired at approximately 3 and 5 years after baseline. Of 245 consecutive randomly chosen participants, Short tau inversion recovery (STIR) MRIs for 228 and 215 participants were available at 3 and 5 years from baseline.¹⁷ Thus, in total 443 MRIs from both time points were used to assess imaging biomarkers.

2.6 | MRI

The right hip was imaged using a 1.5 Tesla GE Signal whole-body magnetic resonance scanner. A set of sagittal images was obtained with a slice thickness of 3.5 mm and an inter-slice gap of 1.5 mm using a STIR-weighted, fat saturation, 2-dimensional fast spin-echo sequence was obtained.¹⁴ Using Osiris X software (University of Geneva) imaging markers such as bone marrow lesions (BMLs),¹⁷ high cartilage signal,¹⁷ hip cartilage defects¹⁸ and hip effusion-synovitis¹⁹ were assessed.

2.6.1 | BMLs

Quantitative assessment of subchondral hip BMLs in STIR MRI were identified as areas of increased signal intensity adjacent to the subchondral bone on the femoral head and/or the acetabulum. The intra-class correlation coefficient (ICC) of the hip BMLs was 0.99.¹⁷

2.6.2 | High cartilage signal

High cartilage signal was identified as an increase in the signal intensity of the articular cartilage due to increased water content that appears as a bright band in the cartilage, either adjacent to a hip BML or at any location on the STIR MRI slice if no BML was present. High

cartilage signal was graded as 0 for absent and 1 for present. The intra-rater agreement high cartilage signal was 0.88.¹⁷

2.6.3 | Hip cartilage defect

Hip defects on either femoral head or acetabulum were identified as any change in the hip cartilage and were categorized as: grade 0 = normal cartilage, grade 1 = focal blistering or irregularities on the cartilage surface or a partial thickness defect and grade 2 = full-thickness defect with bone ulceration and/or exposure of bone. For this study, cartilage defects were coded as 0 for absent and 1 for present regardless of the extent of cartilage damage. The intra-rater agreement (kappa) for cartilage defects was 0.89 and the ICC was 0.84.¹⁸

2.6.4 | Hip effusion-synovitis

Hip effusion-synovitis was identified and assessed in STIR images. The observer (HGA) manually selected the magnetic resonance slice with the largest effusion-synovitis and determined the maximum cross-sectional area of the bright region by manually drawing contours around the outer edges. In a reliability study of 40 subjects with repeated measurements after 4 weeks, the intra-rater agreement (kappa) for the presence of hip effusion-synovitis was 0.84.¹⁹

2.7 | Hip radiographs and assessment of hip radiological OA (ROA)

Anteroposterior radiographs of the pelvis were obtained at the first visit with the individual weight-bearing and with both feet internally rotated by 10°. The Altman atlas was used by 2 trained readers (Prof. Graeme Jones and Dr Helen Cooley) who followed the Osteoarthritis Research Society International grading system (OARS) and assessed the radiographs. Radiographic features of JSN (axial and superior)



and osteophytes (superior acetabular and femoral) of both hips were graded separately on a 4-point scale (range 0-3, where 0 = no disease and 3 = most severe disease). After combining the JSN and osteophytes scores, the presence of radiographic hip OA was defined as a total score of 1 or greater.²⁰

2.8 | Assessment of cam morphology

At baseline the shape of the proximal femur and acetabulum on the anteroposterior radiographs was outlined by HA using statistical shape modeling (SSM) software (ASM toolkit, University of Manchester, Manchester, UK).²¹ HA was trained by JW to use the SSM model developed for the CHECK study.⁵ In this SSM, the shape of the anteroposterior radiograph in either 1 or both hips was assessed by a set of landmark points that are positioned along the surface of the bone in the image. Each point is placed on the same landmark of the outline, to allow comparison between the shapes. The α angle was automatically calculated from this point set (Figure 2) using MATLAB (V 9.0).⁵ The ICC scores for inter-rater reliability between 2 readers (HA and RA) was 0.96-0.98.

We defined cam morphology and severity of cam in the right and left hip by using previous published standardized cut off points established in the CHECK study.⁵ Furthermore, we also assessed the associations of moderate and severe cam morphology in each hip. Severity of cam morphology was categorized as follows. No

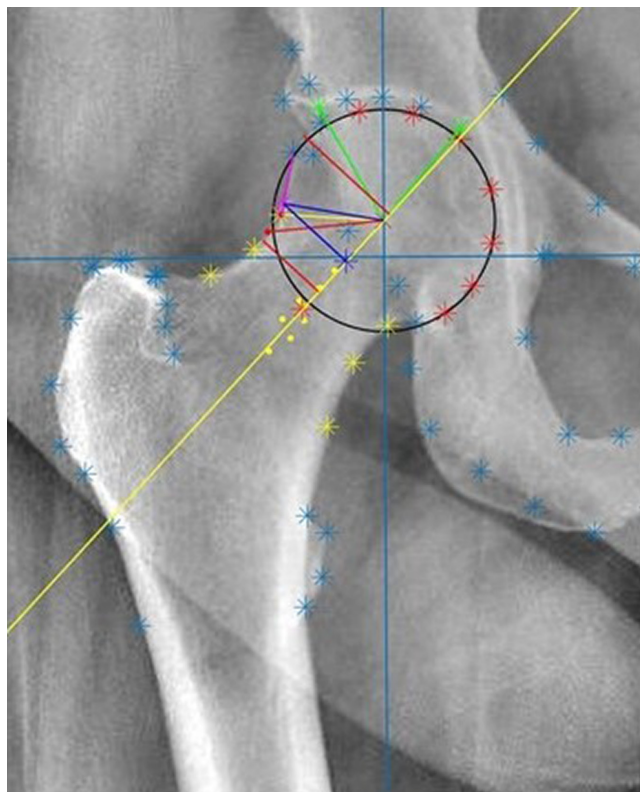

FIGURE 2 Measuring cam morphology using statistical shape modeling

cam morphology, α angle less than 60° ; moderate cam morphology, α angle more than 60° and less than equal to 83° ; and severe cam morphology, α angle more than 83° .^{5,22}

2.9 | Statistical analyses

Characteristics of the population are presented as means and SDs. All analyses were stratified and presented separately for right and left hip. Overall, cam morphology was absent in 617 participants and present in 381 participants. In non-cam hips the proportion of THR was 5%, and in cam hips it was 40%.

In cross-sectional analyses, linear and log binomial regression was used to test the associations between age, gender, and BMI and cam morphology. Furthermore, modified Poisson regression was used to test the association of ROA with cam morphology.

In the longitudinal analyses, modified Poisson regression was employed to investigate the associations of presence of hip pain (hip pain = 0 and hip pain >0) and THR with cam morphology. To estimate the longitudinal association of hip pain severity and cam morphology, linear regression was applied. Analyses for all statistical models (Poisson regression) estimating associations between MRI findings and cam morphology were restricted to the right hip.

All analyses were adjusted for covariates such as age, gender, BMI, presence of ROA, osteophytes, cartilage defects, and BMLs accordingly. Data on participants from both follow-ups were combined in the analyses, and correlations between repeated measurements on individuals were taken into account by adjusting standard errors using the sandwich (robust) estimator of variance.^{23,24} All statistical analyses were performed using Intercooled STATA 12 (Stata Corp.).

3 | RESULTS

Table 1 summarizes characteristics of hips with right and left cam morphology. Proportions of cam morphology in left or right hip in males was similar and no differences in BMI were noted. Radiological changes in right and left hip were more or less similar. At follow-up, presence of hip pain was lower in the left hip in comparison to the right, while there was no difference in hip pain score. Up to 20% of the right hip with cam morphology had structural changes such as cartilage defects, high cartilage signal, effusion-synovitis and BMLs. At the end of 14 years of follow-up, about 38% of hips with cam morphology underwent joint replacement.

Table 2 outlines the cross-sectional associations of cam morphology with age, male gender and BMI. Presence of cam morphology in the right hip was modestly associated with age and BMI. Nevertheless, its prevalence was higher in people over the age of 70 years. Obese individuals were more prone to severe cam of the right hip. In the left hip, only moderate cam morphology was associated with age and BMI. Male gender was strongly associated with presence and severity of cam in both hips.



TABLE 1 Characteristics of hips with right and left cam morphology

	Right hip cam morphology (203/1016)	Left hip cam morphology (181/890)
	Means (SD) or %	Means (SD) or %
Baseline ^a		
Age, y	64.2 (7.57)	63.7 (7.55)
Male gender	150/496 (30.2%)	132/436 (30.2%)
Body mass index, kg/m ²	28.4 (4.50)	28.1 (4.80)
Self-reported presence of hip pain, Y/N	65/345 (18.8%)	60/345 (17.4%)
Hip radiological osteoarthritis, Y/N	85/380 (22.4%)	83/368 (22.5%)
Hip joint space narrowing, Y/N	72/300 (24.0%)	69/300 (23.0%)
Hip osteophytes, Y/N	40/157 (25.5%)	36/142 (25.3%)
Follow-up ^a		
Presence of hip pain, Y/N ^b	59/282 (20.0%)	52/282 (18.4%)
Hip pain score ^b	2.70 (6.16)	2.62 (5.96)
Hip bone marrow lesions, Y/N	11/55 (20.3%)	-
Hip cartilage defects, Y/N	36/188 (19.1%)	-
Hip high cartilage signal, Y/N	30/184 (16.3%)	-
Hip effusion-synovitis, Y/N	41/227 (18.0%)	-
Total hip replacement	12/32 (37.5%)	14/42 (33.3%)

Note: Wherever possible data is matched for each hip side.

^aNumber of participants might vary due to missing data at baseline and follow-up.

^bPresence of hip pain at follow-up and hip pain score were calculated using Western Ontario and McMaster Universities Osteoarthritis Index.

The cross-sectional associations of cam morphology and severity with hip radiological findings are presented in Table 3. In comparison to those without right cam, the prevalence of JSN and osteophytes was 40% and 75% greater in those with right cam morphology. Those with left hip cam were 30%-40% more likely to have radiological changes and moderate left cam showed similar associations.

Table 4 demonstrates the cross-sectional and longitudinal associations of cam morphology with hip pain and THR. Presence of hip pain at baseline or at the end of 5 years follow-up showed no association with cam morphology. However, participants with severe right cam morphology and higher BMI were likely to have greater pain (prevalence ratio [PR]: 17.9, $P < .02$) than those without cam and normal weight. At the end of 14 years of follow-up, cam morphology on either side predicted an almost threefold risk of joint replacement.

Table 5 outlines the longitudinal associations of cam morphology with structural changes in the right hip. Over 5 years of follow-up, presence and categories of cam morphology were associated with higher prevalence of effusion-synovitis (up to 25%) and hip cartilage defects (up to 26%). Only moderate cam morphology estimated 2-fold higher prevalence of BMLs.

4 | DISCUSSION

This longitudinal study shows that cam morphology is associated with several factors that represent progression of hip OA. These relationships were somewhat different for right and left hips and have

been discussed in detail below. In general, cross-sectionally, cam morphology was modestly associated with older age, and BMI. Men and those with hip radiological changes such as reduced JSN and increased number of osteophytes were more vulnerable toward developing cam morphology. Over 5 years of follow-up, cam morphology predicted more hip pain, hip effusion-synovitis, and hip cartilage defects. BMLs were more likely to develop in participants with moderate cam. Lastly, at the end of 14 years, cam morphology predicted end stage hip OA. Overall, cam morphology associates with several important risk factors of OA and might play an important role in its progression.

We found asymmetry in the associations of right and left cam morphology and OA facets which could be due to biomechanical factors, physiological, pathological changes to one joint in comparison to the other, lifestyle, injury or genetics.^{25,26}

4.1 | Baseline

4.1.1 | Cam morphology and demographics

Male gender, higher BMI, and increased age are risk factors for hip OA.²⁷ In the current study, in comparison to women, men had a 2- to 6-fold greater risk of having cam morphology in either hip. These findings are consistent with previous studies.^{28,29}

There is limited data on the relationship between cam morphology, age and BMI. Here, cam morphology was associated with age and was



TABLE 2 The cross-sectional associations of cam morphology with age, male gender, BMI

	All age groups	Age category 1	Age category 2	Male gender	Overall BMI	Overweight	Obese
	PR (95% CI) ^a	PR (95% CI) ^a	PR (95% CI) ^a	PR (95% CI) ^a	PR (95% CI) ^a	PR (95% CI) ^a	PR (95% CI) ^a
Right cam morphology							
Absent							
Present	1.02 (1.00-1.04) P = .03	1.16 (0.82-1.64) P = .36	1.45 (1.00-2.11) P < .05	2.96 (2.15-4.07) P < .001	1.03 (1.00-1.07) P = .03	1.08 (0.74-1.57) P = .69	1.47 (0.99-2.18) P = .05
Categories							
Moderate	1.02 (1.00-1.05) P < .05	1.36 (0.90-2.13) P = .17	1.63 (0.99-2.66) P = .05	6.60 (3.87-11.1) P < .001	1.01 (0.97-1.07) P = .50	1.00 (0.62-1.63) P = .97	1.28 (0.76-2.16) P = .34
Severe	1.01 (0.98-1.04) P = .38	0.93 (0.53-1.63) P = .80	1.41 (0.79-2.51) P = .25	1.66 (1.06-2.58) P < .001	1.06 (1.02-1.10) P < .001	1.18 (0.64-2.16) P = .59	1.95 (1.06-3.56) P = .03
Left cam morphology							
Absent							
Present	1.01 (0.99-1.03) P = .14	1.15 (0.80-1.64) P = .44	1.28 (0.86-1.93) P = .22	2.75 (1.97-3.84) P < .001	1.03 (0.99-1.06) P = .09	1.04 (0.72-1.52) P = .81	1.28 (0.85-1.92) P = .22
Categories							
Moderate	1.02 (1.00-1.04) P = .01	1.21 (0.86-1.71) P = .21	1.48 (1.01-2.20) P < .04	2.17 (1.61-2.93) P < .001	1.03 (1.00-1.07) P = .02	1.11 (0.77-1.60) P = .56	1.40 (0.93-2.03) P = .10
Severe	1.01 (0.98-1.04) P = .35	1.18 (0.71-1.97) P = .18	1.33 (0.74-2.40) P = .34	2.04 (1.33-3.14) P < .001	1.03 (0.98-1.08) P = .58	1.16 (0.70-1.97) P = .35	1.32 (0.73-2.36) P = .14

Note: Dependent variable: age, male gender and BMI. Independent variables: cam morphology in right and left hip. Bold text represents statistically significant results.

Age categories: category 0 (ref) included participants who were between 50-60 years; category 1 included participants who were between 60-70 years; category 2 included participants who were 70 years or older. BMI categories: Normal BMI (ref), participants with BMI 18-25; overweight, participants with BMI 25-30; obese, participants with BMI over 30. Cam severity categories: no cam morphology = α angle <60°; moderate cam morphology = α angle >60° and \leq 83°; severe cam morphology = α angle >83°.

Abbreviation: BMI, body mass index.

^aPR (95% CI) = Prevalence ratios with 95% confidence intervals adjusted for age, gender, BMI, and presence of hip osteophytes at baseline.

TABLE 3 The cross-sectional associations of cam morphology and cam severity with hip radiological findings

	Hip ROA			Hip JSN			Hip osteophytes		
	Adjusted			Adjusted			Adjusted		
	n/N	PR (95% CI) ^a	P value	n/N	PR (95% CI) ^a	P value	n/N	PR (95% CI) ^a	P value
Right hip cam morphology									
Absent	287/380	1.00		223/300	1.00		112/157	1.00	
Present	85/380	1.18 (0.98-1.44)	.08	72/300	1.30 (1.03-1.61)	.03	40/157	1.40, (0.99-1.96)	.06
Categories									
Moderate cam	47/380	1.12 (0.87-1.43)	.40	40/300	1.22 (0.92-1.63)	.16	20/157	1.14 (0.73-1.78)	.57
Severe cam	38/380	1.28 (0.99-1.65)	.05	32/300	1.36 (1.01-1.84)	.04	20/157	1.75 (1.15-2.70)	.009
Left hip cam morphology									
Absent	257/368	1.00		209/300	1.00		98/142	1.00	
Present	83/368	1.30 (1.07-1.56)	.008	69/300	1.32 (1.06-1.65)	.01	36/142	1.47 (1.03-2.10)	.03
Categories									
Moderate cam	46/368	1.48 (1.20-1.86)	.001	37/300	1.46 (1.10-1.93)	.008	18/142	1.50 (0.94-2.41)	.09
Severe cam	37/368	1.13 (0.87-1.48)	.35	32/300	1.20 (0.88-1.61)	.23	18/142	1.44 (0.92-2.27)	.11

Note: Dependent variable: radiological findings at baseline. Independent variable: cam morphology and cam severity at both hips.

Bold text represents statistically significant results.

Cam severity categories: no cam morphology = α angle $<60^\circ$; moderate cam morphology = α angle $>60^\circ$ and $\leq 83^\circ$; severe cam morphology = α angle $>83^\circ$.

Abbreviations: JSN, joint space narrowing; ROA, radiographical osteoarthritis.

^aPR (95% CI) = prevalence ratios with 95% confidence intervals adjusted for age, gender, body mass index at baseline.

more prevalent in older participants (45%), and these associations were independent from the presence of osteophytes. Although right-left cam showed slight differences in their associations with age, the magnitude of the results was similar. Cam morphology or defects can be congenital in nature and prevalent in younger populations. However, our results show that it could be a part of OA pathogenesis and develop later in life. Our analyses are cross-sectional, but it is likely that age influences α angle, leading to higher prevalence of cam. It should be noted that this study did not consider aspects such as history of physical activity, occupation, or genetics.^{30,31}

Cam morphology showed an association with BMI, and the risk of severe cam in the right hip was 2-fold higher in obese participants. It is believed that BMI might influence cam morphology and higher BMI may increase joint loading in hips with cam morphology and intensify the disease process, perhaps more on one side than other.^{32,33} On the other hand, people with hip pain or other issues may become less active and on average more obese. Injury or pain may also alter gait, leading to progress of cam in one hip. Our results support this theory. However, our analyses are cross-sectional and further longitudinal studies could help determine these mechanisms.^{32,33}

4.1.2 | Cam morphology and radiological findings

Left cam morphology was associated with radiological hip OA at baseline. Conversely, JSN was common in both hips with prevalence of cam morphology ranging from 30% to 40%. Hip osteophytes were associated severe cam in the right hip (PR: 1.75, CI: 1.15-2.70) and presence of cam in the left hip (PR: 1.47, CI: 1.03, 2.10). Our results are similar to previous studies. For instance, cam morphology at baseline was associated with a 2-fold higher risk of hip OA over 5 years.⁵ Higher α angle increased the risk of radiographic hip OA in woman over 20 years.⁶ A systematic review established that several radiographic features detected by SSM were associated with incidence or progression of OA.³⁴ However, these studies do not describe associations of cam morphology in the left and/or right hip. Unlike previous studies, we used the OARSI grading system and JSN and osteophytes both associated with cam morphology. It is speculated that presence of osteophytes might influence or drive this shape variation. Perhaps osteophytes alter the joint dynamics, leading to reduction in joint space that is an indicator of cartilage loss. However, our examination is limited by cross-sectional analyses and further studies are required.



TABLE 4 The cross-section and longitudinal associations of cam morphology with hip pain and total hip replacement

	Baseline		Follow-up		Hip pain score		Total hip replacement	
	Presence of hip pain		Presence of hip pain		Mean (SD)	Mean difference (95% CI) ^b	n/N	PR (95% CI) ^a
	n/N	PR (95% CI) ^a	n/N	PR (95% CI) ^a				
Right hip cam morphology								
Absent	282/345	1.00	282/282	1.00	2.54 (5.61)	1.00	18/32	1.00
Present	38/345	1.17 (0.92-1.48) P = .19	59/282	1.09 (0.78-1.52) P = .60	2.70 (6.16)	0.18 (-0.71-1.08) P = .66	12/32	3.19 (1.47-6.94) P = .003
Categories								
Moderate cam	31/345	0.85 (0.61-1.15) P = .27	30/282	0.92 (0.58-1.44) P = .71	2.10 (4.84)	0.26 (-0.66-1.18) P = .54	-	-
Severe cam	34/345	1.20 (0.94-1.53) P = .14	29/282	1.34 (0.87-2.04) P = .18	3.67 (7.78)	0.52 (-0.83-1.88) P = .42	-	-
Interaction*BMI P value				17.9 (1.93-1.66.3) .02				
Left hip cam morphology								
Absent	236/345	1.00	172/282	1.00	2.46 (5.50)	1.00	22/42	1.00
Present	33/345	1.12 (0.87-1.46) P = .30	52/282	1.05 (0.73-1.50) P = .80	2.63 (5.96)	0.04 (-0.92-1.00) P = .93	14/42	2.63 (1.30-5.30) P = .007
Categories								
Moderate cam	30/345	1.17 (0.86-1.58) P = .30	24/282	0.95 (0.58-1.54) P = .83	2.36 (5.42)	-0.32 (-1.23-0.58) P = .48	-	-
Severe cam	30/345	1.15 (0.87-1.51) P = .31	28/282	1.14 (0.71-1.82) P = .57	2.93 (6.54)	0.53 (-0.99-2.04) P = .49	-	-

Note: Dependent variable: self-reported presence of hip pain at baseline, presence and pain score at 5 years of follow-up and total hip replacement at 14 years of follow-up. Independent variables: cam morphology and cam severity at both hips. Bold text represents statistically significant results.

Cam severity categories: no cam morphology = α angle $<60^\circ$; moderate cam morphology = α angle $>60^\circ$ and $\leq 83^\circ$; severe cam morphology = α angle $>83^\circ$.

Abbreviation: BMI, body mass index.

^aPR (95% CI) = prevalence ratios with 95% confidence intervals adjusted for age, gender, BMI, and presence of hip osteophytes at baseline.

^bMean difference with 95% confidence intervals adjusted for age, gender, BMI and presence of hip osteophytes with clustering of observations on subjects at phases 2 and 3 taken into account. Data adjusted for age, gender, BMI and presence of osteophytes at baseline.



TABLE 5 Longitudinal associations of cam morphology and severity with structural changes in the right hip

	Hip BMLs		High cartilage signal		Hip effusion at 1 site		Hip effusion at 2 sites		Hip cartilage defects	
	PR (95% CI)	PR (95% CI) ^a	PR (95% CI)	PR (95% CI) ^a	PR (95% CI)	PR (95% CI) ^b	PR (95% CI)	PR (95% CI) ^b	PR (95% CI)	PR (95% CI) ^b
Right hip cam morphology										
Absent	1.00	1.00	1.00	1.00	1.00	1.00	1.00	1.00	1.00	1.00
Present	1.23 (0.71-2.64)	1.14 (0.50-2.64)	1.01 (0.81-1.27)	1.03 (0.77-1.36)	1.10 (1.02-1.20)	1.07 (0.99-1.20)	1.26 (1.08-1.49)	1.25 (1.04-1.50)	1.21 (1.03-1.42)	1.21 (1.03-1.42)
	P = .46	P = .75	P = .83	P = .72	P = .01	P = .08	P = .004	P = .02	P = .002	P = .02
Right hip cam severity										
No cam	1.00	1.00	1.00	1.00	1.00	1.00	1.00	1.00	1.00	1.00
Moderate	2.16 (1.27-3.70)	1.90 (1.01-3.60)	1.25 (0.99-1.50)	1.16 (0.84-1.61)	1.11 (1.02-1.21)	1.07 (0.96-1.21)	1.30 (1.10-1.52)	1.21 (1.04-1.54)	1.25 (1.06-1.50)	1.18 (0.98-1.40)
	P = .004	P = .04	P = .05	P = .17	P = .01	P = .20	P = .002	P = .04	P = .008	P = .07
Severe	1.21 (0.87-1.68)	1.09 (0.74-1.60)	0.93 (0.60-1.45)	0.80 (0.50-1.34)	1.09 (0.97-1.23)	1.06 (0.99-1.14)	1.21 (0.92-1.60)	1.20 (1.90-1.40)	1.26 (1.02-1.60)	1.26 (1.01-1.57)
	P = .25	P = .66	P = .76	P = .61	P = .13	P = .06	P = .16	P = .02	P = .03	P = .04

Note: Dependent variable: presence of bone marrow lesions. hip effusion and high cartilage signal using right hip over 5 years of follow-up. Independent variable: right hip cam morphology.

Cam severity categories: no cam morphology = α angle $<60^\circ$; moderate cam morphology = α angle $>60^\circ$ and $\leq 83^\circ$; severe cam morphology = α angle $>83^\circ$.

Abbreviation: BMLs, bone marrow lesions.

^aPR: prevalence ratio (95% CI) adjusted for age, gender and body mass index with clustering of observation on subjects at phases 2 and 3 was considered.

^bPR: prevalence ratio (95% CI) adjusted for age, gender, body mass index, hip pain, hip radiographic osteoarthritis, presence of hip BMLs, and cartilage defects (as required) with clustering of observation on subjects at phase 2 and phase 3. Bold denotes statistically significant results.



4.2 | Follow-up

4.2.1 | Cam morphology and hip pain

Those with right hip cam and higher BMI were more likely to have hip pain (PR: 17.9, CI: 1.93, 1.66) at the end 5 years of follow-up, and this association remained significant after adjusting for osteophytes. Hip pain has been a subject of controversy in population-based studies in regard to cam morphology. For instance, cam-type deformity did not predict hip pain in the CHECK cohort.⁵ However, in the Osteoporotic Fracture study an α angle less than 70° was associated with lower hip pain.³⁵ We found an interaction between BMI, right cam morphology and hip pain. Moreover, in this study we demonstrated that severe cam morphology was linked with obesity (PR: 1.95, CI: 1.06, 3.56). Perhaps higher BMI might play a role in increasing hip pain in those with cam morphology as it does with increasing the risk of knee pain and knee OA.³⁶

4.2.2 | Cam morphology and hip structural changes assessed by MRI

Our previous studies have shown that hip BMLs are associated with hip pain and changes in bone density.³⁷ Similarly, high cartilage signal assessed by MRI is an indicator of early changes in the cartilage and is associated with BML and cartilage defects.¹⁰ In this study, BMLs were associated with moderate cam morphology (PR: 1.90, CI: 1.01-3.60), but high cartilage signal showed no such associations. BMLs have emerged as an early and significant marker of development of OA and are associated with several structural changes and predict joint replacement.^{13,17} We are the first to report its link with cam morphology, especially in the early stages of hip OA and in a community-based sample.

Over 5 years of follow-up, those with cam morphology had a higher likelihood of developing cartilage defects (25%). These associations have not been reported in older adults. However, in a surgical study of 50 men and women with average age of 28 years, cartilage lesions at the anterosuperior and superior positions were significantly larger in patients with cam morphology.³⁸ It is speculated that during flexion in participants with cam morphology, the transition zone between the labrum and acetabular cartilage are subjected to compressive and shear stresses. This causes the labrum to translate away from the joint while the cartilage is pushed in the opposite direction, preserving the labrum until later in the disease process.^{33,39} Consequently, cam morphology may damage the cartilage, causing its delamination from the labrum. Our data support this theory and show that cam morphology, independent of the presence of BMLs, hip pain, hip ROA and effusion-synovitis, may predict the development of cartilage defects.⁷

Over 5 years, presence of cam morphology predicted effusion-synovitis at multiple sites (PR: 1.25, CI: 1.04, 1.50). The associations of moderate cam morphology with hip effusion-synovitis were consistent in comparison to severe cam morphology. Effusion-synovitis

is common in those with OA and is associated with increase in pain and joint damage.¹² We have previously established a interlink between MRI-based structural hip changes such as hip effusion-synovitis, cartilage defects, BMLs and hip shape.^{14,18} Hypothetically, cam morphology may damage the cartilage and generate intra-articular debris which results in inflammation of the synovium.^{40,41} This could explain the relationship between hip effusion-synovitis and cam morphology. However, in this study, the association between presence of cam morphology and presence of hip effusion-synovitis was independent of the presence of hip pain, hip ROA, hip BMLs and hip cartilage defects. Thus, cam morphology may be one of the causes of hip effusion-synovitis.

Overall, structural changes of the hip, including effusion-synovitis showed modest associations with categories of cam morphology. This could be due to the nature of the sample population (community-based) and due to the limited number of MRIs. These results should be replicated in other studies.

4.2.3 | Cam morphology and THR

At the end of 14 years of follow-up, cam morphology in both hips at baseline predicted a higher risk of THR (for both hips PR ranging 2.60-3.19). Due to limited data we did not conduct analyses for moderate and severe cam morphology.

Previous literature demonstrates that shape variations of the femoral head predict THR,^{1,14,42} and in the last few years this concept has been well established.^{34,42-45} Each study has used different methods to assess cam morphology, but the results are more or less similar. For example, in the CHECK study, the presence of cam-type deformity (α angle >60°) predicted 3 times higher risk of hip OA, while severe cam-type deformity (α angle >83°) predicted 10 times higher risk of hip OA.⁵ In our study, we used the same methods and found that right-left cam morphology predicted THR. The magnitude of the associations of right-left hip with THR was similar, although right hip predicted a 3-fold risk. This favorability toward the right hip could be due to the involvement of other factors related to joint replacement and cam such as higher BMI, more osteophytes and hip pain.^{46,47}

5 | LIMITATIONS

5.1 | There are certain limitations to this study

For assessment of cam morphology, only anterior-posterior radiographs were used, and thus cam morphology located in the anterolateral head neck junction may be missed. However, obtaining radiographs in all the planes (coronal, axial and lateral) on a large scale can be economically challenging. On the other hand, the anterior-posterior view is inexpensive and easily available. In addition, the Warwick's agreement on femoro-acetabular impingement (FAI) which includes cam morphology states that anterior-posterior

radiograph of the pelvis can be used to identify cam or pincer morphologies.⁴⁸

Osteophytes and cam are both features of OA and although we measured these using different techniques and the shape model was designed to exclude osteophytes, it is possible that an osteophyte might be interpreted as cam. Nevertheless, adjusting for presence of ROA or osteophytes had little effect on the analyses. MRIs were available for only one hip and for a small number of participants. Thus, analyses for MRI structural changes were restricted to the right hip.

6 | CONCLUSIONS

This study examined the cross-sectional and longitudinal link between cam morphology and features of OA. Cross-sectionally, this shape variation was strongly associated with male gender and there was a minor but statistically significant association with age and BMI. Smaller JSN was consistently associated with cam morphology, while osteophytes were more common in those with severe cam. At the end of 5 years, cam morphology predicted hip BMLs, hip effusion-synovitis, cartilage damage, more hip pain in obese participants. Cam morphology at baseline estimated higher risk of THR at the end of 14 years. In summary, these findings suggest that cam morphology plays a significant role in early OA and can be a precursor or contribute to hip OA in later life.

ACKNOWLEDGEMENTS

A special thanks goes to the participants of the TASOAC study. We thank Catrina Boon and Pip Boon for their contribution in collecting the data for this study. Open access publishing facilitated by The University of Sydney, as part of the Wiley - The University of Sydney agreement via the Council of Australian University Librarians.

CONFLICT OF INTEREST

The authors have no conflicts of interest.

AUTHOR CONTRIBUTIONS

HA, TW, RA, JW, SZ, MM, FC and GJ contributed to the conception and design of the study. HA, LB, RA and GJ contributed to analyses of the data. JW trained HA to use the ASM tool kit. HA extracted data and prepared the first draft of the manuscript. All authors contributed to data interpretation, critical revision and final approval of the manuscript. HA assumes responsibility for the integrity and accuracy of the data.

ORCID

Harbeer Ahedi  <https://orcid.org/0000-0001-5901-4720>

Graeme Jones  <https://orcid.org/0000-0002-9814-0006>

REFERENCES

- Doherty M, Courtney P, Doherty S, et al. Nonspherical femoral head shape (Pistol grip deformity), neck shaft angle, and risk of hip osteoarthritis. *Arthritis Rheum*. 2008;58(10):3172-3182.
- Agricola R, Bessems JH, Ginai AZ, et al. The development of Cam-type deformity in adolescent and young male soccer players. *Am J Sports Med*. 2012;40(5):1099-1106.
- Harris JD, Gerrie BJ, Varner KE, Lintner DM, McCulloch PC. Radiographic prevalence of dysplasia, cam, and pincer deformities in elite ballet. *Am J Sports Med*. 2016;44(1):20-27.
- Laborie LB, Lehmann TG, Engesaeter IO, Eastwood DM, Engesaeter LB, Rosendahl K. Prevalence of radiographic findings thought to be associated with femoroacetabular impingement in a population-based cohort of 2081 healthy young adults. *Radiology*. 2011;260(2):494-502.
- Agricola R, Heijboer MP, Bierma-Zeinstra SM, Verhaar JA, Weinans H, Waarsing JH. Cam impingement causes osteoarthritis of the hip: a nationwide prospective cohort study (CHECK). *Ann Rheum Dis*. 2013;72(6):918-923.
- Thomas GE, Palmer AJ, Batra RN, et al. Subclinical deformities of the hip are significant predictors of radiographic osteoarthritis and joint replacement in women. A 20 year longitudinal cohort study. *Osteoarthr Cartil*. 2014;22(10):1504-1510.
- Saberi Hosnijeh F, Zuiderwijk ME, Versteeg M, et al. Cam deformity and acetabular dysplasia as risk factors for hip osteoarthritis. *Arthritis Rheumatol*. 2017;69(1):86-93.
- Kemp JL, Østerås N, Mathiessen A, et al. Relationship between cam morphology, hip symptoms, and hip osteoarthritis: the musculoskeletal pain in Ullersaker Study (MUST) cohort. *Hip Int*. 2020;31(6):1120700020943853.
- Domb BG, Annin S, Chen JW, et al. Optimal treatment of cam morphology may change the natural history of femoroacetabular impingement. *Am J Sports Med*. 2020;48(12):2887-2896.
- Ahedi H, Aitken D, Blizzard L, Cicuttini F, Jones G. A population-based study of the association between hip bone marrow lesions, high cartilage signal, and hip and knee pain. *Clin Rheumatol*. 2014;33(3):369-376.
- Ahedi HG, Aitken DA, Blizzard LC, Ding CH, Cicuttini FM, Jones G. Correlates of hip cartilage defects: a cross-sectional study in older adults. *J Rheumatol*. 2016;43(7):1406-1412.
- Wang X, Jin X, Blizzard L, et al. Associations between knee effusion-synovitis and joint structural changes in patients with knee osteoarthritis. *J Rheumatol*. 2017;44:1644-1651.
- Dore D, Quinn S, Ding C, et al. Natural history and clinical significance of MRI detected bone marrow lesions at the knee: a prospective study in community dwelling older adults. *Arthritis Res Ther*. 2010;12(6):R223.
- Ahedi H, Aspden RM, Blizzard LC, et al. Hip shape as a predictor of osteoarthritis progression in a prospective population cohort. *Arthritis Care Res*. 2016;69(10):1566-1573. doi:10.1002/acr.23166
- Bellamy B, Buchanan W, Goldsmith C, Campbell J, Stitt L. Validation study of WOMAC: a health status instrument for measuring clinically important patient relevant outcomes to antirheumatic drug therapy in patients with osteoarthritis of the hip or knee. *J Rheumatol*. 1988;15(12):1833-1840.
- Munugoda IP, Wills K, Cicuttini F, et al. The association between ambulatory activity, body composition and hip or knee joint replacement due to osteoarthritis: a prospective cohort study. *Osteoarthritis Cartilage*. 2018;26(5):671-679.
- Ahedi H, Aitken D, Blizzard L, Cicuttini F, Jones G. A population-based study of the association between hip bone marrow lesions, high cartilage signal, and hip and knee pain. *J Clin Rheumatol*. 2013;33(3):369-376.
- Ahedi H, Aitken DA, Blizzard LC, Ding CH, Cicuttini FM, Jones G. Correlates of hip cartilage defects: a cross-sectional study in older adults. *J Rheumatol*. 2016;43(7):1406-1412.
- Ahedi H, Aitken D, Blizzard L, Cicuttini F, Jones G. Quantification of hip effusion-synovitis and its cross-sectional and longitudinal associations with hip pain, MRI findings and early radiographic hip OA. *BMC Musculoskelet Disord*. 2020;21(1):533-



20. Ding C, Cicuttini F, Boon C, et al. Knee and hip radiographic osteoarthritis predict total hip bone loss in older adults: a prospective study. *J Bone Miner Res*. 2010;25:858-865.
21. Cootes TF, Hill A, Taylor CJ, Haslam J. Use of active shape models for locating structures in medical images. *Image Vis Comput*. 1994;12(6):355-365. <https://citeseerx.ist.psu.edu/viewdoc/download?doi=10.1.1.17.1047&rep=rep1&type=pdf>
22. Waarsing JH, Rozendaal RM, Verhaar JN, Bierma-Zeinstra SA, Weinans H. A statistical model of shape and density of the proximal femur in relation to radiological and clinical OA of the hip. *Osteoarthr Cartil*. 2010;18:787-794.
23. White H. A heteroskedasticity-consistent covariance matrix estimator and a direct test for heteroskedasticity. *Econometrica*. 1980;48(4):817-838. <https://www.jstor.org/stable/1912934>
24. Williams RL. A note on robust variance estimation for cluster-correlated data. *Biometrics*. 2000;56(2):645-646.
25. Neame R, Zhang W, Deighton C, et al. Distribution of radiographic osteoarthritis between the right and left hands, hips, and knees. *Arthritis Rheum*. 2004;50(5):1487-1494.
26. Savage TN, Saxby DJ, Pizzolato C, et al. Trunk, pelvis and lower limb walking biomechanics are similarly altered in those with femoroacetabular impingement syndrome regardless of cam morphology size. *Gait Posture*. 2021;83:26-34.
27. Melugin HP, Hale RF, Zhou J, et al. Risk factors for long-term hip osteoarthritis in patients with femoroacetabular impingement without surgical intervention. *Am J Sports Med*. 2020;48(12):2881-2886.
28. Kasper K, Goving SJ, Stig S-H. The prevalence of cam-type deformity in the hip joint: a survey of 4151 of the Copenhagen Osteoarthritis Study. *Acta Radiol*. 2008;49(4):436-441. <https://doi.org/10.1080/02841850801935567>
29. Kasper K, Goving SJ, Sonne-Holm S. Prevalence of malformations of the hip joint and their relationship to sex, groin pain and risk of osteoarthritis: a population based survey. *J Bone Joint Surg*. 2010;92-A(5):1162-1169.
30. Hofmann U-K, Ipach I, Rondak I-C, Syha R, Götz M, Mittag F. Influence of age on parameters for femoroacetabular impingement and hip dysplasia in X-rays. *Acta Ortopedica Brasileira*. 2017;25(5):197-201.
31. Yates LB, Karasik D, Beck TJ, Cupples LA, Kiel DP. Hip structural geometry in old and old-old age: similarities and differences between men and women. *Bone*. 2007;41(4):722-732.
32. Kuhns BD, Weber AE, Levy DM, Wuerz TH. The natural history of femoroacetabular impingement. *Front Surg*. 2015;2:58.
33. Beck M, Chegini S, Ferguson S, Hosalkar HS. Mechanism of Femoroacetabular Impingement. In: Marín-Peña Ó, ed. *Femoroacetabular Impingement*. Berlin, Heidelberg: Springer; 2012:9-22. https://doi.org/10.1007/978-3-642-22769-1_2
34. van Buuren MMA, Arden NK, Bierma-Zeinstra SMA, et al. Statistical shape modeling of the hip and the association with hip osteoarthritis: a systematic review. *Osteoarthr Cartil*. 2021;29(5):607-618.
35. Nardo L, Parimi N, Liu F, et al. Femoroacetabular impingement: prevalent and often asymptomatic in older men: the osteoporotic fractures in men study. *Clin Orthop Relat Res*. 2015;473(8):2578-2586.
36. Atukorala I, Makovey J, Lawler L, Messier SP, Bennell K, Hunter DJ. Is there a dose-response relationship between weight loss and symptom improvement in persons with knee osteoarthritis? *Arthritis Care Res (Hoboken)*. 2016;68(8):1106-1114.
37. Ahedi H, Aitken D, Blizzard L, Cicuttini F, Jones G. The association between hip bone marrow lesions and bone mineral density: a cross-sectional and longitudinal population-based study. *Osteoarthritis Cartilage*. 2013;21(10):1545-1549.
38. Pfirrmann CW, Mengiardi B, Dora C, Kalberer F, Zanetti M, Hodler J. Cam and pincer femoroacetabular impingement: characteristic MR arthrographic findings in 50 patients. *Radiology*. 2006;240(3):778-785.
39. Beck M, Kalhor M, Leunig M, Ganz R. Hip morphology influences the pattern of damage to the acetabular cartilage: femoroacetabular impingement as a cause of early osteoarthritis of the hip. *J Bone Joint Surg Br*. 2005;87(7):1012-1018.
40. Scanzello C, Goldring S. The role of synovitis in osteoarthritis pathogenesis. *Bone*. 2012;51(2):249-257.
41. Sellam J, Berenbaum F. The role of synovitis in pathophysiology and clinical symptoms of osteoarthritis. *Nat Rev Rheumatol*. 2010;6(11):625-635.
42. Gregory J, Waarsing JH, Day J, et al. Early identification of radiographic osteoarthritis of the hip using an active shape model to quantify changes in bone morphometric features: can hip shape tell us anything about the progression of osteoarthritis? *Arthritis Rheum*. 2007;56(11):3634-3643.
43. Agricola R, Reijman M, Bierma-Zeinstra SM, Verhaar JA, Weinans H, Waarsing JH. Total hip replacement but not clinical osteoarthritis can be predicted by the shape of the hip: a prospective cohort study (CHECK). *Osteoarthr Cartil*. 2013;21(4):559-564.
44. Barr RJ, Gregory JS, Reid DM, et al. Predicting OA progression to total hip replacement: can we do better than risk factors alone using active shape modelling as an imaging biomarker? *Rheumatology (Oxford)*. 2012;51(3):562-570.
45. Gregory JS, Barr RJ, Yoshida K, et al. Shape of femoral head and neck correlates with clinical features of OA and can predict progression to total hip replacement. *Rheumatology*. 2009;48(Supplement 1):i5-i6.
46. Wluka AE, Ding C, Jones G, Cicuttini FM. The clinical correlates of articular cartilage defects in symptomatic knee osteoarthritis: a prospective study. *Rheumatology*. 2005;44(10):1311-1316.
47. Tanamas SK, Wluka AE, Pelletier J-P, et al. Bone marrow lesions in people with knee osteoarthritis predict progression of disease and joint replacement: a longitudinal study. *Rheumatology*. 2010;49(12):2413-2419.
48. Griffin D, Dickenson E, O'Donnell J, et al. The Warwick Agreement on femoroacetabular impingement syndrome (FAI syndrome): an international consensus statement. *Br J Sports Med*. 2016;50(19):1169-1176.

How to cite this article: Ahedi H, Winzenberg T, Bierma-Zeinstra S, et al. A prospective cohort study on cam morphology and its role in progression of osteoarthritis. *Int J Rheum Dis*. 2022;25:601-612. doi:[10.1111/1756-185X.14313](https://doi.org/10.1111/1756-185X.14313)