



Since January 2020 Elsevier has created a COVID-19 resource centre with free information in English and Mandarin on the novel coronavirus COVID-19. The COVID-19 resource centre is hosted on Elsevier Connect, the company's public news and information website.

Elsevier hereby grants permission to make all its COVID-19-related research that is available on the COVID-19 resource centre - including this research content - immediately available in PubMed Central and other publicly funded repositories, such as the WHO COVID database with rights for unrestricted research re-use and analyses in any form or by any means with acknowledgement of the original source. These permissions are granted for free by Elsevier for as long as the COVID-19 resource centre remains active.



## Case Report

# Multisystem inflammatory syndrome in a young adult successfully treated with plasmapheresis, immunoglobulins, and corticosteroids: a case report

Miodrag Sreckovic<sup>1,2</sup>, Ruzica Radojevic Marjanovic<sup>3</sup>, Biljana Popovska Jovicic<sup>3,4</sup>, Slobodan Jankovic<sup>5,6</sup>, Rasa Medovic<sup>7,8</sup>, Milica Begovic Cvetkovic<sup>9</sup>, Tatjana Lazarevic<sup>1,10</sup>, Milos Milosavljevic<sup>11,12</sup>, Stefan Simovic<sup>1,2,\*</sup>, Rada Vucic<sup>1,2</sup>

<sup>1</sup> Department of Internal Medicine, Faculty of Medical Sciences, University of Kragujevac, Serbia

<sup>2</sup> Clinic for Cardiology, University Clinical Center Kragujevac, Kragujevac, Serbia

<sup>3</sup> Clinic for Infectious Diseases, University Clinical Center Kragujevac, Kragujevac, Serbia

<sup>4</sup> Department of Infectious Diseases, Faculty of Medical Sciences, University of Kragujevac, Kragujevac, Serbia

<sup>5</sup> Department of Pharmacology, Faculty of Medical Sciences, University of Kragujevac, Kragujevac, Serbia

<sup>6</sup> Department of Pharmacology, University Clinical Center Kragujevac, Kragujevac, Serbia

<sup>7</sup> Department of Pediatrics, Faculty of Medical Sciences, University of Kragujevac, Kragujevac, Serbia

<sup>8</sup> Department of Pediatrics, University Clinical Center Kragujevac, Kragujevac, Serbia

<sup>9</sup> Department for Rheumatology, Clinic for Internal Medicine, University Clinical Center Kragujevac, Kragujevac, Serbia

<sup>10</sup> Department of Emergency Medicine, University Clinical Center Kragujevac, Kragujevac, Serbia

<sup>11</sup> Department of Pathology, Faculty of Medical Sciences, University of Kragujevac, Kragujevac, Serbia

<sup>12</sup> Department of Pathology, University Clinical Center Kragujevac, Kragujevac, Serbia

## ARTICLE INFO

## Article history:

Received 7 February 2022

Revised 16 July 2022

Accepted 22 July 2022

## Keywords:

Multisystem inflammatory syndrome

COVID-19

Plasmapheresis

## ABSTRACT

A novel condition named multisystem inflammatory syndrome has raised the alarm worldwide and is leading to severe illness and long-term effects in the post-COVID era. This condition includes infection with fever, abdominal symptoms, acute cardiac injury, and shock. It has similarities with severe forms of Kawasaki disease (KD). In this study, we present a case of a 20-year-old male patient with multisystem inflammatory syndrome associated with COVID-19 infection who was successfully treated with plasmapheresis, immunoglobulins, and steroids for 4 h/day without heparinization or ultrafiltration. Plasmapheresis represents a therapeutic option for KD in patients with all other therapeutic strategies that have failed. However, there is no evidence from controlled clinical trials confirming this option. In our case, plasmapheresis was beneficial in stabilizing and improving the patient's clinical condition. Given the pathophysiological and therapeutic similarities between KD and multisystem inflammatory syndrome, it could be considered a therapeutic option.

© 2022 The Author(s). Published by Elsevier Ltd on behalf of International Society for Infectious Diseases.

This is an open access article under the CC BY-NC-ND license (<http://creativecommons.org/licenses/by-nc-nd/4.0/>)

## Introduction

A novel condition named multisystem inflammatory syndrome in children (MIS-C) has raised alarm the worldwide, as it mainly affects children and leads to severe illness and long-term effects (Jiang *et al.*, 2020). Usually, it presents 2 to 6 weeks after SARS-CoV-2 infection with fever, abdominal symptoms, acute cardiac

injury, and shock and it has similarities with severe forms of Kawasaki disease (KD) (Feldstein *et al.*, 2020). However, a multisystem inflammatory syndrome in adults (MIS-A) occurs more rarely than a multisystem inflammatory syndrome in children (MIS-C) and mainly in young adults. It has not yet been well-defined or well-described and presents with heterogeneity of clinical signs and symptoms primarily seen in MIS-C (Patel *et al.*, 2021). Although several disease control centers have provided diagnostic criteria for MIS-C, clear guidance for diagnosing and treating MIS-A is lacking. For treating MIS-A, IVIG, steroids, and supportive-care treatments are currently suggested. However, they emphasize

\* Correspondence to: Stefan Simovic, Clinic for Cardiology, University Clinical Center Kragujevac, Zmaj Jovina 30, 34000 Kragujevac, Serbia.  
E-mail address: [simovicst@gmail.com](mailto:simovicst@gmail.com) (S. Simovic).

“that this approach to managing MIS-A has not been studied” (Davogustto et al., 2021). The American College of Rheumatology has mentioned that anakinra can be an additional therapy in patients who are refractory to IVIG and steroids. Thus far, there has been no randomized controlled trial to elaborate on the role of anakinra in adults with MIS-A (Ahmad et al., 2021). Findings in the literature indicate that plasmapheresis may be effective in critically ill patients with MIS-C (Atay et al., 2021). The Centers for Disease Control and Prevention recommends COVID-19 vaccination as the best protection against MIS-A, but there are no data on the safety and efficacy of COVID-19 vaccines in patients with a history of MIS-C or MIS-A.

Plasmapheresis, although controversial, represents a therapeutic option for critically ill patients, especially those with preserved renal function. In this study, we describe a case of a young adult male patient with MIS-A associated with SARS-CoV-2 infection who was successfully treated with plasmapheresis.

### Case report

A 20-year-old man was admitted to the intensive care unit with fever (up to 39.5 °C); abdominal, muscle, and joint pain; diarrhea; a petechial rash on the skin of the trunk; and nonpurulent conjunctivitis that appeared on the day before admission. Medical history included a mild form of COVID-19 5 weeks before the presentation. On admission, he had a fever (39.3 °C), periorbital livid edema, and fused macular rash on the skin of the trunk and back. Cardiopulmonary examination revealed tachycardia, whereas the lung sounds were normal. The initial electrocardiogram showed sinus tachycardia with a heart rate of 125 beats/min, blood pressure of 90/50 mm Hg, oxygen saturation of 87%, and partial pressure of oxygen of 60 mm Hg. The parameters monitored were markers of inflammation (CRP, procalcitonin, IL-6[Interleukin-6]), cardiac biomarkers (N-terminal pro-B-type natriuretic peptide [NT-proBNP], troponin), and coagulation markers (D-dimer).

Initial laboratory results (normal ranges indicated in parentheses) showed leukocytosis, with a white blood cell count of 11.3 (4.9–10.8) K/ $\mu$ l; neutrophilia, with a neutrophil count of 10.37 (2.1–6.5) K/ $\mu$ l; CRP level of 334 (0–5) mg/l; procalcitonin level of 24.6 (0.5–2) ng/ml; and IL-6 level of 198.8 (<7) pg/ml. Platelet count was 45 (135–450) K/ $\mu$ l; D-dimer level was 4.2 (<0.5)  $\mu$ g/ml; high-sensitivity troponin I level was 0.568 (<0.0342) ng/ml; NT-proBNP level was 17,570 (<125) pg/ml; anti-streptolysin-O level was 290 (<250) IU/ml; total immunoglobulin G (IgG) level was 31.04 (7–16) g/l; and total immunoglobulin M (IgM) level was 2.4 (0.4–2.3) g/l. Levels of C3 and C4 complement, rheumatoid factor, antimicrobial antibodies, antibodies against double-stranded DNA, anti-cardiolipin IgM and IgG antibodies, antineutrophil cytoplasmic antibodies (cANCA and pANCA), anti-citrullinated protein antibody, and antinuclear antibody were normal. Multiple polymerase chain reaction (PCR) assay results were negative for SARS-CoV-2; SARS-CoV-2 IgM antibodies were not detected, whereas SARS-CoV-2 IgG antibodies were detected. A nasal swab was used for PCR multiplex analysis to detect different microorganisms (*Acinetobacter* spp.; *Bacteroides fragilis*; *Enterobacter cloacae*; *Escherichia coli*; *Klebsiella aerogenes*, *oxytoca*, and *pneumoniae*; *Proteus* spp.; *Salmonella* spp.; *Serratia marcescens*; *Haemophilus influenzae*; *Neisseria meningitidis*; *Pseudomonas aeruginosa*; *Stenotrophomonas maltophilia*; *Candida albicans*, *C. auris*, *C. glabrata*, *C. krusei*, *C. parapsilosis*, and *C. tropicalis*; and *Cryptococcus neoformans* and *gattii*). Enzyme-linked immunosorbent assay was used to detect *Aspergillus galactomannan* and *Candida mannan* antigens. These analyses were all negative.

Echocardiography showed discrete circular pericardial effusion of 2–3 mm and preserved left ventricular global kinetics. Paraumbilical and infraumbilical lymphadenopathy, with the largest

conglomerate measuring 24 × 15 mm, was revealed on the abdominal ultrasound. Hyperechoic lymph nodes without increased vascularization and with a maximum diameter of 7 mm were seen on the neck, axilla, and groin ultrasound. Chest CT showed bilateral ground-glass opacities in posterior segments of lower lung lobes, thickened interlobular septa and consolidation zones, and bilateral pleural effusions, but no signs of hilar and mediastinal lymphadenopathy (Figure 1a). Abdominal magnetic resonance imaging revealed a small amount of free fluid in paracolic, perisplenic, and perihepatic spaces, with pronounced subcutaneous edema on the anterior abdominal wall (Figure 1b). At the level of the mesenteric root, an irregular and inhomogeneous semisolid mass was observed (“misty mesentery”) (Figure 1c).

Pathohistological analysis of the mesenteric lymph node biopsy sample showed a lymph node of disturbed structure, with fields of geographical necrosis around which were numerous polyclonal plasma cells. The network of follicular dendritic cells was preserved. Numerous small T lymphocytes, polyclonal plasma cells, and histiocytes were seen in the paracortex (Figure 1d).

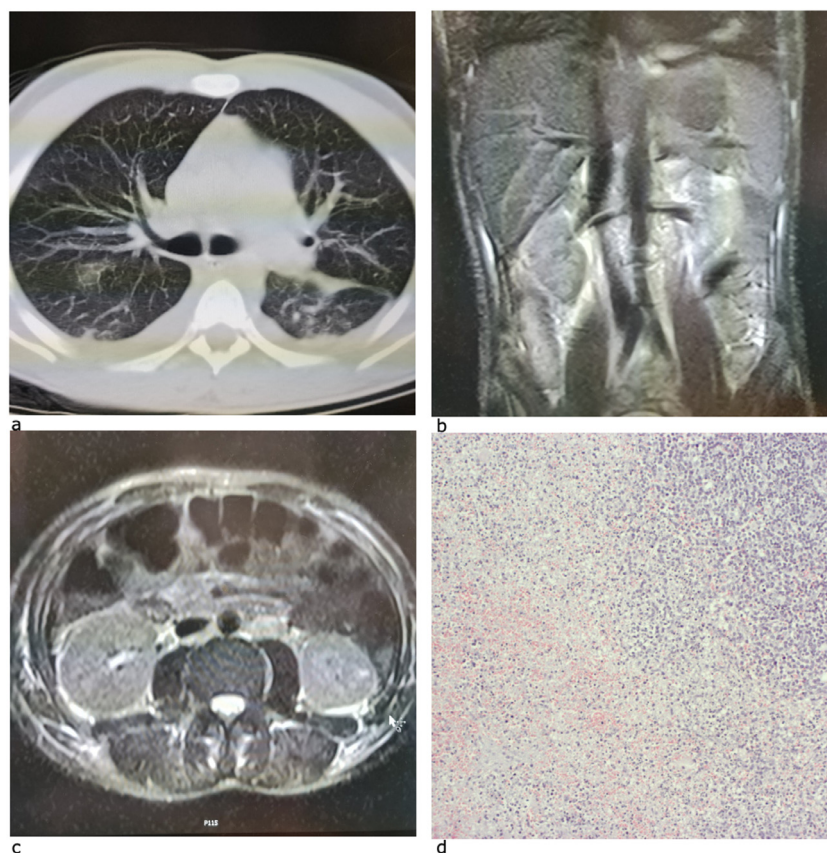
A multidisciplinary team concluded that a multisystemic inflammatory response was present and decided to begin parenteral anticoagulant therapy and plasmapheresis for 4 h/day without heparinization and ultrafiltration. Stabilization of vital signs was achieved; we therefore decided to initiate treatment consisting of IVIG (two doses of 2 g/kg each, with an interval of 24 h) and corticosteroid therapy (methylprednisolone 2 mg/day) 24 h after the initiation of plasmapheresis. Four days after plasmapheresis initiation, the patient’s condition stabilized with normalization of vital signs, promotion of oxygenation, and improvement in inflammatory markers. Further resolution of symptoms and improvement in inflammatory and coagulation markers was observed during the next 3 days. On the fifth day after the initiation of plasmapheresis, a diagnosis of MIS-A was made according to World Health Organization (2020) criteria. The patient was discharged with prednisone, apixaban, and vitamin supplementation 9 days after the plasmapheresis initiation.

Three months after discharge from the hospital, the patient is feeling well and is without laboratory and clinical signs of inflammation.

### Discussion

This report is the first in the literature that describes the successful treatment of a young male patient with MIS-A using plasmapheresis. Although immunoglobulin and corticosteroid therapy was administered after plasmapheresis, the initial administration of plasmapheresis resulted in a clinical improvement.

The prevalence and pathophysiology of MIS-C and MIS-A remain unknown. Data from Public Health England (GOV.UK, 2020) show a drastically increased MIS-C beginning in April 2020, 1 month after the increase in COVID-19 cases in the UK. Vigorous immune response to SARS-CoV-2 and during the chronic COVID phase can be a consequence of viral mimicry by autoantibodies, recognition of viral antigens revealed on infected cells, and formation of immune complexes, or activation of host immune cells by viral superantigen sequences (Cheng et al., 2020). Additionally, several differences in the antibodies produced during COVID-19 in children and adults have been described. In contrast to patients with MIS-A, patients with MIS-C had antibodies associated with IL-16, lymphocytes, and monocyte activation, indicating differences in the inflammatory response (Selva et al., 2020; Gruber et al., 2020). MIS-C has similarities to KD or toxic shock syndrome in clinical and laboratory features, indicating a possible immune-mediated and vascular injury (as seen in KD) by SARS-CoV-2. The majority of MIS-C patients meet the criteria for both typical and atypical KD (Jiang et al., 2020; McCrindle et al., 2017). Therefore, both KD



**Figure 1.** (a) Chest computed tomography showing bilateral ground-glass opacities in posterior segments of lower lung lobes, with thickened interlobular septa and consolidation zones more pronounced posterobasally. (b) Abdominal magnetic resonance imaging showing a small amount of free fluid in paracolic, perisplenic, and perihepatic spaces and pronounced subcutaneous edema on the anterior abdominal wall. (c) Abdominal magnetic resonance imaging revealing an irregular and inhomogeneous semisolid mass at the level of the mesenteric root (“misty mesentery”). (d) Lymph node biopsy sample showing benign reactive hyperplasia.

and MIS-C treatments consist of high-dose immunoglobulin therapy and corticosteroids.

There is no definitive consensus on the treatment options for MIS-A as there is for MIS-C; in our case, plasmapheresis with immunoglobulins and corticosteroids turned out to be a good decision. Early-onset plasmapheresis in patients with severe MIS-A accompanied by severe cytokine seizures may be a powerful immunomodulatory technique that can be used to rapidly suppress the inflammatory response and remove inflammatory cytokines. Early plasmapheresis enabled a prompt clinical and laboratory response in this case; further rapid improvement was obtained using immunoglobulins and corticosteroids. Our patient met all of the criteria for MIS diagnosis, including fever, rash, non-purulent conjunctivitis, abdominal pain and diarrhea, hypotension, coagulopathy, elevated inflammatory biomarkers, evidence of past SARS-CoV-2 infection, and absence of other apparent microbial causes of inflammation. However, the criteria for diagnosing MIS are very general, making the diagnosis a challenge. During the search for a definitive diagnosis, our patient underwent a set of diagnostic procedures that determined generalized lymphadenopathy with free fluid in the abdomen; the lymph node biopsy sample showed benign reactive hyperplasia.

Plasmapheresis or plasma exchange also represents a therapeutic option for KD in patients with all other therapeutic strategies have failed. However, no evidence from controlled clinical trials confirms this option (McCrindle et al., 2017). In our case, plasmapheresis had a beneficial effect in stabilizing and improving the patient’s clinical condition; further and rapid improvement was achieved with immunoglobulins and corticosteroids. The use of plasmapheresis in MIS-C and MIS-A has not been reported previ-

ously. However, given the pathophysiological and therapeutic similarities between KD and MIS, it could be considered a therapeutic option.

## Conclusion

Although there is no consensus on the use of plasmapheresis, our experience in the application of this therapeutic approach in a patient with MIS-A before the application of standard therapy showed significant improvement in clinical picture and in inflammation, coagulation, and cardiac markers. Our experience has shown that this approach has a great benefit for the patient with MIS-A. However, more extensive clinical studies are necessary for the possible recommendation of using such therapeutic options.

## CRediT authorship contribution statement

**Miodrag Sreckovic:** Data curation, Writing – original draft. **Ruzica Radojevic Marjanovic:** Data curation. **Biljana Popovska Jovicic:** Writing – original draft. **Slobodan Jankovic:** Writing – original draft. **Rasa Medovic:** Data curation, Writing – original draft. **Milica Begovic Cvetkovic:** Data curation. **Tatjana Lazarevic:** Data curation, Writing – original draft. **Milos Milosavljevic:** Writing – original draft. **Stefan Simovic:** Data curation, Writing – original draft. **Rada Vucic:** Data curation.

## Declarations of competing interest

The authors have no competing interests to declare.

## Funding

This research did not receive any specific grant from funding agencies in the public, commercial, or not-for-profit sectors.

## Ethical approval

The research was approved by the Ethical Committee, University Clinical Center Kragujevac, Kragujevac, Serbia. Informed consent was obtained before submitting the manuscript according to the CARE guidelines.

## References

- Ahmad F, Ahmed A, Rajendraprasad SS, Loranger A, Gupta S, Velagapudi M, Vivekanandan R, Nahas JA, Plambeck R, Moore D. Multisystem inflammatory syndrome in adults: a rare sequela of SARS-CoV-2 infection. *Int J Infect Dis* 2021;108:209–11.
- Atay G, Hasbal C, Türk M, Erdo?an S, Sözeri B. The role of therapeutic plasma exchange (TPE) in multisystem inflammatory syndrome in children (MIS-C). *Children (Basel)* 2021;8:498.
- Cheng MH, Zhang S, Porritt RA, Arditi M, Bahar I. An insertion unique to SARS-CoV-2 exhibits superantigenic character strengthened by recent mutations. *bioRxiv* 2020. 21 May <https://www.biorxiv.org/content/10.1101/2020.05.21.109272v1>. accessed XXX.
- Davogustto GE, Clark DE, Hardison E, Yanis AH, Lowery BD, Halasa NB, Wells QS. Characteristics associated with multisystem inflammatory syndrome among adults with SARS-CoV-2 infection. *JAMA Netw Open* 2021;4.
- Feldstein LR, Rose EB, Horwitz SM, Collins JP, Newhams MM, Son MBF, Newburger JW, Kleinman LC, Heidemann SM, Martin AA, Singh AR, Li S, Tarquinio KM, Jaggi P, Oster ME, Zackai SP, Gillen J, Ratner AJ, Walsh RF, Fitzgerald JC, Keenaghan MA, Alharash H, Doymaz S, Clouser KN, JS Jr Giuliano, Gupta A, Parker RM, Maddux AB, Havalad V, Ramsingh S, Bukulmez H, Bradford TT, Smith LS, Tenforde MW, Carroll CL, Riggs BJ, Gertz SJ, Daube A, Lansell A, Coronado Munoz A, Hobbs CV, Marohn KL, Halasa NB, Patel MM, Randolph AGCDC COVID-19 Response Team. Multisystem inflammatory syndrome in U.S. children and adolescents. *N Engl J Med* 2020;383:334–46.
- GOV.UK. Coronavirus (COVID-19) statistics and analysis. <https://www.gov.uk/guidance/coronavirus-covid-19-statistics-and-analysis>, 2020 (accessed 20 May 2021).
- Gruber C, Patel R, Trachman R, Lepow L, Amanat F, Krammer F, et al. Mapping systemic inflammation and antibody responses in multisystem inflammatory syndrome in children (MIS-C). *Cell* 2020;183:982–95.
- Jiang L, Tang K, Levin M, Irfan O, Morris SK, Wilson K, et al. COVID-19 and multisystem inflammatory syndrome in children and adolescents. *Lancet Infect Dis* 2020;20:e276–88.
- McCrinkle BW, Rowley AH, Newburger JW, Burns JC, Bolger AF, Gewitz M, et al. Diagnosis, treatment, and long-term management of Kawasaki disease: a scientific statement for health professionals from the American Heart Association. *Circulation* 2017;135:e927–99.
- Patel P, DeCuir J, Abrams J, Campbell AP, Godfred-Cato S, Belay ED. Clinical characteristics of multisystem inflammatory syndrome in adults: a systematic review. *JAMA Netw Open* 2021;4.
- Selva KJ, van de Sandt CE, Lemke MM, Lee CY, Shoffner SK, Chua BY, et al. Distinct systems serology features in children, elderly and COVID patients. *medRxiv*. 18 May 2020. <https://www.medrxiv.org/content/10.1101/2020.05.11.20098459v1> (accessed XXX).
- World Health Organization. Multisystem inflammatory syndrome in children and adolescents with COVID-19: scientific brief. [https://apps.who.int/iris/bitstream/handle/10665/332095/WHO-2019-nCoV-Sci\\_BriefMultisystem\\_Syndrome\\_Children-2020.1-eng.pdf?sequence=1&isAllowed=y](https://apps.who.int/iris/bitstream/handle/10665/332095/WHO-2019-nCoV-Sci_BriefMultisystem_Syndrome_Children-2020.1-eng.pdf?sequence=1&isAllowed=y), 2020 (accessed XXX).