



Case Report

Aggressive scalp and sternal lesion: A presentation of rare case of metastatic eccrine carcinoma



Cha Sha Rownose^a, Mohamad Sobri Mohamad Saupi^b, Siti Zubaidah Sharif^b,
Nik Amin Sahid Nik Lah^{a,*}

^a Surgical Department, Faculty of Medicine & Health Sciences, University Malaysia Sabah, Kota Kinabalu, Sabah, Malaysia

^b Surgical Department, Hospital Queen Elizabeth 2, Kota Kinabalu, Sabah, Malaysia

ARTICLE INFO

Keywords:

Eccrine carcinoma
Sweat gland carcinoma

ABSTRACT

Introduction: Ductal Eccrine carcinoma (DEC) is a rare primary cutaneous tumor that exhibits both squamous and adnexal ductal differentiation. Due to its rarity in clinical practice we present as case of DEC and a literature review on the latest management of this rare disease.

Case presentation: We report a case 41 years old female presented with lesion on the scalp and sternal mass, increasing in size with itchiness and erythematous for 6 months duration. Further CECT scan of brain and neck shows features of malignant left frontal scalp lesion with poor plane with overlying skin and underlying skull bone and CECT of thorax shows a large, irregular heterogeneously enhancing mass with necrotic center noted at right hilar within superior segment of right lower lobe, encasing right middle and lower lobe bronchi. Wedge biopsy of scalp lesion showed an intradermal lesion extensively infiltrating by malignant gland accompanied by desmoplasia and the tumor cells are seen extending into the surgical margins suggestive of ductal eccrine carcinoma.

Clinical Discussion: This case highlights the importance and challenges in achieving early diagnosis coupled with the scarcity of information on these leads to difficulty in managing this patient.

Conclusion: In managing Ductal Eccrine Carcinoma tumor, standard method of treatment for has not been established. However, wide surgical excision is the treatment of choice for localized lesions. Regarding prognosis, there is conflicting data published which we describe in this article.

1. Introduction

Eccrine carcinoma (EC) is a rare carcinoma that originates from the eccrine sweat glands of the skin and accounts for less than 0.01% of diagnosed cutaneous malignancies [1]. Sweat gland tumors have traditionally subdivided into four broad groups: eccrine, apocrine, mixed origin (eccrine and apocrine) and others un-classifiable sweat gland tumors. Eccrine ductal carcinoma exhibits both squamous and adnexal ductal differentiation.) We report a 41 years old female with eccrine ductal carcinoma presented with lesion on the scalp and sternal mass of which was rapidly increase in size with itchiness and erythematous for 6 months duration. This case report has been reported in line with the SCARE 2020 criteria [2].

2. Case presentation

A 41-year-old housewife Dusun, para 3 presented surgical outpatient clinic with erythematous papule for the last 6 month associated with slightly keratotic and ulcerated at the scalp region with yellowish discharge. The lesion increases in size from small pimple size to about 4 cm × 4 cm over 6 months associated with on and off itchiness upon lesion (Fig. 1). Patient also presenting with sternal mass about 6 cm × 5 cm in size, hard in consistency, non-mobile, irregular and associated with pain upon palpation. As comorbidities, patient had systemic hypertension and dyslipidemia for which patient was in diet and lifestyle modification and patient did not take any medication. She did not has any past surgical history. Drug and allergy history was unremarkable. There no family history of cancer running in family. She did not some or consume alcohol. CT-scan of the brain and neck findings of malignant left frontal scalp session, well defined exophytic enhancing scalp session

* Corresponding author.

E-mail address: nike.opo@ums.edu.my (N.A.S.N. Lah).

<https://doi.org/10.1016/j.amsu.2021.102322>

Received 14 February 2021; Received in revised form 11 April 2021; Accepted 13 April 2021

Available online 16 April 2021

2049-0801/© 2021 The Authors. Published by Elsevier Ltd on behalf of IJS Publishing Group Ltd. This is an open access article under the CC BY-NC-ND license

(<http://creativecommons.org/licenses/by-nc-nd/4.0/>).

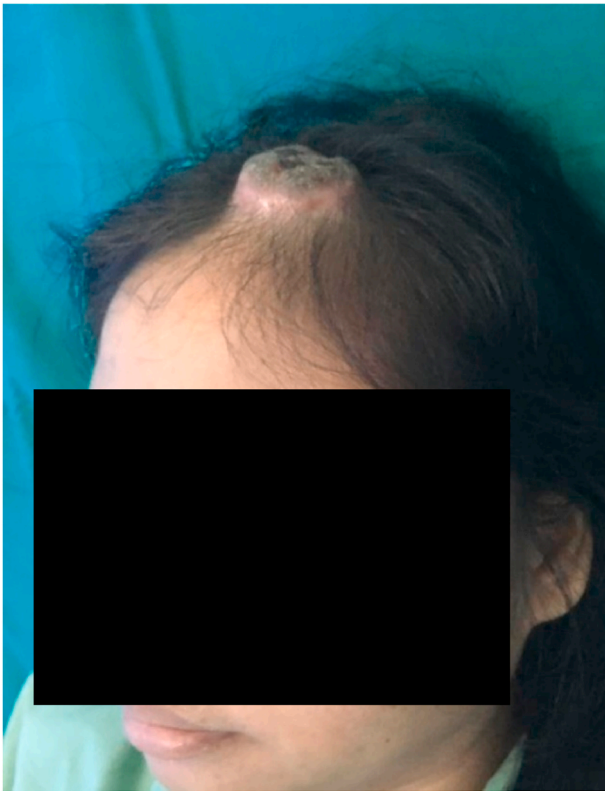

Fig. 1. Scalp lesion of Eccrine Tumor.

with irregular margin & necrotic center seen at the left frontal aspect measuring 2.9 cm × 3.3 cm × 1.5cm, has poor plane with overlying skin & underlying skull bone, no bony erosion (Fig. 2). Other finding of CT brain was of enlarged left intra-parotid lymph node, suspicious of metastatic foci and multiple thyroid nodules. Further USG done with finding

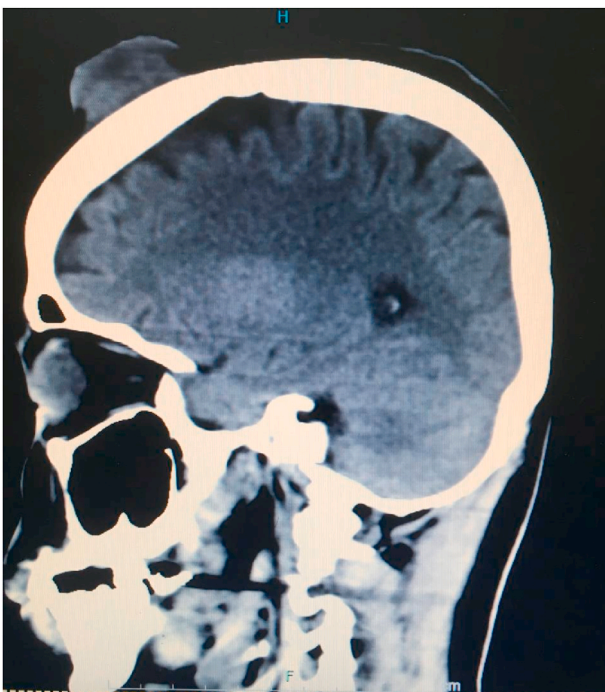


Fig. 2. CT brain and neck findings of malignant left frontal scalp session, well defined exophytic enhancing scalp session with irregular margin.

of right thyroid nodules with bilateral cervical lymphadenopathy (TIRADS 4). Histology from wedge excision biopsy of scalp lesion which was done by the surgeon showed typical features of eccrine ductal carcinoma with glands are seen abutting the overlying epidermis with ulceration. The glands are lined by pseudostratified layer of cuboidal to columnar epithelium displaying markedly pleomorphic nuclei with prominent nucleoli and moderate eosinophilic cytoplasm. Mitosis is brisk with perineural invasion. Others, since patient presented with sternal mass, CT thorax and pelvic done and showed right lung lesion with hilar nodal, left adrenal, subcutaneous and bone metastasis. Patient was referred to oncology team to consider of starting chemotherapy and radiotherapy. However patient refuse to receive any further intervention due to advanced disease. Patient succumbed after three month of diagnosis.

3. Discussion

Ductal Eccrine Carcinoma (DEC) or Sweet Gland Carcinoma (SGC) are rare malignancies. Due to the rare entities, the classification of this tumors is complex.

In general, Eccrine tumors further divide into benign and malignant. Benign entities include poroma, hidradenoma, spiradenoma, cylindroma, syringometaplasia, syringoma, syringofibroadenoma, and chondroid syringoma. Malignant eccrine carcinoma entities include porocarcinoma, hidradenocarcinoma, malignant spiradenoma carcinoma, malignant cylindroma, syringoid eccrine carcinoma, microcystic adnexal carcinoma, mucinous carcinoma, adenoid cystic carcinoma, and ductal papillary adenocarcinoma. Other un-classifiable sweat gland tumors include eccrine ductal carcinoma, basaloid eccrine carcinoma, clear cell eccrine carcinoma and non-specified sweat gland carcinomas [1].

Malignant sweat gland tumors are heterogeneous neoplasms of different biological behavior. The principal characteristic of these tumors is that they are locally aggressive and show a high rate of recurrence. Separation of eccrine carcinoma has traditionally been according to their behavior into low grade and high grade malignant. Proper identification of eccrine carcinoma is sometimes challenging due to the morphological similarity to other common tumors and the lack of consistent immunohistochemical markers. DEC is more frequently located on the head and neck, but cases on the trunk and extremities have also been described [3]. Because of its striking histologic homology to invasive breast carcinoma, differential diagnosis can be challenging, particularly on unusual anatomic sites such as the breast or axilla. Fewer than 50 cases have been reported under the name of DEC and its synonyms. Clinically, DEC usually presents as a slowly growing, ill-defined, hardened nodule or plaque that can measure up to 10 cm [4]. It has a predilection for the head and neck, although cases on the trunk and extremities have also been described and occurs mostly in middle-aged to elderly adults of both sexes [4]. In the case of our reported 41-year-old patient, a single scalp lesion was noted since June 2019. Initially it was small (mistaken for pimples at that time); however, it progressively increased in size. There is itchiness around the skin of the lesion, yellowish pus discharge from the lesion and there is erythematous of the lesion.

Histologically, DEC shows a markedly infiltrative growth pattern and centered on the dermis, often extending into the subcutaneous tissue. Pleomorphism and mitotic activity are variable features but are usually not marked. The stroma is characteristically desmoplastic and perineural and lymph vascular invasion are commonly present [4].

Wedges biopsy of the scalp lesions was done in our reported patient, the result shows an intradermal lesion extensively infiltrating by malignant glands accompanied by desmoplasia. The glands are lined by pseudostratified layer of cuboidal to columnar epithelium displaying markedly pleomorphic nuclei with prominent nucleoli and moderate eosinophilic cytoplasm. Mitosis is brisk with perineural invasion is seen in focus area; however, no lymphovascular permeation observed in the

patient. The tumor cells are seen extending into the surgical margin. This showed the classical findings of DEC.

On immunohistochemistry, usually tumor cells are cytokeratin positive, expressing mostly simple epithelial cytokeratin (CK7, CK8, CK18 and CK19) [1]. They may also express estrogen and progesterone receptors, CEA, c-erbB-2, S-100 and GCDPF15 to varying degrees [4]. However, the biopsy of scalp lesion result on immunohistochemistry shows negative for PAX8, TTF1, P40, CK5/6, NAPSIN A, ER and CDX2.

The investigation method for eccrine ductal carcinoma is usually by biopsy. A shave, punch, or excisional biopsy should be performed in order to obtain a representative sample of the eccrine carcinoma lesion; this sample should be sent for histopathologic evaluation to make the initial diagnosis. Because of the high rate of local recurrence (10–70%) following conventional surgical excision there is another method utilized which is the Moh's micrographic surgery [5].

In this patient, a wedge biopsy of the scalp lesion was done. The biopsy is obtained in order to view the histopathological features of the scalp lesion. The histopathological macroscopic findings were raised scalp lesion, firm with central ulceration measuring 3 × 3 cm. The histopathological microscopic report states that the specimen shows an intradermal lesion extensively infiltrating by malignant glands accompanied by desmoplasia. In a few areas, glands are seen abutting the overlying epidermis with ulceration. Glands are lined by pseudostriated layer of cuboidal to columnar epithelium displaying markedly pleomorphic nuclei with prominent nucleoli and moderate eosinophilic cytoplasm. Perineural invasion is seen in the focus area. Immunohistochemistry was done to rule out the possibility of extracutaneous metastases. From the morphology report, the hemoglobin is reduced, and patient is mildly hypochromic. Leukocytosis with neutrophilia and monocytosis can be seen as well as thrombocytosis. The report suggests that there is underlying iron deficiency anemia and reactive changes likely secondary to underlying inflammation.

Patient also had CT scan of pelvic and thorax and the result came in as an incidental finding of primary right lung tumor with hilar nodular lung, left adrenal, subcutaneous and bone metastasis. A soft ill-defined sclerosis change can be seen at level L1 vertebra body. The mass is large with necrotic center with size of 4 × 4 cm.

Treatment for eccrine tumor depends on the cancer's specific type, how far it has spread, and the person's performance status. Gross total surgical excision with safety margin is the main management of eccrine tumor with cure rate of 70–80%, either by radical surgical excision or Mohs micrographic surgery [5]. As eccrine carcinomas tend to be locally infiltrating and have a tendency for perineural invasion, wide excision is recommended. However, while the clinical experience is limited, the use of Mohs micrographic surgery appears to decrease recurrence rates compared with surgical excision. Lymph nodes dissection is to be considered in case of regional lymph node involvement [6]. It is recommended the use of adjuvant local radiotherapy to reduce local recurrence, especially when margins are close. Chemotherapy and radiotherapy are used in metastatic lesions [5]. One report suggested radio-sensitivity of these tumors, and adjuvant radiation was therefore recommended in high-risk cases (i.e., large tumors of 5 cm and positive surgical margins of 1 cm) and moderate to poorly differentiated tumors with lymphovascular invasion [1]. Adjuvant radiation to the involved lymph node basin is suggested in the setting of extra nodal extension or extensive involvement, that is, 4 lymph nodes. Hormonal therapy can be effective in cases in which estrogen and progesterone receptors are expressed, which can range from 19% to 30% of eccrine sweat gland carcinomas [6]. It was found that the prognosis of eccrine tumor is determined by histological factors that are predictive for poor prognosis. These are lymphovascular invasion, tumor margin status after resection, mitotic count (>14/HPF) and tumor depth (>7 mm) [7]. Because eccrine tumor is an infrequent entity, no randomized control trials exist that examine the management options [2]. In our case, patient was referred to oncology team, however patient was not keen for further intervention due to advanced metastatic disease and succumbed three

month after being diagnosed.

4. Conclusion

Ductal Eccrine Carcinoma (DEC) are rare malignancies. Because of its rarity, a standard method of treatment for has not been established. However, wide surgical excision is the treatment of choice for localized lesions. Regarding prognosis, there is conflicting data published in the literature. Some authors document a good prognosis and rare metastasis, while others report a poor prognosis, with up to 50% of patients developing metastasis to lymph nodes or viscera, and cases with visceral metastases being almost invariably fatal. Local recurrence is common and is seen in up to 70–80% of all cases. A conflict regarding the histological classification of the sweat gland tumor is still ongoing, thus making the management of DEC more difficult and require multidisciplinary approach to achieve the best outcome for the patient.

Provenance and peer review

Not commissioned, externally peer-reviewed.

Sources of funding

None.

Ethical approval

Ethical approval obtained from local institution.

Consent

Written informed consent was obtained from the patient for publication of this case report and accompanying images. A copy of the written consent is available for review by the Editor-in-Chief of this journal on request.

Author contribution

Nik Amin Sahid initiated the case report. Cha Sha Rownose did the writing of the manuscript. Nik Amin Sahid supervised, reviewed and edited the manuscript. Mohamad Sobri Mohamad Saupi involved in the write up and provide the clinical data. Siti Zubaidah Sharif supervised.

Research registration (for case reports detailing a new surgical technique or new equipment/technology)

N/a

Guarantor

Nik Amin Sahid.

Declaration of competing interest

The authors declare that there are no conflicts of interest.

Appendix A. Supplementary data

Supplementary data to this article can be found online at <https://doi.org/10.1016/j.amsu.2021.102322>.

References

- [1] Abhishek Soni, et al., Current management approach to hidradenocarcinoma: a comprehensive review of the literature, *Ecanc. Med. Sci.* 9 (2015).

- [2] R.A. Agha, T. Franchi, C. Sohrabi, G. Mathew, for the Scare Group, The SCARE 2020 guideline: updating consensus surgical CAse REport (SCARE) guidelines, *Int. J. Surg.* 84 (2020) 226–230.
- [3] Hatem Kaseb, Hani M. Babiker, Cancer, an overview of eccrine carcinoma, in: StatPearls, U.S. National Library of Medicine, Treasure Island (FL), StatPearls Publishing, 2019, pp. 1–4. <https://www.ncbi.nlm.nih.gov/books/NBK541042/>.
- [4] Maria Helena Brito, Toda Sanches de, et al., Ductal eccrine carcinoma of the axilla: a diagnostic pitfall, in: *Anais Brasileiros De Dermatologia*, Sociedade Brasileira De Dermatologia 92, Sociedade Brasileira de Dermatologia, 2017, pp. 239–242. <http://www.ncbi.nlm.nih.gov/pmc/articles/PMC5429113/>.
- [5] J.K. Wildemore, J.B. Lee, T.R. Humphreys, Mohs surgery for malignant eccrine neoplasms, *Dermatol. Surg.* 30 (12p2) (2004 Dec. 30) 1574–1579. <https://doi.org/10.1111/j.1524-4725.2004.30569.x>.
- [6] I.M. Cholz, W. Hartschuh, Primary mucinous eccrine carcinoma of the skin - a rare clinical tumor with many differential diagnoses, *J. Dtsch Dermatol. Ges.* 8 (6) (2009 Oct 13) 446–448. <https://doi.org/10.1111/j.1610-0387.2009.07291.x>.
- [7] A. Dairi, K. Ashour, Eccrin/e porocarcinoma of the scalp: a case report and review of literature, 2019.