

Dynamic changes of renal cortical blood perfusion before and after percutaneous transluminal renal artery stenting in patients with severe atherosclerotic renal artery stenosis

Na Ma¹, Yan Li¹, Siyu Wang¹, Mengpu Li¹, Yongjun Li², Hu Ai³, Hui Zhu⁴, Yang Wang⁵, Fajin Guo¹, Junhong Ren¹

¹Department of Sonography, Beijing Hospital, National Center of Gerontology, Institute of Geriatric Medicine, Chinese Academy of Medical Science, Beijing 100730, China;

²Department of Vascular Surgery, National Center of Gerontology, Institute of Geriatric Medicine, Chinese Academy of Medical Science, Beijing 100730, China;

³Department of Cardiology, National Center of Gerontology, Institute of Geriatric Medicine, Chinese Academy of Medical Science, Beijing 100730, China;

⁴Department of Nuclear Medicine, National Center of Gerontology, Institute of Geriatric Medicine, Chinese Academy of Medical Science, Beijing 100730, China;

⁵Department of Medical Research & Biometrics Center, National Center for Cardiovascular Diseases and Fuwai Hospital, CAMS and PUMC, Beijing 100037, China.

Abstract

Background: This study aims to observe the dynamic changes of renal artery (RA) disease and cortical blood perfusion (CBP) evaluated by contrast-enhanced ultrasound (CEUS) after percutaneous transluminal renal artery stenting (PTRAS) in patients with severe atherosclerotic renal artery stenosis (ARAS) and to analyze the relationship between CBP and prognosis.

Methods: This was a single-center retrospective cohort study. A total of 98 patients with unilateral severe ARAS after successful PTRAS in Beijing Hospital from September 2017 to September 2020 were included. According to renal glomerular filtration rate (GFR) detected by radionuclide imaging at 12 months after PTRAS, all patients were divided into the poor prognosis group ($n = 21$, GFR decreased by $\geq 20\%$ compared with baseline) and the control group ($n = 77$, GFR decreased by $< 20\%$ or improved compared with baseline). Renal artery stenosis was diagnosed by digital subtraction angiography, and renal CBP was evaluated by CEUS using TomTec Imaging Systems (Germany) before PTRAS, at 6 months and 12 months after discharge. The receiver operating characteristic (ROC) curve with area under the curve (AUC) was used to analyze the predictive value of CBP parameters, including area under ascending curve (AUC1), area under the descending curve (AUC2), rising time (RT), time to peak intensity (TTP), maximum intensity (IMAX), and mean transit time (MTT) for poor prognosis.

Results: Among the 98 patients, there were 52 males (53.1%), aged 55–74 years old, with an average age of 62.1 ± 8.7 years, and an average artery stenosis of $82.3 \pm 12.9\%$. The poor prognosis group was associated with significantly increased incidence of diabetes (76.2% vs. 41.6%), and lower levels of GFR of the stenotic kidney (21.8 mL/min vs. 25.0 mL/min) and total GFR (57.6 mL/min vs. 63.7 mL/min) (all $P < 0.05$), compared with the control group ($P < 0.05$). In addition, the rate of RA restenosis was significantly higher in the poor prognosis group than in the control group (9.5% vs. 0, $\chi^2 = 9.462$, $P = 0.002$). Compared with the control group, the poor prognosis group was associated with significantly decreased baseline AUC1 and AUC2, and extended duration of TTP and MTT ($P < 0.05$). At 6 months and 12 months of follow-up, patients in the control group were associated with markedly increased AUC1, AUC2, and IMAX, and shorter duration of RT and MTT ($P < 0.05$). The ROC curve showed that the predictive values of AUC1, AUC2, RT, TTP, IMAX, and MTT for poor prognosis were 0.812 (95% CI: 0.698–0.945), 0.752 (95% CI: 0.591–0.957), 0.724 (95% CI: 0.569–0.961), 0.720 (95% CI: 0.522–0.993), 0.693 (95% CI: 0.507–0.947), and 0.786 (95% CI: 0.631–0.979), respectively.

Conclusions: Preoperative renal CBP in severe ARAS patients with poor prognosis is significantly reduced, and does not show significant improvement after stent treatment over the first year of follow-up. The parameter AUC1 may be a good predictor for renal dysfunction after PTRAS in severe ARAS patients.

Trial Registration: ChiCTR.org.cn, ChiCTR1800016252.

Keywords: Atherosclerotic renal artery stenosis; Percutaneous transluminal renal artery stenting; Contrast-enhanced ultrasound; Renal cortical blood perfusion; Follow-up

Introduction

Renal artery stenosis (RAS) is associated with an increasing risk of ischemic nephropathy. RAS is a primary

disease that involves the large and medium renal arteries.^[1] It is a relatively common condition in aged patients with hypertension, especially those with refractory hypertension, with a prevalence that may be as high as

Access this article online	
Quick Response Code:	Website: www.cmj.org
	DOI: 10.1097/CM9.0000000000002162

Correspondence to: Prof. Junhong Ren, Department of Sonography, Beijing Hospital, National Center of Gerontology, Institute of Geriatric Medicine, Chinese Academy of Medical Science, Beijing 100730, China
E-Mail: renjunhong2002@hotmail.com

Copyright © 2022 The Chinese Medical Association, produced by Wolters Kluwer, Inc. under the CC-BY-NC-ND license. This is an open access article distributed under the terms of the Creative Commons Attribution-Non Commercial-No Derivatives License 4.0 (CCBY-NC-ND), where it is permissible to download and share the work provided it is properly cited. The work cannot be changed in any way or used commercially without permission from the journal.

Chinese Medical Journal 2022;135(13)

Received: 01-11-2021; Online: 20-07-2022 Edited by: Yanjie Yin and Xiuyuan Hao

10%–40%.^[2] RAS is conditioned mainly by fibromuscular dysplasia or atherosclerotic renal artery stenosis (ARAS), which primarily affects patients aged ≥ 45 years and usually involves the aortic artery orifice or the proximal main renal artery (RA).^[3] In most cases of ARAS, which ranged from 53% to 80%, one kidney is affected, with the main artery to the second kidney being essentially normal, and hence the name “unilateral” RAS.^[3] Percutaneous transluminal renal artery stenting (PTRAS) has emerged as the primary revascularization strategy in most patients with hemodynamically significant ARAS. The focus of this treatment has shifted to the prevention of renal failure.^[4,5] Some clinical randomized controlled trials, such as Cardiovascular Outcomes in Renal Atherosclerotic Lesions and Angioplasty and Stent for Renal Artery Lesions, demonstrated that subjects with ARAS had similar outcomes whether randomized to optimal medical therapy alone or optimal medical therapy plus RA stenting. On the other hand, there were other studies demonstrating that the endovascular technique had a beneficial effect on blood pressure and renal function in selected patients, and was a safe technique associated with a high rate of technical success and few complications. Therefore, the beneficial effects of PTRAS are still controversial.

Baseline renal function is proved to be a predictor for prognosis.^[6,7] Several observational clinical studies demonstrated that renal glomerular filtration rate (GFR), assessed by radionuclide renal dynamic imaging, was significantly related to the prognosis after stent therapy. However, radionuclide imaging is associated with radioactivity and high price, and the image clarity is easily affected; so, its deployment is not possible in large-scale and wide applications.^[8] Meanwhile, renal cortical blood perfusion (CBP) evaluated by contrast-enhanced ultrasound (CEUS) is also associated with postoperative renal function.^[9] In addition, CEUS imaging data demonstrated that patients with transplant RAS were associated with significantly longer time of contrast agent inflow in comparison to patients without perfusion disturbances (3.47 s vs. 1.5 s, $P < 0.001$),^[10] and grafts with poor prognosis (acute kidney injury) have a delayed peak intensity (PI), which was significantly lower than that associated with normal kidneys. Therefore, renal CBP parameters can be clearly observed and used as a predictor of prognosis.^[11]

Our previous study showed that among 82 consecutive patients with unilateral severe RAS after stent implantation, CBP parameter area under the curve (AUC) was positively related with the risk of cardio-renal vascular adverse events (including renal function deterioration, permanent renal replacement therapy, RA revascularization, myocardial infarction, heart failure, and death) recorded during 12 months of follow-up (odds ratio [OR] = 2.890, 95% CI: 1.324–6.308).^[5,6,11,12] Although the renal function deterioration is the most common event among adverse cardiorenal events (15%–47%), there are few studies evaluating the relationship between renal CBP and deterioration of renal function. Therefore, this article aimed to evaluate the changes of RA diameter and CBP parameters using CEUS before and after PTRAS in 98 patients with unilateral severe ARAS, and to analyze the relationship between CBP and renal function deterioration.

Methods

Ethical approval

This study was approved by the Ethics Committee of Beijing Hospital (2018BJYYEC-043-02) and has been registered in China Clinical Trial Registration Center (ChiCTR1800016252). Written consents were obtained for both the procedure and data collection in all cases.

Patients

This is a single-center retrospective cohort study. A total of 98 patients with unilateral severe ARAS after successful PTRAS in Beijing Hospital from September 2017 to September 2020 were included. There were 52 males (53.1%), aged 55–74 years, with an average age of 62.1 ± 8.7 years, and an average artery stenosis of $82.3 \pm 12.9\%$.

Inclusion criteria: (1) aged 18–80 years; (2) RAS^[13,14] was diagnosed by digital subtraction angiography (DSA), with unilateral RAS of 70%–99%, and contralateral RAS $< 50\%$; (3) long diameter of the affected kidney > 7 cm; (4) no residual stenosis or a residual stenosis of $< 30\%$ assessed by immediate post-operative DSA examination; (5) with complete 12 months' follow-up data. Exclusion criteria: (1) unstable or severe cardiopulmonary dysfunction; (2) contrast agent allergy; (3) advanced tumors; (4) poor CEUS images.

According to the changes of GFR in the stenotic kidney that were measured by radionuclide dynamic imaging at 12 months' follow-up after PTRAS,^[4,5] the patients were divided into two groups, including the poor prognosis group (with GFR decreased by $\geq 20\%$ compared with baseline) (21 cases) and the control group (with GFR decreased by $< 20\%$ or GFR improved compared with baseline) (77 cases).

Data collection

The patients' baseline characteristics, including age, gender, duration of hypertension and diabetes, and stenotic degree of RA were collected. In addition, routine kidney ultrasound examination parameters, such as kidney size, cortex thickness, and hemodynamic parameters, including the main RA peak systolic velocity (PSV), abdominal PSV, interlobar artery PSV, acceleration time, and resistance index were collected from a prospectively maintained RAS Clinical and Imaging Database designed by Medical Research Statistics Center, Fuwai Hospital. Moreover, the features of RA and CBP at 6 months and 12 months follow-up were also recorded. The GFR of each kidney and the total GFR were determined using ^{99m}Tc-DTPA renal dynamic imaging using Symbia T16 SPECT/CT (Siemens Company, Germany) at baseline and 12 months after PTRAS.

RAS diagnoses and CBP assessment

The current “gold standard” for RAS is DSA and CEUS is used as a first-line screening method for evaluating RAS. The color Doppler ultrasound and CEUS examinations were performed with a CA 1–7A (1–7 MHz) transducer on an RS80 ultrasound instrument (SAMSUNG, Korea).

After routine RA ultrasonography, patients were injected with SonoVue (Sulfur Hexafluoride Microbubbles, Bracco, Milan, Italy) bolus twice into the upper limb vein for each kidney, including the main RA (dose, 1.0 mL/kidney) and renal CBP (dose, 1.2 mL/kidney) examination, followed by 5.0 mL saline for each bolus. First, patients were examined with normal breathing in the lateral position, and dynamic contrast-enhanced RA imaging was stored for 1.0 min from the original site to kidney hilum. The main RA lesion included the position, length, and diameter stenosis ratio. The degree of RAS was calculated as $(1 - [\text{diameter of the stenosis} / \text{diameter of the normal portion distal to the stenosis}]) \times 100\%$ in the artery phase of the enhanced image.^[15,16]

And then the maximum long-axis section of the kidney was fixed to be perpendicular to the acoustic beam direction, and SonoVue was injected again to continuously observe and store the real-time contrast agent perfusion of the renal cortical for 3 min. Ultrasound instrument settings were kept constant during the entire procedure, including the contrast mechanical index MI of 0.08, the image depth of 14 cm, and the gain of 60 dB. The interval between each contrast agent injection was 15 min.

After all the examination procedures, the time-intensity curve of renal cortical regions of interest (ROI) was analyzed using TomTec Imaging Systems (Germany) to determine the parameters of renal cortical microvascular perfusion, including area under ascending curve (AUC1), area under the descending curve (AUC2), rising time (RT), time to peak intensity (TTP), maximum intensity (IMAX, with respect to the IMAX of the reference ROI), and mean transit time (MTT) [Figure 1].

CEUS examination's quality supervision

According to the Chinese expert consensus^[15] on methods and procedures of RA CEUS (2021 Edition), the main RA examination with CEUS was performed in the coronal plane based on the improved lateral position. In addition, when the image was not clear, we would change the

viewing plane several times to observe the RA imaging clearly. Moreover, we also considered the patient's clinical information and the RA hemodynamic indicators measured by conventional ultrasound before making a comprehensive judgment. Experts from the Departments of Sonography (Na Ma, Junhong Ren), Vascular Surgery (Yongjun Li), and Cardiology (Hu Ai) independently determined the RAS diagnoses, and two experienced sonographers (Na Ma, Junhong Ren) reviewed the CBP.

Statistical analyses

Data analysis was performed through STATA 13.0 statistical software (Stata-Corp LP, College Station, TX, USA). Normal distributions of measurement data were expressed as mean and standard deviation; comparison between groups were analyzed by *t* test or one-way analysis of variance; non-normally distributed measurement data were represented by median (interquartile range), and non-parametric tests were used for comparison between groups; countable data were expressed as percentage, and comparisons between groups were detected by the χ^2 -test. The receiver operating characteristic (ROC) curve with AUC was used to analyze the predictive value of CBP parameters (AUC1, AUC2, RT, TTP, IMAX, MTT) for poor prognosis. *P* < 0.05 was considered statistically significant.

Results

Baseline data comparison between the two groups

Among the 98 patients with severe RAS, compared with the control group, the poor prognosis group was associated with significantly increased incidence of diabetes (76.2% vs. 41.6%), and lower levels of GFR of the stenotic kidney (21.8 mL/min vs. 25.0 mL/min) and total GFR (57.6 mL/min vs. 63.7 mL/min) (all *P* < 0.05). There was no significant difference in other general conditions between the two groups, including RA stenosis ratio and the hemodynamics parameters of RAS assessed by color Doppler ultrasound examination (all *P* > 0.05) [Table 1].

Renal artery restenosis after PTRAS

No renal restenosis was found at 6 months after PTRAS. However, at 12 months after discharge, two patients (9.5%) in the poor prognosis group developed restenosis (50%–70% instant restenosis) detected by CEUS. Due to the older age of the patient and ideal control of blood pressure with anti-hypertension drugs, the two patients did not receive repeat PTRAS. There was no case of RA restenosis in the control group. Therefore, the rate of RA restenosis was significantly higher in the poor prognosis group than in the control group (9.5% vs. 0, $\chi^2 = 9.462$, *P* = 0.002).

Renal CBP before and after PTRAS

Compared with the baseline data, patients in the poor prognosis group at 6 months and 12 months of follow-up

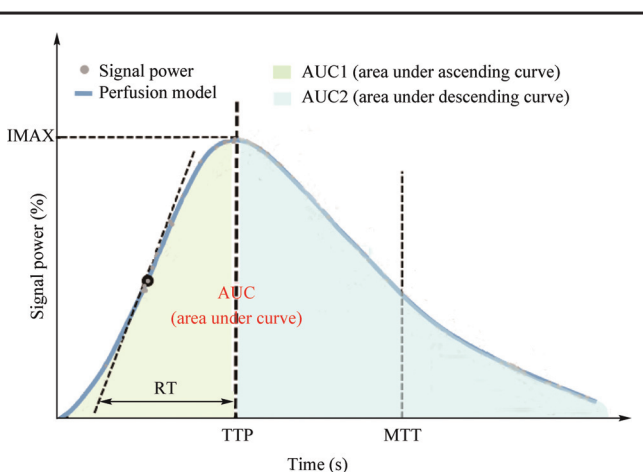


Figure 1: Time-dependent intensity curves based on selected ROI. AUC: Area under the curve; IMAX: Maximum intensity; MTT: Mean transit time; RT: Rising time; ROI: Regions of interest; TTP: Time to peak.

Table 1: Comparison of the baseline data of the patients with unilateral severe ARAS after PTRAS in two groups.

Characteristic	Poor prognosis group (n=21)	Control group (n=77)	t/ χ^2 -value	P value
General conditions				
Age (years)	65.2 ± 7.3	60.4 ± 6.9	3.387	0.001
Male	9 (42.9)	43 (55.8)	1.340	0.247
Hypertension (years)	12.7 ± 9.0	11.6 ± 6.2	0.803	0.423
Diabetes mellitus	16 (76.2)	32 (41.6)	11.063	0.001
Degree of ARAS	83.7 ± 12.9	81.8 ± 9.1	0.951	0.343
Color Doppler ultrasonography				
Main renal artery PSV (cm/s)	341.6 ± 96.7	318.6 ± 74.3	1.443	0.151
AO PSV (cm/s)	68.9 ± 16.3	70.1 ± 10.2	0.517	0.606
Interlobar artery PSV (cm/s)	28.3 ± 12.4	25.7 ± 8.9	1.337	0.183
Acceleration time (ms)	116.5 ± 52.1	99.6 ± 41.1	1.928	0.056
Resistance index	0.63 ± 0.17	0.66 ± 0.11	1.211	0.228
Radionuclide imaging (mL/min)				
GFR of the stenotic kidney	21.8 ± 4.2	25.0 ± 3.7	4.155	<0.001
GFR of the nonstenotic kidney	38.9 ± 8.6	40.7 ± 5.5	1.448	0.150
Total GFR	57.6 ± 8.2	63.7 ± 7.2	2.734	0.007

Data are presented as n (%) or mean ± standard deviation. AO: Abdominal aorta; ARAS: Atherosclerotic renal artery stenosis; GFR: Glomerular filtration rate; PSV: Peak systolic velocity. PTRAS: Percutaneous transluminal renal artery stenting.

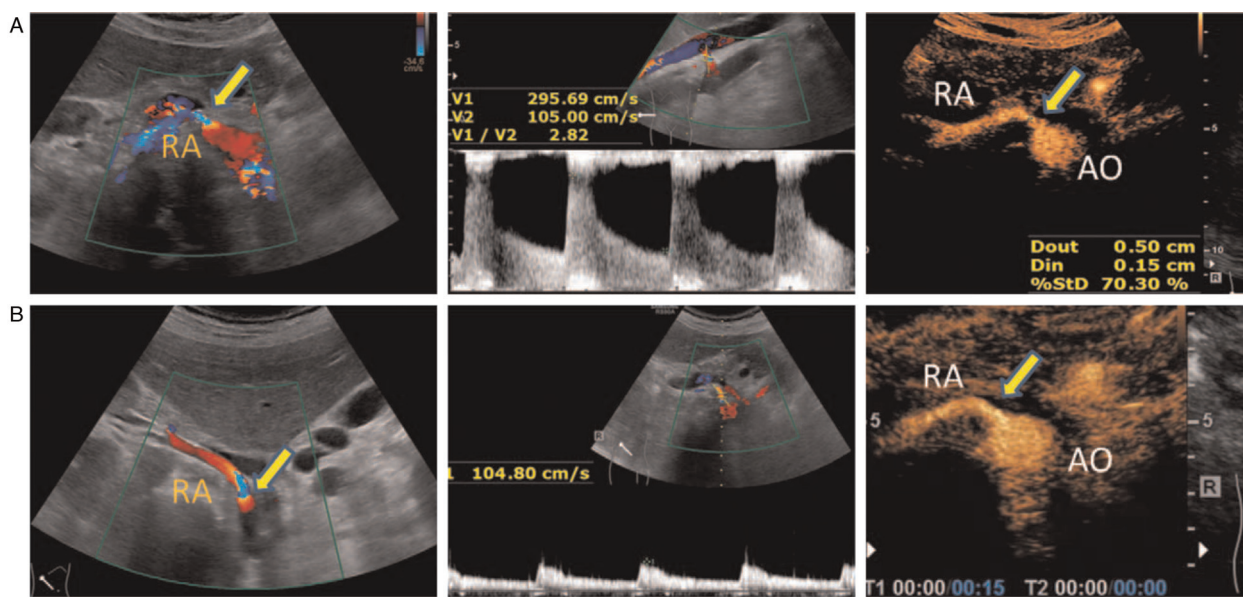


Figure 2: Routine ultrasound and CEUS images of a 65-year-old man with 70% right renal ostial stenosis. (A) Color Doppler flow (left), Doppler frequency spectrum (middle), and CEUS (right) images of the long axis section of right RA before PTRAS. (B) After stent implantation, RA blood flow images (left) and the PSV (middle) of stenosis were corrected; contrast beam filling (right) displayed normally. AO: Abdominal aorta; CEUS: Contrast-enhanced ultrasound; PSV: Peak systolic velocity; PTRAS: Percutaneous transluminal renal artery stenting; RA: Renal artery.

were associated with mildly improved CBP, with significantly increased AUC2. However, other parameters, including AUC1, RT, TTP, IMAX, and MTT, were not significantly improved. In the control group, all CBP parameters were significantly improved, with significantly increased AUC1, AUC2, and IMAX, and decreased duration of RT, TTP, and MTT [Figure 2].

Compared with the control group, the poor prognosis group was associated with significantly decreased baseline CBP, which was characterized by decreased AUC1 and AUC2 and extended duration of TTP and MTT (all

$P < 0.05$). At the follow-up of 6 months and 12 months after stenting, the CBP was further improved, and characterized by markedly increased AUC1, AUC2, and IMAX and shorter duration of RT and MTT (all $P < 0.05$) [Table 2].

Analysis of ROC curve

The AUC of renal CBP parameters AUC1, AUC2, RT, TTP, IMAX, and MTT for predicting poor prognosis were 0.812 (95% CI: 0.698–0.945, $P = 0.007$), 0.752 (95% CI:

Table 2: CBP parameters at baseline and during follow-up monitoring of the patients after PTRAS in two groups.

Parameters	Time	Poor prognosis group (n = 21)	Control group (n = 77)	t/ χ^2 -value	P value
AUC1 (dB × s)	Baseline	61.2 ± 40.3	77.9 ± 30.1	2.567	0.011
	6 months	78.3 ± 35.2	98.9 ± 23.2	3.965	<0.001
	12 months	86.9 ± 32.7	116.5 ± 27.1	5.181	<0.001
	F value	1.941	6.614		
	P value	0.092	<0.001		
AUC2 (dB × s)	Baseline	236.8 ± 144.2	291.2 ± 107.3	2.343	0.020
	6 months	340.2 ± 127.3	433.6 ± 177.4	2.697	0.008
	12 months	362.7 ± 130.5	473.7 ± 122.6	4.403	<0.001
	F value	3.378	11.551		
	P value	0.017	<0.001		
RT (s)	Baseline	7.1 ± 2.4	6.2 ± 2.2	1.916	0.057
	6 months	6.4 ± 3.1	6.0 ± 1.8	2.742	0.007
	12 months	6.2 ± 2.3	5.8 ± 1.4	2.999	0.003
	F value	2.731	12.628		
	P value	0.056	<0.001		
TTP (s)	Baseline	14.0 ± 5.5	11.8 ± 4.6	2.273	0.024
	6 months	12.0 ± 4.7	10.2 ± 4.5	1.952	0.053
	12 months	11.1 ± 4.2	9.1 ± 5.3	1.914	0.057
	F value	2.381	7.773		
	P value	0.075	<0.001		
IMAX (%)	Baseline	780.4 ± 224.1	825.4 ± 224.7	2.598	0.011
	6 months	817.5 ± 167.4	875.3 ± 231.2	2.264	0.025
	12 months	887.2 ± 253.7	1242.7 ± 154.6	2.152	0.033
	F-value	2.335	7.608		
	P-value	0.083	<0.001		
MTT (s)	Baseline	98.8 ± 35.0	82.4 ± 30.2	2.598	0.011
	6 months	87.9 ± 36.3	74.6 ± 27.2	2.264	0.025
	12 months	78.2 ± 33.7	64.5 ± 30.8	2.152	0.033
	F value	2.104	7.608		
	P value	0.079	<0.001		

Data are presented as mean ± standard deviation. AUC: Area under the curve; CBP: Cortical blood perfusion; IMAX: Maximum intensity; MTT: Mean transit time; RT: Rising time; TTP: Time to peak; PTRAS: Percutaneous transluminal renal artery stenting.

0.591–0.957, $P = 0.021$), 0.724 (95% CI: 0.569–0.961, $P = 0.019$), 0.720 (95% CI: 0.522–0.993, $P = 0.045$), 0.693 (95% CI: 0.507–0.947, $P = 0.022$), and 0.786 (95% CI: 0.631–0.979, $P = 0.032$), respectively. The best thresholds were 72.9 dB × S, 252.2 dB × S, 325.7 dB, 11.7 second, 793.4%, and 85.3 seconds. The sensitivities of the indices were 79.2%, 70.4%, 73.7%, 74.6%, 73.3%, and 75.3%, and the specificities were 81.0%, 58.6%, 59.6%, 57.8%, 65.8%, and 64.9%, respectively [Figure 3].

Discussions

In our study, the poor prognosis group was associated with a significantly higher rate of diabetes and lower GFR of the stenotic kidney and total GFR compared with the control group ($P < 0.05$). In addition, the rate of RA restenosis was significantly higher in the poor prognosis group than in the control group (9.5% vs. 0, $\chi^2 = 9.462$, $P = 0.002$). Compared with the control group, the poor prognosis group was associated with significantly decreased baseline CBP, which was characterized by decreased AUC1 and AUC2 and extended duration of TTP and MTT (all $P < 0.05$). At 6 months and 12 months

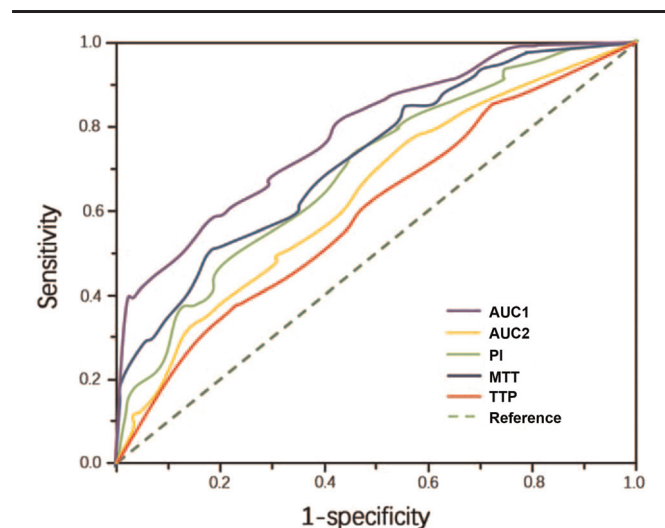


Figure 3: ROC Curve of renal blood perfusion parameters for predicting poor prognosis. MTT: Mean transit time; PI: Peak intensity; ROC: Receiver operating characteristic; TTP: Time to peak.

of follow-up, though the CBP was mildly improved in the poor prognosis group, patients in the control group were associated with further improved renal perfusion, which was characterized by markedly increased AUC1, AUC2, and IMAX, and a shorter duration of RT and MTT (all $P < 0.05$). The ROC curve showed that renal RBP parameters are associated with prognosis.

Some patients with severe RAS experience ischemic nephropathy aggravation after stent implantation, which was manifested as renal function deterioration.^[17] Renal CBP is closely related to renal function. The application of CEUS for studying renal microvascular perfusion has been recently concerned and examined of various kidney diseases. Mahoney *et al*^[18] compared the CBP assessed with CEUS and pathological changes in diabetic nephropathy rat models, and showed that the CBP parameters were significantly correlated with pathological changes. Stock *et al*^[19] studied 14 cats with chronic kidney disease (CKD), and demonstrated that the CPB parameter RT of the renal cortex was prolonged and the RT of the medullary substance was shortened, which was related to the decreased blood flow velocity in capillaries due to the increase of vascular resistance in the renal cortex of CKD. Wang *et al*^[20] revealed high renal CBP in the mild-to-moderate CKD group in elderly diabetic patients, and found that there were significant differences in quantitative perfusion parameters, including AUC, PI, A, and TTP between the mild-to-moderate and severe CKD groups. In addition, they further reported that CBP was reduced in patients with diabetic nephropathy, and that there was a good correlation with the urine protein/creatinine ratio. Kim *et al*^[21] evaluated CBP after renal transplantation using CEUS, and the results showed that there was a good correlation between CBP and the ^{99m}Tc-DTPA scan results. It was also revealed that the preoperative CBP can be used to evaluate the effect of stent implantation in ARAS.

Recently, several studies^[8,22,23] proved that AUC was considered to be a sensitive indicator for early renal function deterioration and the risk of ischemic nephropathy. Patients with renal function deterioration had different RBP characteristics. In a small retrospective study that enrolled 24 severe RAS patients who underwent PTRAS, for 21 patients CBP examination was performed with CEUS, and CBP parameters included PI, TTP, MTT, curve ascending slope (S) and AUC, AUC-wash-in, and AUC-wash-out. Ran *et al*^[8] found that the parameters of PI, TTP, MTT, and S differed significantly between the pre- and post-intervention ($P < 0.05$), and the PI difference was correlated positively with the estimated GFR difference ($r = 0.433$, $P < 0.05$).^[22] In a study of 38 kidneys in 30 ARAS patients who received PTRAS, CBP parameters (AUC and PI) were positively correlated with renal function ($r = 0.617$, 0.663), but weakly and negatively correlated with the stenotic degree ($r = -0.360$, -0.435). Importantly, they found that baseline renal GFR was not accurate in predicting improved renal function after PTRAS, and combined CBP parameters of baseline AUC and PI were a good predictor for renal function.^[23] In another study that involved 93 RAS patients, Pearson correlation analysis showed that the CBP parameters AUC ($r = 0.774$), A ($r = 0.815$), and PI ($r = 0.772$) were positively correlated with renal function, and TTP

($r = -0.803$) and MTT ($r = -0.741$) were negatively correlated with renal function. In our study, we found that compared with the control group, the poor prognosis group was associated with significantly decreased baseline CBP, which was characterized by decreased AUC1 and AUC2 and extended duration of TTP and MTT ($P < 0.05$). At 6 months and 12 months of follow-up, though the CBP was mildly improved in the poor prognosis group, patients in the control group were associated with further improved renal perfusion, which was characterized by markedly increased AUC1, AUC2, and IMAX and shorter duration of RT and MTT ($P < 0.05$). The ROC curve showed that the predictive values of AUC1, AUC2, RT, TTP, IMAX, and MTT for poor prognosis were 0.812, 0.752, 0.724, 0.720, 0.693, and 0.786, respectively. Therefore, RBP parameters are associated with prognosis and could be used as a prognosis predictor.

Clinical and animal studies suggest that multiple mechanisms mediate renal deterioration in ARAS after stent implantation.^[24,25] Studies in patients with mild-to-moderate RAS demonstrate that, despite a moderate reduction in RA perfusion pressure (up to 40%) and in renal blood flow (mean 30%), glomerular filtration was reduced but tissue oxygenation within the kidney cortex and medulla can adapt without the development of severe hypoxia. However, more severe vascular occlusion, with a 70%–80% narrowing of the RA, leads to evident renal cortical hypoxia.^[26] In animal studies, tissue hypoxia produces rarefaction of renal parenchymal microvessels, as well as activation of inflammatory and oxidative pathways, which lead to interstitial fibrosis.^[27] Several studies suggest that inflammatory markers, such as neutrophil-gelatinase-associated lipocalin and monocyte-chemoattractant protein-1, which are sampled from the renal veins of stenotic kidneys, are correlated strongly with the degree of hypoxia assessed by blood oxygenation level dependent magnetic resonance imaging, particularly those after stent implantation.^[28,29] Inflammatory changes and fibrosis are also demonstrable in human “pressor” kidneys that were removed to treat hypertension in patients with a totally occluded RA. Meanwhile, atherosclerosis modulates the impact of a stenosis in the RA on stenotic kidney hemodynamics, function, and tubular dynamics. In an study that enrolled unilateral RAS in domestic pigs (4 in normal group, 26 in RAS group, and 22 in ARAS group), Urbietta-Caceres *et al*^[25] found that stenotic single-kidney volume, blood flow, GFR, and CBP were lower than normal in both RAS and ARAS groups, but only in RAS correlated inversely with an increasing degree of stenosis. In addition, basal tubular fluid concentration capacity and CBP response to Ach were both blunted only in ARAS. Finally, long-standing parenchymal inflammation and fibrosis eventually becomes an irreversible injury.^[30] At some point, restoring renal blood flow with stent implantation provides no recovery of kidney function and/or clinical benefit.

Limitations

This study had some limitations. (1) This study was a single-center cohort with a small sample. (2) All patients included in our study had atherosclerotic RAS,^[31] and

those with a non-atherosclerotic reason underlying RAS, such as Takayasu's arteritis, fibromuscular dysplasia, and embolism may have different characteristics, as well as a difference in prognosis and its related factors. (3) Patients enrolled were often middle-aged and elderly and had several atherosclerotic related factors. Therefore, those younger patients with few atherosclerotic related factors may have different related factors for renal function deterioration. (4) In clinic, $>1/2$ moderate-to-severe RAS patients had bilateral lesions and both kidneys were related with prognosis.^[32] However, patients included in our study had unilateral RAS.^[33](5) In addition, longer follow-up data are needed to evaluate the prognosis.

Conclusions

In conclusion, preoperative CBP in severe ARAS patients with poor prognosis is significantly reduced, and do not be improved significantly after stent treatment over the first year of follow-up. The parameter AUC1 may be a good predictor for renal dysfunction after PTRAS in severe ARAS patients.

Funding

This study was supported by grants from the National High Level Hospital Clinical Research Funding (No. BJ-2018-198), Basic Research Project of the Central Academy of Medical Sciences of China (No. 2019PT320012), Beijing Science and Technology Project (No. Z211100002921011), and National Key R&D Program of China (No. 2020YFC2008100).

Conflicts of interest

None.

References

- Mishima E, Suzuki T, Ito S. Selection of patients for angioplasty for treatment of atherosclerotic renovascular disease: predicting responsive patients. *Am J Hypertens* 2020;33:391–401. doi: 10.1093/ajh/hpaa016.
- Investigator ASTRAL, Wheatley K, Ives N, Gray R, Kalra PA, Moss JG, *et al.* Revascularization versus medical therapy for renal-artery stenosis. *N Engl J Med* 2009;361:1953–1962. doi: 10.1056/NEJMoa0905368.
- Cooper CJ, Murphy TP, Cutlip DE, Jamerson K, Henrich W, Reid DM, *et al.* Stenting and medical therapy for atherosclerotic renal-artery stenosis. *N Engl J Med* 2014;370:13–22. doi: 10.1056/NEJMoa1310753.
- Tirtayasa PMW, Duarsa GWK, Situmorang GR, Yudianta IW, Santosa KB, Oka AAG, *et al.* Association between early resistive index measurement and early graft function and long-term graft survival after kidney transplantation: an evidence-based clinical review. *Acta Med Indones* 2019;51:77–85.
- Zhou Q, Yu Y, Qin W, Pu Y, Hu S, Tang M, *et al.* Current status of ultrasound in acute rejection after renal transplantation: a review with a focus on contrast-enhanced ultrasound. *Ann Transplant* 2021;26:e929729. doi: 10.12659/AOT.929729.
- Chrysochou C, Green D, Ritchie J, Buckley DL, Kalra PA. Kidney volume to GFR ratio predicts functional improvement after revascularization in atheromatous renal artery stenosis. *PLoS One* 2017;12:e0177178. doi: 10.1371/journal.pone.0177178.
- Feng QC, Li X, Luan JY, Wang CM, Li TR. Significance of renal filtration fraction evaluation of renal artery stenting for atherosclerotic renal artery stenosis treatment. *Beijing Da Xue Xue Bao Yi Xue Ban* 2017;49:158–163. doi: 10.3969/j.issn.1671-167X.2017.01.029.
- Ran X, Lin L, Yang M, Niu G, Chen L, Shao Y, *et al.* Contrast-enhanced ultrasound evaluation of renal blood perfusion changes after percutaneous transluminal renal angioplasty and stenting for severe atherosclerotic renal artery stenosis. *Ultrasound Med Biol* 2020;46:1872–1879. doi: 10.1016/j.ultrasmedbio.2020.04.006.
- Grzelak P, Kurnatowska I, Nowicki M, Muras K, Podgórski M, Strzelczyk J, *et al.* Detection of transplant renal artery stenosis in the early postoperative period with analysis of parenchymal perfusion with ultrasound contrast agent. *Ann Transplant* 2013;18:187–194. doi: 10.12659/AOT.883896.
- Álvarez Rodríguez S, Hevia Palacios V, Sanz Mayayo E, Gómez Dos Santos V, Díez Nicolás V, Sánchez Gallego MD, *et al.* The usefulness of contrast-enhanced ultrasound in the assessment of early kidney transplant function and complications. *Diagnostics (Basel)* 2017;7:53. doi: 10.3390/diagnostics7030053.
- Guo FJ, Ma N, Zhang YW, Wang SY, Sun YJ, Li MP, *et al.* Changes of CBP before and after treatment of severe renal artery stenosis and its risk factors for short-term prognosis. *Chin J Cardiol* 2021;26:159–164. doi: 10.3969/j.issn.1007-5410.2022.02.013.
- Sun YJ, Wang SY, Ma N, Guo FJ, Li MP, Ai H, *et al.* An observational study of the effect of baseline renal CBP with contrast-enhanced ultrasound on short-term outcomes of stent implantation for severe renal artery stenosis. *Chin J Ultrasonogr* 2021;30:944–949. doi: 10.3760/cma.j.cn131148-20210430-00301.
- Rundback JH, Sacks D, Kent KC, Cooper C, Jones D, Murphy T, *et al.* Guidelines for the reporting of renal artery revascularization in clinical trials. *Circulation* 2002;106:1572–1585. doi: 10.1097/01.rvi.0000094621.61428.d5.
- Jiang XJ, Zou YB. Chinese expert consensus for the diagnosis and management of renal artery stenosis. *Chin Circ J* 2017;32:835–844. doi: 10.3969/j.issn.1000-3614.2017.09.002.
- Ultrasound Branch of Chinese Medical Doctor, Association National Center of Gerontology. Chinese expert consensus on methods and procedures of renal artery contrast-enhanced ultrasound (2021 Edition). *Chin J Ultrasonogr* 2021;30:921–926. doi: 10.3760/cma.j.cn131148-20210827-00605.
- Ren JH, Ma N, Wang SY, Sun YJ, Zhang YW, Guo FJ, *et al.* Rationale and study design for one-stop assessment of renal artery stenosis and renal microvascular perfusion with contrast-enhanced ultrasound for patients with suspected renovascular hypertension. *Chin Med J* 2019;132:63–68. doi: 10.1097/CM9.0000000000000002.
- Ren JH. Standardized thought of examination and operation with contrast-enhanced ultrasound for diagnosis of renal artery stenosis. *Chin J Cardiol* 2020;100:1281–1283. doi: 10.3760/cma.j.cn112137-20200302-00561.
- Mahoney M, Sorace A, Warram J, Samuel S, Hoyt K. Volumetric contrast-enhanced ultrasound imaging of renal perfusion. *J Ultrasound Med* 2014;33:1427–1437. doi: 10.7863/ultra.33.8.1427.
- Stock E, Paepe D, Daminet S, Vandermeulen E, Duchateau L, Saunders JH, *et al.* Contrast-enhanced ultrasound examination for the assessment of renal perfusion in cats with chronic kidney disease. *J Vet Intern Med* 2018;32:260–266. doi: 10.1111/jvim.14869.
- Wang L, Wu J, Cheng JF, Liu XY, Ma F, Guo LH, *et al.* Diagnostic value of quantitative contrast-enhanced ultrasound (CEUS) for early detection of renal hyperperfusion in diabetic kidney disease. *J Nephrol* 2015;28:669–678. doi: 10.1007/s40620-015-0183-3.
- Kim JH, Eun HW, Lee HJ, Goo DE, Choi DL. Clinical use of renal perfusion imaging by means of harmonic sonography with a microbubble contrast agent in patients after renal transplantation: preliminary study. *J Ultrasound Med* 2005;24:755–762. doi: 10.7863/jum.2005.24.6.755.
- Wang X, Wang S, Pang YP, Jiang T, Yu C, Li Y, *et al.* Contrast-enhanced ultrasound assessment of renal parenchymal perfusion in patients with atherosclerotic renal artery stenosis to predict renal function improvement after revascularization. *Int J Gen Med* 2020;13:1713–1721. doi: 10.2147/IJGM.S293316.
- Ma N, Sun YJ, Ren JH, Wang SY, Zhang YW, Ji XP, *et al.* Characteristics of renal cortical perfusion and its association with renal function among elderly patients with renal artery stenosis.

- Chin J Cardiol 2019;47:628–633. doi: 10.3760/cma.j.issn.0253-3758.2019.08.007.
24. Herrmann SMS, Saad A, Eirin A, Woollard J, Tang H, McKusick MA, *et al.* Differences in GFR and tissue oxygenation, and interactions between stenotic and contralateral kidneys in unilateral atherosclerotic renovascular disease. *Clin J Am Soc Nephrol* 2016;11:458–469. doi: 10.2215/CJN.03620415.
 25. Urbieto-Caceres VH, Lavi R, Zhu XY, Crane JA, Textor SC, Lerman A, *et al.* Early atherosclerosis aggravates the effect of renal artery stenosis on the swine kidney. *Am J Physiol Renal Physiol* 2010;299:F135–F140. doi: 10.1152/ajprenal.00159.2010.
 26. Abumoawad A, Saad A, Ferguson CM, Eirin A, Woollard JR, Herrmann SM, *et al.* Tissue hypoxia, inflammation, and loss of glomerular filtration rate in human atherosclerotic renovascular disease. *Kidney Int* 2019;95:948–957. doi: 10.1016/j.kint.2018.11.039.
 27. Keddis MT, Garovic VD, Bailey KR, Wood CM, Raissian Y, Grande JP. Ischaemic nephropathy secondary to atherosclerotic renal artery stenosis: clinical and histopathological correlates. *Nephrol Dial Transplant* 2010;25:3615–3622. doi: 10.1093/ndt/gfq269.
 28. Saad A, Herrmann SMS, Crane J, Glockner JF, McKusick MA, Misra S, *et al.* Stent revascularization restores cortical blood flow and reverses tissue hypoxia in atherosclerotic renal artery stenosis but fails to reverse inflammatory pathways or glomerular filtration rate. *Circ Cardiovasc Interv* 2013;6:428–435. doi: 10.1161/circinterventions.113.000219.
 29. de Bhailís ÁM, Chrysochou C, Kalra PA. Inflammation and oxidative damage in ischaemic renal disease. *Antioxidants (Basel)* 2021;10:845. doi: 10.3390/antiox10060845.
 30. Ferguson CM, Farahani RA, Zhu XY, Tang H, Jordan KL, Saadiq IM, *et al.* Mesenchymal stem/stromal cell-derived extracellular vesicles elicit better preservation of the intra-renal microvasculature than renal revascularization in pigs with renovascular disease. *Cells* 2021;10:763. doi: 10.3390/cells10040763.
 31. Colbert GB, Abra G, Lerma EV. Update and review of renal artery stenosis. *Dis Mon* 2021;67:101118. doi: 10.1016/j.disamonth.2020.101118.
 32. Dobrek L. An outline of renal artery stenosis pathophysiology—a narrative review. *Life (Basel)* 2021;11:208. doi: 10.3390/life11030208.
 33. Manaktala R, Tafur-Soto JD, White CJ. Renal artery stenosis in the patient with hypertension: prevalence, impact and management. *Integr Blood Press Control* 2020;13:71–82. doi: 10.2147/ibpc.S248579.
-
- How to cite this article:** Ma N, Li Y, Wang S, Li M, Li Y, Ai H, Zhu H, Wang Y, Guo F, Ren J. Dynamic changes of renal cortical blood perfusion before and after percutaneous transluminal renal artery stenting in patients with severe atherosclerotic renal artery stenosis. *Chin Med J* 2022;135:1570–1577. doi: 10.1097/CM9.0000000000002162