



Contents lists available at ScienceDirect

## International Journal of Surgery Case Reports

journal homepage: [www.casereports.com](http://www.casereports.com)

# The colovesical fistula in diverticular disease: Laparoscopic approach in two different cases

Giuseppe Di Buono\*, Giulia Bonventre, Salvatore Buscemi, Brenda Randisi, Giorgio Romano, Antonino Agrusa

Department of Surgical, Oncological and Oral Sciences, Section of General and Urgent Surgery, University of Palermo, Italy

## ARTICLE INFO

### Article history:

Received 4 July 2020

Received in revised form 6 September 2020

Accepted 6 September 2020

Available online 11 September 2020

### Keywords:

Colovesical fistula

Laparoscopy

Complicated diverticulitis

Laparoscopic sutures

Surgical skills

Laparoscopic colorectal resection

## ABSTRACT

**INTRODUCTION:** The colovesical fistula is one of the complications of diverticular disease. It can cause significant symptoms like pneumaturia and fecaluria affecting the quality of life and sometimes leading to death, usually secondary to sepsis. We describe two cases of colovesical fistula treated by laparoscopic approach in patients with diagnosis of complicated acute diverticulitis.

**CASE REPORT:** We studied two patients with clinical, radiological and endoscopic diagnosis of colovesical fistula as a consequence of diverticular disease. We performed a totally laparoscopic treatment with colonic resection and colo-proctoanastomosis after the closure of the fistula with intracorporeal sutures.

**DISCUSSION:** Colovesical fistula should be suspected in patients who present fever with persistent dysuria, pneumaturia or fecaluria. The diagnosis is confirmed by a CT abdominal scan, a colonoscopy in order to rule out a colon cancer and a cystoscopy to assess the grade of bladder involvement.

**CONCLUSION:** Although colovesical fistulas caused by diverticular disease were once considered a contraindication to laparoscopic resection, nowadays they are increasingly treated by experienced surgeons using laparoscopic techniques. Compared with laparoscopic surgery for uncomplicated diverticulitis the mini-invasive treatment of colovesical fistulas requires a longer operative time and advanced surgical skills.

© 2020 The Author(s). Published by Elsevier Ltd on behalf of IJS Publishing Group Ltd. This is an open access article under the CC BY-NC-ND license (<http://creativecommons.org/licenses/by-nc-nd/4.0/>).

## 1. Introduction

Approximately 25% of patients with acute diverticulitis or persistent chronic diverticular inflammation have consensual complications as bowel obstruction because of a colonic stricture, development of abdominal and/or pelvic abscesses, a colonic free perforation with consequent peritonitis and fistulas [1]. Fistula formation is present in 17–27% of surgically treated cases of diverticular disease and the colovesical one is found in 3–4% of these patients. So it should be suspected in patients with diverticular disease who present symptoms like pneumaturia or fecaluria often with fever and lower abdominal pain [2]. Radiological findings, colonoscopy and cystoscopy can supports the diagnosis confirmed during surgical procedure [3,4]. We describe two patients with clinical evidences of pneumaturia and fecaluria as a consequence of

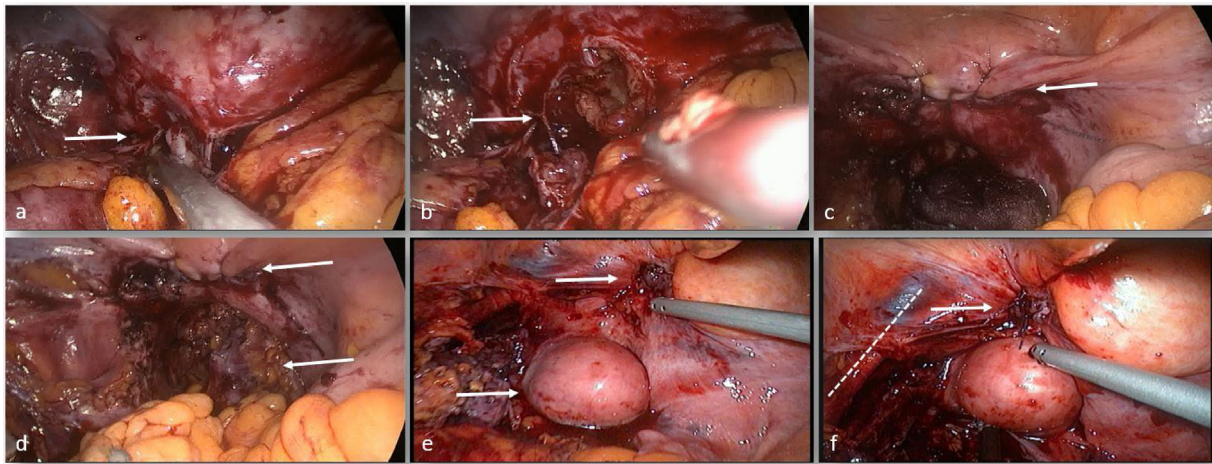
a complicated diverticular disease confirmed with CT abdominal scan and colonoscopy and totally managed with laparoscopic technique with identification, colonic resection and bladder repair in line with the SCARE criteria [5].

## 2. Presentation of cases

We studied two patients with clinical, radiological and endoscopic diagnosis of colovesical fistula as a consequence of complicated diverticular disease. The first patient was a 79-years old male (BMI 28.4 kg/m<sup>2</sup>) who suffered from hypertension, chronic obstructive pulmonary disease. He had had an acute myocardial infarction 10 years earlier. He arrived to our observation in elective setting after three month of gravative abdominal pain in left flank and in suprapubic region. In the last two week he refered fever with turbid and foul-smelling urine with contemporary emission of air. White blood cell count was  $13 \times 10^3/\text{mmc}$ . We performed a CT abdominal scan that showed sigmoid colon with thickened walls and with no cleavage planes from bladder. Colonoscopy confirmed a picture of severe chronic diverticulitis with strong suspicion of colovesical fistula. Cystoscopy demonstrated the fistulous orifice in bladder dome and urinoculture revealed infection from *Klebsiella* spp. The second patient was a 76-years old female (BMI 27.3

\* Corresponding author at: Department of Surgical, Oncological and Oral Sciences (Di.Chir.On.S.), University of Palermo, Via L. Giuffrè, 5, 90127, Palermo, Italy.

E-mail addresses: [giuseppe.dibuono@unipa.it](mailto:giuseppe.dibuono@unipa.it) (G. Di Buono), [giulia.bonv@gmail.com](mailto:giulia.bonv@gmail.com) (G. Bonventre), [buscemi.salvatore@gmail.com](mailto:buscemi.salvatore@gmail.com) (S. Buscemi), [brenda.randisi91@gmail.com](mailto:brenda.randisi91@gmail.com) (B. Randisi), [giorgio.romano@unipa.it](mailto:giorgio.romano@unipa.it) (G. Romano), [antonino.agrusa@unipa.it](mailto:antonino.agrusa@unipa.it) (A. Agrusa).



**Fig. 1.** Intraoperative findings of colovesical fistulas: a-b) male patient with a wide colovesical fistula (arrows); we performed a blunt dissection in order to avoid vascular or visceral injuries; c) double line adsorbable barbed suture; d) complete view of the bladder suture and colonic anastomosis (arrows); e) female patient with subcentimetric fistula and its position respect to uterus (arrows); f) course of the hypogastric vessels (dotted line).

kg/m<sup>2</sup>) with hypertension who went to emergency room with an acute abdominal pain in suprapubic region with no diarrhea or fever. The patient referred recurrent cystitis in the last six months unresponsive to antibiotic therapy and pneumaturia. White blood cell count was  $16 \times 10^3$ /mmc. Also in this case we performed a CT abdominal scan with findings of sigmoid diverticulitis with no abscess or perforation. The urologist carried out a cystoscopy that highlighted a colovesical fistula and urinculture identified *E. coli*. None of these patients had previous abdominal surgery and there were no contraindications to laparoscopic surgery. On the basis of these preoperative clinical and instrumental findings we decided to perform a laparoscopic approach for both cases in elective setting with conversion to open surgery in case of severe pelvic inflammatory syndrome and risk for visceral and/or vascular injuries (e.g. ureter, iliac vessels, small bowel, vaginal dome). The procedures were performed by a senior resident with an experienced team in laparoscopic surgery. We decided to perform a laparoscopic approach for both cases. The procedures were performed by a senior resident with an experienced team in laparoscopic surgery. We induced pneumoperitoneum by Veress needle [6] and a 10-mm optical trocar was placed in the right para-umbilical region. We placed other three trocars respectively in the right hypochondrium (5 mm), in the right iliac fossa (12 mm) and in the left flank (5 mm) [7]. On laparoscopic exploration of abdominal cavity the sigmoid colon appeared convoluted and with thickened wall firmly attached to the bladder dome configuring a picture of severe diverticular inflammation (Fig. 1). We chose a medial to lateral dissection with isolation of mesenteric inferior vein and artery and then we mobilized the left colon up to the splenic flexure. After identification and preservation of the left ureter under the Gerota fascia, we detached the strict adhesions between the sigmoid colon and the bladder [8]. During these maneuvers we identified the colovesical fistula and a bladder double layer suture with intracorporeal knotting was performed. In the male patient we found a wider fistula with need for resection of the bladder dome in order to obtain an undamaged margin. In the other case, we saw a subcentimetric fistula for whom it was not appropriate to carry out the resection but only the suture in double layer [9]. In both cases we tested laparoscopic suture with bladder filling with indocyanine green that demonstrated no vesical dye spillage. At the end of this procedure we completed the left hemicolectomy performing a mechanical colo-proctoanastomosis. The patients were satisfied with the treatment received with typical advantages of laparoscopic surgery with rapid postoperative

recovery, earlier food intake and less postoperative pain. The postoperative course was uneventful and both patients were discharged on POD 7.

### 3. Discussion

Diverticular disease in Western countries usually involves the sigmoid colon and fistulas most frequently arise from this segment. The most common types of fistulas are colovesical fistulas (65%) and colovaginal fistulas (25%), followed by coloenteric (7%), colouterine (3%), colocutaneous fistulas and complex fistulas with involvement of multiple pelvic organs (10%) [10]. Although diverticulitis occurs with a slight female predominance colovesical fistulas secondary to diverticulitis have a distinct (2 to 3:1) male predominance because the uterus preserves the bladder from the inflamed sigmoid colon. Patients typically present laboratory findings of leukocytosis in association with urinary symptoms including dysuria or recurrent urinary tract infections often cause of fever (100%), pneumaturia (71%) and fecaluria (51%). Other symptoms occurring in fewer than 50% of patients are chronic abdominal pain, diarrhea, hematuria and loss of urine via rectum [11,12]. On CT abdominal scan we can find suggestive features of acute diverticulitis including the presence of localized bowel wall thickening (>4 mm), an increase in soft tissue density within the pericolonic fat secondary to inflammation and the presence of colonic diverticula. The sensitivity and specificity of CT scan for the diagnosis of acute diverticulitis are respectively 94 and 99%. The integration with colonoscopy, cystoscopy or intravenous urography (IVU) is fundamental to preoperatively confirm the diagnosis of colovesical fistula even if nowadays there is not a gold standard test [13,14]. Regarding the operative technique, laparoscopic left colonic resection does not provide difficult maneuvers for experienced surgical team, but the presence of a colovesical fistula or other complex fistulas [15] significantly increases the technical challenge of the procedure and consequently these operations should be performed by a skilled surgeon in advanced laparoscopic surgery [16–20]. Surgical treatment of colovesical fistulas provides the identification and dissection of the fistula, resection of the involved colon and bladder repair [21,22]. An incomplete colonic resection or a simple division of the colovesical fistula without colonic resection will lead to higher recurrence rates. The presence of a diverticular colovesical fistula is rarely an indication for urgent surgical procedure (2%). An elective one-stage proce-

ture with primary resection and anastomosis (PRA) is safe and feasible in the most of cases (84%) [23–25]. The one-stage procedure is associated with decreased morbidity and length of hospital stay.

#### 4. Conclusion

The diagnosis and treatment of a colovesical fistula requires multidisciplinary involvement with the radiologist, endoscopist, urologist and surgeon. Treatment requires colonic resection and closure of the fistula in order to reduce the recurrence rate. Laparoscopic left colonic or sigmoid resection does not provide difficult maneuvers for experienced surgical team, but the presence of a colovesical fistula or other complex fistulas significantly increases the technical challenge of the procedure and consequently these procedures should be performed by a skilled surgeon in advanced laparoscopic surgery.

#### Declaration of Competing Interest

The authors report no declarations of interest.

#### Funding

Di Buono Giuseppe and other co-authors have no study sponsor.

#### Ethical approval

Ethical Approval was not necessary for this study.  
We obtained written patient consent to publication.

#### Consent

Written informed consent was obtained from the patient for publication of this case report and accompanying images. A copy of the written consent is available for review by the Editor-in-Chief of this journal on request.

#### Author contribution

Di Buono Giuseppe: study design, data collections, data analysis and writing.

Bonventre Giulia: study design, data collections, data analysis and writing.

Buscemi Salvatore: data collections.

Randisi Brenda: data collection.

Romano Giorgio: study design, data collections, data analysis and writing.

Agrusa Antonino: study design, data collections, data analysis and writing.

#### Registration of research studies

Not applicable.

#### Guarantor

Di Buono Giuseppe.  
Agrusa Antonino.

#### Provenance and peer review

Not commissioned, externally peer-reviewed.

#### Availability of data and materials

The datasets used and/or analysed during the current study are available from the corresponding author on reasonable request.

#### Acknowledgements

This article is part of a supplement entitled Case reports from Italian young surgeons, published with support from the Department of Surgical, Oncological and Oral Sciences – University of Palermo.

#### References

- [1] Akbar N. Ashrafi, Rene Sotelo, Colovesical fistulas, *N. Engl. J. Med.* 380 (June (26)) (2019) e51, <http://dx.doi.org/10.1056/NEJMicm1900267>.
- [2] G. Garcea, I. Majid, C.D. Sutton, C.J. Pattenden, W.M. Thomas, Diagnosis and management of colovesical fistulae; six-year experience of 90 consecutive cases, *Colorectal Dis.* 8 (May (4)) (2006) 347–352, <http://dx.doi.org/10.1111/j.1463-1318.2005.00928.x>.
- [3] S. Melchior, D. Cudovic, J. Jones, et al., Diagnosis and surgical management of colovesical fistulas due to sigmoid diverticulitis, *J. Urol.* 182 (September (3)) (2009) 978–982, <http://dx.doi.org/10.1016/j.juro.2009.05.022>, Epub 2009 Jul 18.
- [4] P.D. Morrison, N.V. Addison, A study of colovesical fistulae in a district hospital, *Ann. R. Coll. Surg. Engl.* 65 (1983) 221.
- [5] R.A. Agha, M.R. Borrelli, R. Farwana, K. Koshy, A. Fowler, D.P. Orgill, For the SCARE Group, The SCARE 2018 statement: updating consensus surgical CAse report (SCARE) guidelines, *Int. J. Surg.* 60 (2018) 132–136.
- [6] G. Di Buono, S. Buscemi, A.I. Lo Monte, G. Geraci, V. Sorce, R. Citarrella, E. Gulotta, V.D. Palumbo, S. Fazzotta, L. Gulotta, D. Albano, M. Galia, G. Romano, A. Agrusa, Laparoscopic adrenalectomy: preoperative data, surgical technique and clinical outcomes, *BMC Surg.* 18 (April (Suppl. 1)) (2019) 128, <http://dx.doi.org/10.1186/s12893-018-0456-6>.
- [7] A. Agrusa, G. Frazzetta, D. Chianetta, S. Di Giovanni, L. Gulotta, G. Di Buono, V. Sorce, G. Romano, G. Gulotta, “Relaparoscopic” management of surgical complications: the experience of an Emergency Center, *Surg. Endosc.* 30 (2016) 2804–2810.
- [8] A. Agrusa, G. Di Buono, S. Buscemi, G. Cucinella, G. Romano, G. Gulotta, 3D laparoscopic surgery: a prospective clinical trial, *Oncotarget* 9 (April (25)) (2018) 17325–17333, <http://dx.doi.org/10.18632/oncotarget.24669>, eCollection 2018 Apr 3.
- [9] C.H. Yang, K.H. Liu, T.C. Chen, et al., Enterovesical fistula caused by a bladder squamous cell carcinoma, *World J. Gastroenterol.* 15 (2009) 4215.
- [10] C.C. Carson, R.S. Malek, W.H. Remine, Urologic aspects of vesicoenteric fistulas, *J. Urol.* 119 (1978) 744.
- [11] J.D. Labs, M.G. Sarr, E.K. Fishman, et al., Complications of acute diverticulitis of the colon: improved early diagnosis with computerized tomography, *Am. J. Surg.* 155 (1988) 331.
- [12] D.J. Holroyd, S. Banerjee, M. Beavan, et al., Colovaginal and colovesical fistulae: the diagnostic paradigm, *Tech. Coloproctol.* 16 (2012) 119.
- [13] R.J. Woods, I.C. Lavery, V.W. Fazio, et al., Internal fistulas in diverticular disease, *Dis. Colon Rectum* 31 (1988) 591.
- [14] G. Bonventre, G. Di Buono, S. Buscemi, G. Romano, A. Agrusa, Laparoscopic management of cholecystocolonic fistula: a case report and a brief literature review, *Int. J. Surg. Case Rep.* 68 (2020) 218–220, <http://dx.doi.org/10.1016/j.ijscr.2020.02.052>, Epub 2020 Feb 28.
- [15] I.R. Daniels, B. Bekdash, H.J. Scott, et al., Diagnostic lessons learnt from a series of enterovesical fistulae, *Colorectal Dis.* 4 (2002) 459.
- [16] A. Agrusa, G. Romano, G. Navarra, G. Conzo, G. Pantuso, G.D. Buono, R. Citarrella, M. Galia, A.L. Monte, G. Cucinella, G. Gulotta, Innovation in endocrine surgery: robotic versus laparoscopic adrenalectomy. Meta-analysis and systematic literature review, *Oncotarget* 8 (October (60)) (2017) 102392–102400, <http://dx.doi.org/10.18632/oncotarget.22059>, eCollection 2017 Nov 24.
- [17] G. Cucinella, A. Perino, G. Romano, G. Di Buono, G. Calagna, V. Sorce, L. Gulotta, M. Triolo, V. Billone, G. Gulotta, A. Agrusa, Endometrial cancer: robotic versus laparoscopic treatment. Preliminary report, *GIOG* 37 (November–December (6)) (2015), 283–273.
- [18] A. Agrusa, G. Romano, L.J. Dominguez, G. Amato, R. Citarrella, L. Vernuccio, G. Di Buono, V. Sorce, L. Gulotta, M. Galia, P. Mansueto, G. Gulotta, Adrenal cavernous hemangioma: which correct decision making process? *Acta Med. Mediterranea* 32 (2016) 385–389.
- [19] G. Cucinella, G. Calagna, G. Romano, G. Di Buono, G. Gugliotta, S. Saitta, G. Adile, M. Manzone, G. Accardi, A. Perino, A. Agrusa, Robotic versus laparoscopic sacrocolpopexy for apical prolapse: a case-control study, *G Chir.* 37 (May–June (3)) (2016) 113–117.
- [20] E. Menenakos, D. Hahnloser, K. Nassiopoulou, et al., Laparoscopic surgery for fistulas that complicate diverticular disease, *Langenbecks Arch. Surg.* 388 (2003) 189.
- [21] S.F. Najjar, M.K. Jamal, J.F. Savas, T.A. Miller, The spectrum of colovesical fistula and diagnostic paradigm, *Am. J. Surg.* 188 (2004) 617.

- [22] M.H. Solkar, M.J. Forshaw, D. Sankararajah, et al., Colovesical fistula—is a surgical approach always justified? *Colorectal Dis.* 7 (2005) 467.
- [23] H.M. El-Haddad, M.I. Kassem, A.A. Sabry, A. Abouelfotouh, Surgical protocol and outcome for sigmoidovesical fistula secondary to diverticular disease of the left colon: a retrospective cohort study, *Int. J. Surg.* 56 (2018) 115.
- [24] S.C. Dolejs, A.J. Penning, M.J. Guzman, et al., Perioperative management of patients with colovesical fistula, *J. Gastrointest. Surg.* 23 (2019) 1867.
- [25] R.M. Smeenk, P.W. Plaisier, J.A. van der Hoeven, W.L. Hesp, Outcome of surgery for colovesical and colovaginal fistulas of diverticular origin in 40 patients, *J. Gastrointest. Surg.* 16 (2012) 1559.

#### Open Access

This article is published Open Access at [sciencedirect.com](https://www.sciencedirect.com). It is distributed under the [IJSCR Supplemental terms and conditions](#), which permits unrestricted non commercial use, distribution, and reproduction in any medium, provided the original authors and source are credited.