

Traumatic female urethral avulsion

Walid A. Al-Asbahi, MSc, MD.

ABSTRACT

يعتبر تمزق احليل مجرى البول في الإناث حالة نادرة الحدوث خصوصاً في غياب كسور عظيمة الحوض، مع عدم وجود آلية واضحة للتعامل مع مثل هذه الحالات. نستعرض في هذا التقرير حالة لتهتك شديد في الجدار الأمامي للمهبل مع انفصال كلي للإحليل لسيدة 35 من العمر و حامل في الشهر السادس، ناتج عن سقوط مع ارتطام علي حجر حاد لمنطقة العانة. وقد اجري لها عملية إصلاح فوري بعد الحادث مباشرة لوقف النزيف و إصلاح للإحليل عن طريق المثاغره و إصلاح لجدار المهبل.

Traumatic female urethral avulsion in the absence of a pelvic fracture is an exceedingly rare entity, with no consensus on its management. Here, we present a 35-year-old pregnant woman with severe anterior vaginal wall laceration and complete urethral avulsion secondary to straddle injury. Management consisted of primary urethral and vaginal repair.

Saudi Med J 2015; Vol. 36 (3): 366-367
doi: 10.15537/smj.2015.3.10399

From the Urology and Nephrology Center, Al-Thawra Modern General and Teaching Hospital, Faculty of Medicine and Health Sciences, Sana'a University, Sana'a, Yemen.

Received 30th September 2014. Accepted 8th December 2014.

Address correspondence and reprint request to: Dr. Walid A. Al-Asbahi, Urology and Nephrology Center, Al-Thawra Modern General and Teaching Hospital, Faculty of Medicine and Health Sciences, Sana'a University, Sana'a, Yemen. Tel. +967 (734) 929979. E-mail: walasbahi@hotmail.com.

Complete circumferential rupture of the female urethra is extremely rare, and represents a challenging management situation.¹ As the entire posterior length of the urethra is closely adherent to the anterior wall of the vagina; it is subsequently prone to simultaneous injury. Most reported cases were associated with pelvic bone fractures, but there is no current consensus on management.² The diagnosis should be considered in cases of deep vaginal lacerations, with an inability to void with unsuccessful catheterization.³ Our objective in presenting this particular case is to highlight that

early recognition and strict adherence to the principles of reconstructive surgery are necessary to maximize the results and prevent subsequent risks of morbidity.

Case Report. A 35-year-old woman in the sixth month of pregnancy, presented to the emergency department post fall down straddle injury onto a sharp object (rock), during her work as a farmer. Her injuries involved the genitalia. There was profuse vaginal bleeding with an inability to pass urine. Examination revealed severe laceration of the anterior vaginal wall with complete urethral avulsion (Figure 1). Abdominal ultrasound findings showed that the urinary bladder was full and tender, with no intra-abdominal collection. The fetus was alive in the 26th week, with a cephalic presentation. Full informed consent was obtained for the possibility of preterm termination of pregnancy, urinary diversion, urethral stricture or fistula, incontinence, vaginal infection, or stenosis. Emergency surgery under general anesthesia, in the dorsal lithotomy position with hemostasis was carried out. A small catheter was passed from the anteriorly displaced meatus for 2 cm in the intact distal urethra, to the level of the avulsed urethra. Thereafter, the catheter was manipulated back into the bladder, until urine passed through the catheter from the urinary bladder. Primary urethral repair was performed trans-vaginally with end-to-end urethral anastomosis over stenting silicone catheter by interrupting 5/0 vicryl. The muscularis over the urethra was closed in a second layer, and the vaginal mucosa was then closed as a third layer by 2/0 vicryl; with an attempt being made to offset the suture line from the muscular closure (Figures 2a & 2b). The catheter was removed 4 weeks postoperatively, and the repair was intact. She was fully continent and voided satisfactorily with a good stream. At full term, a lower cesarean section was carried out and yielded a well baby of 3 kg. She was followed up every 2 months for 2 years to monitor any lower urinary

Disclosure. Authors have no conflict of interests, and the work was not supported or funded by any drug company.

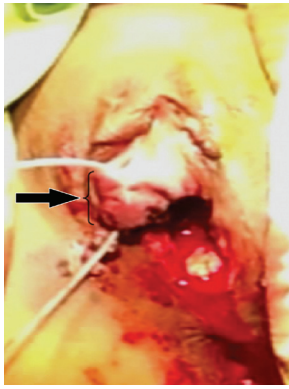


Figure 1 - Severe laceration of the anterior vaginal wall with complete urethral avulsion; with the catheter passed through the avulsed distal segment.

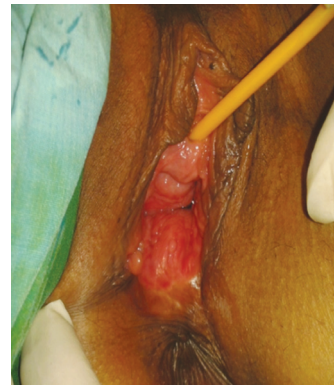

Figure 3 - Urethral calibration after one year, with wide urethral lumen and very healthy vagina.

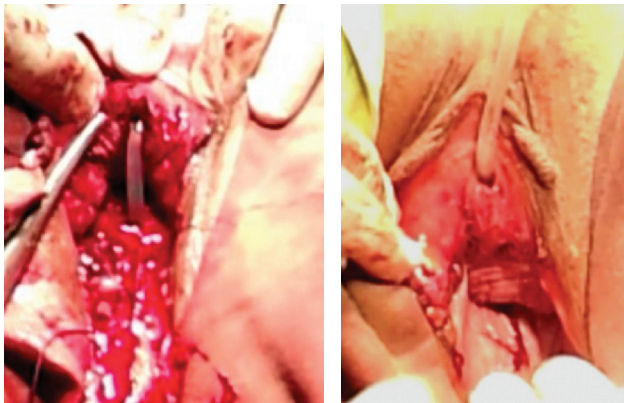


Figure 2 - Photograph of the A) end-to-end urethral anastomosis over stenting silicone catheter; and B) after final closure.

tract symptoms and sexual dysfunction. Two years post surgery, she is continent with a good stream of urine with a normal sexual life (Figure 3).

Discussion. Traumatic female urethral avulsion in the absence of a pelvic fracture is an exceedingly rare occurrence. On literature review, we found only 2 previously reported cases of urethral injury without pelvic fracture. The first, was a complete urethral and bladder neck disruption;¹ while the second case was a longitudinal urethral tear with vaginal laceration.² We report a case of pregnant female traumatic urethral avulsion without an associated pelvic fracture.

The management of female urethral injury is not well established, and most reported cases were associated with pelvic fracture. In some cases, management consisted of suprapubic cystostomy and deferred surgical reconstruction;³ while other authors favored primary repair over delayed repair whenever possible.^{1,2,4-6} Depending on the extent of urethral

injury, repair may be performed vaginally, trans-abdominally, or combined.⁴ In our patient, the repair was accomplished transvaginally. Anatomically, the female urethra is embedded in to the anterior wall of the vagina. The urethra itself consists of 3 layers: 1) the mucous layer, which is continuous with the bladder epithelium; 2) the thin layer of spongy erectile tissue, which includes the plexus of veins and bundles of smooth muscle fibers located immediately below the mucous layer, with both taken together during end to end anastomosis; and, 3) the muscular layer, which is continuous with the muscular layer of the bladder and closed as a second layer over the anastomosis. In some reports, authors maintain the urethral catheter for 3 weeks,⁵ while others keep it for 6 weeks.² In our patient, it was maintained for 4 weeks to allow proper healing and as a diversion for urine.

In conclusion, early recognition and proper management with primary urethral and vaginal repair can prevent the subsequent risk of morbidity.

References

1. McCool AC, Joseph DB. Complete urethral disruption without pelvic fracture. *J Urol* 2001; 166: 1425.
2. Bockholt NA, Nepple KG, Powell CR, Kreder KJ. Traumatic urethral injury without pelvic fracture in an adult female. *Scientific World Journal* 2010; 10: 308-310.
3. Podestá ML, Jordan GH. Pelvic fracture urethral injuries in girls. *J Urol* 2001; 165: 1660-1665.
4. Black PC, Miller EA, Porter JR, Wessells H. Urethral and bladder neck injury associated with pelvic fracture in 25 female patients. *J Urol* 2006; 175: 2140-2144.
5. Dorairajan LN, Gupta H, Kumar S. Pelvic fracture-associated urethral injuries in girls: experience with primary repair. *BJU Int* 2004; 94: 134-136.
6. Hemal AK, Dorairajan LN, Gupta NP. Posttraumatic complete and partial loss of urethra with pelvic fracture in girls: an appraisal of management. *J Urol* 2000; 163: 282-287.