

# Amputation vs Reconstruction in Type IV Tibial Hemimelia: Functional Outcomes and Description of a Novel Surgical Technique

Chun Hong Tang<sup>1</sup>, Abdullah Addar<sup>2</sup>, James Alfred Fernandes<sup>3</sup>

Received on: 16 September 2022; Accepted on: 06 April 2023; Published on: 31 May 2023

## ABSTRACT

**Introduction:** The management of tibial hemimelia can be complex and involve either amputation or reconstruction. The decision made carries significant implications on patients and their families. This is a case series in the management of Type IV tibial hemimelia with a description of a novel surgical technique in the reconstructive arm of the pathway.

**Materials and methods:** The study included four patients with bilateral tibial hemimelia have an amputation in one limb and reconstructive surgery on the other. The reconstruction involved a supratotal double osteotomy of the tibia and fibula, followed by a staged hindfoot osteotomy using a circular ring fixator. Functional outcomes are reported using the Special Interest Group in Amputee Medicine (SIGAM) and the short form 12 (SF-12) methods.

**Results:** The mean age of patients in our cohort is 14 years (3–27 years) with mean age of surgery at 3 years. One case had an amputation following initial reconstructive surgery due to psychological distress and regressive behaviour. SIGAM functional outcome scores of *F* were recorded in three of four cases, with one patient performing at level B. On the reconstructive side, two of three patients reported a mean physical short form 12 (SF-12) score of 56.7 and a mental SF-12 score of 55.7. One patient reported a physical SF-12 score of 28.5 and a mental SF-12 score of 30.3.

**Discussion and conclusion:** A reconstructive option provides a satisfactory functional outcome, comparable to the population mean, in the majority of patients in our cohort.

**Clinical significance:** A staged supratotal double osteotomy followed later by a hindfoot osteotomy is effective in centralising the ankle and creates a plantigrade weight-bearing platform for ambulation in patients with Type IV tibial hemimelia.

**Keywords:** Amputation, Deformity correction, Limb reconstruction, Skeletal dysplasia, Tibial hemimelia.

*Strategies in Trauma and Limb Reconstruction* (2023): 10.5005/jp-journals-10080-1576

## INTRODUCTION

Tibial hemimelia is a congenital anomaly with an absent or dysplastic tibia. It is seen in isolation or as part of complex syndromes such as Wolfgang–Gollup syndrome, ectrodactyly ectodermal dysplasia clefting syndrome, Werner's syndrome and others.<sup>1</sup>

The management of tibial hemimelia has unpredictable outcomes and a wide variety of treatment options with no guarantee of predictable results. The treatment options are broadly either reconstructive or removal, with both options having significant implications on the patient in later life. The incidence of this rare disease in the general population of 1/1,000,000 makes determining the optimum management more difficult.

The most widely applied classification is the Jones Classification, which divides the disease into four distinct categories depending on the length and shape of the remaining tibial stump seen radiologically. Jones then divided the disease into three distinct groups when considering the management options. Group I (absent tibia), for which a knee disarticulation is recommended, group II (proximal tibia present) where a tibia–fibula synostosis was the preferred option, followed by a Syme's amputation, and group III (short tibia with diastasis) where they described their failed

<sup>1,3</sup>Paediatric Limb Reconstruction Service, Sheffield Children's Hospital, Western Bank, Sheffield, United Kingdom

<sup>2</sup>Department of Orthopedic Surgery, College of Medicine, King Saud University, Riyadh, Saudi Arabia

**Corresponding Author:** James Alfred Fernandes, Paediatric Limb Reconstruction Service, Sheffield Children's Hospital, Western Bank, Sheffield, United Kingdom, Phone: +01142717094, e-mail: james.fernandes@nhs.net

**How to cite this article:** Tang CH, Addar A, Fernandes JA. Amputation vs Reconstruction in Type IV Tibial Hemimelia: Functional Outcomes and Description of a Novel Surgical Technique. *Strategies Trauma Limb Reconstr* 2023;18(1):32–36.

**Source of support:** Nil

**Conflict of interest:** Dr James Alfred Fernandes is associated as the Associate Editor of this journal and this manuscript was subjected to this journal's standard review procedures, with this peer review handled independently of this editorial board member and his research group.

experience with reconstructive options and recommended a Syme's amputation for these cases.<sup>2</sup> Subsequently, different modifications of this classification system have been described.<sup>3–5</sup>

This is a case series of this unit's management of tibial hemimelia with Jones type IV or group III by reconstruction. We report the functional scores in our group of patients and provide a description of the staged reconstructive technique which utilises supratotal bi-focal osteotomies to correct the foot deformity and achieve a centralised plantigrade foot position.

## MATERIALS AND METHODS

A retrospective case series of four patients treated over 15 years is described. The Jones Classification was used. The inclusion criterion was a diagnosis of Jones type IV tibial hemimelia managed with a staged supratotal double osteotomy as reconstructive surgery. Patients with an associated diagnosis of longitudinal deficiency in the same limb, such as congenital fibular or femoral deficiency, or those who had monolateral external fixation or other circular fixation types were excluded. All authors reviewed the radiographs independently and consensus was achieved across all four cases. The local institutional review board approved this study.

All patients in this case series had bilateral tibial hemimelia and underwent an amputation on one side. The primary outcomes were functional scores after they had completed their treatment. The Special Interest Group in Amputee Medicine (SIGAM) score was used to assess patients with an amputation.<sup>6</sup> The short form 12 (SF-12) was used to assess the functional outcomes on their reconstructive side. Both mental and physical functional scores were documented. The functional scores were obtained by telephone interviews with the interviewer filling in the results according to the patient's responses.

Other variables such as the number of procedures undergone by each patient were also documented, along with any complications.

### Operative Technique

The senior most author's reconstructive technique of tibial hemimelia involves a staged procedure. Stage 1 centralises the foot under the leg and uses a circular fixator, and stage 2 corrects the mid- and hindfoot deformity, which is in equinovarus (Figs 1 and 2). The circular fixator utilises the principles of Gavriil Iltzarov to achieve a stable construct to allow distraction and gradual correction of the deformity, in addition to controlled osteotomies of the leg and foot.<sup>7-9</sup> The patients are counselled and assessed by the paediatric limb reconstruction assessment team through whom are shown an example of the frame and taught how the gradual adjustments are made. They are also given an opportunity to meet other patients who had similar treatment.

The operation is performed in the supine position. A supratotal bifocal osteotomy is done percutaneously on the distal tibia and fibula, utilising the De Bastiani technique starting with drilling and completed with an osteotome.<sup>10</sup> The frame construct comprises two leg rings and a foot plate (Figs 3 to 5). The frame is fixed with an all-wire construct that enables better access in the paediatric foot. All the rings are connected via rods. Triple hinges or hexapod struts are applied to control correction. The correction in stage 1 is acute distraction in the operating theatre with more gradual distraction over the subsequent 7 days before abduction and external rotation of the distal tibia and fibula is commenced. Note the position of the talus in relation to the tibia, and fibula is not deliberately altered (Figs 6 and 7). The first stage is done independently to correct the complex deformity, making the foot plantigrade, externally rotated and normalise the foot progression angle. The frame is removed once the osteotomy site is healed and the patient has mobilised.

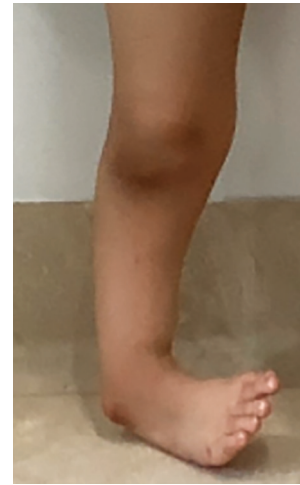

Fig. 1: Demonstrating weight-bearing position on the lateral border of the foot

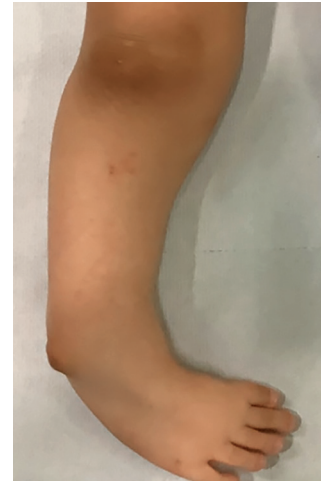

Fig. 2: Demonstrating the equinovarus foot deformity

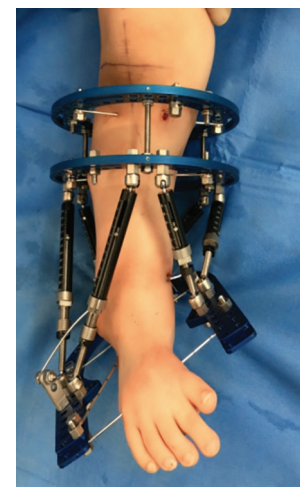

Fig. 3: Lateral view of the hexapod frame construct

Typically, after 8–12 months, when the ankle is neutral, foot size has increased and central in all planes, the patient undergoes the second stage which involves a hindfoot U-osteotomy of the

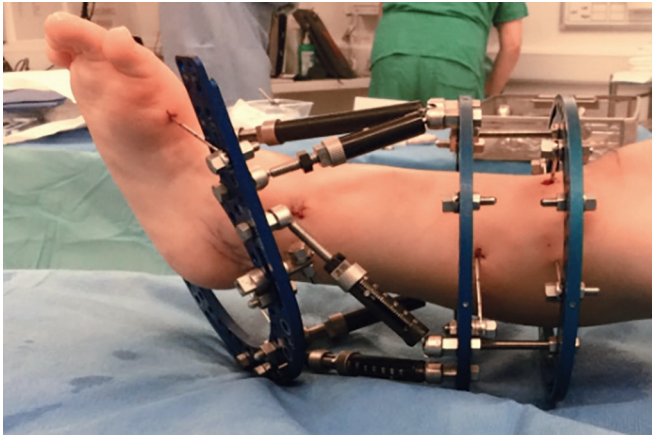


Fig. 4: Antero-posterior view of the hexapod frame construct

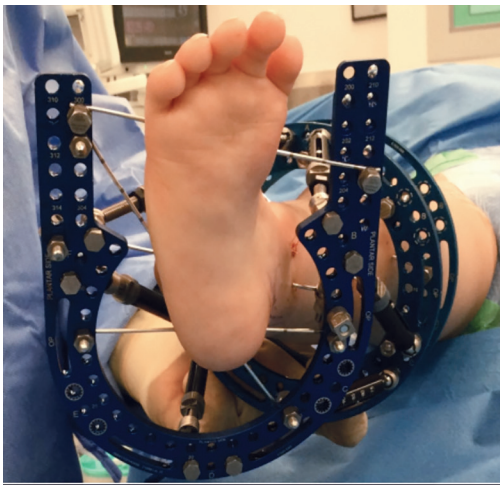


Fig. 5: Axial view of the hexapod frame construct

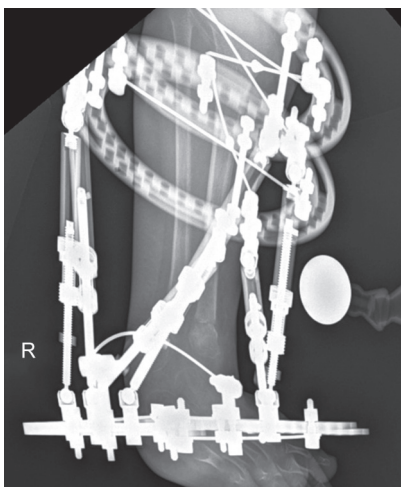


Fig. 6: Antero-posterior radiograph showing initial correction post 1st stage supratalar biosseous osteotomy

posterior calcaneum. The osteotomy site is again distracted for a week, before correcting any residual minor deformities of the foot gradually in the circular fixator with increase in submalleolar height to improve shoe wear. Once the deformity and height are corrected,

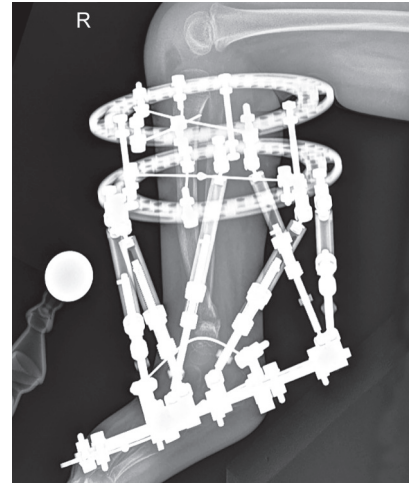


Fig. 7: Lateral radiograph showing initial correction post 1st stage supratalar biosseous osteotomy

the osteotomy sites are allowed to consolidate. This may also involve dynamising the frame to allow progressive weight-bearing through the limb rather than the frame. The frame is removed once sufficient consolidation is confirmed clinically and radiologically.

The Syme's ankle disarticulation is performed as described by James Syme in 1843, with a slight modification of suturing the heel pad to the exposed distal tibia epiphysis and inserting a nerve catheter along the severed posteromedial neurovascular bundle for post-operative pain relief.<sup>11,12</sup>

## RESULTS

There were one male and three female patients in our cohort. The median age was 14 years (3–27 years). The mean age of patients when surgery was first done was 3 years (median age 2).

All patients had bilateral tibial hemimelia with one patient having type IV on the left and type Ib on the right (case 1), one patient having bilateral type IV tibial hemimelia (case 2), two patients having type IV on the right and type II on the left (cases 3 and 4).

All patients underwent amputation on one limb and the staged supratalar osteotomy reconstruction on the other. The decision to choose between pathways was determined by the Jones classification, with types I–III primarily undergoing ablation due to the complications with regard to reconstructive options.<sup>2</sup> Where patients had bilateral type IV tibial hemimelia, the decision pathway was made based on the presence or absence of a functional foot, as described by Birch et al.<sup>13</sup>

Case 1 underwent a primary Syme's amputation on the right limb and a reconstruction on the left. He reports a functional status of *F* on his amputation side, indicating a normal or near-normal gait. On his reconstructive side, he reported a physical SF-12 score of 55.1 and a mental SF-12 score of 57.7.

Case 2 had a primary Syme's amputation on the left because of two missing rays in the foot with a significant equinovarus deformity. There was only one ray missing on the right foot; the decision was made to proceed with a reconstructive option on that side. She underwent a staged supratalar double osteotomy with gradual correction using a circular fixator. Unfortunately, following her second stage surgery, she developed regressive behaviour. This was reviewed by clinical psychology and the staff at the limb deficiency clinic where a joint decision was made to

amputate her reconstructed side to allow her to manage her functional independence. Her current functional scores on both sides is F.

Cases 3 and 4 underwent primary Syme's amputations on the left side with reconstruction on the right. The functional status were F and B, respectively, on the amputated sides; the physical SF-12 scores were of 57.7 and 28.5, and the mental SF-12 scores were 53.7 and 30.3, respectively, on the reconstructive side.

## DISCUSSION

Tibial hemimelia is a challenging condition to treat. The current literature indicates the most reproducible treatment with acceptable results is an amputation at varying levels.

The use of circular external fixators to treat tibial hemimelia is established with many recent modifications to the technique.<sup>5,14</sup> One of the earliest and most extensive studies to be done was by Clinton and Birch et al., who reviewed a total of 125 cases over 37 years at their institution. They reported that most cases underwent an amputation primarily or following a failed reconstructive procedure. Only four patients underwent a successful primary reconstructive procedure and these were what the authors term a "Jones type V" subgroup.

A study by Kumar et al. involving 35 cases of tibial hemimelia were managed with a combination of nonoperative techniques like serial casting or orthoses in the skeletally mature, or by surgical reconstruction in nine cases involving tibiofibular synostosis, in addition to knee and ankle centralisation procedures.<sup>15</sup> They reported that amputations were not socially acceptable in their society and were not commonly performed. There were no surgical outcomes reported in their study.

Paley<sup>5</sup> published a new classification system that was based on management options and recommended a series of reconstructive procedures to correct the deformity based on the severity of the disease and the deformity pattern, not dissimilar to our technique of a supratotal double tibia and fibula osteotomy followed by a hindfoot osteotomy.

Wada et al.<sup>16</sup> published 19-foot centralisations cases in 14 patients with Jones type I or II deformities. The technique described involves resection of the posterior talus and a calcaneofibular arthrodesis with a complete posteromedial release of the foot. This is done following a Brown's or tibiofibular fusion procedure. The primary outcome was the correction of the equinus deformity. They reported that in 15 of 19 cases further surgery was required for recurrence of deformity.<sup>16</sup>

Shahcheraghi and Javid<sup>17</sup> published on foot reconstruction in 48 cases of tibial hemimelia in 36 patients. They had 14 cases of Jones type I, 16 cases of type II, 0 case of type III, and 11 cases of type IV, with a further 7 cases not classifiable by the Jones system. Ten cases had undergone an amputation, all of which were Jones type I. The remaining 38 cases had reconstructive surgery to the foot, involving a combination of tibiofibular synostosis (20 cases), ankle centralisations (23 cases), Ilizarov lengthening (18 cases), and the Brown procedure (5 cases). There were no statistically significant differences when the functional outcomes of both groups were compared using the PedsQL score. However, the reconstructed group had better functional scores in the physical, social, psychological, and schooling domains.<sup>17</sup> Most patients in the amputation group had bilateral amputations. When they compared patients' satisfaction levels between groups, half of the amputation group were entirely satisfied and the other half was partially

satisfied. There were 29% fully satisfied in the reconstruction group, 67% almost satisfied, and 4% were unsatisfied.<sup>17</sup>

Our results echo those above; they demonstrate equivalent functional scores when the reconstructed group was compared with the general population scores using the SF-12 questionnaire.<sup>18-21</sup> In addition, we found amputation as the primary treatment modality for patients in our group, also resulted in good functional outcomes.

Case 4 in our study has poorer than average results because of persistent pain and poor prosthetic fitting on the amputated side. The reconstructive side had a plantigrade foot and a good range of motion in the ankle, and did not seem to be limiting the patient. However, as both SIGAM and SF-12 scores were not specifically designed for patients who underwent both ablative and reconstructive options, there was inevitably some crossover in terms of functional results observed. This patient is being reviewed currently by both the paediatricians and prosthetic limb team to enable greater symptomatic relief and improve her functional outcome.

This study is limited by the number of cases included. There were only four cases with the staged supratotal double osteotomy and hindfoot osteotomy procedures, three of which resulted in a good outcome and the other subsequently requiring an amputation due to psychological challenges. The lack of pre-operative functional scores impairs the complete evaluation of post-operative outcomes. Owing to the rarity of this disease, it is worthwhile to report these results. In addition, the reconstructive option as described here can improve the functional outcomes for a select group of patients. This case series has shown that both management pathways can result in good and acceptable functional outcomes in this cohort of patients. Psychological acceptance and tolerance of an external fixator remains a potential complication that clinicians need to be aware of.

## CONCLUSION

Tibial hemimelia is a challenging condition to treat with most patients requiring an amputation to provide them with a predictable functional outcome. However, in a select group of patients, namely type IV Jones, a staged reconstructive procedure can allow for successful correction of the deformity and provide the patient with a plantigrade functional foot on which to weight bear.

## REFERENCES

1. Dhanakodi N, Tripathy SK. Gollop-Wolfgang syndrome. *Indian J Med Res* 2014;139(6):963-964. PMID: 25109738.
2. Jones D, Barnes J, Lloyd-Roberts G. Congenital aplasia and dysplasia of the tibia with intact fibula. Classification and management. *J Bone Joint Surg Br* 1978;60-B(1):31-39. DOI: 10.1302/0301-620X.60B1.627576.
3. Clinton R., Birch JG. Congenital tibial deficiency: a 37-year experience at 1 institution. *J Pediatr Orthop* 2015;35(4):385-390. DOI: 10.1097/BPO.0000000000000280.
4. Weber M. New classification and score for tibial hemimelia. *J Child Orthop* 2008;2(3):169-175. DOI: 10.1007/s11832-008-0081-5.
5. Paley D. Tibial hemimelia: new classification and reconstructive options. *J Child Orthop* 2016;10(6):529-555. DOI: 10.1007/s11832-016-0785-x.
6. Calder P, Shaw S, Roberts A, et al. A comparison of functional outcome between amputation and extension prosthesis in the treatment of congenital absence of the fibula with severe limb deformity. *J Child Orthop* 2017;11(4):318-325. DOI: 10.1302/1863-2548.11.160264.
7. Ilizarov GA The tension-stress effect on the genesis and growth of tissues. Part I. The influence of stability of fixation and soft-tissue preservation. *Clin Orthop* 1989;(238):249-281. PMID: 2910611.

8. Ilizarov GA. The tension-stress effect on the genesis and growth of tissues: part II. The influence of the rate and frequency of distraction. *Clin Orthop* 1989;(239):263–285. PMID: 2912628.
9. Ilizarov GA, Lediaev VI, Shitin VP. The course of compact bone reparative regeneration in distraction osteosynthesis under different conditions of bone fragment fixation (experimental study). *Eksp Khir Anesteziol* 1969;14(6):3–12. PMID: 5385792.
10. De Bastiani G, Aldegheri R, Renzi-Brivio L, Trivella G. Limb lengthening by callus distraction (callotaxis). *J Pediatr Orthop* 1987;7(2):129–134. DOI: 10.1097/01241398-198703000-00002.
11. Syme J. On amputation at the ankle joint. *Lond Edinb Mon J Med Sci* 1843;3:93. DOI: 10.1016/S0140-6736(02)37748-1.
12. Oppenheim WL. Fibular deficiency and the indications for Syme's amputation. *Prosthet Orthot Int* 1991;15(2):131–136. DOI: 10.3109/03093649109164648.
13. Birch JG, Lincoln TL, Mack PW, Birch CM. Congenital fibular deficiency: a review of thirty years' experience at one institution and a proposed classification system based on clinical deformity. *J Bone Joint Surg Am* 2011;93(12):1144–1151. DOI: 10.2106/JBJS.J.00683.
14. Chong DY, Paley D. Deformity reconstruction surgery for tibial hemimelia. *Children* 2021;8(6):461. DOI: 10.3390/children8060461.
15. Kumar Sahoo P, Sahu MM, Prasad Das S. Clinical spectrum of congenital tibial hemimelia in 35 limbs of 24 patients: a single center observational study from India. *Eur J Med Genet* 2019;62(7):103666. DOI: 10.1016/j.ejmg.2019.05.005.
16. Wada, A, Nakamura T, Urano N, et al. Foot centralization for tibial hemimelia. *J Pediatr Orthop B* 2015;24(2):147–153. DOI: 10.1097/BPB.0000000000000149.
17. Shahcheraghi GH, Javid M. Functional assessment in tibial hemimelia (can we also save the foot in reconstruction?). *J Pediatr Orthop* 2016;36:572–581. DOI: 10.1097/BPO.0000000000000513.
18. Foster PAL, Barton SB, Jones SCE, et al. The treatment of complex tibial shaft fractures by the Ilizarov method. *J Bone Joint Surg Br* 2012; 94-B(12):1678–1683. DOI: 10.1302/0301-620X.94B12.29266.
19. Mekhail AO, Abraham E, Gruber B et al. Bone transport in the management of posttraumatic bone defects in the lower extremity. *J Trauma Inj Infect Crit Care* 2004;56:368–378. DOI: 10.1097/01.TA.0000057234.48501.30.
20. Brinker MR, O'Connor DP. Outcomes of tibial nonunion in older adults following treatment using the Ilizarov method. *J Orthop Trauma* 2007;21(9):634–642. DOI: 10.1097/BOT.0b013e318156c2a2.
21. Robinson PM, Papanna MC, Somanchi BV, Khan SA. High tibial osteotomy in medial compartment osteoarthritis and varus deformity using the Taylor spatial frame: early results. *Strateg Trauma Limb Reconstr* 2011;6(3):137–145. DOI: 10.1007/s11751-011-0123-2.