

Treatment of Disseminated Aspergillosis with Posaconazole in 10 Dogs

V.K. Corrigan, A.M. Legendre, L.J. Wheat, R. Mullis, B. Johnson, D.A. Bemis, and L. Cepero

Background: Few effective treatments for disseminated *Aspergillus* infections in dogs are available. Posaconazole has potent and broad-spectrum activity against *Aspergillus spp.*, but its use has not yet been sufficiently evaluated in dogs.

Hypothesis/Objectives: The aim of this study was to determine the safety and efficacy of posaconazole for the treatment of naturally occurring disseminated *Aspergillus* infections in dogs.

Animals: Ten client-owned dogs with disseminated aspergillosis.

Methods: Prospective, nonrandomized, noncontrolled study with posaconazole administered to dogs at dosage of 5 mg/kg PO q12h. The primary veterinarian or the veterinary specialist caring for the dogs provided patient data.

Results: The treatment response for dogs with disseminated disease while receiving posaconazole was defined as clinical remission ($n = 4$) and clinical improvement ($n = 6$). There was a high rate of relapse during treatment or after cessation of treatment in both groups, and most dogs died or were euthanized due to progressive disease. Excluding 1 dog concurrently treated with terbinafine that remains alive 5 years after diagnosis, the mean survival time for dogs was 241 days (range 44–516 days). Three other dogs lived >1 year after starting treatment. No clinically relevant adverse events or increases in serum liver enzyme activity occurred during treatment with posaconazole.

Conclusions and Clinical Importance: Posaconazole appears to be safe and well-tolerated for treatment of disseminated *Aspergillus* infections in dogs. Long-term survival >1 year is possible with prolonged treatment, but relapse is common.

Key words: *Aspergillus*; Diskospondylitis; Fungal; Pyelonephritis.

Fungi of the genus *Aspergillus* are ubiquitous in the environment and can cause disease in both animals and humans. The sinonasal form of disease in dogs is most common, with disseminated and primary bronchopulmonary forms occurring rarely.¹ *Aspergillus terreus* and *Aspergillus deflexus* are the most common species in patients with disseminated disease,¹ and associated pathology often involves several tissues, such as the kidneys, intervertebral discs, bones, and central nervous system.²

Few effective drugs currently are available for treating disseminated *Aspergillus* infections in dogs, and the prognosis typically is poor.¹ Many of the available medications are prohibitively expensive or are available only for parenteral administration. Amphotericin B (AMB) was shown to be ineffective in murine and in vitro experimental models of disseminated *A. terreus* infection.^{3–5} Long-term clinical remission was achieved by administration of

Abbreviations:

AMB	amphotericin B
GMA	galactomannan antigen assay
GSD	German Shepherd dog
MIC	minimum inhibitory concentration
UTCVM	University of Tennessee College of Veterinary Medicine
UTVMC	University of Tennessee Veterinary Medical Center

itraconazole PO in 4 dogs⁶ but similar success has not been achieved in recent case reports.^{7–10} Voriconazole, a newer azole derivative, has been used with success in human patients with invasive aspergillosis, but the drug is very expensive.¹¹ Terbinafine and caspofungin are non-azole antifungal drugs that have been used alone or in combination with other therapies to treat resistant strains of *Aspergillus* in people.^{12–14} Terbinafine and caspofungin have been used empirically in dogs, but additional studies are required to determine their efficacy.^{2,14–16}

Posaconazole, a lipophilic triazole antifungal agent structurally similar to itraconazole, has potent and broad-spectrum activity against *Aspergillus* and other fungi.^{5,17} Posaconazole has been approved by the Food and Drug Administration for the prevention of invasive *Aspergillus* infection in humans.¹⁸ This drug, as do other triazoles, inhibits lanosterol-14- α -demethylase, a fungal enzyme necessary for ergosterol formation and maintenance of cell membrane permeability.¹⁹ Posaconazole is active in vitro and in vivo, and was the most effective of the azoles tested, inhibiting 94% of *Aspergillus* spp. isolates at a minimum inhibitory concentration (MIC) ≤ 1 .^{17,20,21} Clinical experience with posaconazole in humans with systemic aspergillosis has been promising, and 75% of patients in a recent study had complete or partial clinical response after 8 weeks of posaconazole treatment.^{21–23}

From the Department of Small Animal Clinical Sciences, Virginia-Maryland College of Veterinary Medicine, Blacksburg, VA (Corrigan); Department of Small Animal Clinical Sciences, College of Veterinary Medicine, University of Tennessee, Knoxville, TN (Legendre, Mullis, Johnson, Cepero); MiraVista Diagnostics, Indianapolis, IN (Wheat); and Diagnostic Services, Knoxville, TN (Bemis).

Corresponding author: V.K. Corrigan, Department of Small Animal Clinical Sciences, Virginia-Maryland College of Veterinary Medicine, 245 Duck Pond Drive, Blacksburg VA 24061, Mail Code 0442; e-mail: vavet10@vt.edu.

Submitted February 24, 2015; Revised October 4, 2015; Accepted October 15, 2015.

Copyright © 2015 The Authors. Journal of Veterinary Internal Medicine published by Wiley Periodicals, Inc. on behalf of the American College of Veterinary Internal Medicine.

This is an open access article under the terms of the Creative Commons Attribution-NonCommercial License, which permits use, distribution and reproduction in any medium, provided the original work is properly cited and is not used for commercial purposes.

DOI: 10.1111/jvim.13795

Administering the oral suspension with food in divided daily doses achieves maximum bioavailability in people^{24–26} and dogs.²⁷ When given PO to dogs, the serum drug concentrations were dose-proportional and accumulated with multiple dosing.^{5,27} Serum concentrations above the MIC were observed 24 hours after a single PO dose of 10 mg/kg.^{5,28}

Reported adverse events associated with posaconazole are rare, and the drug appears to be well-tolerated in dogs and people.^{17,27,29–31} Less than 1% of the parent compound is eliminated by renal excretion, and metabolism mainly is by glucuronidation. Therefore, dose adjustments are not necessary with renal impairment.³² Posaconazole is highly protein-bound and has a large volume of distribution, which indicates extensive extravascular distribution and intracellular penetration,^{17,28} including penetration of the blood-brain barrier.⁵ Hepatotoxicity can occur, but resultant hepatic dysfunction is rare.^{17,18,29,32}

The primary objective of our study was to determine the safety and efficacy of posaconazole for the treatment of naturally occurring disseminated *Aspergillus* infections in dogs.

Materials and Methods

Dogs

Client-owned dogs with disseminated aspergillosis were recruited for the study using the American College of Veterinary Internal Medicine list serve and through referral to the University of Tennessee Veterinary Medical Center (UTVMC) from June 2008 to June 2011. A total of 10 dogs were treated with posaconazole.

Inclusion Criteria

Inclusion criteria for entry into the study were a confirmed diagnosis of disseminated aspergillosis by a culture from tissue, urine, or lesion aspirates. Dogs with disseminated aspergillosis that had received or currently were receiving antifungal treatment were included. The University of Tennessee Institutional Animal Care and Use Committee (IACUC), protocol number 1742-0608, approved all procedures before commencement of the study, and informed consent was obtained from owners of enrolled dogs.

Study Design

The design was a nonrandomized noncontrolled prospective study. Data for the study were obtained from the primary care veterinarian or from the veterinary specialist treating the dogs. Two patients were treated at the UTVMC.

Posaconazole Treatment

Dogs in the study received an oral suspension of posaconazole^a (40 mg/mL) at 5 mg/kg PO q12h with food. The posaconazole was dispensed to the owners free of charge but any other costs associated with diagnostic testing and treatment were not covered by the study. Treatment with posaconazole was to continue for 1 month after a negative urine culture. Patients then were to be monitored for relapse for at least 1 year after the completion of treatment. Patients that relapsed after discontinuation of

posaconazole could receive more drug at the discretion of the principal investigator (AML).

Posaconazole Treatment Monitoring

Dogs were evaluated monthly during the posaconazole treatment, and owners were instructed to notify the attending veterinarian if their dog was anorexic, vomiting, or if they had any other concerns. In addition to physical examination, a CBC, serum biochemical profile, and urinalysis were to be done monthly to monitor liver enzyme activities as well as to identify any other potential adverse effects of the posaconazole. Increase in serum alkaline phosphatase (ALP) activity was classified as mild (73–200 IU/L; reference range, 12–72 IU/L), moderate (201–400 IU/L), or severe (>400 IU/L). Increase in serum alanine transferase activity (ALT) was classified as mild (76–200 IU/L; reference range, 20–75 IU/L), moderate (201–400 IU/L), or severe (>400 IU/L).

Owners kept daily logs to ensure compliance with drug administration and to monitor for possible adverse effects of posaconazole. These logs included a record of the time of drug administration, as well as appetite, level of fatigue, vomiting, diarrhea, and increased or decreased frequency of urination. These logs were submitted to the veterinarian treating the dog on a monthly basis.

Clinical Data

At study inclusion, physical examination, CBC, biochemical profile, urinalysis (including sediment to examine for fungal hyphae), fungal culture from urine or a lesion aspirate, and a full ophthalmic examination were required. Throughout the treatment period, repeated physical examination, CBC, biochemistry and urinalysis testing were repeated monthly, and again at 2 months after treatment cessation. A urine fungal culture was repeated at the 3-month evaluation and before discontinuation of treatment. At the discretion of the treating veterinarian, additional diagnostic tests including thoracic radiographs, ultrasonographic examination of the kidneys, radiographs of lesion(s) or some combinations of these were repeated at monthly intervals or as indicated by the specific aspects of each individual case. After completion of posaconazole treatment, re-evaluations were continued monthly for 3 months, and then every other month for at least 1 year.

At each visit, physical examination findings were documented on a standardized form. Repeat diagnostic testing was performed either in-house or at an external laboratory chosen at the discretion of the treating veterinarian. Samples for serum *Aspergillus* galactomannan antigen assay (GMA) index tests^{b,c} and serum posaconazole concentrations^d were collected whenever possible, and were batched for later analysis at completion of the study.

For this report, clinical records obtained from the UTVMC or referring veterinarian were retrospectively reviewed. Clinical data extracted from each case included signalment, history and prior treatment, physical examination findings, clinicopathologic and diagnostic imaging findings, fungal culture results, and the presence of any concurrent conditions. For analysis of response to treatment, the duration and clinical response to treatment were evaluated, as well as evidence of relapse during the treatment period or after cessation of treatment. Results of GMA testing and posaconazole concentration also were evaluated whenever available.

Treatment Data

The treatment response while the dogs were currently receiving posaconazole was categorized as clinical remission, clinical improvement, or treatment failure. Clinical remission was defined

as elimination of clinical signs during treatment resulting in a clinically normal dog. Clinical improvement was defined as improvement without resolution of clinical signs during treatment. Treatment failure was defined as no improvement of clinical signs at any stage of treatment. Patients also were assigned a relapse category (yes/no). Relapse was defined as recurrence of clinical signs at any time during or after cessation of treatment with posaconazole. Survival time was defined as the time from initiation of treatment until death, euthanasia, or loss of follow-up.

Adverse events while being treated with posaconazole were documented based on owner logs and assessments by the attending veterinarian. Clinical signs were not considered to be adverse events of the medication if they were present before entry into the study, and if no clinically relevant changes in these signs occurred during the course of treatment. Abnormal biochemical variables that were present at the beginning of the study were not considered adverse events if they did not change substantially during the course of treatment.

Results

Signalment and Clinical Findings

Ten dogs with disseminated aspergillosis were treated. German Shepherd Dogs (GSDs) were most common (6), with the remaining dogs consisting of mixed breed (1), Vizsla (1), Newfoundland (1), and Giant Schnauzer (1). Ages of the dogs ranged from 1 to 7 years (mean, 5.8 years). Duration of clinical signs before entrance in the study ranged from 2 months to 2 years. There were 7 spayed females and 3 neutered males.

Physical examination findings at the time of enrollment included back pain, pelvic limb ataxia, or both (5), decreased appetite, weight loss, or both (5), lethargy (3), gastrointestinal signs (vomiting, diarrhea, or both) (3), lameness in ≥ 1 limb (3), polyuria, polydipsia or both (2), anterior uveitis (2), vestibular signs (2), skin lesions (1), lower urinary tract signs (1), and peripheral lymphadenopathy (1). Seven dogs previously had been treated with ≥ 1 antifungal drug, including itraconazole (6), terbinafine (2), and voriconazole (1). Three dogs had not received any prior antifungal treatment before enrollment into the study. None of the dogs were receiving immunosuppressive drugs before entry or during the study.

Diagnostic Findings

Diagnostic imaging findings and biochemical abnormalities at the time of enrollment were dependent upon site(s) of disease involvement. Common diagnostic imaging findings included urinary tract involvement with or without evidence of pyelonephritis (10), diskospondylitis (7), abdominal lymph node enlargement (4), splenic nodules or abnormal splenic architecture or size (3), osteomyelitis (2), and pulmonary involvement (2). Abnormalities on CBC included nonregenerative anemia (2), leukocytosis (4), neutrophilia (4), monocytosis (3), eosinophilia (3), and thrombocytopenia (1). Biochemical profile abnormalities included hyperglobulinemia (4), hypoalbuminemia (3), azotemia (3), increased ALP activity (2), increased AST activity (1), increased ALT activity (1), hyperbilirubinemia (1),

increased CK activity (1), hyperphosphatemia (1), and hypokalemia (1). Urinalysis abnormalities included isosthenuria or hyposthenuria (7), hematuria, pyuria or both (5), and fungal hyphae noted on urinary sediment examination (4).

Confirmation of disseminated aspergillosis was obtained by cultures of urine (6), a spinal mass (1), fluid from a cystic renal mass (1), histopathology of an enucleated eye (1), and fungal hyphae noted on fine needle aspirate of a peripheral lymph node (1). *Aspergillus terreus* was the most commonly cultured organism (5), with *Aspergillus fumigatus* (1) and *Aspergillus versicolor* (1) also isolated. In 3 dogs, the species of *Aspergillus* was not identified.

Response to Posaconazole Treatment

All dogs experienced at least partial responses to posaconazole treatment, with 4 dogs achieving clinical remission, and 6 dogs achieving clinical improvement. There were no treatment failures. Average treatment time for all dogs was 7.25 months (range 1.5–15 months). Mean survival time for 9 of the 10 dogs was 241 days (range 44–516 days). One dog was still alive at the time of manuscript submission >5 years after starting treatment, and was not included in mean survival time calculation because it was considered an extreme outlier. Median survival time for these 9 dogs was 215 days.

Of the 4 dogs that experienced clinical remission during treatment, 2 dogs relapsed after treatment was discontinued, 1 dog did not relapse, and 1 dog was lost to follow-up during treatment. All of these dogs were GSDs. The dog that did not relapse is the dog that was alive at time of writing. This dog was treated concurrently with terbinafine at a dosage of 15 mg/kg PO q12h and posaconazole for 15 months, along with amoxicillin–clavulanic acid for the final 10 months of treatment. A secondary bacterial component was suspected to be a contributing factor because bacterial urine cultures were positive for *Escherichia coli* on 2 occasions. One dog was lost to follow-up after 150 days of treatment. The 2 remaining dogs relapsed at 188 and 42 days after posaconazole was discontinued, and eventually were euthanized. The mean survival time for this group of dogs (excluding the outlier) was 383 days (range 150–516 days), and average treatment time was 11 months (range 5–15 months). At 1 year after starting treatment, 3 of these dogs were alive.

Of the 6 dogs with clinical improvement while on posaconazole, 3 dogs relapsed after treatment was discontinued, and 3 dogs relapsed during treatment. Two of these dogs were GSDs. One dog initially was treated for 5 months and then relapsed 42 days after posaconazole was discontinued. This dog then was treated for 8 additional months, but was eventually euthanized because of deteriorating condition while still on treatment. Two other dogs experienced relapse shortly after treatment was discontinued. One of these dogs was restarted on posaconazole, but eventually was euthanized because of worsening of clinical signs after 2

additional months of treatment. The remaining dog died 35 days after completing 5 months of posaconazole treatment; necropsy identified severe retroperitoneal hemorrhage found in association with a fungal granuloma in 1 kidney. The remaining 3 dogs relapsed after an initial period of clinical improvement, and died or were euthanized because of progressive disease while still on treatment. The mean survival time for this group of dogs was 171 days (range 44–432 days), and the average treatment time was 4.75 months (range 1.5–13 months). One dog was alive 1 year after starting treatment.

Overall, 4 of the 10 dogs experienced long-term survival (>1 year). All of these dogs were GSDs. The mean survival time for dogs living >1 year was 477 days (range 432–516 days), not including the dog that survived >5 years. These dogs were treated with posaconazole for an extended period of time (10–15 months). Six of the 10 dogs lived <1 year, and the mean survival time for these dogs was 124 days (range 44–230 days).

Four dogs with disseminated disease had the *Aspergillus* GMA test performed at the time of initial evaluation; all of them were positive. Two dogs had serial GMA results available as well as 30-day serum posaconazole drug concentration measurements. The results of the serial GMA results are presented in Fig 1. The first data set gives GMA results in the dog still alive at the time of writing. The GMA results decreased to negative after 120 days of treatment, and remained negative at each successive time point, except for the 13-month time point (result, 1.58). Because results ≥ 1.5 are considered positive, this 1 data point above the reference range may indicate a false positive because the dog was clinically cured after 15 months of treatment. The second set of data was from a dog that experienced clinical remission, but relapsed after treatment was discontinued. The results were positive at all time points. The 30-day posaconazole concentrations for these dogs were 3.88 and 3.41 $\mu\text{g}/\text{mL}$, respectively.

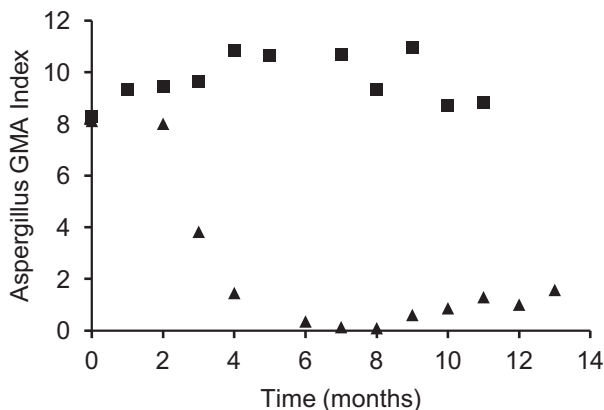


Fig 1. Serial serum *Aspergillus* galactomannan antigen assay (GMA) index results for 2 dogs while receiving posaconazole treatment; data set 1 (diamonds) and data set 2 (squares). GMA index results ≥ 1.5 were considered positive. Missing data points not included.

Adverse Events seen with Posaconazole

There were no clinically relevant adverse events noted in any dog while receiving posaconazole. Reported clinical findings noted by owners while dogs were receiving posaconazole were vomiting, diarrhea, or both (3), polyuria, polydipsia, or both (3), and decreased appetite (3). The only noted changes in liver enzyme activity were mild increases in ALT activity (2). Other documented hematologic and biochemical changes included mild thrombocytopenia of 92,300/ μL (1), and mild, self-limiting leukopenia of 3,500/ μL and neutropenia of 1,470/ μL (1). None of the reported clinical signs or biochemical variables required discontinuation or alteration of the dose during the course of treatment.

Discussion

Based on our small study, posaconazole appears to be safe and well-tolerated for the treatment of disseminated *Aspergillus* infections in dogs. Long-term (>1 year) survival was achieved with prolonged treatment in 4 dogs, but relapse was common. No clinically relevant adverse events occurred in association with treatment other than mild increases in ALT activity in 2 dogs.

Despite favorable clinical responses to posaconazole, most dogs died or were euthanized because of recurrence of clinical signs before or after the posaconazole was discontinued. Therefore, despite appearing to have achieved clinical remission or clinical improvement infection was not entirely eliminated in most dogs. Reasons for this outcome are likely to be multifactorial, but may relate to the following: high prevalence of urinary tract involvement, single agent antifungal treatment in most cases, inadequate treatment duration, lack of objective measures to determine when discontinuation of treatment was appropriate, host immune factors, and ineffective posaconazole concentrations at required sites.

In our study, all 10 dogs had some form of urinary tract involvement, which may have been a factor in the reported treatment outcomes. Urinary tract involvement, specifically pyelonephritis, is common in dogs with disseminated aspergillosis.² Studies in humans have indicated that posaconazole does not concentrate as an active metabolite in the urine, but appears to produce adequate tissue concentrations in the renal parenchyma.³³ Therefore, urinary tract involvement outside the renal parenchyma may be difficult to cure because of inadequate concentration of active metabolite in the renal pelvis.

The dog that survived >5 years received a combination of posaconazole, terbinafine, and amoxicillin-clavulanic acid, experienced clinical remission during treatment, was a GSD, and did not relapse at any point. Whether this dog had a less severe form of disease, did better because treatment was continued long term, or if combination treatment was more effective, is unknown. No other dogs in this study received combination treatment during the course of posaconazole treatment. Terbinafine has been shown to have potent

in vitro activity against several species of *Aspergillus*, including *A. terreus*.^{34–36} Terbinafine has fungicidal effects,³⁵ and may be synergistic when given in combination with posaconazole or other azoles, because the drugs have complementary targets within fungal cells.³⁶

The duration of treatment required to eliminate the organism in dogs with disseminated aspergillosis could not be determined from the results of this study. As evidenced by the high rate of relapse during and after discontinuation of treatment, it is unlikely that the organism was eliminated in the majority of dogs in our study. It is likely that cure is not possible without an effective immune response. The innate immune system plays a primary role in defence against *Aspergillus* infections.³⁷ German shepherd dogs with aspergillosis are commonly reported in the veterinary literature, a finding that was previously attributed to a defect in mucosal immunity.^{38–40} Recent research in human medicine has identified a correlation between a mutation in the gene for Toll-like receptor-4 to the risk of invasive aspergillosis in immunocompromised people.^{37,41,42} Interestingly, in our study, the dog that lived longest and all of the dogs that lived >1 year were GSDs. Based on our study and previous studies of disseminated aspergillosis, recurrence of clinical signs, re-infection with the same or different species of fungus or both are common once antifungal drugs have been discontinued.^{6–8,43} It therefore may be beneficial to continue treatment long term, as long as the patient is adequately responding to and tolerating medical treatment, because an effective immune response may be lacking.

No objective measures are available to determine when treatment can reasonably be discontinued in dogs with disseminated aspergillosis. Urine *Blastomyces* antigen testing has been shown to be highly specific for clinical relapse of blastomycosis in dogs, and currently is used when treatment discontinuation is being considered.⁴⁴ The *Aspergillus* GMA enzyme-linked immunosorbent assay in serum and urine was both sensitive and specific in the adjunctive diagnosis of disseminated aspergillosis in dogs when a cut-off GMA index of ≥ 1.5 was used.⁴⁵ In our study, a negative urine culture was used as an objective indicator to guide discontinuation of treatment. However, this diagnostic test may not be the best objective assessment of remission of disease. In 1 study, urine cultures were only positive in 52% of dogs with disseminated aspergillosis, and it is unknown how a negative urine culture correlates with clinical remission.²

Serum samples were available from 2 dogs for serial follow-up GMA index measurements. The first dog lived >5 years and essentially was cured; the data correspond well with the dog's excellent clinical response. The second dog had positive GMA index results at every time point, despite experiencing clinical remission during treatment. The latter dog experienced relapse after the drug was discontinued, whereas the former did not. In humans with systemic aspergillosis, decreasing GMA index results have been shown to correlate with improved survival.^{46,47} The value of the *Aspergillus*

GMA index to objectively assess treatment response cannot be determined from 2 dogs, and therefore warrants further investigation.

Measurements of serum posaconazole concentrations in 2 dogs were $>3 \mu\text{g/mL}$ at the 30-day time point. The threshold posaconazole concentration associated with clinical efficacy in dogs or humans currently is unknown.⁴⁸ However, evidence from human medicine suggests that plasma drug concentration monitoring may play an important role in optimizing the efficacy of posaconazole in people with or at risk for invasive aspergillosis.¹¹ In 1 study of invasive aspergillosis, improved efficacy of the drug occurred with higher plasma posaconazole concentrations, with a median concentration of $1.25 \mu\text{g/mL}$ in patients with the best response rates.⁴⁹

One dog in our study was culture-positive for *A. fumigatus*. This species typically is associated with sino-nasal disease in dogs.⁵⁰ The species that were identified in our study were based on laboratory reports. Morphologic identification methods are known to have potential inaccuracies regarding species identification, which could explain the report of *A. fumigatus* in this case.⁵¹ Recent advances in mycology have improved the ability of laboratories to more accurately identify various species of *Aspergillus* and other fungi.⁵²

Limitations of this study include the small number of cases, the lack of complete follow-up data and imaging studies for all dogs, reliance mainly on clinical signs and urine culture to guide treatment decisions, and the fact that several different clinicians treated the dogs. Only the posaconazole was free for the owners, and financial constraints may have been an important factor precluding ideal follow-up imaging and other tests to more objectively determine response to treatment for all dogs. Posaconazole currently is an expensive drug; the current cost for treating a large breed dog is approximately \$100 USD per day. The cost is expected to decrease when the patent for the drug expires. Despite these limitations, clinically relevant conclusions can be drawn from the results.

In conclusion, our study indicates that posaconazole administered at a dosage of 5 mg/kg PO q12h appears to be safe for prolonged treatment of disseminated *Aspergillus* infections in dogs. Survival times of >1 year with good quality of life were documented in 4 dogs, including 1 dog with a survival time of >5 years that was treated concurrently with terbinafine. Unfortunately, relapse was a common occurrence, and most dogs died or were euthanized because of progressive disease either during the course of treatment or in the follow-up period. Posaconazole should be considered as an option for treatment of disseminated aspergillosis in dogs. Additional prospective studies are warranted to corroborate and expand upon these findings. Future studies also are indicated to determine whether *Aspergillus* GMA results can be used to assess treatment response, clinical relapse, or cure in dogs with disseminated aspergillosis and whether combination treatment of posaconazole with terbinafine may be more effective for long-term control of disease.

Footnotes

- ^a Noxafil (Posaconazole) oral suspension 40 mg/mL, Merck & Co., Inc., Whitehouse Station, NJ
^b Platelia Aspergillus, MiraVista Laboratories, Indianapolis, IN
^c MiraVista Diagnostics, Indianapolis IN
^d Fungus Testing Lab, University of Texas Health Science Center at San Antonio, San Antonio TX
-

Acknowledgments

The authors thank all of the clinicians (Dr Robert Presley, Dr Marc Seitz, Dr Bruce Sullivan, Dr Dominique Paquette, Dr Gary Block, Dr Caitrine Hellenga, Dr Candace Carter, and Dr Ashley Bensfield) and their technicians and staff who cared for these dogs and collected the study data, and UTCVM technicians Gina Galyon and Tammy Moyers. Special thanks to Merck & Co., Inc. (formerly Schering-Plough) for supplying the posaconazole for the study.

Conflict of Interest Declaration: Authors disclose no conflict of interest.

Off-Label Antimicrobial Declaration: Authors declare no off-label use of antimicrobials.

References

- Day MJ. Canine disseminated aspergillosis. In: Greene C, ed. Infectious Diseases of the Dog and Cat, 3rd ed. St. Louis, MO: Saunders Elsevier; 2006:620–626.
- Schultz RM, Johnson EG, Wisner ER, et al. Clinicopathologic and diagnostic imaging characteristics of systemic aspergillosis in 30 dogs. *J Vet Intern Med* 2008;22:851–859.
- Walsh TJ, Petraitis V, Petraitiene R, et al. Experimental pulmonary aspergillosis due to *Aspergillus terreus*: Pathogenesis and treatment of an emerging fungal pathogen resistant to amphotericin B. *J Infect Dis* 2003;188:305–319.
- Graybill JR, Hernandez S, Bocanegra R, et al. Antifungal therapy of murine *Aspergillus terreus* infection. *Antimicrob Agents Chemother* 2004;48:3715–3719.
- Groll AH, Walsh TJ. Antifungal efficacy and pharmacodynamics of posaconazole in experimental models of invasive fungal infections. *Mycoses* 2006;49(Suppl 1):7–16.
- Kelly SE, Shaw SE, Clark WT. Long-term survival of four dogs with disseminated *Aspergillus terreus* infection treated with itraconazole. *Aust Vet J* 1995;72:311–313.
- Bruchim Y, Elad D, Klainbart S. Disseminated aspergillosis in two dogs in Israel. *Mycoses* 2006;49:130–133.
- Burrough E, Deitz K, Kinyon J, et al. Disseminated aspergillosis in a dog due to *Aspergillus alabamensis*. *Med Mycol Case Rep* 2012;1:1–4.
- Robinson WF, Connole MD, King TJ, et al. Systemic mycosis due to *Aspergillus deftectus* in a dog. *Aust Vet J* 2000;78:600–602.
- Walker JT, Frazho JK, Randell SC. A novel case of canine disseminated aspergillosis following mating. *Can Vet J* 2012;53:190–192.
- Walsh TJ, Anaissie EJ, Denning DW, et al. Treatment of aspergillosis: Clinical practice guidelines of the Infectious Diseases Society of America. *Clin Infect Dis* 2008;46:327–360.
- Maertens J, Raad I, Petrikos G, et al. Efficacy and safety of caspofungin for treatment of invasive aspergillosis in patients refractory to or intolerant of conventional antifungal therapy. *Clin Infect Dis* 2004;39:1563–1571.
- Maertens J, Glasmacher A, Herbrecht R, et al. Multicenter, noncomparative study of caspofungin in combination with other antifungals as salvage therapy in adults with invasive aspergillosis. *Cancer* 2006;107:2888–2897.
- Schiraldi GF, Cicero SL, Colombo MD, et al. Refractory pulmonary aspergillosis: Compassionate trial with terbinafine. *Br J Dermatol* 1996;134(Suppl 46):25–29 discussion 39–40.
- Hector RF. An overview of antifungal drugs and their use for treatment of deep and superficial mycoses in animals. *Clin Tech Small Anim Pract* 2005;20:240–249.
- Smith LN, Hoffman SB. A case series of unilateral orbital aspergillosis in three cats and treatment with voriconazole. *Vet Ophthalmol* 2010;13:190–203.
- Greer ND. Posaconazole (Noxafil): A new triazole antifungal agent. *Proc (Bayl Univ Med Cent)* 2007;20:188–196.
- Nagappan V, Deresinski S. Reviews of anti-infective agents: Posaconazole: A broad-spectrum triazole antifungal agent. *Clin Infect Dis* 2007;45:1610–1617.
- Herbrecht R. Posaconazole: A potent, extended-spectrum triazole anti-fungal for the treatment of serious fungal infections. *Int J Clin Pract* 2004;58:612–624.
- Diekema DJ, Messer SA, Hollis RJ, et al. Activities of caspofungin, itraconazole, posaconazole, ravuconazole, voriconazole, and amphotericin B against 448 recent clinical isolates of filamentous fungi. *J Clin Microbiol* 2003;41:3623–3626.
- Pfaller MA, Messer SA, Hollis RJ, et al. Antifungal activities of posaconazole, ravuconazole, and voriconazole compared to those of itraconazole and amphotericin B against 239 clinical isolates of *Aspergillus* spp. and other filamentous fungi: Report from SENTRY Antimicrobial Surveillance Program, 2000. *Antimicrob Agents Chemother* 2002;46:1032–1037.
- Hachem R, Raad I, Afif C, et al. An open, non-comparative multicenter study to evaluate efficacy and safety of posaconazole (SCH 56592) in the treatment of invasive fungal infections refractory to or intolerant of standard therapy. 40th Interscience Conference on Antimicrobial Agents and Chemotherapy 2000.
- Sabatelli F, Patel R, Mann PA, et al. In vitro activities of posaconazole, fluconazole, itraconazole, voriconazole, and amphotericin B against a large collection of clinically important molds and yeasts. *Antimicrob Agents Chemother* 2006;50:2009–2015.
- Courtney R, Wexler D, Radwanski E, et al. Effect of food on the relative bioavailability of two oral formulations of posaconazole in healthy adults. *Br J Clin Pharmacol* 2004;57:218–222.
- Ezzet F, Wexler D, Courtney R, et al. Oral bioavailability of posaconazole in fasted healthy subjects: Comparison between three regimens and basis for clinical dosage recommendations. *Clin Pharmacokinet* 2005;44:211–220.
- Courtney R, Radwanski E, Lim J, et al. Pharmacokinetics of posaconazole coadministered with antacid in fasting or nonfasting healthy men. *Antimicrob Agents Chemother* 2004;48:804–808.
- Nomeir AA, Kumari P, Hilbert MJ, et al. Pharmacokinetics of SCH 56592, a new azole broad-spectrum antifungal agent, in mice, rats, rabbits, dogs, and cynomolgus monkeys. *Antimicrob Agents Chemother* 2000;44:727–731.
- Li Y, Theuretzbacher U, Clancy CJ, et al. Pharmacokinetic/pharmacodynamic profile of posaconazole. *Clin Pharmacokinet* 2010;49:379–396.
- Noxafil® (posaconazole). Prescribing information. Whitehouse Station, NJ, USA: Merck & Co., Inc.; 2014.
- Cartwright ME, Petruska J, Arezzo J, et al. Phospholipidosis in neurons caused by posaconazole, without evidence for functional neurologic effects. *Toxicol Pathol* 2009;37:902–910.

31. Raad II, Graybill JR, Bustamante AB, et al. Safety of long-term oral posaconazole use in the treatment of refractory invasive fungal infections. *Clin Infect Dis* 2006;42:1726–1734.
32. Courtney R, Sansone A, Smith W, et al. Posaconazole pharmacokinetics, safety, and tolerability in subjects with varying degrees of chronic renal disease. *J Clin Pharmacol* 2005;45:185–192.
33. Elizabeth Ashley SD, Lewis R, Lewis JS, et al. Pharmacology of systemic antifungal agents. *Clin Infect Dis* 2006;43:S28–S39.
34. Moore CB, Walls CM, Denning DW. In vitro activities of terbinafine against *Aspergillus* species in comparison with those of itraconazole and amphotericin B. *Antimicrob Agents Chemother* 2001;45:1882–1885.
35. Ryder NS. Terbinafine: Mode of action and properties of the squalene epoxidase inhibition. *Br J Dermatol* 1992;126(Suppl 39):2–7.
36. Mukherjee PK, Sheehan DJ, Hitchcock CA, et al. Combination treatment of invasive fungal infections. *Clin Microbiol Rev* 2005;18:163–194.
37. de Boer MG, Jolink H, Halkes CJ, et al. Influence of polymorphisms in innate immunity genes on susceptibility to invasive aspergillosis after stem cell transplantation. *PLoS One* 2011;6:e18403.
38. Day MJ, Eger CE, Shaw SE, et al. Immunologic study of systemic aspergillosis in German shepherd dogs. *Vet Immunol Immunopathol* 1985;9:335–347.
39. Day MJ, Penhale WJ. Humoral immunity in disseminated *Aspergillus terreus* infection in the dog. *Vet Microbiol* 1988;16:283–294.
40. Day MJ, Penhale WJ. Serum immunoglobulin A concentrations in normal and diseased dogs. *Res Vet Sci* 1988;45:360–363.
41. Bochud PY, Chien JW, Marr KA, et al. Toll-like receptor 4 polymorphisms and aspergillosis in stem-cell transplantation. *N Engl J Med* 2008;359:1766–1777.
42. Mercier E, Peters IR, Farnir F, et al. Assessment of Toll-like receptor 2, 4 and 9 SNP genotypes in canine sino-nasal aspergillosis. *BMC Vet Res* 2014;10:187.
43. Krockenberger MB, Swinney G, Martin P, et al. Sequential opportunistic infections in two German Shepherd dogs. *Aust Vet J* 2011;89:9–14.
44. Foy DS, Trepanier LA, Kirsch EJ, et al. Serum and urine blastomyces antigen concentrations as markers of clinical remission in dogs treated for systemic blastomycosis. *J Vet Intern Med* 2014;28:305–310.
45. Garcia RS, Wheat LJ, Cook AK, et al. Sensitivity and specificity of a blood and urine galactomannan antigen assay for diagnosis of systemic aspergillosis in dogs. *J Vet Intern Med* 2012;26:911–919.
46. Miceli MH, Graziutti ML, Woods G, et al. Strong correlation between serum aspergillus galactomannan index and outcome of aspergillosis in patients with hematological cancer: Clinical and research implications. *Clin Infect Dis* 2008;46:1412–1422.
47. Maertens J, Buve K, Theunissen K, et al. Galactomannan serves as a surrogate endpoint for outcome of pulmonary invasive aspergillosis in neutropenic hematology patients. *Cancer* 2009;115:355–362.
48. Wiederhold NP, Pennick GJ, Dorsey SA, et al. A reference laboratory experience of clinically achievable voriconazole, posaconazole, and itraconazole concentrations within the bloodstream and cerebral spinal fluid. *Antimicrob Agents Chemother* 2014;58:424–431.
49. Walsh TJ, Raad I, Patterson TF, et al. Treatment of invasive aspergillosis with posaconazole in patients who are refractory to or intolerant of conventional therapy: An externally controlled trial. *Clin Infect Dis* 2007;44:2–12.
50. Matthews KGSN. Canine nasal aspergillosis–penicilliosis. In: Greene C, ed. *Infectious Diseases of the Dog and Cat*, 3rd ed. St. Louis, MO: Saunders Elsevier; 2006:613–620.
51. Balajee SA, Houbraken J, Verweij PE, et al. *Aspergillus* species identification in the clinical setting. *Stud Mycol* 2007;59:39–46.
52. Balajee SA, Borman AM, Brandt ME, et al. Sequence-based identification of *Aspergillus*, *fusarium*, and *mucorales* species in the clinical mycology laboratory: Where are we and where should we go from here? *J Clin Microbiol* 2009;47:877–884.

Supporting Information

Additional Supporting Information may be found online in Supporting Information:

Table S1. Patient characteristics and clinical data at time of entrance into study.

Table S2. Summarized patient treatment data.