

# Percutaneous Glycerol Rhizotomy for Trigeminal Neuralgia Using a Single-Plane, Flat Panel Detector Angiography System: Technical Note

Hidetaka ARISHIMA,<sup>1</sup> Satoshi KAWAJIRI,<sup>1</sup> Hiroshi ARAI,<sup>1</sup> Yoshifumi HIGASHINO,<sup>1</sup> Toshiaki KODERA,<sup>1</sup> and Ken-ichiro KIKUTA<sup>1</sup>

<sup>1</sup>Department of Neurosurgery, University of Fukui, Yoshida-gun, Fukui

## Abstract

Percutaneous treatments for trigeminal neuralgia (TN) including glycerol rhizotomy (GR), radiofrequency thermocoagulation (RT), and balloon compression (BC) are effective for patients with medical comorbidities and risk factors of microvascular decompression (MVD). These procedures are usually performed under fluoroscopy. Surgeons advance the needle to the trigeminal plexus through the foramen ovale while observing landmarks of fluoroscopic images; however, it is sometimes difficult to appropriately place the needle tip in Meckel's cave. We present the technical details of percutaneous GR using a single-plane, flat panel detector angiography system to check the needle positioning. When the needle tip may be located near the trigeminal cistern, three-dimensional (3-D) bone images are taken with cone-beam computed tomography (CT). These images clearly show the position of the needle tip in Meckel's cave. If it is difficult to place it through the foramen ovale, surgeons perform cone beam CT to observe the actual position of the needle tip at the skull base. After confirming the positional relation between the needle tip and foramen ovale, surgeons can advance it in the precise direction. In 10 procedures, we could place the nerve-block needle in about 14.5 minutes on average without complications. We think that our method is simple and convenient for percutaneous treatments for TN, and it may be helpful for surgeons to perform such treatments.

Key words: angiography system, cone-beam computed tomography, glycerol rhizotomy, trigeminal neuralgia

## Introduction

Although microvascular decompression (MVD) for trigeminal neuralgia (TN) has been reported as an effective treatment modality,<sup>1–3)</sup> percutaneous treatments including glycerol rhizotomy (GR),<sup>4–9)</sup> radiofrequency thermocoagulation (RT),<sup>10–12)</sup> and balloon compression (BC)<sup>7,13–16)</sup> are also useful for patients with severe TN. These percutaneous treatments are helpful for patients who have medical comorbidities and risk factors of MVD, and are especially suitable for the advanced elderly.<sup>5)</sup> The most important point in percutaneous treatments is to insert the nerve-block needle into the foramen ovale and place it in the trigeminal cistern accurately and safely. Traditionally, they are performed with a conventional fluoroscopy system.<sup>17–19)</sup> The foramen ovale can be seen with an anteroposterior oblique (APO) view, and surgeons speculate on the location of the needle tip with

lateral X-ray views as two-dimensional (2-D) images. The junction of the posterior clivus and petrous bone is known to be near Meckel's cave; however, surgeons cannot precisely confirm the actual position of the needle tip. It is sometimes difficult to detect the foramen ovale even with an APO view. Surgeons need extensive experience to perform this procedure, and sometimes require a number of trials, which may cause some serious complications.<sup>6,20–25)</sup>

Some authors reported RT using computed tomography (CT) fluoroscopy to clearly show the real-time position of the nerve-block needle going to the foramen ovale.<sup>26–29)</sup> Neuronavigator-guided percutaneous RT has also been reported as a modern technique.<sup>30–32)</sup> Current techniques make percutaneous treatments accurate and safe. Here, we describe the technical details of GR using a single-plane, flat panel detector angiography system with cone-beam CT, which is used for examinations and endovascular treatment of cerebrovascular disease.

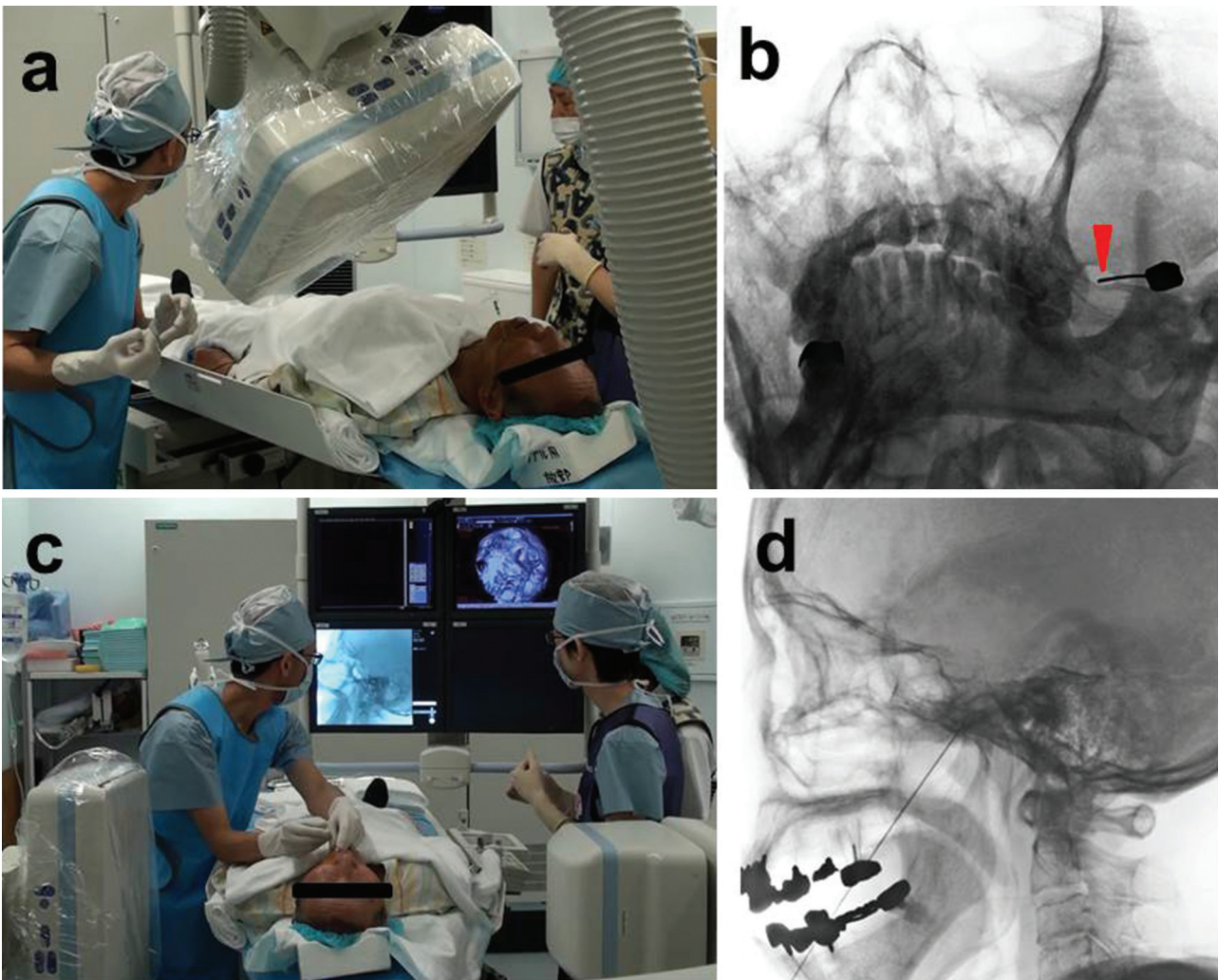
Received November 19, 2015; Accepted February 25, 2016

## Materials and Methods

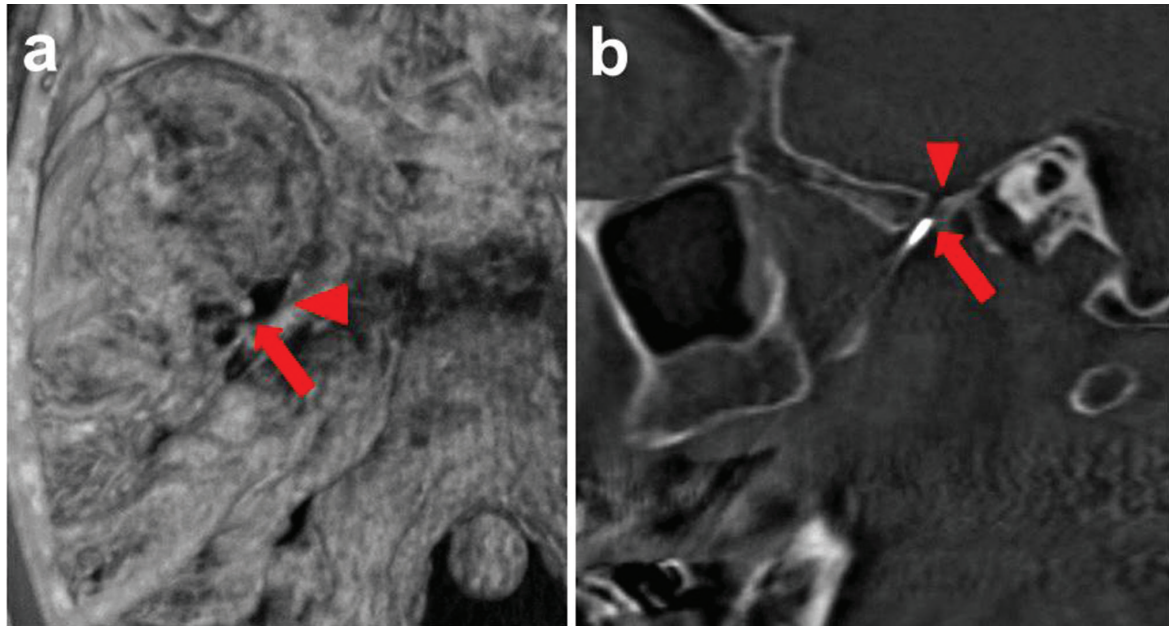
The patient is placed in a supine position with mild retroflexion on the bed of a single-plane angiography system (AXIOM Artis dFA; Siemens, Germany) under conscious sedation using diazepam or pentazocine (Fig. 1a). Vital sign monitors including an electrocardiogram, blood pressure monitor, and pulse oximetry are always set to observe bradycardia and hypotension arising from the trigeminal depressor response. After local anesthesia, the procedure is performed according to Hartel's technique.<sup>17–19)</sup> A 22 G nerve-block needle is inserted at 2.5–3 cm lateral to the labial commissure, and it should be advanced toward a coronal landmark (the floor of the orbita

under the ipsilateral pupil) and a sagittal landmark (3.5 cm anterior to the tragus at the lower border of the zygoma). According to these landmarks, surgeons advance the needle tip while conforming the foramen ovale with an APO view (Fig. 1a, b), and the junction of the posterior clivus and petrous bone with a lateral view (Fig. 1c, d) under fluoroscopy.

So far, our method is the same as the traditional method using conventional fluoroscopy; however, a flat panel detector angiography system can perform 2- and 3-D bone imaging by cone-beam CT. When the needle tip seems to be directed though the foramen ovale to the trigeminal cistern, we stop advancing the needle and perform cone-beam CT which immediately shows 2- and 3-D images of



**Fig. 1** a: Intraoperative photograph showing the position of a patient and a single-plane angiography system with an anteroposterior oblique (APO) view to see the foramen ovale. b: APO fluoroscopic image showing the foramen ovale (*arrowhead*) and the needle tip going toward the foramen ovale. c: Intraoperative photograph showing an operator observing a lateral fluoroscopic image and advancing the needle. d: Lateral fluoroscopic image showing the needle tip going toward the junction of the posterior clivus and petrous bone.



**Fig. 2** a: Three-dimensional bone image of cone-beam computed tomography (CT) showing the needle tip near Meckel's cave. b: Two-dimensional bone imaging of cone-beam CT showing the needle tip remaining in the foramen ovale, and not in Meckel's cave.

the needle position. The needle tip in the foramen ovale means that it is not located in the trigeminal cistern (Fig. 2a, b). The needle tip on the outside of Meckel's cave means that it may be near the third-division in the trigeminal plexus (Fig. 3a), the needle tip in the center may be in the second-division (Fig. 3b), and the needle tip on the inside may be near the first-division (Fig. 3c).

If it is difficult to advance the needle tip through the foramen ovale, numerous trials should not be performed blindly for a long time. Cone-beam CT should be conducted to check for inappropriate positioning of the needle (Fig. 4a, b). Surgeons can understand where the needle tip is located and should be advanced. After confirming the positional relation between the needle tip and foramen ovale, the needle can be advanced in the precise direction. Finally, the needle tip can be placed in Meckel's cave and 3-D images should be taken again to verify the correct location of the needle tip. To confirm that the needle tip is in the trigeminal cistern, we always perform trigeminal cisternography after cone-beam CT. Glycerol (from 0.2 ml to 0.4 ml) is injected with the patients in a seated position, and they remain in the same position for 2 hours.<sup>4-9)</sup>

We obtained written informed consent from the patient who is shown in Fig. 1 of this article, and sent the written informed consent form to the Neurologia medico-chirurgica editorial office.

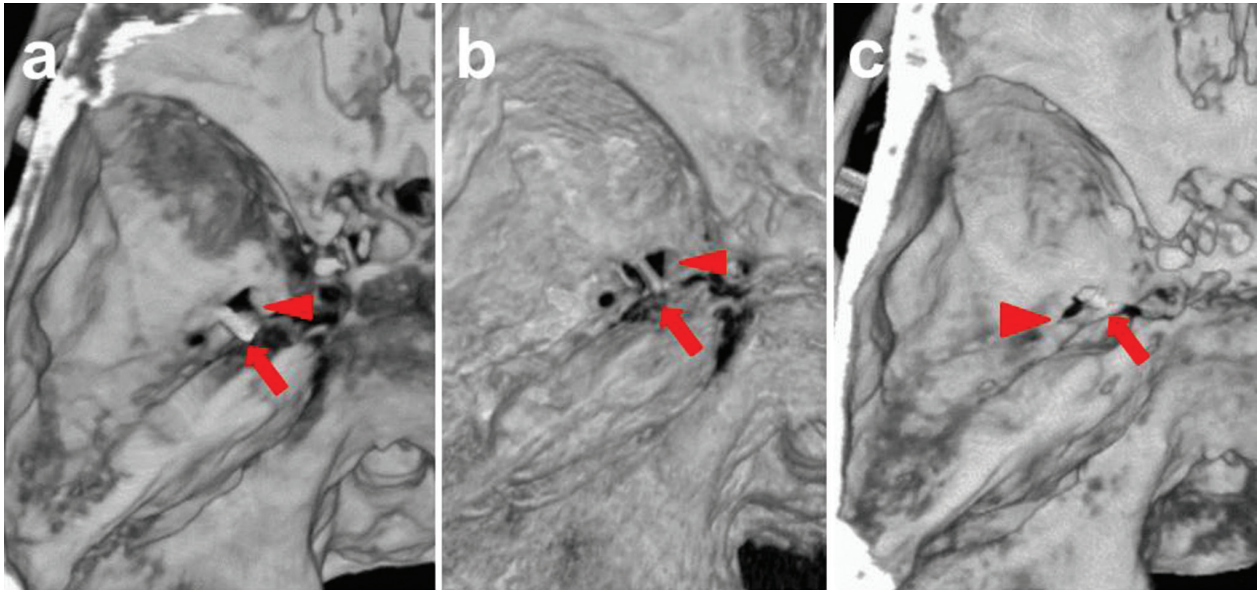
## Results

Between July 2013 and September 2015, we conducted 10 procedures for seven patients with idiopathic TN who desired to undergo GR (Table 1). Preoperatively, we explained about surgical treatments of MVD, Gamma Knife radiosurgery (GKR), and GR, and all patients with intolerable pain desired GR. Seven procedures required cone beam CT once, and three procedures required it twice. The average time from the puncture to confirmation of the needle position with 3-D CT images was 14.5 minutes. All procedures needed only one trigeminal cisternography showing the needle tip in the trigeminal cistern. Except for three cases who could not take medicine because of allergy to carbamazepine (No. 5) and renal failure (Nos. 7 and 8), the other seven cases needed no medicine postoperatively. All patients achieved initial pain relief without complications associated with this method.

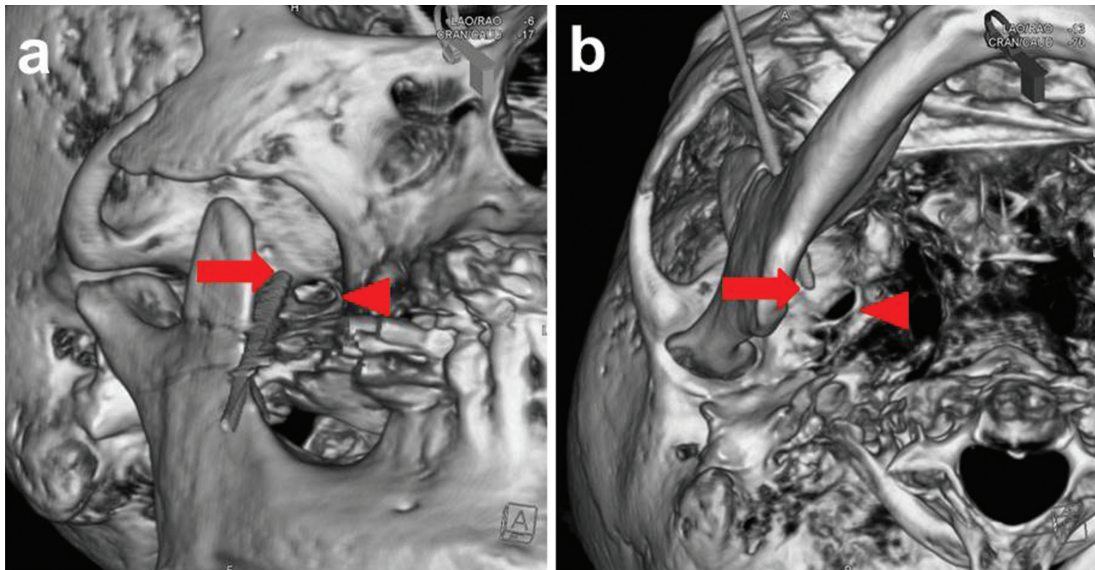
## Discussion

The percutaneous treatments including GR, RT, and BC have been shown to provide effective pain relief following injury to pain fibers in the trigeminal nerve. According to previous reports,<sup>5)</sup> these techniques provided similar effective pain relief: pain control rates up to 90% at 6 months and about 60% at 3 years. Commonly reported complications





**Fig. 3** a: A 3-D (three-dimensional) bone imaging of cone-beam computed tomography (CT) showing the needle tip (*arrow*) outside of Meckel's cave (*arrowhead*), which suggests that the needle tip may be near the third-division in the trigeminal plexus. b: A 3-D bone imaging of cone-beam CT showing the needle tip (*arrow*) in the center of Meckel's cave (*arrowhead*), which suggests that the needle tip may be near the second-division in the trigeminal plexus. c: A 3-D bone imaging of cone-beam CT showing the needle tip (*arrow*) inside of Meckel's cave (*arrowhead*), which suggests that the needle tip may be near the first-division in the trigeminal plexus.



**Fig. 4** a, b: Three-dimensional bone imagings of cone-beam computed tomography showing the needle tip (*arrows*) remaining at the anterolateral edge of the foramen ovale (*arrowheads*).

of these percutaneous treatments include dysesthesia (average, 8.3% in GR), masseter weakness (average, 3.1% in GR), and corneal numbness (average, 8.1% in GR); however, these side effects seem to be acceptable for patients with intolerable pain. Neuropathic pain has not been reported secondary

to these percutaneous treatments. Although most patients in our cases complained of pain during the glycerol injection, this symptom seems to be correlated with a good pain outcome in GR. Recurrence rates are diverse: up to 35% within 5 years in the previous review of GR. Although RT seems

**Table 1** Summary of glycerol rhizotomy for trigeminal neuralgia using angiography system

Procedures (No.)	Offending trigeminal division	Time from puncture to 3-D CT (minutes)	Frequency of 3-D CT	Medication		Initial pain relief
				Before GR	After GR	
1	V2.3	14	1	CBZ 400 mg	no	satisfactory
2	V2.3	26	2	CBZ 400 mg	no	satisfactory
3	V2.3	11	1	CBZ 400 mg	no	satisfactory
4	V1.2	12	1	CBZ 600 mg	no	satisfactory
5	V2	15	2	no (drug allergy)		satisfactory
6	V2.3	9	1	GBP 800 mg	no	satisfactory
7	V2.3	26	2	no (renal failure)		satisfactory
8	V2.3	7	1	no (renal failure)		satisfactory
9	V2	10	1	CBZ 600 mg	no	satisfactory
10	V2	15	1	CBZ 400 mg	no	satisfactory

CBZ: carbamazepine, GBP: gabapentin, GR: glycerol rhizotomy, No.: number, 3-D CT: 3-dimensional computed tomography.

to show a slightly better result compared with the two other procedures, we have performed GR as a percutaneous treatment for TN because we do not have instruments and materials for RF. GKR also demonstrates good pain control rates of 50–75% at 5 years.<sup>5)</sup> This noninvasive approach is not covered by insurance in Japan, being one of the reasons why patients did not desire GKR in this study.

During percutaneous procedures, inserting the needle into the foramen ovale and placing it at Meckel's cave is a key procedure. According to the traditional technique,<sup>17–19)</sup> the surgeons speculate on the position of the needle tip based on fluoroscopic images. Conventional C-arm fluoroscopy is usually conducted. The foramen ovale can be seen with an APO view; however, it cannot always be seen clearly. When the needle tip is located at the junction of the clivus and petrous bone with a lateral view, this suggests that the needle tip may have been inserted though the foramen ovale; however, surgeons cannot confirm the actual location of the needle tip. Numerous trials of inadequate punctures may cause not only anxiety during operations but also facial pain and postoperative hematoma. Some serious complications were rarely reported as injuries of the superior or inferior orbital fissure, carotid artery, cavernous sinus, and jugular foramen which caused blindness, abducens nerve palsy, or carotid-cavernous fistula.<sup>21,22,25)</sup> Moreover, subdural, subarachnoid, and intracranial hemorrhage have been reported.<sup>20,23,25)</sup> Sindou et al. described 10 false punctures in 200 procedures based on their abundant experience: 2 in the carotid artery canal, 1 in the jugular foramen, and 7 in the sphenoidal emissary foramen.<sup>24)</sup>

To prevent these complications, new techniques of percutaneous treatments for TN have been reported. Some authors reported RT guided by high-speed real-time CT fluoroscopy.<sup>26–29)</sup> These techniques show the foramen ovale and nerve-block needle with 2- and 3-D images during operations. CT-guided percutaneous procedures can be used to precisely advance the needle tip to the trigeminal cistern. Recently, percutaneous treatments guided by neuronavigation and, moreover, CT with neuronavigation have been reported.<sup>30–32)</sup> These procedures are also ideal, and surgeons can obtain visual-spatial information.

Angiography systems with a flat panel detector are necessary for intervention therapy of neurosurgery, cardiovascular surgery, and medicine. We use this system for percutaneous treatments for TN instead of the conventional C-arm which usually is equipped with an image intensifier system. Compared with the conventional C-arm, an angiography system with a flat panel detector has advantages of not only reducing radiation exposure and improving image quality,<sup>33–35)</sup> but also provides the function of CT-like 3-D imaging using cone-beam CT.<sup>36)</sup> Surgeons can immediately check the position of the needle during procedures. Our procedure also has other advantages. Because neurosurgeons usually use angiography systems in their daily work, they can use them skillfully. We think that our method is convenient and useful for percutaneous treatments, including RT and BC. Although we had little experience of percutaneous treatments, with 10 procedures in 26 months, we could finish in about 14.5 minutes on average without complications. This simple technique will provide another therapeutic option for neurosurgeons treating TN.

Radiation exposure is the most significant problem regarding this procedure. Although the reduced radiation exposure from a flat panel detector is less than that using an image intensifier system,<sup>33–35)</sup> surgeons should perform cone-beam CT once or twice during operations. In our experience, this procedure is completed in 14.5 minutes on average; therefore, radiation exposure may be less than that with routine angiographical examinations.

### Conflicts of Interest Disclosure

The authors have no conflicts of interest (COI). All authors who are members of The Japan Neurosurgical Society (JNS) have registered online Self-reported COI Disclosure Statement Forms through the website for JNS members.

### References

- 1) Cohen-Gadol AA: Microvascular decompression surgery for trigeminal neuralgia and hemifacial spasm: nuances of the technique based on experiences with 100 patients and review of the literature. *Clin Neurol Neurosurg* 113: 844–853, 2011
- 2) Kondo A: Follow-up results of microvascular decompression in trigeminal neuralgia and hemifacial spasm. *Neurosurgery* 40: 46–51, discussion 51–52, 1997
- 3) Jannetta PJ, Rand RW: Transtentorial retrogasserian rhizotomy in trigeminal neuralgia by microneurosurgical technique. *Bull Los Angeles Neurol Soc* 31: 93–99, 1966
- 4) Bennett MH, Lunsford LD: Percutaneous retrogasserian glycerol rhizotomy for tic douloureux: Part 2. Results and implications of trigeminal evoked potential studies. *Neurosurgery* 14: 431–435, 1984
- 5) Cheng JS, Lim DA, Chang EF, Barbaro NM: A review of percutaneous treatments for trigeminal neuralgia. *Neurosurgery* 10(Suppl 1): 25–33; discussion 33, 2014
- 6) Håkanson S: Trigeminal neuralgia treated by the injection of glycerol into the trigeminal cistern. *Neurosurgery* 9: 638–646, 1981
- 7) Kouzounias K, Lind G, Schechtmann G, Winter J, Linderoth B: Comparison of percutaneous balloon compression and glycerol rhizotomy for the treatment of trigeminal neuralgia. *J Neurosurg* 113: 486–492, 2010
- 8) Lunsford LD, Bennett MH: Percutaneous retrogasserian glycerol rhizotomy for tic douloureux: Part 1. Technique and results in 112 patients. *Neurosurgery* 14: 424–430, 1984
- 9) Pollock BE: Percutaneous retrogasserian glycerol rhizotomy for patients with idiopathic trigeminal neuralgia: a prospective analysis of factors related to pain relief. *J Neurosurg* 102: 223–228, 2005
- 10) Latchaw JP Jr, Hardy RW Jr, Forsythe SB, Cook AF: Trigeminal neuralgia treated by radiofrequency coagulation. *J Neurosurg* 59: 479–484, 1983
- 11) Sweet WG: Proceedings: analgesia dolorosa after differential retrogasserian thermal or mechanical rhizotomy: tactics employed to decrease its influence. *J Neurol Neurosurg Psychiatry* 38: 407, 1975
- 12) Taha JM, Tew JM Jr, Buncher CR: A prospective 15-year follow up of 154 consecutive patients with trigeminal neuralgia treated by percutaneous stereotactic radiofrequency thermal rhizotomy. *J Neurosurg* 83: 989–993, 1995
- 13) Goerss SJ, Atkinson JL, Kallmes DF: Variable size percutaneous balloon compression of the gasserian ganglion for trigeminal neuralgia. *Surg Neurol* 71: 388–390, discussion 391, 2009
- 14) Lee ST, Chen JF: Percutaneous trigeminal ganglion balloon compression for treatment of trigeminal neuralgia, part II: results related to compression duration. *Surg Neurol* 60: 149–153; discussion 153–154, 2003
- 15) Lichtor T, Mullan JF: A 10-year follow-up review of percutaneous microcompression of the trigeminal ganglion. *J Neurosurg* 72: 49–54, 1990
- 16) Skirving DJ, Dan NG: A 20-year review of percutaneous balloon compression of the trigeminal ganglion. *J Neurosurg* 94: 913–917, 2001
- 17) Härtel F: Die Leitungsanästhesie und Injektionsbehandlung des Ganglion Gasseri und der Trigeminiusstämme. *Arch Klin Chir* 100: 193–292, 1912 (German)
- 18) Hori T: [Percutaneous Gasserian ganglion thermocoagulation]. *No Shinkei Geka* 10: 923–930, 1982 (Japanese)
- 19) Sweet WH, Wepsic JG: Controlled thermocoagulation of trigeminal ganglion and rootlets for differential destruction of pain fibers. 1. Trigeminal neuralgia. *J Neurosurg* 40: 143–156, 1974
- 20) Arrese I, Lobato RD, Alén JF, Lagares A, Miranda P: Acute subdural and intratemporal hematoma as a complication of percutaneous compression of the gasserian ganglion for trigeminal neuralgia. *Neurocirugia (Astur)* 16: 177–182, 2005
- 21) Egan RA, Pless M, Shults WT: Monocular blindness as a complication of trigeminal radiofrequency rhizotomy. *Am J Ophthalmol* 131: 237–240, 2001
- 22) Harrigan MR, Chandler WF: Abducens nerve palsy after radiofrequency rhizolysis for trigeminal neuralgia: case report. *Neurosurgery* 43: 623–625, 1998
- 23) Savas A, Sayin M: Subarachnoid bleeding into the superior cerebellopontine cistern after radiofrequency trigeminal rhizotomy: case report. *Acta Neurochir (Wien)* 152: 561–562, 2010
- 24) Sindou M, Keravel Y, Abdennebi B, Szapiro J: [Neurosurgical treatment of trigeminal neuralgia. Direct approach of percutaneous method?]. *Neurochirurgie* 33: 89–111, 1987 (French)
- 25) Tatli M, Satici O, Kanpolat Y, Sindou M: Various surgical modalities for trigeminal neuralgia: literature study of respective long-term outcomes. *Acta Neurochir (Wien)* 150: 243–255, 2008
- 26) Gusmão S, Oliveira M, Tazinaffo U, Honey CR: Percutaneous trigeminal nerve radiofrequency rhizotomy



- guided by computerized tomography fluoroscopy. Technical note. *J Neurosurg* 99: 785–786, 2003
- 27) Koizuka S, Saito S, Sekimoto K, Tobe M, Obata H, Koyama Y: Percutaneous radio-frequency thermo-coagulation of the Gasserian ganglion guided by high-speed real-time CT fluoroscopy. *Neuroradiology* 51: 563–566, 2009
- 28) Koizuka S, Saito S, Tobe M, Sekimoto K, Obata H, Koyama Y: Technical communication: percutaneous radiofrequency mandibular nerve rhizotomy guided by high-speed real-time computed tomography fluoroscopy. *Anesth Analg* 111: 763–767, 2010
- 29) Sekimoto K, Koizuka S, Saito S, Goto F: Thermogangliolysis of the Gasserian ganglion under computed tomography fluoroscopy. *J Anesth* 19: 177–179, 2005
- 30) Xu SJ, Zhang WH, Chen T, Wu CY, Zhou MD: Neuro-navigator-guided percutaneous radiofrequency thermo-coagulation in the treatment of intractable trigeminal neuralgia. *Chin Med J (Engl)* 119: 1528–1535, 2006
- 31) Yang Y, Shao Y, Wang H, Liu Y, Zhu S, Wu C: Neuronavigation-assisted percutaneous radiofrequency thermocoagulation therapy in trigeminal neuralgia. *Clin J Pain* 23: 159–164, 2007
- 32) Zhang WC, Zhong WX, Li ST, Zheng XS, Yang M, Shi J: Neuronavigator-guided percutaneous radio-frequency thermocoagulation in the treatment of trigeminal neuralgia. *Ir J Med Sci* 181: 7–13, 2012
- 33) Suzuki S, Furui S, Kobayashi I, Yamauchi T, Kohtake H, Takeshita K, Takada K, Yamagishi M: Radiation dose to patients and radiologists during transcatheter arterial embolization: comparison of a digital flat-panel system and conventional unit. *AJR Am J Roentgenol* 185: 855–859, 2005
- 34) Geijer H, Beckman KW, Andersson T, Persliden J: Image quality vs. radiation dose for a flat-panel amorphous silicon detector: a phantom study. *Eur Radiol* 11: 1704–1709, 2001
- 35) Heran NS, Song JK, Namba K, Smith W, Niimi Y, Berenstein A: The utility of DynaCT in neuroendovascular procedures. *AJNR Am J Neuroradiol* 27: 330–332, 2006
- 36) Hiu T, Kitagawa N, Morikawa M, Hayashi K, Horie N, Morofuji Y, Suyama K, Nagata I: Efficacy of DynaCT digital angiography in the detection of the fistulous point of dural arteriovenous fistulas. *AJNR Am J Neuroradiol* 30: 487–491, 2009

---

Address reprint requests to: Hidetaka Arishima, MD, PhD, Department of Neurosurgery, University of Fukui, 23-3 Matsuokashimoaizuki, Eiheiji-cho, Yoshida-gun, Fukui, Fukui 910-1193, Japan.  
e-mail: ari@u-fukui.ac.jp