

Diverging Artifact in a Subcutaneous Abscess

CME
Credits

Wei-Ting Wu, Yu-Chun Hsu, Ke-Vin Chang*

Department of Physical Medicine and Rehabilitation, National Taiwan University Hospital, National Taiwan University College of Medicine, Taipei, Taiwan

SECTION 1 – QUIZ

A 60-year-old male had one painful, erythematous mass of the inferior abdominal wall for 3 months. He received a hernia repair surgery 1 year ago. Wound infection developed after the surgery, and an abscess was formed nearby. He received debridement, but there was only partial improvement. Under the impression of a residual abscess, ultrasound was arranged, revealing a hypoechoic lesion [Figure 1a] with peripheral hyperemia [Figure 1b]. A subcutaneous abscess with active inflammation was diagnosed. Furthermore, a hyperechoic structure was found in its center with diverging acoustic shadows [Figure 1c]. What is your impression about these findings in Figure 1c?

Declaration of patient consent

The authors certify that they have obtained all appropriate patient consent forms. In the form, the patient has given his consent for his images and other clinical information to be reported in the journal. The patient understands that his name and initials will not be published and due efforts will be made to conceal the identity, but anonymity cannot be guaranteed.

Financial support and sponsorship

Nil.

Conflicts of interest

Dr. Ke-Vin Chang, an editorial board member at *Journal of Medical Ultrasound*, had no role in the peer review process of or decision to publish this article. The other authors declared no conflicts of interest in writing this paper.

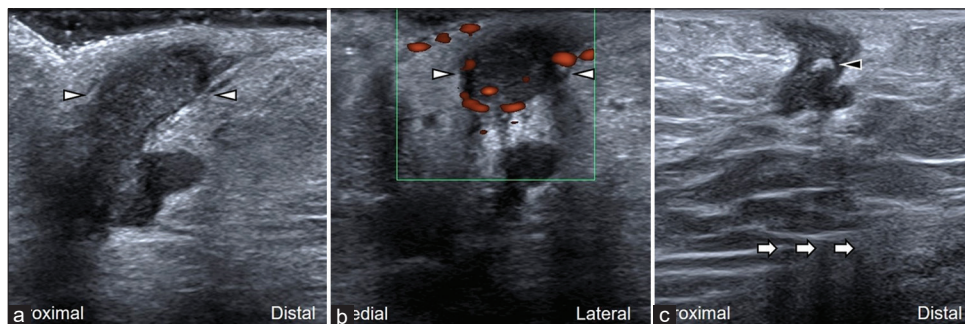


Figure 1: (a) The image was obtained by placing the transducer in the sagittal plane over the mass (arrowheads). (b) The image was obtained in the power Doppler mode showing hyperemia surrounding the mass. (c) The diverging artifacts (white arrows) behind the hyperechoic structure (black arrowhead) were observed

Received: 16-01-2021 Revised: 29-03-2021 Accepted: 14-04-2021 Available Online: 16-06-2021

Access this article online

Quick Response Code:



Website:
www.jmuonline.org

DOI:
10.4103/JMU.JMU_12_21

Address for correspondence:

Dr. Ke-Vin Chang,
Department of Physical Medicine and Rehabilitation, National Taiwan University Hospital, Bei-Hu Branch and National Taiwan University College of Medicine, No. 87 Neijiang Street, Wanhua District, Taipei City 108, Taiwan.
E-mail: kvchang011@gmail.com

This is an open access journal, and articles are distributed under the terms of the Creative Commons Attribution-NonCommercial-ShareAlike 4.0 License, which allows others to remix, tweak, and build upon the work non-commercially, as long as appropriate credit is given and the new creations are licensed under the identical terms.

For reprints contact: WKHLRPMedknow_reprints@wolterskluwer.com

How to cite this article: Wu WT, Hsu YC, Chang KV. Diverging artifact in a subcutaneous abscess. *J Med Ultrasound* 2022;30:163.