



CASE REPORT

REVISED Case Report: Acute effect of benralizumab on asthma exacerbation without concomitant corticosteroid use [version 2; peer review: 2 approved]

Santi Nolasco ¹, Raffaele Campisi², Rossella Intravaia¹, Morena Porto¹, Corrado Pelaia ³, Nunzio Crimi^{1,2}, Claudia Crimi ²

¹Department of Clinical and Experimental Medicine, Section of Respiratory Diseases, University of Catania, Catania, Italy

²Respiratory Medicine Unit, A.O.U. "Policlinico-Vittorio Emanuele", Catania, Italy

³Department of Medical and Surgical Sciences, University "Magna Graecia", Catanzaro, Italy

v2 First published: 23 Jun 2020, 9:637
<https://doi.org/10.12688/f1000research.24603.1>
 Latest published: 23 Jul 2020, 9:637
<https://doi.org/10.12688/f1000research.24603.2>

Abstract

Background: Monoclonal antibodies are a relatively new therapeutic option for patients with severe refractory asthma, which can be used as an add-on to maintenance therapy, reducing the need for systemic corticosteroid usage, improving asthma symptom control and reducing exacerbations. We report a case of a patient with severe refractory eosinophilic asthma, reluctant to take systemic steroids, who was successfully treated with benralizumab alone during an acute asthma attack.

Case presentation: A 59-year-old Caucasian woman with a history of allergic asthma since childhood showed a progressive decline in lung function with difficult to control symptoms and an increased number of hospitalizations despite maximal maintenance treatment, and was diagnosed with severe refractory asthma. She was reluctant to take systemic corticosteroids during exacerbations due to severe urinary retention; therefore, she started omalizumab with a partial reduction of symptoms and exacerbations over time. During a follow-up visit, she showed signs of acute exacerbation and she was switched to benralizumab during her acute phase with a rapid, dramatic amelioration of respiratory symptoms and pulmonary function, without concomitant systemic corticosteroid administration. During the treatment and at follow-up after one month, good tolerance and no side effects were observed.

Conclusions: The use of benralizumab seems to be feasible, rapid, and safe in treating acute exacerbation of severe eosinophilic asthma without the use of systemic corticosteroids.

Keywords

anti-IL-5 antibody, asthma control test, benralizumab, eosinophilic asthma, speed of onset, severe refractory asthma, asthma exacerbation

Open Peer Review

Reviewer Status

Invited Reviewers

1 2

version 2

(revision)
23 Jul 2020



report



version 1

23 Jun 2020



report



report

1. **Paula Kauppi** , University of Helsinki, Helsinki, Finland

2. **Claudio Micheletto**, Integrated University Hospital, Verona, Italy

Any reports and responses or comments on the article can be found at the end of the article.

Corresponding author: Claudia Crimi (dott.claudiacrimi@gmail.com)

Author roles: **Nolasco S:** Data Curation, Resources, Writing – Original Draft Preparation, Writing – Review & Editing; **Campisi R:** Writing – Original Draft Preparation, Writing – Review & Editing; **Intravaia R:** Data Curation, Resources; **Porto M:** Data Curation, Resources, Writing – Review & Editing; **Pelaia C:** Conceptualization, Writing – Review & Editing; **Crimi N:** Conceptualization, Supervision, Writing – Review & Editing; **Crimi C:** Conceptualization, Supervision, Writing – Original Draft Preparation, Writing – Review & Editing

Competing interests: No competing interests were disclosed.

Grant information: The author(s) declared that no grants were involved in supporting this work.

Copyright: © 2020 Nolasco S *et al.* This is an open access article distributed under the terms of the [Creative Commons Attribution License](#), which permits unrestricted use, distribution, and reproduction in any medium, provided the original work is properly cited.

How to cite this article: Nolasco S, Campisi R, Intravaia R *et al.* **Case Report: Acute effect of benralizumab on asthma exacerbation without concomitant corticosteroid use [version 2; peer review: 2 approved]** F1000Research 2020, 9:637 <https://doi.org/10.12688/f1000research.24603.2>

First published: 23 Jun 2020, 9:637 <https://doi.org/10.12688/f1000research.24603.1>

REVISED Amendments from Version 1

Based on the reviewers' requests, we now have added more information on the patient's clinical history and treatment adherence. Moreover, we discussed in detail the potential reasons for the unexpected rapid improvement in lung function after benralizumab administration and the novelty of our report compared to the previously published ones, as suggested by the reviewers.

Any further responses from the reviewers can be found at the end of the article

Abbreviations

ACT, Asthma Control Test; BID, bis in die; FEV1, forced expiratory volume in 1 second, FVC, forced vital capacity; FeNO, fraction of exhaled nitric oxide; LAMA, long-acting muscarinic antagonist; IV, intravenous.

Introduction

Acute exacerbation of severe asthma is a medical emergency that requires treatment with high-dose corticosteroids and

accounts for >60% of the total costs of the disease care, primarily required for emergency visits and hospitalizations^{1,2}.

Monoclonal antibodies are a relatively new therapeutic option for patients with severe refractory asthma, which can be used as an add-on to the maintenance therapy, with long-term effects such as reducing the need for systemic corticosteroids usage, improving asthma symptoms control and reducing exacerbations³. We report the use of a monoclonal antibody against interleukin-5, benralizumab, for the treatment of an acute exacerbation of severe asthma in a patient who refused to take systemic steroids.

Case presentation

Patient information and medical history

We present the case of a 59-year-old non-smoker Caucasian female, lawyer, with a history of allergic asthma since childhood. She had no pets at home.

Timeline of patient's clinical evolution with diagnostic tests and treatments is shown in **Figure 1**.

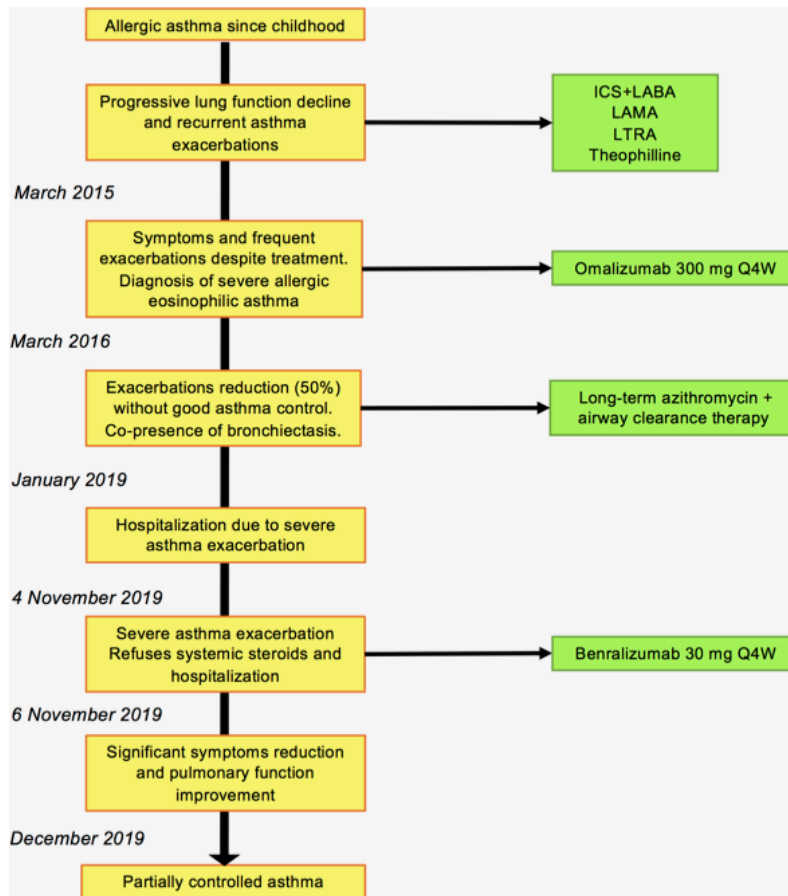


Figure 1. Case report timeline following CARE guidelines. LAMA, long acting muscarinic agonist; LTRA, leukotrienes receptor antagonist; Q4W: every four weeks.

The patient had a body mass index within the normal range, chronic rhinosinusitis without nasal polyposis, and gastro-esophageal reflux under pharmacological control.

Her basal asthma regimen over the years was budesonide/formoterol 160 mcg/4.5 mcg, four puffs/day, with good treatment adherence and correct inhalation technique.

Over the past years, despite her adequate adherence to her maintenance regimen, the patient experienced a gradual worsening of her asthma symptoms, together with a progressive decline of her lung function and an increasing number of exacerbations, some of which required hospitalization. Therefore, after a pulmonologist consultation, combined treatment with a long-acting muscarinic antagonist (LAMA; 2.5 mcg tiotropium Respimat inhaler, two puffs daily), theophylline (300 mg tablets, bis in die) and a leukotriene receptor antagonist (montelukast, 10 mg daily) were added to her maintenance treatment regimen.

The patient's adherence to both inhaled (ICS + LABA and LAMA) and oral (theophylline and montelukast) therapy continues to be very good, due to her fear of possible need for intravenous/oral steroids in case of non-adequate adherence.

Initial presentation, diagnostic tests and treatment

In March 2015, she was referred to our outpatient respiratory clinic at Policlinico Vittorio-Emanuele di Catania, Italy, due to the persistence of asthma symptoms despite the therapy. Pulmonary function tests showed a forced vital capacity (FVC) of 78% of predicted value (2620 mL), and a forced expiratory volume in one second (FEV₁) of 55% of predicted value (1400 mL), with a post-bronchodilator (after 400 mcg of salbutamol) increase in FEV₁ of 24% (1990 mL).

She showed sensitization to multiple inhalant allergens by skin prick tests (house dust mites, dog and cat dander, and *Parietaria judaica*), high serum total IgE levels (201 IU/mL), high blood eosinophils count (670 cells/ μ L) and high fraction of exhaled nitric oxide (FeNO; 51 ppb). She complained of frequent exacerbations of her asthma symptoms and recurrent hospital admissions over the past year (nearly one/month) and, therefore, we classified her as severe refractory asthma according to Global Initiative for Asthma (GINA) guidelines⁴, after excluding other respiratory diseases that may share common clinical manifestations with severe asthma, as recommended by ERS/ATS guidelines⁵.

Moreover, the patient had always been reluctant to use systemic corticosteroids, referring to an almost immediate appearance of urinary retention, so she refused the proposed short course of oral corticosteroids. Therefore, we started treatment with omalizumab (300 mg via subcutaneous injections administered every four weeks).

Subsequent presentations, diagnostic tests and treatments

We further evaluated our patient every four weeks, and she reported a dramatic reduction in the number and severity of exacerbations (nearly 50% less) and the number of hospitalizations

overall, without using systemic steroids. Still, she described persistence of respiratory symptoms and poor asthma control with the need of a salbutamol inhaler at least five times a day, despite the maintenance and the biologic therapy. At her follow-up visit after one year from the first dose of omalizumab, her Asthma Control Test (ACT) score was 8, her FeNo was 33 ppb, and her pulmonary function tests showed an FEV₁ of 73% of predicted value (1860 mL) and FVC of 90% of predicted value (3030 mL), an FEV₁ / FVC of 61% and a positive post-bronchodilatation test response, with FEV₁ reaching 85% (+ 12%) and 2105 mL. She underwent a chest computed tomography scan, revealing diffuse bronchiectasis; therefore, she started long-term azithromycin and airway clearance therapy on top of her usual maintenance treatment. The patient still achieved partially controlled asthma with treatment optimization.

In January 2019, she presented to the emergency department for a new severe exacerbation characterized by whistling dyspnea, greenish sputum, and acute respiratory failure, and required hospitalization.

During the hospital stay, her sputum cytological analysis showed 17% of eosinophils out of a total count of 250,000 cells/mL, and her blood tests exhibited an elevated peripheral eosinophilic count (470 cells/ μ L). Pulmonary function tests revealed an FEV₁ of 49% of predicted, FVC of 72% of predicted and FEV₁ / FVC of 57.4%. She started intravenous (IV) theophylline (240 mg intravenous slow bolus followed by a continuous infusion of 0.5 mg/kg/h), IV piperacillin/tazobactam (4.5 g every eight hours), IV corticosteroids (40 mg of methylprednisolone), and oxygen (nasal cannula 2 liters/minute) on top of her maintenance therapy, with progressive symptoms relieved. At discharge, we proposed a switch from omalizumab to mepolizumab, but the patient refused.

On November 4, 2019, she presented for a regular outpatient visit and complained of a worsening of her usual respiratory symptoms, presence of wheezing, reduced tolerance to physical activity, abundant purulent sputum, and frequent nocturnal awakenings. She had taken 25+ puffs of salbutamol to alleviate her chest tightness. Her oxygen saturation was 91% at rest.

Pulmonary function tests showed an FEV₁ of 61% of predicted value (1480 mL), FVC of 74% of predicted value (2410 mL), and FEV₁ / FVC of 61%. A post-bronchodilatation test FEV₁ reached 70% (+9%) and 1700 mL. Her ACT score was 6. She also underwent blood tests, showing elevated eosinophils (390 cells/ μ L) and her FeNo was 60 ppb.

We proposed a short course of steroids, but she refused to take them due to the fear of urinary retention; she also refused hospitalization. Therefore, as a rescue solution, and due to the presence of elevated eosinophils, we decided to switch omalizumab to benralizumab (30 mg by subcutaneous injection every four weeks for the first three doses, and then every eight weeks thereafter) on top of her maintenance therapy. The same day the patient started the first administration of 30 mg subcutaneous injection of benralizumab.

Follow-up and outcomes

At a telephone follow-up after 24 hours, she reported a significant improvement in her asthma symptoms with the almost total disappearance of sputum, absence of nocturnal awakening, and noticeable reduction of dyspnea, which made her stop rescue medication. At her 48 hours follow-up visit, the physical examination revealed a dramatic decrease in whistles as compared to the day before. The FEV₁ was 80% of predicted value (1940 ml, +19% compared to two days before), FVC was 88% of predicted value (2890 ml, +14% compared to two days before) and FEV₁ / FVC was 67% (+6%). Oxygen saturation has improved too, reaching 98% at rest, and her blood test showed complete depletion of eosinophils in peripheral blood. After four weeks, she returned to our outpatient service for administration of the second dose of benralizumab. She described good control of respiratory symptoms within the last month with no exacerbations, nocturnal awakening, nor sputum, and only occasional use of salbutamol. She did not report any adverse effects. Her blood count continued to show complete eosinophils depletion. Pulmonary function tests showed a further increase in lung function: an FEV₁ of 98% of predicted value (2360 ml), FVC of 94% of predicted value (3140 ml), and FEV₁ / FVC 75%. Her ACT reached a score of 18, her highest result ever and her FeNo was 47 ppb. Based on these excellent results the patient was then prescribed with benralizumab 30 mg every four weeks for the following two doses and then every 8 weeks, with the indication of performing a blood test to evaluate the blood eosinophils count before each biologic dose administration.

Discussion

To the best of our knowledge, this case report is the first in the literature on the use of benralizumab administration during an acute attack of severe refractory eosinophilic asthma, without the concomitant use of systemic steroids. The main finding of this report is the efficacy and safety of benralizumab treatment during the acute phase of eosinophilic asthma exacerbation, showing a terrific and rapid response in terms of improvement of symptoms and pulmonary function (significant gain in FEV₁ after only 48 hours), and reduction of sputum production, without the concomitant use of systemic corticosteroids and avoiding hospitalization.

Biologics have shown long-term beneficial effects in the management of severe asthma patients⁶. Characterizing the properties of one molecule versus another might be crucial for a more personalized treatment approach⁷. The speed of treatment onset might represent an essential underrated characteristic to consider in this context.

Omalizumab has been shown to reduce both asthma symptoms and exacerbations within the first 30 days of treatment⁸, while mepolizumab in months⁹ and reslizumab in weeks¹⁰. Indeed, benralizumab is responsible for rapid symptomatologic improvement, obtainable after only a few days¹¹.

This brilliant and fast therapeutic effect is due to its antibody-dependent cell-mediated cytotoxicity activity, which

results in a complete depletion of eosinophils in both peripheral blood and tissues¹².

The rapid improvement in symptoms observed is in line with the results of a post-hoc analysis of two studies (SIROCCO and CALIMA), which showed positive impacts on symptoms by the third day after administration, reducing salbutamol use¹¹. Our report strengthens the data from Nowak and coworkers¹³, who described similar rapid effects, indicating that the administration of one dose of benralizumab added to usual care in patients who presented with acute asthma to the emergency department decreased asthma exacerbation rate and severity as well as hospitalizations at twelve weeks.

A recent case report¹⁴ described a reduction in asthma symptoms after two days and an improvement in respiratory peak flow after four days of benralizumab administration¹⁴. Rapid response to treatment was previously described in another report from our group¹⁵.

The case presented is the first in which treatment with benralizumab during the acute phase of eosinophilic asthma exacerbation without the concomitant use of systemic steroids, on top of the maintenance treatment regimen, showed rapid resolution of symptoms within 24 hours. The immediate response to the treatment is also supported by a considerable increase in pulmonary function parameters (FEV₁ +19%) obtained only after 48 hours, even without the concomitant use of systemic steroids. This case could be the starting point for the use of benralizumab in the acute phase of severe eosinophilic asthma exacerbations, starting the treatment early in the emergency room without resorting to systemic steroids. This rapid effect on lung function might be explained by the ability of benralizumab to reduce eosinophils not only in peripheral blood but also in the airways, limiting the release of noxious eosinophil granule proteins in bronchial tissue^{12,16}.

Moreover, differently from previously published reports^{17,18} showing the rapid effects of biologics use together with high doses of systemic steroids and bronchodilators, our report is likely to reveal the real fast effect of benralizumab on acute asthma exacerbation, being used alone on top of the maintenance therapy, without concomitant use of systemic steroids.

This case report has some limitations. We did not report a long-term follow-up. Therefore, we cannot document long-term beneficial effects and treatment tolerance.

In conclusion, benralizumab may represent a feasible treatment as an add-on therapy in the management of acute asthma attacks, even without the use of systemic corticosteroids. Adequately powered multicenter trials are needed to confirm our observation.

Data availability

All data underlying the results are available as part of the article and no additional source data are required.

Consent

Written informed consent for publication of clinical details was obtained by the patient.

References

1. Bahadori K, Doyle-Waters MM, Marra C, *et al.*: **Economic burden of asthma: a systematic review.** *BMC Pulm Med.* 2009; **9**: 24.
[PubMed Abstract](#) | [Publisher Full Text](#) | [Free Full Text](#)
2. Godard P, Chanez P, Siraudin L, *et al.*: **Costs of asthma are correlated with severity: a 1-yr prospective study.** *Eur Respir J.* 2002; **19**(1): 61–67.
[PubMed Abstract](#) | [Publisher Full Text](#)
3. Bagnasco D, Heffler E, Testino E, *et al.*: **Pharmacokinetics and pharmacodynamics of monoclonal antibodies for asthma treatment.** *Expert Opin Drug Metab Toxicol.* 2019; **15**(2): 113–120.
[PubMed Abstract](#) | [Publisher Full Text](#)
4. **Global strategy for Asthma Management and Prevention.** 2016; Last accessed 17 July 2020.
[Reference Source](#)
5. Chung KF, Wenzel SE, Brozek JL, *et al.*: **International ERS/ATS guidelines on definition, evaluation and treatment of severe asthma.** *Eur Respir J.* 2014; **43**(2): 343–373.
[PubMed Abstract](#) | [Publisher Full Text](#)
6. McCracken JL, Trippl JW, Calhoun WJ: **Biologic therapy in the management of asthma.** *Curr Opin Allergy Clin Immunol.* 2016; **16**(4): 375–382.
[PubMed Abstract](#) | [Publisher Full Text](#) | [Free Full Text](#)
7. Siddiqui S, Denlinger LC, Fowler SJ, *et al.*: **Unmet Needs in Severe Asthma Subtyping and Precision Medicine Trials. Bridging Clinical and Patient Perspectives.** *Am J Respir Crit Care Med.* 2019; **199**(7): 823–829.
[PubMed Abstract](#) | [Publisher Full Text](#) | [Free Full Text](#)
8. Sorkness CA, Wildfire JJ, Calatroni A, *et al.*: **Reassessment of omalizumab-dosing strategies and pharmacodynamics in inner-city children and adolescents.** *J Allergy Clin Immunol Pract.* 2013; **1**(2): 163–171.
[PubMed Abstract](#) | [Publisher Full Text](#) | [Free Full Text](#)
9. Haldar P, Brightling CE, Hargadon B, *et al.*: **Mepolizumab and exacerbations of refractory eosinophilic asthma.** *N Engl J Med.* 2009; **360**(10): 973–984.
[PubMed Abstract](#) | [Publisher Full Text](#) | [Free Full Text](#)
10. Castro M, Zangrilli J, Wechsler ME, *et al.*: **Reslizumab for inadequately controlled asthma with elevated blood eosinophil counts: results from two multicentre, parallel, double-blind, randomised, placebo-controlled, phase 3 trials.** *Lancet Respir Med.* 2015; **3**(5): 355–366.
[PubMed Abstract](#) | [Publisher Full Text](#)
11. O'Quinn S, Xu X, Hirsch I: **Daily patient-reported health status assessment improvements with benralizumab for patients with severe, uncontrolled eosinophilic asthma.** *J Asthma Allergy.* 2019; **12**: 21–33.
[PubMed Abstract](#) | [Publisher Full Text](#) | [Free Full Text](#)
12. Laviolette M, Gossage DL, Gauvreau G, *et al.*: **Effects of benralizumab on airway eosinophils in asthmatic patients with sputum eosinophilia.** *J Allergy Clin Immunol.* 2013; **132**(5): 1086–1096.e5.
[PubMed Abstract](#) | [Publisher Full Text](#) | [Free Full Text](#)
13. Nowak RM, Parker JM, Silverman RA, *et al.*: **A randomized trial of benralizumab, an antiinterleukin 5 receptor alpha monoclonal antibody, after acute asthma.** *Am J Emerg Med.* 2015; **33**(1): 14–20.
[PubMed Abstract](#) | [Publisher Full Text](#)
14. Izumo T, Terada Y, Tone M, *et al.*: **Rapid effects of benralizumab on severe asthma during surgery for residual tumor after advanced lung squamous cell carcinoma treatment with pembrolizumab.** *Respir Med Case Rep.* 2019; **26**: 292–295.
[PubMed Abstract](#) | [Publisher Full Text](#) | [Free Full Text](#)
15. Pelala C, Busceti MT, Vatrella A, *et al.*: **Effects of the first three doses of benralizumab on symptom control, lung function, blood eosinophils, oral corticosteroid intake, and nasal polyps in a patient with severe allergic asthma.** *SAGE Open Med Case Rep.* 2020; **8**: 2050313X20906963.
[PubMed Abstract](#) | [Publisher Full Text](#) | [Free Full Text](#)
16. Mukherjee M, Bakakos P, Loukides S: **New paradigm in asthma management: Switching between biologics!** *Allergy.* 2020; **75**(4): 743–745.
[PubMed Abstract](#) | [Publisher Full Text](#)
17. Renner A, Marth K, Schäffl-Doweik L, *et al.*: **Reslizumab in an invasively ventilated patient with acute respiratory failure.** *J Allergy Clin Immunol Pract.* 2019; **7**(8): 2922–3.
[PubMed Abstract](#) | [Publisher Full Text](#)
18. Milger K, Schroeder I, Behr J, *et al.*: **Omalizumab Rescue Therapy for Refractory Status Asthmaticus.** *Ann Intern Med.* 2019; **170**(5): 351–352.
[PubMed Abstract](#) | [Publisher Full Text](#)

Open Peer Review

Current Peer Review Status:  

Version 2

Reviewer Report 20 August 2020

<https://doi.org/10.5256/f1000research.28193.r67879>

© 2020 Kauppi P. This is an open access peer review report distributed under the terms of the [Creative Commons Attribution License](#), which permits unrestricted use, distribution, and reproduction in any medium, provided the original work is properly cited.



Paula Kauppi 

Inflammation Centre, Skin and Allergy Hospital, Helsinki University Hospital, University of Helsinki, Helsinki, Finland

I have no further comments.

Competing Interests: PK has received a fee for lecturing or for consultancy from TEVA, Novartis, GSK, Sanofi, AstraZeneca however, this has not affected my review

I confirm that I have read this submission and believe that I have an appropriate level of expertise to confirm that it is of an acceptable scientific standard.

Version 1

Reviewer Report 08 July 2020

<https://doi.org/10.5256/f1000research.27141.r65420>

© 2020 Micheletto C. This is an open access peer review report distributed under the terms of the [Creative Commons Attribution License](#), which permits unrestricted use, distribution, and reproduction in any medium, provided the original work is properly cited.



Claudio Micheletto

Cardio-Thoracic Dept, Respiratory Unit, Integrated University Hospital, Verona, Italy

The Authors presented a case report on the use of benralizumab administration during an acute attack of severe refractory eosinophilic asthma, without the concomitant use of systemic steroids. Benralizumab is an anti-receptor monoclonal anti-IL-5 antibody, which has been shown to be particularly effective in reducing exacerbations, used as regular therapy in severe eosinophilic

asthma.

Some questions:

- How was the patient's adherence to inhalation therapy?
- Did the patient have a previous accurate diagnosis of severe asthma?
- Was the patient then regularly treated with benralizumab?
- Were eosinophils measured in the following weeks?

References

1. Nowak RM, Parker JM, Silverman RA, Rowe BH, et al.: A randomized trial of benralizumab, an antiinterleukin 5 receptor α monoclonal antibody, after acute asthma. *Am J Emerg Med.* 2015; **33** (1): 14-20 [PubMed Abstract](#) | [Publisher Full Text](#)

Is the background of the case's history and progression described in sufficient detail?

Yes

Are enough details provided of any physical examination and diagnostic tests, treatment given and outcomes?

Yes

Is sufficient discussion included of the importance of the findings and their relevance to future understanding of disease processes, diagnosis or treatment?

Yes

Is the case presented with sufficient detail to be useful for other practitioners?

Yes

Competing Interests: No competing interests were disclosed.

Reviewer Expertise: severe asthma

I confirm that I have read this submission and believe that I have an appropriate level of expertise to confirm that it is of an acceptable scientific standard.

Author Response 17 Jul 2020

Claudia Crimi, A.O.U. "Policlinico-Vittorio Emanuele", Catania, Italy

Dear Dr. Micheletto,

Thank you for your time and consideration in reviewing our article.

We are glad that you find our case report interesting. We were thrilled to read the approval

from an expert in the field like you.

We have now added a bit more information as you requested.

Best Regards,

Claudia Crimi, MD, PhD

Specific point-by-point response:

The Authors presented a case report on the use of benralizumab administration during an acute attack of severe refractory eosinophilic asthma, without the concomitant use of systemic steroids. Benralizumab is an anti-receptor monoclonal anti-IL-5 antibody, which has been shown to be particularly effective in reducing exacerbations, used as regular therapy in severe eosinophilic asthma.

- How was the patient's adherence to inhalation therapy?

Reply: Thank you for your comment. Based on your suggestion we have added a sentence stating that patient's adherence to both inhaled (ICS + LABA and LAMA) and oral (theophylline and Montelukast) therapy, continue to be very good, also due to her fear of possible need for intravenous/oral steroids in case of non-adequate adherence.

- Did the patient have a previous accurate diagnosis of severe asthma?

Reply: Thank you for your comment. We diagnosed severe asthma according to ERS/ATS guidelines [1]; therefore, we excluded other respiratory diseases that may share common clinical manifestations of severe asthma (i.e., bronchopulmonary aspergillosis, vasculitis, chronic cough). We have now specified it in the text and added the appropriate reference as below.

1. Chung KF, Wenzel SE, Brozek JL, et al.: International ERS/ATS guidelines on definition, evaluation and treatment of severe asthma. *Eur Respir J*. 2014; 43(2): 343–373.

- Was the patient then regularly treated with benralizumab?

Reply: Thank you for pointing out this aspect. Yes, the patient was then treated regularly with benralizumab 30 mg subcutaneously every four weeks for the first three doses and then every eight weeks. We have better clarified this in the text (paragraph follow-up and outcomes, last sentence).

- Were eosinophils measured in the following weeks?

Reply: Thank you for highlighting this aspect. Yes, we executed blood eosinophils count 48h and exactly four weeks after the first benralizumab administration (right before the second dose), showing a complete eosinophils depletion in both determinations (as described in the paragraph follow-up and outcomes). Moreover, a blood test was performed before every next benralizumab dose. We have now better specify this aspect in the text

(paragraph follow-up and outcomes, last sentence).

Competing Interests: No competing interests were disclosed.

Reviewer Report 06 July 2020

<https://doi.org/10.5256/f1000research.27141.r65647>

© 2020 Kauppi P. This is an open access peer review report distributed under the terms of the [Creative Commons Attribution License](#), which permits unrestricted use, distribution, and reproduction in any medium, provided the original work is properly cited.

? **Paula Kauppi** 

Inflammation Centre, Skin and Allergy Hospital, Helsinki University Hospital, University of Helsinki, Helsinki, Finland

This is a case report of a patient who received a dose of benralizumab for acute asthma. The patient had been on omalizumab as an add on therapy with ICS, LABA, LAMA, montelukast and theophylline. She refused per oral glucocorticoids. She had moderate to severe obstruction in spirometry and bronchodilator response. She received a dose of benralizumab when having an asthma exacerbation. Two days later her asthma symptoms had decreased and lung function increased.

1. What was adherence of the patient with her asthma medication (ICS, LABA, LAMA, montelukast and theophylline)?
2. Did the patient smoke regularly or had she ever smoked regularly?
3. Did the patient have pets at home?
4. How many exacerbations or severe exacerbations the patient had had a year before she started omalizumab?
5. How many exacerbations or severe exacerbations the patient had had a year before she started benralizumab?
6. In previous studies, benralizumab has been shown to reduce number of eosinophils in 24 hours and to increase FEV1 in 4 weeks. In this case report, benralizumab seemed to increase FEV1 in two days? Could you discuss the unexpected rapid changes?
7. Did the patient receive some other asthma drugs or were the other asthma drugs changed on the same visit when benralizumab was started?
8. Please consider these two reports on use of biologicals in acute asthma: Renner A, Marth K, Schäffl-Doweik L, Pohl W. Case Report: Reslizumab in an Invasively Ventilated Patient With Acute Respiratory Failure. *J Allergy Clin Immunol Pract.* 2019;7(8):2922-2923.

doi:10.1016/j.jaip.2019.05.019¹ and Milger K, Schroeder I, Behr J, Meis T, Wulffen WV, Kneidinger N. Omalizumab Rescue Therapy for Refractory Status Asthmaticus. *Ann Intern Med.* 2019;170(5):351-352. doi:10.7326/L18-0359².

References

1. Renner A, Marth K, Schäffli-Doweik L, Pohl W: Reslizumab in an invasively ventilated patient with acute respiratory failure. *The Journal of Allergy and Clinical Immunology: In Practice.* 2019; **7** (8): 2922-2923 [Publisher Full Text](#)
2. Milger K, Schroeder I, Behr J, Meis T, et al.: Omalizumab Rescue Therapy for Refractory Status Asthmaticus. *Annals of Internal Medicine.* 2019; **170** (5). [Publisher Full Text](#)

Is the background of the case's history and progression described in sufficient detail?

Partly

Are enough details provided of any physical examination and diagnostic tests, treatment given and outcomes?

Partly

Is sufficient discussion included of the importance of the findings and their relevance to future understanding of disease processes, diagnosis or treatment?

Partly

Is the case presented with sufficient detail to be useful for other practitioners?

Partly

Competing Interests: PK has received a fee for lecturing or for consultancy from TEVA, Novartis, GSK, Sanofi, AstraZeneca however, this has not affected my review

Reviewer Expertise: Asthma, obstructive pulmonary disease, bronchiectasis, allergic diseases

I confirm that I have read this submission and believe that I have an appropriate level of expertise to confirm that it is of an acceptable scientific standard, however I have significant reservations, as outlined above.

Author Response 18 Jul 2020

Claudia Crimi, A.O.U. "Policlinico-Vittorio Emanuele", Catania, Italy

Dear Dr. Kauppi,

Thank you for your time and consideration in reviewing our article.

Your comments were very helpful to improve the manuscript and we hope that the revised version makes it now acceptable for you.

We hereby provide a point-by-point reply to your comments.

We look forward hearing from you soon.

Best Regards,

Claudia Crimi, MD, PhD

This is a case report of a patient who received a dose of benralizumab for acute asthma. The patient had been on omalizumab as an add on therapy with ICS, LABA, LAMA, montelukast and theophylline. She refused per oral glucocorticoids. She had moderate to severe obstruction in spirometry and bronchodilator response. She received a dose of benralizumab when having an asthma exacerbation. Two days later her asthma symptoms had decreased and lung function increased.

1. What was adherence of the patient with her asthma medication (ICS, LABA, LAMA, montelukast and theophylline)?

Reply:Thank you for your comment. Based on your suggestion we have added a sentence stating that the patient's adherence to both inhaled (ICS + LABA and LAMA) and oral (theophylline and montelukast) therapy continues to be very good, due to her fear of possible need for intravenous/oral steroids in case of non-adequate adherence (see the section "Patient information and medical history" last sentence).

2. Did the patient smoke regularly or had she ever smoked regularly?

Reply:Thanks for pointing out this. No, the patient has never smoked; this information is present in the first sentence of the paragraph "Patient information and medical history".

3. Did the patient have pets at home?

Reply:Thanks for this comment. No, the patient has never had pets at home; we have now clarified this in the description of patient's medical history (Second sentence of the paragraph "Patient information and medical history").

4. How many exacerbations or severe exacerbations the patient had had a year before she started omalizumab?

Reply:Thanks for highlighting this aspect. As stated in the section "Initial presentation, diagnostic tests and treatment" (please see second paragraph) the patient complained one exacerbation per month (12 exacerbations/year) over the past year before starting omalizumab treatment.

5. How many exacerbations or severe exacerbations the patient had had a year before she started benralizumab?

Reply:Thanks for highlighting this aspect. As stated in the section "Subsequent presentation, diagnostic tests and treatments" (please see first sentence) the patient reported a reduction of nearly 50% of exacerbation after one year of omalizumab (one

exacerbation every 2 months - 6 exacerbations/year) before starting benralizumab treatment.

6. In previous studies, benralizumab has been shown to reduce number of eosinophils in 24 hours and to increase FEV1 in 4 weeks. In this case report, benralizumab seemed to increase FEV1 in two days? Could you discuss the unexpected rapid changes?

Reply:The patient showed a complete depletion in peripheral blood eosinophil count within 2 days after switching from omalizumab to benralizumab, showing an increase of pre-bronchodilator FEV1% (+19%), FVC (+14%) and FEV1/FVC (6%).

This rapid eosinophils reduction is consistent with previous benralizumab studies [1] and reflects its mechanism. Moreover, benralizumab has shown to significantly reduce eosinophils not only in peripheral blood but also in airways, limiting the release of noxious eosinophil granule proteins in bronchial tissues [2,3]. IL-5 is upstream of IgE in the canonical allergic inflammatory cascade, coupled with current emerging evidence of non-IgE-mediated alternative IL-5 pathways that can maintain eosinophilia is reasonable to expect an anti-IL-5R mAb to be effective when an anti-IgE mAb fails to curb symptoms [3]. We suggest that these mechanisms have been responsible for the rapid improvement of the patient's lung function. In our patient, eosinophils reduction allowed the tapering of type-2 inflammatory processes accountable for her asthma exacerbations. These considerations are corroborated by the good control of respiratory symptoms, and further respiratory function improvements 4 weeks after the first benralizumab administration. Therefore, our observation confirms that the therapeutic responses to anti-asthma biological drugs are strictly individual, being dependent on each patient's specific endotype. We have discussed this point in the discussion section, as requested.

1. Nowak RM, Parker JM, Silverman RA, et al. A randomized trial of benralizumab, an anti interleukin 5 receptor monoclonal antibody, after acute asthma. *Am J Emerg Med.* 2015;33(1):14-20. doi:10.1016/j.ajem.2014.09.036 (REF 13)
2. Laviolette M, Gossage DL, Gauvreau G, et al.: Effects of benralizumab on airway eosinophils in asthmatic patients with sputum eosinophilia. *J Allergy Clin Immunol.* 2013; 132(5): 1086–1096 e1085 (REF 12)
3. Mukherjee M, Bakakos P, Loukides S. New paradigm in asthma management: Switching between biologics!. *Allergy.* 2020;75(4):743-745. doi:10.1111/all.14038 (REF 16)

7. Did the patient receive some other asthma drugs or were the other asthma drugs changed on the same visit when benralizumab was started?

Reply:Thank you for highlighting this aspect. No. The patient at this point was already taking high-dose ICS+LABA, LAMA, montelukast, theophylline, omalizumab (last administration exactly 4 weeks prior), azithromycin and 25+ daily puffs of salbutamol. During the visit, due to presence of wheezing, reduced tolerance to physical activity, abundant purulent sputum, frequent nocturnal awakenings and rest oxygen saturation of 91%, her reluctance to be hospitalized and to take oral or systemic corticosteroids, and because of the presence of 390 eosinophils/ μ L we decided to immediately switch from omalizumab to benralizumab 30mg. We have now clarified this aspect adding a sentence at the end of the section "Subsequent presentations, diagnostic tests and treatments" (second-last sentence).

8. Please consider these two reports on use of biologicals in acute asthma: Renner A, Marth K, Schäffl-Doweik L, Pohl W. Case Report: Reslizumab in an Invasively Ventilated Patient With Acute Respiratory Failure. *J Allergy Clin Immunol Pract.* 2019;7(8):2922-2923. doi:10.1016/j.jaip.2019.05.019¹ and Milger K, Schroeder I, Behr J, Meis T, Wulffen WV, Kneidinger N. Omalizumab Rescue Therapy for Refractory Status Asthmaticus. *Ann Intern Med.* 2019;170(5):351-352. doi:10.7326/L18-0359².

doi:10.1016/j.jaip.2019.05.019¹ and Milger K, Schroeder I, Behr J, Meis T, Wulffen WV, Kneidinger N. Omalizumab Rescue Therapy for Refractory Status Asthmaticus. *Ann Intern Med.* 2019;170(5):351-352. doi:10.7326/L18-0359².

Reply: Thank you for referring to these interesting references. Both reports showed the rapid effects of biologics, but, as stated by the authors, it is not possible to exclude that patients would have improved anyway due to the high doses of systemic bronchodilators and corticosteroids not possible to establish the effect of biologic alone. Our case is the first report of an acute asthma exacerbation treated with benralizumab without the addition of systemic corticosteroid, antibiotic or aggressive bronchodilator therapy, being benralizumab administered on top of patient's maintenance treatment. Therefore, in our report, it is likely to verify and measure the real effect of benralizumab alone during an acute asthma exacerbation, with complete eosinophils reduction and pulmonary function improvement only after 48 hours benralizumab 30 mg subcutaneous administration. We have now discussed the references as suggested.

Competing Interests: No competing interests were disclosed.

The benefits of publishing with F1000Research:

- Your article is published within days, with no editorial bias
- You can publish traditional articles, null/negative results, case reports, data notes and more
- The peer review process is transparent and collaborative
- Your article is indexed in PubMed after passing peer review
- Dedicated customer support at every stage

For pre-submission enquiries, contact research@f1000.com

F1000Research