Pediatr Nephrol (2010) 25:1641–1652
DOI 10.1007/s00467-009-1336-1

EDUCATIONAL REVIEW

Medium-size-vessel vasculitis

Michael J. Dillon · Despina Eleftheriou · Paul A. Brogan

Received: 7 July 2009 / Revised: 10 September 2009 / Accepted: 11 September 2009 / Published online: 28 November 2009
© IPNA 2009

Abstract Medium-size-artery vasculitides do occur in childhood and manifest, in the main, as polyarteritis nodosa (PAN), cutaneous PAN and Kawasaki disease. Of these, PAN is the most serious, with high morbidity and not inconsequential mortality rates. New classification criteria for PAN have been validated that will have value in epidemiological studies and clinical trials. Renal involvement is common and recent therapeutic advances may result in improved treatment options. Cutaneous PAN is a milder disease characterised by periodic exacerbations and often associated with streptococcal infection. There is controversy as to whether this is a separate entity or part of the systemic PAN spectrum. Kawasaki disease is an acute self-limiting systemic vasculitis, the second commonest vasculitis in childhood and the commonest cause of childhood-acquired heart disease. Renal manifestations occur and include tubulointerstitial nephritis and renal failure. An infectious trigger and a genetic predisposition seem likely. Intravenous immunoglobulin (IV-Ig) and aspirin are effective therapeutically, but in resistant cases, either steroid or infliximab have a role. Greater understanding of the pathogenetic mechanisms involved in these three types of vasculitis and better long-term follow-up data will lead to improved therapy and prediction of prognosis.

Keywords Vasculitis · Polyarteritis nodosa · Cutaneous polyarteritis nodosa · Kawasaki disease · Child

M. J. Dillon (✉)
Nephrourology Unit, UCL Institute of Child Health,
30 Guilford Street,
London WC1N 1EH, UK
e-mail: m.dillon@ich.ucl.ac.uk

D. Eleftheriou · P. A. Brogan
Department of Rheumatology, UCL Institute of Child Health,
London, UK

Introduction

Vasculitis can be defined as inflammation and necrosis of blood vessels. By common usage, the term predominantly refers to arterial disease, and this interpretation will be used in this educational review. Although more common in adults than in children, vasculitis does occur in childhood and may present as a primary disorder or be a feature of some other systemic disease. Various attempts at classification and nomenclature of vasculitides in both adults and children have been published [1–9]. Most have focussed on vessel size as a useful distinguishing feature, resulting in vasculitis being categorised as affecting large vessels, medium-size vessels and small vessels. The large-vessel category in childhood refers primarily to Takayasu disease; the medium-size-vessel category includes polyarteritis nodosa (PAN), Kawasaki disease (KD) and cutaneous polyarteritis nodosa (CPAN); the small-vessel category is usually subdivided into granulomatous disease [Wegener's granulomatosis (WG) and Churg-Strauss syndrome] and nongranulomatous disorders [microscopic polyangiitis (MPA), the leukocytoclastic vasculitides such as Henoch-Schönlein purpura (HSP), isolated cutaneous leukocytoclastic vasculitis and hypocomplementemic urticarial vasculitis]. There are, in addition, vasculitides affecting various-sized vessels, including Behçet disease, vasculitis associated with infection, vasculitis secondary to connective tissue diseases, isolated vasculitis of the central nervous system, Cogan's syndrome and others [5]. This educational review focuses on medium-size-vessel vasculitis, specifically, PAN, KD and CPAN.

Polyarteritis nodosa

This is a necrotising vasculitis associated with aneurysmal nodules along the walls of medium-sized muscular arteries and is the condition classically described by Kussmaul and Maier in 1866 [10]. Despite some overlap with smaller-vessel

disease, PAN appears to be a distinct entity and, in adults in Europe and the United States, appears to have an estimated annual incidence of 2.0–9.0/million [11]. Although comparatively rare in childhood, it is the most common form of systemic vasculitis after HSP and KD [12, 13]. However, the data are difficult to interpret, as the incidence in various reports differs widely depending on which criteria are used to classify patients as PAN [11]. Peak age of onset in childhood is 7–11 years, with often a male preponderance.

Classification

Until recently, no specific criteria for classifying a child as having PAN existed. Most paediatricians either used the American College of Rheumatology (ACR) criteria [14] or the Chapel Hill Consensus Conference on nomenclature description [3]. To overcome these shortcomings, an International Paediatric Consensus Conference was held in Vienna in 2005. This resulted in a new proposal for the general classification of childhood vasculitides and proposals for classification criteria for several important categories of childhood vasculitis, including PAN [5, 15] (Table 1).

The classification criteria for childhood PAN were biopsy of a small or medium artery showing necrotising vasculitis or suggestive arteriography as a mandatory criterion, plus at least two of the following: skin involvement, myalgia or muscle tenderness, hypertension, mono- or polyneuropathy, abnormal urine analysis and/or renal impairment, testicular pain or tenderness and signs or symptoms suggestive of vasculitis of any other organ system [5]. It was proposed that these criteria would be subjected to a validation process. These and the ACR criteria were found to perform suboptimally, and modifications of the criteria were proposed. These new criteria for PAN are as follows: histopathological evidence of necrotising vasculitis in medium- or small-sized arteries or angiographic abnormality (aneurysm, stenosis or occlusion) as a mandatory criterion; plus one of the following five: skin involvement, myalgia or muscle tenderness, hypertension, peripheral neuropathy, renal involvement [16]. Sensitivity and specificity were 73% and 100% respectively (Table 2).

It is, however, important to appreciate that classification criteria are not diagnostic criteria, and meeting classification criteria is not equivalent to making a diagnosis in an individual patient [17]. A diagnosis is made by considering all clinical features in a patient, only some of which may be classification criteria [17]. In this context, it has been considered that the establishment of diagnostic criteria for childhood PAN would also be of value, and although attempts have been made to do so [18], this is currently under review.

Table 1 Proposed classification of childhood vasculitis (adapted from Ozen et al. [5] with permission)

I. Predominantly large vessel vasculitis
Takayasu arteritis
II. Predominantly medium-sized-vessel vasculitis
Childhood systemic polyarteritis nodosa (PAN)
Cutaneous PAN
Kawasaki disease (KD)
III. Predominantly small-vessel vasculitis
A. Granulomatous
Wegener's granulomatosis
Churg Strauss syndrome
B. Nongranulomatous
Microscopic polyangiitis
Henoch-Schönlein purpura
Isolated cutaneous leukocyclastic vasculitis
Hypocomplementemic urticarial vasculitis
IV. Other vasculitides
Behçet's disease
Vasculitis secondary to infection (including hepatitis-B-associated PAN), malignancy and drugs, including hypersensitivity vasculitis
Vasculitis associated with connective tissue disease
Isolated vasculitis of the central nervous system
Cogan's syndrome
Unclassified

Clinical manifestations

The main clinical features of PAN are malaise, fever, weight loss, skin rash, myalgia, abdominal pain and arthropathy [6, 18–25]. In addition, ischaemic heart and testicular pain; renal manifestations such as haematuria, proteinuria and hypertension [23, 26, 27]; neurologic features such as focal defects, hemiplegia, visual loss, mononeuritis multiplex; and organic psychosis [28–30] may be present. Skin lesions are variable, and may masquerade as those of HSP or multiform erythema but can also be necrotic and associated with peripheral gangrene [31, 32]. Lesions sometimes mimic pyoderma gangrenosum. Livido reticularis is also a characteristic feature, and occasionally subcutaneous nodules overlying affected

Table 2 Criteria for classifying polyarteritis nodosa (PN) (adapted from Ozen et al. [16] with permission)

Histological evidence of necrotizing vasculitis in medium or small sized arteries or angiographic abnormalities (aneurysms, stenoses or occlusion) as a mandatory criterion, plus one out of the following five:
1 Skin involvement
2 Myalgia or muscle tenderness
3 Hypertension
4 Peripheral neuropathy
5 Renal involvement

arteries are present [31, 32]. Systemic involvement is variable, but the skin, the musculoskeletal system, the kidneys and the gastrointestinal tract are most prominently affected, with cardiac, neurological and respiratory manifestations occurring less frequently [9, 18, 19, 21–23, 33, 34]. In some patients, rupture of arterial aneurysms can cause retroperitoneal and peritoneal bleeding, with perirenal haematomata being a recognised manifestation of this phenomenon [35]. This feature has been noted a number of times in Turkey where it has occurred in patients with the well-recognised association of PAN and familial Mediterranean fever [36, 37]. However, clinical manifestations (and investigation findings) can be very confusing, with certainly in the early phase and sometimes the late phase of the illness absence of conclusive diagnostic evidence [38].

Differential diagnosis

Differential diagnosis includes other primary vasculitides (HSP, WG, MPA, KD); connective tissue diseases (juvenile rheumatoid arthritis, dermatomyositis, lupus, mixed connective tissue disease); sarcoidosis; Behçet's disease, viral infections, subacute bacterial endocarditis and lymphoma and other malignancies.

Diagnostic laboratory and radiological investigation

Anaemia, polymorphonuclear leukocytosis, thrombocytosis, increased erythrocyte sedimentation rate (ESR) and C-reactive protein (CRP) are usually present in the active phase of the disease. Platelets are hyperaggregable, and there are circulating immune complexes [39]. Positive hepatitis B serology in children is unusual in association with PAN but can occur [40]. However, the association between hepatitis B infection and PAN is well recognised in adults [41]. Antineutrophil cytoplasmic antibodies (ANCA) are not thought to play a major part in the causality of PAN, but there are reports demonstrating their presence in some adults [42, 43] and children with PAN [44, 45]. The presence of cytoplasmic ANCA (C-ANCA) with antibodies to proteinase 3 in a patient suspected of having PAN makes it mandatory to eliminate Wegener's granulomatosis as a diagnosis. Likewise, a significant titre of perinuclear ANCA (P-ANCA) with antibodies to myeloperoxidase would necessitate steps to ensure that MPA was not the diagnosis. Biopsy material can prove diagnostically important, especially if an affected area or lesion of the skin, muscle or other tissue is available. The characteristic histopathological changes of PAN are fibrinoid necrosis of the walls of medium or small arteries, with a marked inflammatory response within or surrounding the vessel [46] (Fig. 1). However, absence of such changes would not exclude the diagnosis, as the vasculitic features are variable and affected tissue may not have been sampled at the time. Renal biopsy is usually not helpful and carries a greater risk than usual of bleeding and the formation of arteriovenous fistulae [32, 47].

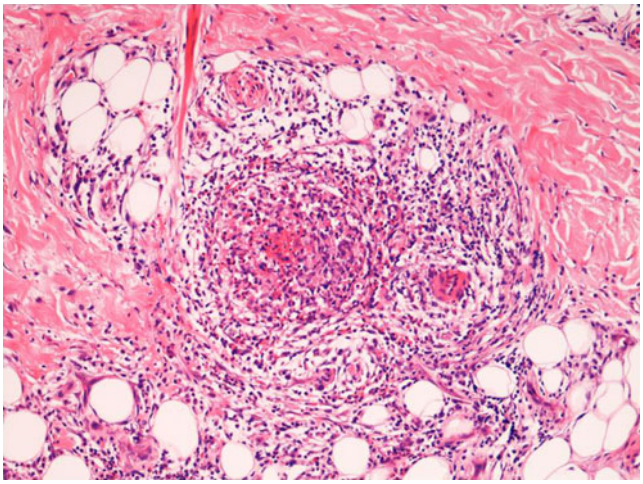

Fig. 1 Polyarteritis nodosa (PAN), acute phase. High-power view of skin biopsy from a 4-year-old boy with PAN. Biopsy shows a neutrophilic vasculitis affecting medium and small arteries in the deep dermis and subcutis. There is also an associated lobular panniculitis

Indirect evidence of the presence of medium-size artery vasculitis affecting the renal arteries may be obtained by demonstrating patchy areas within the renal parenchyma of decreased isotope uptake on Tc-99m dimercaptosuccinic acid (DMSA) scanning of the kidneys [34, 48]. However, the most valuable investigative procedure is renal and hepatic ± mesenteric angiography. Radiological findings include aneurysms, segmental narrowing and variations in the calibre of arteries, together with pruning of the peripheral vascular tree [26, 33, 49–51] (Fig. 2). Magnetic resonance angiography (MRA) usually fails to detect microaneurysms, although it can demonstrate large intra- and extrarenal aneurysms and stenoses/occlusions of the renal arteries or their branches and areas of ischaemia and infarction [52]. However, MRA overestimates vascular stenotic lesions [53, 54]. Computed tomography angiography (CTA) may also reveal larger aneurysms and occlusive lesions and demonstrate areas of cortical ischaemia and infarction but at the expense of high ionising radiation exposure, which is a concern in childhood [52, 54, 55].

Although not a routine investigative procedure, the recently developed measurements of circulating endothelial microparticles and circulating endothelial cells may prove helpful in demonstrating the presence of active vasculitic disease as well as throwing light on the mechanisms involved [56–62]. Furthermore, measurement of circulating endothelial progenitor cells may be helpful in pointing to evidence of a repair process being under way in the recovery phase of disease [61, 63]. However, this may not be so clear cut in children and further work is necessary to clarify their role [64, 65].

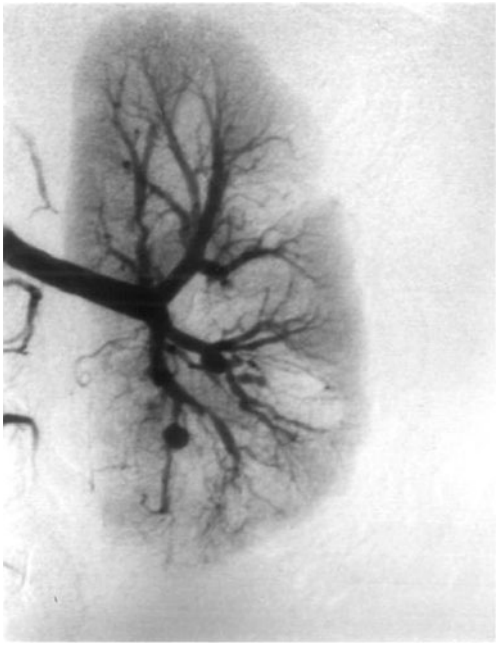

Fig. 2 A renal angiogram from a 6-year-old girl with polyarteritis nodosa (PAN) demonstrating florid aneurysmal and nonaneurysmal changes. There are large and small aneurysms, perfusion defects, arterial cutoff and lack of crossing of peripheral renal arteries (From Brogan et al. [33] with permission)

Aetiopathogenesis

The aetiology of PAN remains unclear, but there are data to support roles for hepatitis B [40, 41] and reports of a higher frequency of exposure to parvovirus B19 and cytomegalovirus in PAN patients compared with control populations [66, 67]. HIV has also been implicated [68], and PAN-like illnesses have been reported in association with cancers and haematological malignancies [69]. However, in childhood, associations between PAN and these infections or other conditions are rare. Evidence has emerged suggesting that bacterial superantigens may play a role in some cases [70]. Occasional reports link PAN to immunisation, but the evidence is not convincing. It seems likely that the immunological processes involved are similar to those in other systemic vasculitides and include immune complexes, complement, possibly autoantibodies, cell adhesion molecules, cytokines, growth factors, chemokines, neutrophils and T cells [71, 72]. Recent evidence that rituximab can be successful therapeutically suggests that B cells also have a pathogenetic role [24]. There may be genetically predisposing factors that may make individuals vulnerable to PAN and other vasculitides. An example of this is the link with familial Mediterranean fever [36, 37]. There are three reports of PAN occurring in siblings that add weight to this hypothesis, but there are no detailed genetic studies [73–75].

Treatment

For many years, PAN treatment has involved administration of high-dose steroid with an additional cytotoxic agent, such as cyclophosphamide, to induce remission [76–82]. In most patients, it is appropriate to treat aggressively. However, in those presenting with mild disease, verging on CPAN, steroid alone is sometimes recommended. Cyclophosphamide might be given orally in a dose of 2 mg/kg per day for 2–3 months or by pulsed monthly intravenous injections for up to 6 months or for shorter periods in children if remission is achieved. Aspirin has also been prescribed empirically as an antiplatelet agent [24]. Once remission is achieved, maintenance therapy with daily or alternate-day low-dose prednisolone and oral azathioprine is frequently used for up to 18 months [80]. Other maintenance agents include methotrexate, mycophenolate mofetil and cyclosporin A [82]. Adjunctive plasma exchange can be used in life-threatening situations [83, 84], and more recently, successful treatment with biologic agents such as infliximab or rituximab has been reported for those unresponsive to conventional therapy [24, 80–82, 85–88]. Treatment response can be assessed using a modified Birmingham Vasculitis Activity Score [82].

Outcome

PAN, unlike some other vasculitides such as WG, appears to be a condition in which permanent remission can be achieved. Relapses can occur, but despite these, a real possibility of cure can be anticipated. However, if treatment is delayed or inadequate, life-threatening complications can occur due to the vasculitic process. Severe complications, especially infections, can occur from treatment with immunosuppressive drugs [77, 81, 89, 90]. In comparison with the almost 100% mortality rate in the presteroid era [91], mortality rates as low as 1.1% were reported in a recent retrospective multicentre analysis [40]. However, this may not truly reflect mortality in circumstances of severe disease because 30% of patients in that series were considered to have CPAN. A mortality rate of 10% was recently recorded from a major tertiary referral centre seeing predominantly children with aggressive advanced disease [92]. Late morbidity can occur years after childhood PAN from chronic vascular injury, resulting in premature atherosclerosis [93] (Fig. 3). This remains a cause for concern and an area of ongoing research.

Cutaneous polyarteritis nodosa

CPAN is a form of vasculitis affecting small- and medium-sized vessels limited to the skin [94]. It is characterised by the presence of fever; subcutaneous nodular, painful, nonpurpuric lesions with or without livedo reticularis occurring

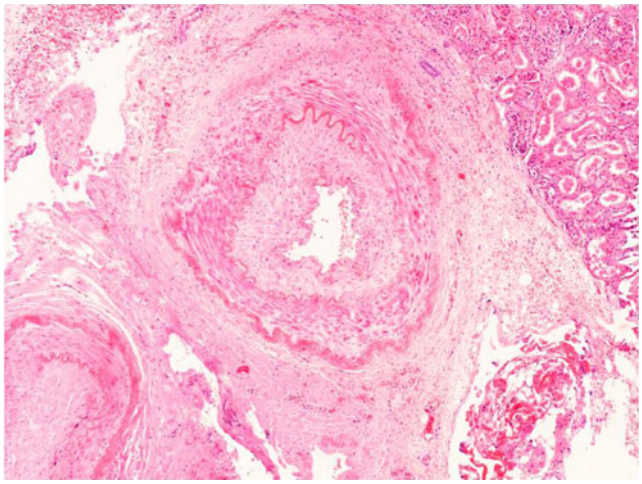

Fig. 3 Late vasculopathy associated with polyarteritis nodosa (PAN). High-power view of histology taken from a heminephrectomy specimen (duplex system and recurrent infection) from a 4-year-old girl with classic severe PAN of 18 months duration who was in remission on treatment. Very abnormal medium-sized arteries are present, consistent with healed vasculitis with internal elastic lamina rupture, fibrosis and intimal thickening but no active vasculitis

predominantly in the lower extremities; with no systemic involvement (except for myalgia, arthralgia and nonerosive arthritis) [94, 95]. It is well recognised in childhood, and there are a number of reports in the literature [40, 96–98]. In a recent international survey of childhood vasculitis, approximately one third of children identified as having PAN were categorised as CPAN [40]. The clinical course is characterised by periodic exacerbations and remissions that may persist for many years and occasionally throughout childhood. Skin biopsy shows necrotizing nongranulomatous small- and medium-sized vessel vasculitis, tests for ANCA are usually negative and the condition is often associated with serological or microbiological evidence of streptococcal infection [99, 100]. Nonrecurring CPAN has been observed in neonates born to mothers with chronic CPAN [94, 101, 102]. There has been much discussion as to whether the condition should be classed as a separate entity or as a part of the spectrum of PAN [94]. In the main, the condition remains localized to the skin [94, 103], although a proportion of cases appear to evolve into full-blown PAN, and clinicians need to be mindful of this possibility [104]. The distinction is difficult, and patients with more extensive clinical involvement or lack of response to standard treatment may need to be further evaluated and possibly treated as if they had PAN [105]. There are some investigators who feel that their data support the view that CPAN does not progress to PAN [106].

Treatment

The condition may respond to nonsteroidal anti-inflammatory drugs [96, 107] but can achieve remission with moderate doses of oral steroids [94]. When streptococcal infection is implicated, penicillin may be effective [100, 108]. Some clinicians recommend continuing prophylactic penicillin throughout childhood, as relapses are common and occur in up to 25% of cases in association with further streptococcal infections [100, 109]. When there is a lack of response to standard treatment or concerns about possible steroid toxicity, intravenous immunoglobulin (IV-Ig) has been successfully used [110]. Some success has also been reported with methotrexate [111], colchicine and dapsone [112], cyclophosphamide [98], pentoxifylline [113] and chloroquine [114].

Outcome

Many, but not all, patients experience a persistence of cutaneous lesions through childhood, but it is uncommon for the condition to progress to PAN [94]. However, it is mandatory for such patients to remain under surveillance to detect any evidence of developing systemic disease that would be an indication for intensification of treatment along the lines of that required for PAN.

Kawasaki disease

KD is an acute self-limiting systemic vasculitis predominantly affecting young children. Distribution is worldwide, with a male preponderance, an ethnic bias towards Asian children, seasonality and occasional epidemics [115–119]. It is the second commonest vasculitic illness of childhood (HSP being the commonest) and the commonest cause of acquired heart disease in children in the UK and USA [120–122]. The incidence in Japan is 138/100,000 [123] in children younger than 5 years, whereas in the United States, it is 17.1 [124] and in the UK 8.1 [125].

Clinical manifestations

The principal clinical features are fever persisting for 5 days or more, peripheral extremity changes (reddening of the palms and soles, indurative oedema and subsequent desquamation), a polymorphous exanthema, bilateral conjunctival injection/congestion, lips and oral cavity changes (reddening/cracking of lips, strawberry tongue, oral and pharyngeal injection) and cervical lymphadenopathy (acute nonpurulent). For the diagnosis to be established according to the Diagnostic Guidelines of the Japan Kawasaki Disease Research Committee, five of six criteria should be present [126]. The North American recommendations for the diagnosis are similar, except that fever is a mandatory criterion and four of the remaining five criteria are required to establish the diagnosis [127]. If coronary artery aneurysms are present, fewer features may be necessary for diagnostic

purposes [126]. These diagnostic criteria, with minor modifications, were adopted as classification criteria for KD, but perineal desquamation was added to the criteria at the Vienna Consensus Conference on the Classification of Childhood Vasculitides [5] describing changes in extremities. Cardiovascular features are the most important manifestations of the condition, with widespread vasculitis affecting predominantly medium-size muscular arteries, especially the coronary arteries. Coronary artery involvement occurs in 15–25% of untreated cases, with additional cardiac features in a significant proportion of these, including pericardial effusion, electrocardiographic abnormalities, pericarditis, myocarditis, valvular incompetence, cardiac failure and myocardial infarction [128, 129]. Vascular damage to the major limb arteries, renal and other visceral vessels and the aorta can be demonstrated [129, 130]. Other systemic involvement can occur, including in the gastrointestinal tract [131], the hepatobiliary tract with hydrops of the gall bladder being well recognised [132], the respiratory tract [133], the central nervous system with seizures and meningeal features [134], deafness [135], arthropathy [136] and renal involvement. Renal manifestations include pyuria, proteinuria, tubular disturbances, tubulointerstitial nephritis and renal failure [137–147]. The mechanism of the renal impairment is unclear, and there is some evidence suggesting that IV-Ig used in treatment might play a part [148]. Another clinical sign that may be relatively specific to KD is the development of erythema and induration at sites of Bacillus Calmette-Guérin (BCG) inoculations [149]. The mechanism of this is thought to be cross-reactivity of T cells in KD between specific epitopes of mycobacterial and human heat-shock proteins [150].

Diagnostic laboratory and other investigations

Polymorphonuclear leukocytosis, thrombocythemia and increased ESR and CRP are characteristic findings in the acute phase of KD [116, 118]. Two-dimensional echocardiography is the means of identifying coronary artery involvement acutely and monitoring changes long term [116, 118]. Coronary angiography has a role, especially in the presence of giant coronary artery aneurysms or in circumstances when stenotic lesions are suspected, but provides little information about the microvasculature [118, 151]. Dobutamine stress echocardiography has a role in follow-up evaluation [152]. Spiral CTA [153] and MRA [154] have been advocated, but the former is associated with significant radiation and the latter has limited resolution. Coronary arteriography has an important role for delineating detailed anatomical injury, particularly for children with giant coronary artery aneurysms (>8 mm), in which stenoses adjacent to the inlet/outlet of the aneurysms are a concern. It is important to note that coronary arteriography should be delayed until at least 6 months after disease onset, as there could be a risk of myocardial infarction if performed in children with ongoing severe coronary artery inflammation [118].

Aetiopathogenesis

The aetiology of KD is unknown, but it is thought that some ubiquitous infectious agent produces an abnormal immunological response in a genetically susceptible individual, which results in the characteristic clinical picture. A number of polymorphisms have been identified that appear to be linked to disease susceptibility or the risk of coronary artery aneurysms [155, 156]. A genome-wide association study identified five genes with functional relationships to inflammation, apoptosis and cardiovascular pathology [157]. In addition, another study has reported an association of the functional polymorphism of the inositol 1,4,5-triphosphate 3-kinase C (ITPKC) gene with immune activation of KD [158]. ITPKC acts as a negative regulator of T-cell activation and may contribute to immune hyper-reactivity in KD. Furthermore, there is some evidence that a bacterial toxin causes KD [155]. This hypothesis is based on clinical and immunological similarities between KD and staphylococcal or streptococcal toxin-mediated illnesses and the recent observations that some children with KD seroconvert with IgM antibodies against a number of bacterial superantigens [159]. However, an alternative view is that the immune response in KD is oligoclonal (as with conventional antigens) and that IgA plasma cells play a central role [160].

Treatment

Treatment of KD with aspirin and IV-Ig has been shown to reduce the occurrence of coronary artery aneurysms [118, 161]. IV-Ig is recommended within 10 days of disease onset but is also appropriate for late presenters with active disease [116, 118]. IV-Ig resistance occurs in up to 20% of cases [118]. In such circumstances, corticosteroids have been advocated, but there are conflicting data from various randomised controlled trials as to their effectiveness [162–166]. From these data it is suggestive that perhaps corticosteroids need to be given over a more protracted period to achieve benefit, as the major studies used a single IV dose of methylprednisolone. All studies have been complicated by the need to evaluate steroid treatment along with IV-Ig, as it has not been considered ethically appropriate to undertake a trial directly comparing steroid with IV-Ig. Anecdotally, however, there are reports of steroid being beneficial when IV-Ig has failed and also of the effective use of steroid in patients who have refused IV-Ig on the basis of being Jehovah's Witnesses [116, 167, 168]. Additionally, there is

some evidence that steroid given as pulsed methylprednisolone plus gammaglobulin may have a role as initial treatment in high-risk KD patients [169]. More recently, there are reports of the beneficial effects of infliximab in the treatment of IV-Ig-resistant KD [169–171].

In the convalescent phase, if aneurysms persist, antiplatelet therapy in the form of low-dose aspirin should be continued long term until the aneurysms resolve [116]. In the presence of giant aneurysms (>8 mm), warfarin is recommended in addition to aspirin [118]. Some patients may require coronary angioplasty or a revascularisation procedure should ischemic symptoms arise or evidence of obstruction occur [129].

Outcome

The outlook for KD patients is generally good. The acute mortality rate in Japan is 1.14 [172, 173]. Angiographic resolution 1–2 years after disease onset has been observed in 50–70% of vessels with coronary aneurysms [174]. About 20% of patients who develop coronary artery aneurysms during the acute stage of the disease will develop coronary artery stenoses [174], and the risk is greater with large (giant) aneurysms [175]. However, there are data suggesting that, despite seeming recovery, there are long-term cardiovascular sequelae that persist into adult life and that may have important implications. Impaired endothelial function in peripheral [176, 177] and coronary arteries [178] has been reported, as have increased carotid media thickness and arterial stiffness [179]. Perhaps more important than these studies of novel surrogate markers for subclinical atherosclerosis is the long-term epidemiological data from Japan. In the seventh look at the long-term outcomes of a cohort of 6,576 patients with KD enrolled between 1982 and 2004, the mortality rate for patients without cardiac sequelae in the acute phase of the disease and for female patients with sequelae did not differ from the normal population [172]. The mortality rate of male patients with cardiac sequelae was, however, 2.4 times higher than the normal population [172]. Epidemiological studies from Japan also have demonstrated that late sequelae, especially in patients with large aneurysms, include myocardial ischaemia with a frequency of 3% within 4 years after the disease onset [118].

Conclusion

Vasculitis affecting medium-size vessels does occur in childhood. The distinction from other conditions is often difficult, especially in the context of PAN, although it is usually possible to categorise the disorders into clinical-pathological entities. Further studies are needed on the aetiopathogenetic mechanisms involved in the development of these vasculitides that might hopefully lead to more focussed therapeutic approaches. Although current treatment has made a major impact on disease activity control, there remains a need for more randomised controlled trials, especially using newer biologic agents, to establish their roles in therapy. Finally, more follow-up studies are needed to establish the long-term implications of developing these conditions in childhood.

Multiple-choice questions:
(Answers appear following the reference list)

1. Which of the following is true in relation to childhood PAN?
   a. Crescentic glomerulonephritis is a well-recognised complication
   b. There is often a discrepancy between the ESR and the CRP results
   c. Cytoplasmic ANCA is usually detectable
   d. Livido reticularis is a characteristic feature
2. In childhood PAN, which of the following statements is correct?
   a. Most cases have an infective aetiology
   b. Renal and hepatic angiography is a valuable investigative tool
   c. The aorta is frequently affected
   d. Cyclophosphamide is contraindicated because of side effects
3. In relation to cutaneous childhood PAN, which of the following is true?
   a. Pyoderma gangrenosum is a severe manifestation
   b. Leukocytoclastic vasculitis is a characteristic histological finding
   c. The condition rarely progresses to systemic PAN
   d. It is the commonest cause of vasculitis involving the skin in children
4. Regarding KD, which of the following is correct?
   a. IV-Ig can be effective if administered later than 10 days after disease onset
   b. Only coronary arteries are affected
   c. Acute glomerulonephritis is the usual renal manifestation
   d. The disease is unlikely unless all criteria are met
5. For KD, which of the following is false?
   a. There is evidence for genetically determined susceptibility to the disease
   b. Long-term endothelial dysfunction has been demonstrated after the acute phase
   c. Female patients with cardiac sequelae have a higher mortality rate than male patients
   d. There are data supporting an aetiological role for superantigens

References

1. Tervaert JW, Kallenberg C (1993) Neurologic manifestations of systemic vasculitides. Rheum Dis Clin North Am 19:913–940
2. Jennette JC, Falk RJ (1997) Small-vessel vasculitis. N Engl J Med 337:1512–1523
3. Jennette JC, Falk RJ, Andrassy K, Bacon PA, Churg J, Gross WL, Hagen EC, Hoffman GS, Hunder GG, Kallenberg CG, McClusky RT, Sinico A, Rees AJ, vanEs LA, Waldherr R, Wiik A (1994) Nomenclature of systemic vasculitides: proposal of an international consensus conference. Arthritis Rheum 37:187–192
4. Savage CO, Harper L, Adu D (1997) Primary systemic vasculitis. Lancet 349:553–558
5. Ozen S, Ruperto N, Dillon MJ, Bagga A, Barron K, Davin JC, Kawasaki T, Lindsley C, Petty RE, Prieur AM, Ravelli A, Woo P (2006) EULAR/PReS endorsed consensus criteria for the classification of childhood vasculitides. Ann Rheum Dis 65:936–941
6. Fink CW (1986) Vasculitis. Pediatr Clin North Am 33:1203–1219
7. Dillon MJ (1998) Childhood vasculitis. Lupus 7:259–265
8. Lie JT (1994) Nomenclature and classification of vasculitis: plus ça change, plus c'est la même chose. Arthritis Rheum 37:181–186
9. Cassidy JT, Petty RE (2005) Polyarteritis nodosa and related vasculitides. In: Cassidy JT, Petty RE (eds) Textbook of pediatric rheumatology, 5th edn. Elsevier Saunders, Philadelphia, pp 512–552
10. Kussmaul A, Maier R (1866) Über eine bisher nicht beschriebene eigenthümliche Arterienerkrankung (Periarteriitis nodosa), die mit Morbus Brightii und rapid fortschreitender allgemeiner Muskellähmung einhergeht. Dtsch Arch Klin Med 1:484–518
11. Watts RA, Scott DGI (2008) Epidemiology of vasculitis. In: Ball GV, Bridges SL (eds) Vasculitis, 2nd edn. Oxford University Press, Oxford, pp 7–21
12. Dillon MJ (1989) Classification and pathogenesis of arteritis in children. Toxicol Pathol 17:214–218
13. Ozen S, Bakkaloglu A, Dusunsel R, Soylemezoglu O, Ozaltin F, Poyrazoglu H, Kasapcopur O, Ozkaya O, Yalcinkaya F, Balat A, Kural N, Donmez O, Alpay H, Anarat A, Mir S, Gur-Guven A, Sonmez F, Gok F (2007) Childhood vasculitides in Turkey: a nationwide survey. Clin Rheumatol 26:196–200
14. Lightfoot RW Jr, Michel BA, Bloch DA, Hunder GG, Zvaifler NJ, McShane DJ, Arend WP, Calabrese LH, Leavitt RY, Lie JT, Masi AT, Mitts JH, Stevens MB, Wallace SL (1990) The American College of Rheumatology 1990 criteria for the classification of polyarteritis nodosa. Arthritis Rheum 33:1088–1093
15. Dillon MJ, Ozen S (2006) A new international classification of childhood vasculitis. Pediatr Nephrol 21:1219–1222
16. Ozen S, Pistorio A, Iusan MS, Ravelli A, Cuttica R, Lovell DJ, Anton J, Bilge I, Garay SM, Saad Magalhaes C, Kondi A, Bircan Z, Breda L, Cimaz R, Kanakoudi Tsakalidou F, Magni Manzoni S, Maldonado MR, Stanevicha V, Tambic-Bukovac L, Unsal E, Martini A, Ruperto N, for PRINTO (2009) The EULAR/PRINTO/PRES criteria for childhood polyarteritis nodosa. Ankara 2008. Ann Rheum Dis 68(Suppl 3):713
17. Hunder GG (1998) The use and misuse of classification and diagnostic criteria for complex diseases. Ann Intern Med 129:417–418
18. Ozen S, Besbas N, Saatci U, Bakkaloglu A (1992) Diagnostic criteria for polyarteritis nodosa in childhood. J Pediatr 120: 206–209
19. Fink CW (1977) Polyarteritis and other diseases with necrotizing vasculitis in childhood. Arthritis Rheum 20:378–384
20. Reimold EW, Weinberg AG, Fink CW, Battles ND (1976) Polyarteritis in children. Am J Dis Child 130:534–541
21. Magilavy DB, Petty RE, Cassidy JT, Sullivan DB (1977) A syndrome of childhood polyarteritis. J Pediatr 91:25–30
22. Ettlinger RE, Nelson AM, Burke EC, Lie JT (1979) Polyarteritis nodosa in childhood a clinical pathologic study. Arthritis Rheum 22:820–825
23. Maeda M, Kobayashi M, Okamoto S, Fuse T, Matsuyama T, Watanabe N, Fujikawa S (1997) Clinical observation of 14 cases of childhood polyarteritis nodosa in Japan. Acta Paediatr Jpn 39:277–279
24. Eleftheriou D, Dillon MJ, Brogan PA (2009) Advances in childhood vasculitis. Curr Opin Rheumatol 21:411–418
25. Petty RE, Magilavy DB, Cassidy JT, Sullivan DB (1977) Polyarteritis in childhood. A clinical description of eight cases. Arthritis Rheum (Suppl 20):392–394
26. Besbas N, Ozen S, Saatci U, Topaloglu R, Tinaztepe K, Bakkaloglu A (2000) Renal involvement in polyarteritis nodosa: evaluation of 26 Turkish children. Pediatr Nephrol 14:325–327
27. Cakar N, Ozcakar ZB, Soy D, Ucar Y, Fitoz S, Kara N, Uncu N, Atakan C, Ekim M, Yalcinkaya F (2008) Renal involvement in childhood vasculitis. Nephron Clin Pract 108:c202–c206
28. Topaloglu R, Besbas N, Saatci U, Bakkaloglu A, Oner A (1992) Cranial nerve involvement in childhood polyarteritis nodosa. Clin Neurol Neurosurg 94:11–13
29. Engel DG, Gospe SM Jr, Tracy KA, Ellis WG, Lie JT (1995) Fatal infantile polyarteritis nodosa with predominant central nervous system involvement. Stroke 26:699–701
30. Ragge NK, Harris CM, Dillon MJ, Chong WK, Elston J, Taylor DS (2003) Ocular tilt reaction due to a mesencephalic lesion in juvenile polyarteritis nodosa. Am J Ophthalmol 135:249–251
31. Tizard EJ, Dillon MJ (2006) Wegener's granulomatosis, polyarteritis nodosa, Behcet's disease and relapsing polychondritis. In: Harper J, Oranje A, Prose N (eds) Textbook of pediatric dermatology, 2nd edn. Blackwell, Oxford, pp 1937–1952
32. Guillevin L, Pagnoux C, Teixeira L (2008) Polyarteritis nodosa. In: Ball GV, Bridges SL (eds) Vasculitis, 2nd edn. Oxford University Press, Oxford, pp 335–353
33. Brogan PA, Davies R, Gordon I, Dillon MJ (2002) Renal angiography in children with polyarteritis nodosa. Pediatr Nephrol 17:277–283
34. Dillon MJ (1990) Vasculitic syndromes. In: Woo P, White PH, Ansell BM (eds) Paediatric rheumatology update. Oxford University Press, Oxford, pp 227–242
35. Tasdemir I, Turgan C, Emri S, Yasavul U, Caglar S, Bakkaloglu M, Erkan I, Erol D (1988) Spontaneous perirenal haematoma secondary to polyarteritis nodosa. Br J Urol 62:219–222
36. Glikson M, Galun E, Schlesinger M, Cohen D, Haskell L, Rubinow A, Eliakim M (1989) Polyarteritis nodosa and familial Mediterranean fever: a report of 2 cases and review of the literature. J Rheumatol 16:536–539
37. Ozen S, Ben-Chetrit E, Bakkaloglu A, Gur H, Tinaztepe K, Calguneri M, Turgan C, Turkmen A, Akpolat I, Danaci M, Besbas N, Akpolat T (2001) Polyarteritis nodosa in patients with Familial Mediterranean Fever (FMF): a concomitant disease or a feature of FMF? Semin Arthritis Rheum 30:281–287
38. Bywaters EG (1968) The Cheshire cat syndrome. Postgrad Med J 44:19–22
39. Levin M, Holland PC, Nokes TJ, Novelli V, Mola M, Levinsky RJ, Dillon MJ, Barratt TM, Marshall WC (1985) Platelet immune complex interaction in pathogenesis of Kawasaki disease and childhood polyarteritis. Br Med J (Clin Res Ed) 290:1456–1460
40. Ozen S, Anton J, Arisoy N, Bakkaloglu A, Besbas N, Brogan P, Garcia-Consuegra J, Dolezalova P, Dressler F, Duzova A, Ferriani VP, Hilario MO, Ibanez-Rubio M, Kasapcopur O, Kuis

W, Lehman TJ, Nemcova D, Nielsen S, Oliveira SK, Schikler K, Sztajnbok F, Terreri MT, Zulian F, Woo P (2004) Juvenile polyarteritis: results of a multicenter survey of 110 children. J Pediatr 145:517–522
41. Guillevin L, Mahr A, Callard P, Godmer P, Pagnoux C, Leray E, Cohen P (2005) Hepatitis B virus-associated polyarteritis nodosa: clinical characteristics, outcome, and impact of treatment in 115 patients. Medicine (Baltimore) 84:313–322
42. Gaskin G, Savage CO, Ryan JJ, Jones S, Rees AJ, Lockwood CM, Pusey CD (1991) Anti-neutrophil cytoplasmic antibodies and disease activity during long-term follow-up of 70 patients with systemic vasculitis. Nephrol Dial Transplant 6:689–694
43. Hauschild S, Csernok E, Schmitt WH, Gross WL (1994) Antineutrophil cytoplasmic antibodies in systemic polyarteritis nodosa with and without hepatitis B virus infection and Churg-Strauss syndrome-62 patients. J Rheumatol 21:1173–1174
44. Wong SN, Shah V, Dillon MJ (1998) Antineutrophil cytoplasmic antibodies in Wegener's granulomatosis. Arch Dis Child 79: 246–250
45. Bakkaloglu A, Ozen S, Baskin E, Besbas N, Gur-Guven A, Kasapcopur O, Tinaztepe K (2001) The significance of antineutrophil cytoplasmic antibody in microscopic polyangitis and classic polyarteritis nodosa. Arch Dis Child 85:427–430
46. Churg A (2008) Pathologic features of vasculitis. In: Ball GV, Bridges SL (eds) Vasculitis, 2nd edn. Oxford University Press, Oxford, pp 97–114
47. Curren RE, Steinberg I, Hagstrom WC (1967) Arteriovenous fistula complicating percutaneous renal biopsy in polyarteritis nodosa. Am J Med 43:465–470
48. Basoglu T, Akpolat T, Canbaz F, Bernay I, Albayrak S, Kilic M, Danaci M (1999) Tc-99m DMSA renal scan in polyarteritis nodosa with bilateral intraparenchymal renal artery aneurysms. Clin Nucl Med 24:201–202
49. Ewald EA, Griffin D, McCune WJ (1987) Correlation of angiographic abnormalities with disease manifestations and disease severity in polyarteritis nodosa. J Rheumatol 4:952–956
50. Hekali P, Kajander H, Pajari R, Stenman S, Somer T (1991) Diagnostic significance of angiographically observed visceral aneurysms with regard to polyarteritis nodosa. Acta Radiol 32: 143–148
51. Saddekni S, Horesh L, Leonardo R, Kasthuri S (2008) Angiography and percutaneous interventions. In: Ball GV, Bridges SL (eds) Vasculitis, 2nd edn. Oxford University Press, Oxford, pp 227–245
52. Sabater EA, Stanson AW (2008) Cross sectional imaging in vasculitis. In: Ball GV, Bridges SL (eds) Vasculitis, 2nd edn. Oxford University Press, Oxford, pp 247–265
53. Schmidt WA (2004) Use of imaging studies in the diagnosis of vasculitis. Curr Rheumatol Rep 6:203–211
54. Ozaki K, Miyayama S, Ushiogi Y, Matsui O (2009) Renal involvement of polyarteritis nodosa: CT and MR findings. Abdom Imaging 34:265–270
55. Ozcakar ZB, Yalcinkaya F, Fitoz S, Yuksel S, Acar B, Caltik A, Ekim M (2006) Polyarteritis nodosa: successful diagnostic imaging utilizing pulsed and color Doppler ultrasonography and computed tomography angiography. Eur J Pediatr 165:120–123
56. Brogan PA, Dillon MJ (2004) Endothelial microparticles and the diagnosis of the vasculitides. Intern Med 43:1115–1119
57. Brogan PA, Shah V, Brachet C, Harnden A, Mant D, Klein N, Dillon MJ (2004) Endothelial and platelet microparticles in vasculitis of the young. Arthritis Rheum 50:927–936
58. Erdbruegger U, Grossheim M, Hertel B, Wyss K, Kirsch T, Woywodt A, Haller H, Haubitz M (2008) Diagnostic role of endothelial microparticles in vasculitis. Rheumatology (Oxford) 47:1820–1825
59. Woywodt A, Goldberg C, Kirsch T, de Groot K, Erdbruegger U, Haller H, Haubitz M (2006) Circulating endothelial cells in relapse and limited granulomatous disease due to ANCA associated vasculitis. Ann Rheum Dis 65:164–168
60. Holmen C, Elsheikh E, Stenvinkel P, Qureshi AR, Pettersson E, Jalkanen S, Sumitran-Holgersson S (2005) Circulating inflammatory endothelial cells contribute to endothelial progenitor cell dysfunction in patients with vasculitis and kidney involvement. J Am Soc Nephrol 16:3110–3120
61. de Groot K, Goldberg C, Bahlmann FH, Woywodt A, Haller H, Fliser D, Haubitz M (2007) Vascular endothelial damage and repair in antineutrophil cytoplasmic antibody-associated vasculitis. Arthritis Rheum 56:3847–3853
62. Haubitz M, Woywodt A (2004) Circulating endothelial cells and vasculitis. Intern Med 43:660–667
63. Kawamoto A, Asahara T (2009) Vascular regeneration therapy for intractable vasculitis. Nippon Rinsho 67:612–618
64. Clark LA, Hong Y, Eleftheriou D, Klein N, Brogan PA (2008) Endothelial progenitor cells and vasculogenic responses to therapy in children with primary systemic vasculitis. Pediatr Rheumatol 6(Suppl 1):S22
65. Eleftheriou D, Clarke LA, Hong Y, Klein N, Ganesan V, Brogan PA (2008) Circulating endothelial cells and endothelial progenitor cells in childhood primary angiitis of the central nervous system. Pediatr Rheumatol 6(Suppl 1):P276
66. Finkel TH, Torok TJ, Ferguson PJ, Durigon EL, Zaki SR, Leung DY, Harbeck RJ, Gelfand EW, Saulsbury FT, Hollister JR (1994) Chronic parvovirus B19 infection and systemic necrotising vasculitis: opportunistic infection or aetiological agent? Lancet 343:1255–1258
67. Golden MP, Hammer SM, Wanke CA, Albrecht MA (1994) Cytomegalovirus vasculitis. Case reports and review of the literature. Medicine (Baltimore) 73:246–255
68. Pagnoux C, Cohen P, Guillevin L (2006) Vasculitides secondary to infections. Clin Exp Rheumatol 24(Suppl 4): S71–S81
69. Fain O, Hamidou M, Cacoub P, Godeau B, Wechsler B, Paries J, Stirnemann J, Morin AS, Gatfosse M, Hanslik T, Belmatoug N, Bletry O, Cevallos R, Delevaux I, Fisher E, Hayem G, Kaplan G, Le HC, Mouthon L, Larroche C, Lemaire V, Piette AM, Piette JC, Ponge T, Puechal X, Rossert J, Sarrot-Reynauld F, Sicard D, Ziza JM, Kahn MF, Guillevin L (2007) Vasculitides associated with malignancies: analysis of sixty patients. Arthritis Rheum 57:1473–1480
70. Brogan PA, Shah V, Bagga A, Klein N, Dillon MJ (2003) T cell Vbeta repertoires in childhood vasculitides. Clin Exp Immunol 131:517–527
71. Guillevin L, Lhote F, Amouroux J, Gherardi R, Callard P, Casassus P (1996) Antineutrophil cytoplasmic antibodies, abnormal angiograms and pathological findings in polyarteritis nodosa and Churg-Strauss syndrome: indications for the classification of vasculitides of the polyarteritis nodosa group. Br J Rheumatol 35:958–964
72. Ball GV, Bridges SL (2008) Pathogenesis of vasculitis. In: Ball GV, Bridges SL (eds) Vasculitis, 2nd edn. Oxford University Press, Oxford, pp 67–88
73. Leff R, Harrer WV, Baylis JC, Jackson L, Faber K (1971) Polyarteritis nodosa in two siblings. Am J Dis Child 121:67–70
74. Rottem M, Cotch MF, Fauci AS, Hoffman GS (1994) Familial vasculitis: report of 2 families. J Rheumatol 21:561–563
75. Mason JC, Cowie MR, Davies KA, Schofield JB, Cambridge J, Jackson J, So A, Allard SA, Walport MJ (1994) Familial polyarteritis nodosa. Arthritis Rheum 37:1249–1253
76. Brogan PA, Dillon MJ (2000) Vasculitis from the pediatric perspective. Curr Rheumatol Rep 2:411–416

77. Brogan PA, Dillon MJ (2000) The use of immunosuppressive and cytotoxic drugs in non-malignant disease. Arch Dis Child 83:259–264
78. Leib ES, Restivo C, Paulus HE (1979) Immunosuppressive and corticosteroid therapy of polyarteritis nodosa. Am J Med 67:941–947
79. Fauci AS, Katz P, Haynes BF, Wolff SM (1979) Cyclophosphamide therapy of severe systemic necrotizing vasculitis. N Engl J Med 301:235–238
80. Dillon MJ (2006) Vasculitis treatment - new therapeutic approaches. Eur J Pediatr 165:351–357
81. Jayne D (2003) Current attitudes to the therapy of vasculitis. Kidney Blood Press Res 26:231–239
82. Eleftheriou D, Melo M, Marks SD, Tullus K, Sills J, Cleary G, Dolezalova P, Ozen S, Pilkington C, Woo P, Klein N, Dillon MJ, Brogan PA (2009) Biologic therapy in primary systemic vasculitis of the young. Rheumatology 48:978–986
83. Gianviti A, Trompeter RS, Barratt TM, Lythgoe MF, Dillon MJ (1996) Retrospective study of plasma exchange in patients with idiopathic rapidly progressive glomerulonephritis and vasculitis. Arch Dis Child 75:186–190
84. Wright E, Dillon MJ, Tullus K (2007) Childhood vasculitis and plasma exchange. Eur J Pediatr 166:145–151
85. de Kort SW, van Rossum MA, ten Cate R (2006) Infliximab in a child with therapy-resistant systemic vasculitis. Clin Rheumatol 25:769–771
86. Sonomoto K, Miyamura T, Watanabe H, Takahama S, Nakamura M, Ando H, Minami R, Yamamoto M, Saito T, Imayama S, Hosokawa C, Suematsu E (2008) A case of polyarteritis nodosa successfully treated by rituximab. Nihon Rinsho Meneki Gakkai Kaishi 31:119–123
87. Al-Bishri J, le Riche N, Pope JE (2005) Refractory polyarteritis nodosa successfully treated with infliximab. J Rheumatol 32:1371–1373
88. Wu K, Throssell D (2006) A new treatment for polyarteritis nodosa. Nephrol Dial Transplant 21:1710–1712
89. Beimler JH, Andrassy K (2004) Cyclophosphamide treatment in systemic necrotizing vasculitis and lupus nephritis. How long? How much? Pediatr Nephrol 19:949–955
90. Gayraud M, Guillevin L, Le Toumelin P, Cohen P, Lhote F, Casassus P, Jarrousse B (2001) Long-term follow-up of polyarteritis nodosa, microscopic polyangiitis, and Churg-Strauss syndrome: analysis of four prospective trials including 278 patients. Arthritis Rheum 44:666–675
91. Royer P, Levy M, Gagnadoux MF (1954) Glomerular nephropathies in systemic disease. In: Royer P, Habib R, Mathieu H, Broyer M (eds) Pediatric nephrology. WB Saunders, Philadelphia, pp 302–326
92. Brogan PA, Shah V, Dillon MJ (2002) Polyarteritis nodosa in childhood. Abstract. 10th International Vasculitis and ANCA Workshop, Cleveland
93. Cheung YF, Brogan PA, Pilla CB, Dillon MJ, Redington AN (2002) Arterial distensibility in children and teenagers: normal evolution and the effect of childhood vasculitis. Arch Dis Child 87:348–351
94. Bastian HM (2008) Cutaneous polyarteritis nodosa. In: Ball GV, Bridges SL (eds) Vasculitis, 2nd edn. Oxford University Press, Oxford, pp 365–372
95. Daoud MS, Hutton KP, Gibson LE (1997) Cutaneous periarteritis nodosa: a clinicopathological study of 79 cases. Br J Dermatol 136:706–713
96. Sheth AP, Olson JC, Esterly NB (1994) Cutaneous polyarteritis nodosa of childhood. J Am Acad Dermatol 31:561–566
97. Fathalla BM, Miller L, Brady S, Schaller JG (2005) Cutaneous polyarteritis nodosa in children. J Am Acad Dermatol 53:724–728
98. Kumar L, Thapa BR, Sarkar B, Walia BN (1995) Benign cutaneous polyarteritis nodosa in children below 10 years of age-a clinical experience. Ann Rheum Dis 54:134–136
99. Minkowitz G, Smoller BR, McNutt NS (1991) Benign cutaneous polyarteritis nodosa. Relationship to systemic polyarteritis nodosa and to hepatitis B infection. Arch Dermatol 127:1520–1523
100. David J, Ansell BM, Woo P (1993) Polyarteritis nodosa associated with streptococcus. Arch Dis Child 69:685–688
101. Stone MS, Olson RR, Weismann DN, Giller RH, Goeken JA (1993) Cutaneous vasculitis in the newborn of a mother with cutaneous polyarteritis nodosa. J Am Acad Dermatol 28:101–105
102. Boren RJ, Everett MA (1965) Cutaneous vasculitis in mother and child. Arch Dermatol 92:568–570
103. Borrie P (1972) Cutaneous polyarteritis nodosa. Br J Dermatol 87:87–95
104. Chen KR (1989) Cutaneous polyarteritis nodosa: a clinical and histopathological study of 20 cases. J Dermatol 16:429–442
105. Dewar CL, Bellamy N (1992) Necrotizing mesenteric vasculitis after longstanding cutaneous polyarteritis nodosa. J Rheumatol 19:1308–1311
106. Nakamura T, Kanazawa N, Ikeda T, Yamamoto Y, Nakabayashi K, Ozaki S, Furukawa F (2009) Cutaneous polyarteritis nodosa: revisiting its definition and diagnostic criteria. Arch Dermatol Res 301:117–121
107. Siberry GK, Cohen BA, Johnson B (1994) Cutaneous polyarteritis nodosa. Reports of two cases in children and review of the literature. Arch Dermatol 130:884–889
108. Falcini F (2004) Vascular and connective tissue diseases in the paediatric world. Lupus 13:77–84
109. Fink CW (1991) The role of the streptococcus in poststreptococcal reactive arthritis and childhood polyarteritis nodosa. J Rheumatol Suppl 29:14–20
110. Uziel Y, Silverman ED (1998) Intravenous immunoglobulin therapy in a child with cutaneous polyarteritis nodosa. Clin Exp Rheumatol 16:187–189
111. Schartz NE, Alaoui S, Vignon-Pennamen MD, Cordoliani F, Fermand JP, Morel P, Rybojad M (2001) Successful treatment in two cases of steroid-dependent cutaneous polyarteritis nodosa with low-dose methotrexate. Dermatology 203:336–338
112. Maillard H, Szczesniak S, Martin L, Garot D, Machet MC, Machet L, Lorette G, Vaillant L (1999) Cutaneous periarteritis nodosa: diagnostic and therapeutic aspects of 9 cases. Ann Dermatol Venereol 126:125–129
113. Calderon MJ, Landa N, Aguirre A, Diaz-Perez JL (1993) Successful treatment of cutaneous PAN with pentoxifylline. Br J Dermatol 128:706–708
114. Ginarte M, Pereiro M, Toribio J (1998) Cutaneous polyarteritis nodosa in a child. Pediatr Dermatol 15:103–107
115. Kawasaki T (1967) Acute febrile mucocutaneous syndrome in young children with unique digital desquamation. Jpn J Allergol 16:178–222
116. Brogan PA, Bose A, Burgner D, Shingadia D, Tulloh R, Michie C, Klein N, Booy R, Levin M, Dillon MJ (2002) Kawasaki disease: an evidence based approach to diagnosis, treatment, and proposals for future research. Arch Dis Child 86:286–290
117. Burns JC, Glode MP (2004) Kawasaki syndrome. Lancet 364:533–544
118. Newburger JW, Takahashi M, Gerber MA, Gewitz MH, Tani LY, Burns JC, Shulman ST, Bolger AF, Ferrieri P, Baltimore RS, Wilson WR, Baddour LM, Levison ME, Pallasch TJ, Falace DA, Taubert KA (2004) Diagnosis, treatment, and long-term management of Kawasaki disease: a statement for health professionals from the Committee on Rheumatic Fever, Endocarditis, and Kawasaki Disease, Council on Cardiovascular Disease in the Young, American Heart Association. Pediatrics 114:1708–1733

119. Harnden A, Takahashi M, Burgner D (2009) Kawasaki disease. BMJ 338:b1514
120. Shulman ST, De Inocencio J, Hirsch R (1995) Kawasaki disease. Pediatr Clin North Am 42:1205–1222
121. Gardner-Medwin JM, Dolezalova P, Cummins C, Southwood TR (2002) Incidence of Henoch-Schonlein purpura, Kawasaki disease, and rare vasculitides in children of different ethnic origins. Lancet 360:1197–1202
122. Tizard EJ (1999) Recognition and management of Kawasaki disease. Curr Pediatr 8:97–101
123. Yanagawa H, Nakamura Y, Yashiro M, Uehara R, Oki I, Kayaba K (2006) Incidence of Kawasaki disease in Japan: the nationwide surveys of 1999–2002. Pediatr Int 48:356–361
124. Holman RC, Curns AT, Belay ED, Steiner CA, Schonberg LB (2003) Kawasaki syndrome hospitalizations in the United States, 1997 and 2000. Pediatrics 112:495–501
125. Harnden A, Alves B, Sheikh A (2002) Rising incidence of Kawasaki disease in England: analysis of hospital admission data. BMJ 324:1424–1425
126. Japan Kawasaki Disease Research Committee (2002) Diagnostic Guidelines for Kawasaki Disease. 5th Edition, Tokyo
127. Council on Cardiovascular Disease in the Young, Committee on Rheumatic Fever, Endocarditis and Kawasaki Disease; American Heart Association (2001) Diagnostic guidelines for Kawasaki Disease. Circulation 103:335–336
128. Dajani AS, Taubert KA, Gerber MA, Shulman ST, Ferrieri P, Freed M, Takahashi M, Bierman FZ, Karchmer AW, Wilson W (1993) Diagnosis and therapy of Kawasaki disease in children. Circulation 87:1776–1780
129. Kato H, Takahashi K (2008) Kawasaki disease. In: Ball GV, Bridges SL (eds) Vasculitis, 2nd edn. Oxford University Press, Oxford, pp 373–389
130. Suzuki A, Kamiya T, Kuwahara N, Ono Y, Kohata T, Takahashi O, Kimura K, Takamiya M (1986) Coronary arterial lesions of Kawasaki disease: cardiac catheterization findings of 1100 cases. Pediatr Cardiol 7:3–9
131. Zulian F, Falcini F, Zancan L, Martini G, Secchieri S, Luzzatto C, Zacchello F (2003) Acute surgical abdomen as presenting manifestation of Kawasaki disease. J Pediatr 142:731–735
132. Suddleson EA, Reid B, Woolley MM, Takahashi M (1987) Hydrops of the gallbladder associated with Kawasaki syndrome. J Pediatr Surg 22:956–959
133. Freeman AF, Crawford SE, Finn LS, Lopez-Andreu JA, Ferrando-Monleon S, Perez-Tamarit D, Cornwall ML, Shulman ST, Rowley AH (2003) Inflammatory pulmonary nodules in Kawasaki disease. Pediatr Pulmonol 36:102–106
134. Dengler LD, Capparelli EV, Bastian JF, Bradley DJ, Glode MP, Santa S, Newburger JW, Baker AL, Matsubara T, Burns JC (1998) Cerebrospinal fluid profile in patients with acute Kawasaki disease. Pediatr Infect Dis J 17:478–481
135. Knott PD, Orloff LA, Harris JP, Novak RE, Burns JC, Kawasaki Disease Multicenter Hearing Loss Study Group (2001) Sensorineural hearing loss and Kawasaki disease: a prospective study. Am J Otolaryngol 22:343–348
136. Gong GW, McCrindle BW, Ching JC, Yeung RS (2006) Arthritis presenting during the acute phase of Kawasaki disease. J Pediatr 148:800–805
137. Melish ME, Hicks RM, Larson EJ (1976) Mucocutaneous lymph node syndrome in the United States. Am J Dis Child 130:599–607
138. Ferriero DM, Wolfsdorf JI (1981) Hemolytic uremic syndrome associated with Kawasaki disease. Pediatrics 68:405–406
139. Sasaguri Y, Kato H (1982) Regression of aneurysms in Kawasaki disease: a pathological study. J Pediatr 100:225–231
140. Salcedo JR, Greenberg L, Kapur S (1988) Renal histology of mucocutaneous lymph node syndrome (Kawasaki disease). Clin Nephrol 29:47–51
141. Mac Ardle BM, Chambers TL, Weller SD, Tribe CR (1983) Acute renal failure in Kawasaki disease. J R Soc Med. 76:615–616
142. Nardi PM, Haller JO, Friedman AP, Slovis TL, Schaffer RM (1985) Renal manifestations of Kawasaki's disease. Pediatr Radiol 15:116–118
143. Tizard EJ, Suzuki A, Levin M, Dillon MJ (1991) Clinical aspects of 100 patients with Kawasaki disease. Arch Dis Child 66:185–188
144. Veiga PA, Pieroni D, Baier W, Feld LG (1992) Association of Kawasaki disease and interstitial nephritis. Pediatr Nephrol 6:421–423
145. Lande MB, Gleeson JG, Sundel RP (1993) Kawasaki disease and acute renal failure. Pediatr Nephrol 7:593
146. Papadodima SA, Sakelliadis EI, Goutas ND, Vlachodimitropoulos DG, Spiliopoulou CA (2009) Atypical kawasaki disease presenting with symptoms from the genitourinary system: an autopsy report. J Trop Pediatr 55:55–57
147. Sevin C, Heidet L, Gagnadoux MF, Cheron G, Niaudet P (1993) Acute renal insufficiency in Kawasaki disease. Arch Fr Pediatr 50:505–507
148. Tanaka H, Waga S, Tateyama T, Sugimoto K, Kakizaki Y, Yokoyama M (1999) Acute tubulointerstitial nephritis following intravenous immunoglobulin therapy in a male infant with minimal-change nephrotic syndrome. Tohoku J Exp Med 189:155–161
149. Kuniyuki S, Asada M (1997) An ulcerated lesion at the BCG vaccination site during the course of Kawasaki disease. J Am Acad Dermatol 37:303–304
150. Sireci G, Dieli F, Salerno A (2000) T cells recognize an immunodominant epitope of heat shock protein 65 in Kawasaki disease. Mol Med 6:581–590
151. Wood LE, Tulloh RM (2009) Kawasaki disease in children. Heart 95:787–792
152. Zilberman MV, Goya G, Witt SA, Glascock B, Kimball TR (2003) Dobutamine stress echocardiography in the evaluation of young patients with Kawasaki disease. Pediatr Cardiol 24:338–343
153. Sato Y, Kato M, Inoue F, Fukui T, Imazeki T, Mitsui M, Matsumoto N, Takahashi M, Karasawa K, Ayusawa M, Kanamaru H, Harada K, Kanmatsuse K (2003) Detection of coronary artery aneurysms, stenoses and occlusions by multislice spiral computed tomography in adolescents with Kawasaki disease. Circ J 67:427–430
154. Greil GF, Stuber M, Botnar RM, Kissinger KV, Geva T, Newburger JW, Manning WJ, Powell AJ (2002) Coronary magnetic resonance angiography in adolescents and young adults with Kawasaki disease. Circulation 105:908–911
155. Brogan PA (2007) What's new in the aetiopathogenesis of vasculitis? Pediatr Nephrol 22:1083–1094
156. Hsueh KC, Lin YJ, Chang JS, Wan L, Tsai YH, Tsai CH, Tsai FJ (2008) Influence of interleukin 18 promoter polymorphisms in susceptibility to Kawasaki disease in Taiwan. J Rheumatol 35:1408–1413
157. Burgner D, Davila S, Breunis WB, Ng SB, Li Y, Bonnard C, Ling L, Wright VJ, Thalamuthu A, Odam M, Shimizu C, Burns JC, Levin M, Kuijpers TW, Hibberd ML (2009) A genome-wide association study identifies novel and functionally related susceptibility Loci for Kawasaki disease. PLoS Genet 5:e1000319
158. Onouchi Y, Gunji T, Burns JC, Shimizu C, Newburger JW, Yashiro M, Nakamura Y, Yanagawa H, Wakui K, Fukushima Y, Kishi F, Hamamoto K, Terai M, Sato Y, Ouchi K, Saji T, Nariai A, Kaburagi Y, Yoshikawa T, Suzuki K, Tanaka T, Nagai T, Cho H, Fujino A, Sekine A, Nakamichi R, Tsunoda T, Kawasaki T, Nakamura Y, Hata A (2008) ITPKC functional polymorphism associated with Kawasaki disease susceptibility and formation of coronary artery aneurysms. Nat Genet 40:35–42
159. Matsubara K, Fukaya T, Miwa K, Shibayama N, Nigami H, Harigaya H, Nozaki H, Hirata T, Baba K, Suzuki T, Ishiguro A (2006) Development of serum IgM antibodies against super-

antigens of Staphylococcus aureus and Streptococcus pyogenes in Kawasaki disease. Clin Exp Immunol 143:427–434
160. Rowley AH, Shulman ST, Spike BT, Mask CA, Baker SC (2001) Oligoclonal IgA response in the vascular wall in acute Kawasaki disease. J Immunol 166:1334–1343
161. Durongpisitkul K, Gururaj VJ, Park JM, Martin CF (1995) The prevention of coronary artery aneurysms in Kawasaki disease: a meta-analysis on the effects of aspirin and immunoglobulin treatment. Pediatrics 96:1057–1061
162. Newburger JW, Sleeper LA, McCrindle BW, Minich LL, Gersony W, Vetter VL, Atz AM, Li JS, Takahashi M, Baker AL, Colan SD, Mitchell PD, Klein GL, Sundel RP (2007) Randomized trial of pulsed corticosteroid therapy for primary treatment of Kawasaki disease. N Engl J Med 356:663–675
163. Kijima Y, Kamiya T, Suzuki A, Hirose O, Manabe H (1982) A trial procedure to prevent aneurysm formation of the coronary arteries by steroid pulse therapy in Kawasaki disease. Jpn Circ J 46:1239–1242
164. Sundel RP, Baker AL, Fulton DR, Newburger JW (2003) Corticosteroids in the initial treatment of Kawasaki disease: report of a randomized trial. J Pediatr 142:611–616
165. Inoue Y, Okada Y, Shinohara M, Kobayashi T, Kobayashi T, Tomomasa T, Takeuchi K, Morikawa A (2006) A multicenter prospective randomized trial of corticosteroids in primary therapy for Kawasaki disease: clinical course and coronary artery outcome. J Pediatr 149:336–341
166. Shinohara M, Sone K, Tomomasa T, Morikawa A (1999) Corticosteroids in the treatment of the acute phase of Kawasaki disease. J Pediatr 135:465–469
167. Dale RC, Saleem MA, Daw S, Dillon MJ (2000) Treatment of severe complicated Kawasaki disease with oral prednisolone and aspirin. J Pediatr 137:723–726
168. Furukawa T, Kishiro M, Akimoto K, Nagata S, Shimizu T, Yamashiro Y (2008) Effects of steroid pulse therapy on immunoglobulin-resistant Kawasaki disease. Arch Dis Child 93:142–146
169. Okada K, Hara J, Maki K, Matsuzaki K, Matsuoka T, Yamamoto T, Nishigaki T, Kuotobi S, Sano T, Osaka Kawasaki Disease Study Group (2009) Pulse methylprednisolone with gammaglobulin as an initial treatment for acute Kawasaki disease. Eur J Pediatr 168:181–185
170. Brogan RJ, Eleftheriou D, Gnanapragasam J, Klein NJ, Brogan PA (2009) Infliximab for the treatment of intravenous immunoglobulin resistant Kawasaki disease complicated by coronary artery aneurysms: a case report. Pediatr Rheumatol Online J 7:3
171. Burns JC, Best BM, Mejias A, Mahony L, Fixler DE, Jafri HS, Melish ME, Jackson MA, Asmar BI, Lang DJ, Connor JD, Capparelli EV, Keen ML, Mamun K, Keenan GF, Ramilo O (2008) Infliximab treatment of intravenous immunoglobulin-resistant Kawasaki disease. J Pediatr 153:833–838
172. Nakamura Y, Aso E, Yashiro M, Uehara R, Watanabe M, Oki I, Yanagawa H (2008) Mortality among persons with a history of Kawasaki disease in Japan: mortality among males with cardiac sequelae is significantly higher than that of the general population. Circ J 72:134–138
173. Phillip R, Luqmani R (2008) Mortality in systemic vasculitis: a systematic review. Clin Exp Rheumatol 26:S94–S104
174. Kato H, Sugimura T, Akagi T, Sato N, Hashino K, Maeno Y, Kazue T, Eto G, Yamakawa R (1996) Long-term consequences of Kawasaki disease. A 10− to 21-year follow-up study of 594 patients. Circulation 94:1379–1385
175. Tatara K, Kusakawa S (1987) Long-term prognosis of giant coronary aneurysm in Kawasaki disease: an angiographic study. J Pediatr 111:705–710
176. Dhillon R, Clarkson P, Donald AE, Powe AJ, Nash M, Novelli V, Dillon MJ, Deanfield JE (1996) Endothelial dysfunction late after Kawasaki disease. Circulation 94:2103–2106
177. Niboshi A, Hamaoka K, Sakata K, Yamaguchi N (2008) Endothelial dysfunction in adult patients with a history of Kawasaki disease. Eur J Pediatr 167:189–196
178. Mitani Y, Okuda Y, Shimpo H, Uchida F, Hamanaka K, Aoki K, Sakurai M (1997) Impaired endothelial function in epicardial coronary arteries after Kawasaki disease. Circulation 96:454–461
179. Cheung YF, Wong SJ, Ho MH (2007) Relationship between carotid intima-media thickness and arterial stiffness in children after Kawasaki disease. Arch Dis Child 92:43–47

Answers:

1. d
2. b
3. c
4. a
5. c