

Value of ultrasound-guided transforaminal nerve block in the treatment of lumbar disc herniation

Journal of International Medical Research

48(4) 1–10

© The Author(s) 2020


Article reuse guidelines:

sagepub.com/journals-permissions

DOI: 10.1177/0300060520910910

journals.sagepub.com/home/imr



Liu Guang-hui^{1,#}, Zhu Guang-yu^{2,#},
Liu Yu-zhang³ , Zhu Yong-Tao¹,
Zhang Shi-min³ and Jin Jiao³

Abstract

Objective: This study was performed to investigate the effectiveness and safety of ultrasound-guided transforaminal nerve block in the treatment of lumbar disc herniation.

Methods: Sixty patients who underwent treatment for protrusion of a lumbar intervertebral disc in Wangjing Hospital from January 2016 to December 2017 were divided into the study group and the control group. The visual analog scale (VAS) pain scores, the Japanese Orthopaedic Association (JOA) scores of the lumbar vertebra, PRI (pain rating index), and PPI (present pain intensity) were recorded at 30 minutes, 1 week, and 3 months after the operation.

Results: There were significant differences in the VAS, JOA, PRI, and PPI scores between the study group and control group.

Conclusion: Ultrasound guidance can improve the efficacy and safety of transforaminal nerve block in the treatment of lumbar disc herniation and shorten the operative duration.

Keywords

Ultrasound guidance, effectiveness, safety, transforaminal nerve block, lumbar disc herniation, pain scores

Date received: 13 September 2019; accepted: 20 January 2020

¹Department of Ultrasound, Wangjing Hospital, China Academy of Chinese Medical Sciences, Beijing, China

²Minimal Invasive Joint Department, the Third Affiliated Hospital of Beijing University of Chinese Medicine, Beijing, China

³Department of Spine I, Wangjing Hospital, China Academy of Chinese Medical Sciences, Beijing, China

[#]These authors contributed equally to this work.

Corresponding author:

Liu Yu-zhang, Department of Spine I, Wangjing Hospital, China Academy of Chinese Medical Sciences, No. 6 Wangjing Zhonghuan Nan Lu, Chaoyang District, Beijing 100102, China.

Email: liuyuzhang_73@yahoo.com



Introduction

Disc herniation is one of the most common causes of lumbar and leg pain, which can restrict the patient's mobility.^{1,2} In severe cases, people are unable to care for themselves in daily life. The most common types of disc herniation are L3/4 and L4/5 herniations.³

Treatment of disc herniation by transforaminal nerve block therapy leads to quick relief from pain.^{4,5} However, traditional nerve block therapy is based on the surface anatomy, and the drug is injected blindly. The success of this procedure mainly depends on the operator's experience. The nerve block effect is poor in some cases,³ and accidental injury to other nerves or vessels may occur.⁶

Ultrasound guidance allows for clear visualization of the anatomical structures of the muscles, intervertebral foramen, nerve roots, and blood vessels in the area of puncture and can accurately guide the puncture needle to an expected position in real time.^{7,8} However, its effectiveness and safety need further investigation. Therefore, the present study was performed to assess the effectiveness and safety of ultrasound-guided transforaminal nerve block in the treatment of lumbar disc herniation.

Materials and methods

General information

Ethical approval of this study was obtained from the China Academy of Chinese Medical Sciences, Beijing, China, and the study was executed in accordance with the guidelines for human use in experimental studies as outlined in the Declaration of Helsinki.³ Patients with lumbar disc herniation admitted to the Department of Spine 1 from January 2016 to December 2017 were randomly divided into two equal groups according to a random number

table. The patients in the study group received ultrasound-guided nerve block therapy, and the patients in the control group received blindly administered nerve block therapy. The main disease symptom was low back pain, particularly pain that radiated to the lower extremity. Ultrasound examinations were conducted using an ARIETTA 70 ultrasound scanner (probe, L441; frequency, 2.0–12.0 MHz; Hitachi-Aloka, Tokyo, Japan). Ultrasound guidance was performed by two senior physicians in Wangjing Hospital. The injection procedure was performed by a spine surgeon. All patients provided written informed consent before surgery.

Inclusion and exclusion criteria

The inclusion criteria were the presence of symptoms and signs consistent with the diagnostic criteria for lumbar disc herniation, agreement to undergo examination and treatment, absence of any other serious disease, no history of having taken hormonal drugs within 3 months before treatment or during treatment, age of 20 to 65 years, and confirmation of a single-segment lesion by computed tomography or magnetic resonance imaging with clinical symptoms related to a unilateral lower extremity, except L5/S1 disc herniation (such herniation is not suitable for treatment under B-mode ultrasound guidance because this imaging technique cannot show the L5/S1 foramina). No restrictions were placed on sex.

The exclusion criteria were numbness of the lower extremities caused by cerebrovascular disease or lower extremity vascular disease; medical diseases such as severe heart, brain, lung, or kidney diseases; mental diseases; pregnancy; skin ulceration, scar physique, or previous lumbar surgery; poor compliance or incomplete data that would affect the efficiency of the study;

use of hormonal drugs; and symptoms of muscle weakness in the lower limbs.

Drug preparation method

The drug used for injection was prepared by adding 1 mL of compound betamethasone injection in a preloaded syringe (Debaosong; Hangzhou Moshadong Pharmaceutical Co., Ltd., Hangzhou, Zhejiang, China) to 5 mL of 2% lidocaine, followed by the addition of 10 mL of water for injection.

Observation indicators and evaluation criteria

Each patient's visual analog scale (VAS) pain score was obtained before treatment, 30 minutes after treatment, 1 week after treatment, and 3 months after treatment. A score of 0 points indicated that the patient had no pain symptoms, and a score of 10 points indicated that the patient had severe, intolerable pain.⁹

Each patient's functional evaluation was performed by obtaining the lumbar spine Japanese Orthopaedic Association (JOA) score. The maximum lumbar spine JOA score was 29 points, and the remission rate was determined with the following formula:

$$\text{Remission rate} = \left[\frac{(\text{post-treatment score} - \text{pretreatment score})}{(29 - \text{pretreatment score})} \right] \times 100\%$$

A remission rate of >74% was excellent, that of 50% to 74% (inclusive) was good, that of 25% to 49% (inclusive) was moderate, and that of <25% was poor.

The pain rating index (PRI) contains 12 sensory words and 4 emotional words. Each word is divided into none (0 points), light (1 point), medium (2 points), and heavy

(4 points). The total PRI pain score is calculated by determining the sensory index, the emotional index, and a combination of the two.

The present pain intensity (PPI) is an index comprising a feeling of no pain, mild pain, uncomfortable pain, miserable pain, severe pain, and fierce pain with scores of 0, 1, 2, 3, 4, and 5 points, respectively.

Complications recorded during each patient's treatment period and within 3 months of follow-up (including 3 months) included dizziness, spinal anesthesia, urinary retention, intravascular injection, and transient increasing pain in the waist and leg after injection.

The operation time (duration from start of disinfection to end of injection) was also recorded.

Nerve block and determination of VAS and JOA scores in the study group

The patient lay prostrate on the treatment bed in the ultrasound intervention room, fully exposing the lumbar vertebrae of the back, and a pillow was used to support the abdomen and ensure that the lumbar vertebrae were straight. The surgeon wore a hat, mask, and sterile gloves. Conventional iodophor was used to disinfect an adequate-

ly large area of skin on the back (including room for use of the probe), and the sterilized treatment area was isolated from the surrounding unsterilized area with a sterile towel. If the lesion segment was located at L4/5, the L441 high-frequency ultrasound probe was used, and the lumbar vertebrae were parallelly and longitudinally cut to

determine the position of the fifth lumbar spinous process (Figure 1(a)). The probe was translated to the direction of the diseased side and positioned over the fifth lumbar vertebra. Finally, the articular process between the spinous process and the transverse process was found. The longitudinal probe was slightly inclined from outside to upper inside. The L4/5 transforaminal nerve root exited below the base of the transverse lumbar process of the fourth lumbar vertebra. The sieve-like hyperechoic exit branch of the L4 nerve root structure was seen (Figure 1(b)), and the inferior epidural space could then be identified inward and downward. The out-of-plane injection point was located downward at the upper

edge of the superior articular process and transverse process of the L5 centrum. The precise location of the guide was the bone surface close to the superior articular process. The position of the probe was fixed at the angle and punctured with a 10-cm-long needle, and the needle was then inserted in the direction of the short axis of the probe. When the needle reached the level of the articular process as shown by ultrasound real-time monitoring, the needle was further inserted 1 to 2 cm. Under the direct view of the ultrasound, we observed that at the transforaminal L5 base of the superior articular process and close to the upper abaxial surface of the strong echo point image (Figure 1(c)), no blood or

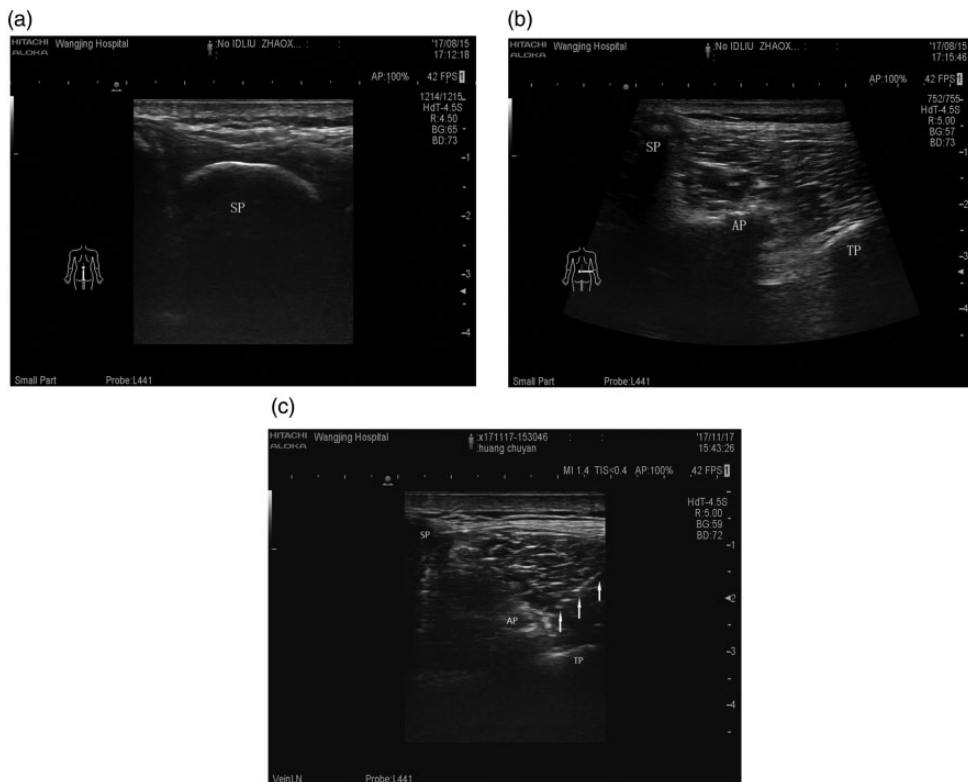


Figure 1. Ultrasound intervention during determination of the visual analog scale score and Japanese Orthopaedic Association score in the study group. (a) Longitudinal orientation of the ultrasound probe. (b) Oblique orientation of the ultrasound probe. (c) Oblique orientation of the ultrasound probe. The arrows indicate the puncture needle. SP, fifth lumbar spinous process; AP, articular process; TP, transverse process.

cerebrospinal fluid was present when the needle was dropped back. The previously prepared liquid was slowly injected so that the drug infiltrated the tissue in the vicinity of the epidural space and the L5 nerve root transforaminally. During drug injection, the patient's limb sensation and feelings of relaxation, fever, or numbness were monitored to control the infusion speed. After injection, the needle hole was pressed with a sterile cotton ball for 5 minutes, and a hemostatic stick was used to treat the pin-hole. Finally, the patient lay on his or her side for 20 minutes with the affected side upward to allow the liquid to fully infiltrate the intervertebral disc, running through the nerve root and epidural space.

The operation time was recorded. The VAS, lumbar spine JOA, PRI, and PPI scores were determined at 30 minutes, 1 week, and 3 months after treatment. All complications from the start of treatment to 3 months of follow-up were recorded. The same method was used for L3/4 disc herniation by moving up by one vertebral body.

Nerve block and determination of VAS and JOA scores in the control group

The patient lay in the same position and the skin disinfection process was performed in the same manner as in the study group. The spine surgeon determined the location of the outward spinous process of the fifth vertebral body corresponding to the diseased disc by palpating the surface anatomy. The needle entry point was positioned 3 cm from the outward spinous process, and the needle was inserted vertically. The articular process was contacted when the needle tip reached a bony structure. The needle was then lifted slightly and tilted 30 degrees to the outside; insertion was then continued for about 2 cm. Insertion of the needle was stopped when it was felt to slide from the outward aspect of the articular process.

No blood or cerebrospinal fluid was seen when the needle was dropped back. The remainder of the procedure was identical to that in the study group.

Statistical analysis

The data of this study were statistically analyzed using SPSS version 22.0 software (IBM Corp., Armonk, NY, USA) and are expressed as mean \pm standard deviation. The between- and within-group statistical differences were compared by the t-test. The count data, such as the rates of excellent outcomes, are expressed as percentages, and the chi-square test was used to examine their differences. A P value of <0.05 was regarded as statistically significant.

Results

Patients

In total, 60 patients were included in this study. The study group comprised 16 men and 14 women with a mean age of 49.11 ± 1.41 years and mean disease duration of 9.3 ± 1.5 months. L4/5 disc-related disease was seen in 21 patients, while 9 patients had L3/4 disc disease. The control group comprised 17 men and 13 women with a mean age of 48.19 ± 1.01 years and mean disease duration of 11.2 ± 1.7 months. L4/5 disc-related disease was seen in 23 patients, while 7 patients had L3/4 disc disease. None of these factors were significantly different between the two groups.

Comparison of VAS scores between the groups

The preoperative VAS scores were not significantly different between the two groups. However, there were significant differences between the two groups at the same time points after the operation. Specifically, the VAS scores were significantly lower in the

Table 1. Comparison of VAS scores between the two groups before and after the operation.

Groups	30 minutes before the operation	30 minutes after the operation	One week after the operation	Three months after the operation
Study group	7.1 ± 1.2	2.6 ± 1.3 ^{a,b}	2.8 ± 1.2 ^{a,b}	2.9 ± 1.2 ^{a,b}
Control group	6.9 ± 1.3	3.4 ± 1.2	3.6 ± 1.1	3.5 ± 1.3

VAS, visual analog scale.

^aP < 0.05 compared with the same group before the operation.

^bP < 0.05 compared with the control group after the operation.

study group than in the control group at 30 minutes, 1 week, and 3 months after the operation ($P < 0.05$) (Table 1).

Comparison of rate of excellent JOA scores between the groups

In the study group, the rate of an excellent JOA score was 90.0% at 30 minutes post-operatively, 93.3% at 1 week postoperatively, and 90.0% at 3 months postoperatively. However, the rate of an excellent JOA score in the control group was 76.7% at all three time points ($P < 0.05$ for all).

Comparison of PRI scores between the groups

The PRI sensory index, PRI emotional index, and PRI total score were not significantly different between the two groups. In both groups, the PRI sensory index, PRI emotional index, and PRI total score were lower after treatment than before treatment, and the differences were statistically significant ($P < 0.05$). The PRI sensory index and PRI total score were lower in the study group than in the control group ($P < 0.05$), but there was no significant difference in the PRI emotional index between the two groups (Table 2).

Comparison of PPI scores between the groups

The preoperative PPI scores were not significantly different between the two groups.

The pain was reduced after the operation as indicated by the PPI score, and this effect was significantly better in the study group than in the control group ($P < 0.05$) (Table 3).

Comparison of complications between the groups

In the study group, there were no complications at any of the three points after treatment. In the control group, four patients developed complications at 30 minutes after treatment, four developed complications at 1 week after treatment, and five developed complications at 3 months after treatment: spinal anesthesia ($n = 2$) and upper innervation numbness associated with the injection ($n = 2$) and new pain exacerbation 3 months after treatment ($n = 1$) (Table 4).

Comparison of treatment time between the groups

In the study group, the mean operation time was 6.4 ± 2.9 minutes (range, 5.6–8.9 minutes). In the control group, the mean operation time was 8.6 ± 3.9 minutes (range, 7.6–12.9 minutes). The difference between the two groups was statistically significant ($P < 0.05$).

Discussion

Protrusion of an intervertebral disc produces mechanical, chemical, and autoimmune

Table 2. Comparison of PRI scores between the two groups before and after the operation.

Group	PRI		
	Sensory index	Emotional index	Total scores
Study group			
Before operation	7.11 ± 1.00	3.23 ± 0.89	10.35 ± 1.32
30 minutes after operation	3.65 ± 1.22 ^{a,b}	1.84 ± 0.71 ^a	5.62 ± 1.38 ^{a,b}
One week after operation	3.78 ± 1.23 ^{a,b}	1.84 ± 0.75 ^a	5.77 ± 1.37 ^{a,b}
Three months after operation	3.80 ± 1.03 ^{a,b}	1.90 ± 0.69 ^a	5.80 ± 1.29 ^{a,b}
Control group			
Before operation	7.46 ± 1.26	3.61 ± 1.13	11.03 ± 1.47
30 minutes after operation	4.97 ± 0.87 ^a	2.02 ± 0.92	6.95 ± 1.25 ^a
One week after operation	4.99 ± 0.90 ^a	2.09 ± 0.83	6.98 ± 1.30 ^a
Three months after operation	5.00 ± 0.77 ^a	2.08 ± 0.90	7.01 ± 1.28 ^a

Scores are presented as mean ± standard deviation.

PRI, pain rating index.

^aP < 0.05 compared with the same group before the operation.

^bP < 0.05 compared with the control group after the operation.

Table 3. Comparison of PPI scores between the two groups of patients before and after the operation.

Group	Before the operation	30 minutes after the operation	One week after the operation	Three months after the operation
Study group	3.51 ± 0.58	0.82 ± 0.45 ^{a,b}	0.83 ± 0.44 ^{a,b}	0.86 ± 0.49 ^{a,b}
Control group	3.98 ± 0.98	1.20 ± 0.45 ^a	1.21 ± 0.46 ^a	1.31 ± 0.48 ^a

Scores are presented as mean ± standard deviation.

PPI, present pain intensity.

^aP < 0.05 compared with the same group before the operation.

^bP < 0.05 compared with the control group after the operation.

Table 4. Comparison of postoperative complication rates between the two groups.

Groups	30 minutes after the operation	One week after the operation	Three months after the operation
Study group	0.0% (0/30)	0.0% (0/30)	0.0% (0/30)
Control group	13.3% (4/30)	13.3% (4/30)	16.7% (5/30)

stimulation of nerve roots, causing aseptic inflammation.¹⁰ Lumbar disc herniation is a common disease characterized by low back pain with or without numbness and pain in one lower extremity. Traditional transforaminal injection is rapidly effective and has become one of the most common treatment

measures for lumbar and leg pain caused by lumbar disc herniation.^{11,12} However, the traditional injection method is blind and dependent on the operator's experience. The effect of this therapy is inevitably affected by anatomical variations, obesity, and other factors, resulting in low accuracy

of nerve positioning and thus a poor nerve block effect; the failure rate is as high as 15.0% to 17.0%.¹¹ High-frequency ultrasound can accurately distinguish the transforaminal, nerves, ligaments, blood vessels, puncture needles, and even the diffusion of drug solution. Ultrasound guidance facilitates visualization of the whole operation, greatly improving accuracy and safety; this in turn improves the efficacy of the procedure and reduces the incidence of complications. The use of ultrasound-guided cervical nerve root injection for cervical spondylosis and the use of fistula injection for lumbar disc herniation reportedly have very high effectiveness.¹¹⁻¹⁶

In total, 60 patients were enrolled in the present study. The evaluation indicators included the operation time, VAS scores, rate of excellent JOA scores, and incidence of complications. The operation time was significantly shorter in the study group than in the control group ($P < 0.05$). The current quality of ultrasound examination, especially high-frequency ultrasound with high resolution, enables clear identification of the anatomical structures in the puncture path, including muscles, ligaments, blood vessels, nerves, and various bone surfaces. This not only allows for accurate positioning but also provides direct visualization, facilitating an easier operation. When the precise puncture position is ensured, the operation can be performed much more rapidly. This highlights the superiority of the ultrasound-guided nerve block with direct visualization.¹⁷⁻²¹

The postoperative VAS scores of the two groups were significantly lower at all three time points after the operation, which further verifies the reliability of transforaminal nerve block in the treatment of lumbar disc herniation. By using ultrasound guidance, the superior and inferior articular processes, the branch nerve roots, the puncture needle, and the diffusion of the drug solution can be clearly observed. This allows

more accurate positioning for injection of the drug solution and thus a more remarkable curative effect. At each time point, the VAS scores were lower in the study group than in the control group. This difference is related to the more accurate placement of the ultrasound-guided needle at the expected position, closer to the descending branch of the diseased nerve root. Such placement is more conducive to the diffusion of lidocaine into the surrounding nerve roots, blocking the pain nerve conduction and expanding the local blood vessels to relieve muscle tension.²² At the same time, the difference in the VAS scores may also be related to the precise and rapid diffusion of steroid hormones around the diseased nerve roots, eliminating or alleviating aseptic inflammatory stimuli such as congestion and edema around the nerve roots caused by mechanical compression of tissue by the disc herniation.

Traditional transforaminal lumbar nerve block has a quick and exact effect, and it is therefore one of the most common measures for the treatment of lumbar and leg pain caused by a lumbar disc herniation.²³ In the present study, the VAS scores were significantly lower in the study group than in the control group ($P < 0.05$), indicating that the ultrasound-guided operation provided good visualization, was more accurate, and had a better curative effect; overall, the patients benefited more.

Another evaluation index in this study was the rate of an excellent JOA score of the lumbar spine. The rate of an excellent score in the study group was 90.0% at both 30 minutes and 3 months after the operation. One patient had a <50% remission rate of an excellent JOA score of the lumbar spine at 30 minutes postoperatively. The remission rate reached a good level at 1 week postoperatively, which may have been related to the severe disc herniation of the diseased segment and edema of the descending branch of the nerve root; this prevented

the drug solution from penetrating the nerve root around the lesion in an adequately short amount of time. However, the remission rate was <50% at 3 months of follow-up. This might have been associated with the persistent compression of the nerve roots by edema and the severe local aseptic inflammation. In the control group, the rate of excellent JOA scores was 76.7% (23/30) at all three time points postoperatively. There were differences in these rates between the two groups, indicating that ultrasound guidance can facilitate accurate localization of the target site for drug injection. This can significantly improve the accuracy and efficacy of the operation. Our findings are consistent with the conclusions of previous reports.^{12–16}

The results of this study also showed that the PRI and PPI scores, two quantitative pain indexes, were significantly lower in both groups after treatment ($P < 0.05$), and the effect was better in the study group than in the control group.

No postoperative complications occurred in the study group; however, the complication rate in the control group was 13.3% at 30 minutes and 1 week postoperatively and increased to 16.7% at 3 months postoperatively. Two patients in the control group developed spinal anesthesia complications, which were considered to have been caused by blind injection of the drug into the intradural space. Although the symptoms disappeared in a short time, affected patients may become confused or even panicked. In two other patients, the symptoms caused by the affected nerve roots were not alleviated, and skin numbness appeared in the upper nerve root dominating area after the operation. This may have been caused by the syringe becoming stuck to the outlet branch nerve root. Such adverse reactions can be avoided in ultrasound-guided operations. During the 3-month follow-up, patients in the control group developed recurrence of the aggravated pain caused

by their disc herniation. This might have been related to the fact that the injected drug was located far from the diseased nerve root, and only a small amount of the drug solution therefore diffused to the diseased nerve root. These findings verify that ultrasound guidance can improve the safety and effectiveness of nerve blocks.

Conclusion

Ultrasound-guided visualization can improve the efficacy and safety of nerve block in the treatment of lumbar disc herniation, shorten the operation time, and reduce the occurrence of complications. Therefore, this procedure is worthy of widespread promotion.

Declaration of conflicting interest

The authors declare that there is no conflict of interest.

Funding

This research received no specific grant from any funding agency in the public, commercial, or not-for-profit sectors.

ORCID iD

Liu Yu-zhang  <https://orcid.org/0000-0003-2913-7150>

References

1. Zhang MB, Yan LT, Li SP, et al. Ultrasound guidance for transforaminal percutaneous endoscopic lumbar discectomy may prevent radiation exposure: a case report. *World J Clin Cases* 2019; 7: 1161–1168.
2. Beynon R, Elwenspoek MMC, Sheppard A, et al. The utility of diagnostic selective nerve root blocks in the management of patients with lumbar radiculopathy: a systematic review. *BMJ Open* 2019; 9: e025790. doi: 10.1136/bmjopen-2018-025790
3. Filippiadis DK and Kelekis A. A review of percutaneous techniques for low back pain and neuralgia: current trends in epidural

- infiltrations, intervertebral disk and facet joint therapies. *Br J Radiol* 2016; 89: 20150357.
4. Lee JW, Lee E, Lee GY, et al. Epidural steroid injection-related events requiring hospitalisation or emergency room visits among 52,935 procedures performed at a single centre. *Eur Radiol* 2018; 28: 418.
 5. Zhang X, Shi H, Zhou J, et al. The effectiveness of ultrasound-guided cervical transforaminal epidural steroid injections in cervical radiculopathy: a prospective pilot study. *J Pain Res* 2019; 12: 171–177.
 6. Zhou P, Chen NZ and Rao XH. Effect observation of Nerve Block guided by neurostimulator to the treatment of protrusion of lumbar intervertebral disc. *Guangdong Med* 2014; 35: 2075–2077.
 7. Liu J, Zhou H, Lu L, et al. The effectiveness of transforaminal versus caudal routes for epidural steroid injections in managing lumbosacral radicular pain. A systematic review and meta-analysis. *Medicine* 2016; 95: e3373. doi: 10.1097/MD.0000000000003373
 8. Kanna RM, Shetty AP and Rajasekaran S. Predictors of successful outcomes of selective nerve root blocks for acute lumbar disc herniation. *Global Spine J* 2018; 9: 473–479.
 9. Irshad M, Ahmad K and Malla HA. Lumbar disc herniation causing cauda equina syndrome in a paediatric patient: a case report. *Ortop Traumatol Rehabil* 2016; 18: 389–492.
 10. Wang JN, Fu ZJ and Zhao XL. Curative effect retrospective analysis of epidural injection of glucocorticoid to the treatment of protrusion of lumbar intervertebral disc. *Chin J Pain Med* 2012; 18: 78–80.
 11. Mo ZL, Lu MX and Li XL. Observation of curative effect of Lumbosacral block combined with waist percussion to the treatment of protrusion of lumbar intervertebral disc. *You-Jiang Med* 2015; 43: 112–113.
 12. Xu LF, Zuo J and He CJ. Clinical observation of sacral canal injection combined with nerve block to the treatment of protrusion of lumbar intervertebral disc. *J Neck and Back Pain* 2016; 37: 553–554.
 13. He CH, Xie SC and Wang JG. Effect of ultrasound guided sacral block in the treatment of lumbago and leg pain caused by protrusion of lumbar intervertebral disc. *Guangdong Med* 2015; 36: 1240–1243.
 14. Zhou SH, Yang J, Meng QG, et al. The relationship between sacral canal injection curative effect and lumbar disc herniation, different segments, types and course of disease. *China J Orthop Traumatol* 2013; 26: 580–583.
 15. Korbe S, Udoji EN, Ness TJ, et al. Ultrasound-guided interventional procedures for chronic pain management. *Pain Manag* 2015; 5: 465–482.
 16. Yang GH, Lin JL and Lin AT. The Influence of ultrasound guided sacral block to the inflammatory reaction of formation of hypospadias. *Zhejiang Clin Med J* 2016; 18: 228–230.
 17. Hashemi M, Dadkhah P, Taheri M, et al. Ultrasound-guided lumbar transforaminal epidural injections; a single center fluoroscopic validation study. *Bull Emerg Trauma* 2019; 7: 251–255.
 18. Hazra AK, Bhattacharya D, Mukherjee S, et al. Ultrasound versus fluoroscopy-guided caudal epidural steroid injection for the treatment of chronic low back pain with radiculopathy: a randomised, controlled clinical trial. *Indian J Anaesth* 2016; 60: 388–392.
 19. Kim SC, Hauser S, Staniek A, et al. Learning curve of medical students in ultrasound-guided simulated nerve block. *J Anesth* 2014; 28: 76–80.
 20. Kang S, Yang SN, Kim SH, et al. Ultrasound-guided cervical nerve root block: does volume affect the spreading pattern? *Pain Med* 2016; 17: 1978–1984.
 21. Wan Q, Wu S, Li X, et al. Ultrasonography-guided lumbar periradicular injections for unilateral radicular pain. *Biomed Res Int* 2017; 2017: Article No. 8784149.
 22. Wang D. Image guidance technologies for interventional pain procedures: ultrasound, fluoroscopy, and CT. *Curr Pain Headache Rep* 2018; 22: 6–12.
 23. Zhu W, Shen W and Yuan Y. The curative effect by using ultrasound guided and combined nerve stimulator to locate nerve block beside vertebrae cervicales in the treatment cervical spondylosis of nerve root type. *J Pract Pain Sci* 2016; 12: 259–262.