

Endovascular Treatment of the Huge Dissecting Aneurysms Involving the Basilar Artery by the Internal Trapping Technique: Technical Note

Shi-Qing Mu, Xin-Jian Yang, You-Xiang Li, Chu-Han Jiang, Zhong-Xue Wu

Department of Interventional Neuroradiology, Beijing Neurosurgical Institute and Beijing Tiantan Hospital, Capital Medical University, Beijing 100050, China

Abstract

Background: The endovascular strategy of the huge dissecting aneurysms involving the basilar artery (BA) is controversial and challenging. This study was to investigate the clinical and angiographic outcomes of the treatment of the huge dissecting aneurysms involving the BA by the internal trapping (IT) technique.

Methods: We retrospectively studied 15 patients with the huge dissecting aneurysms involving the BA treated by the IT technique between September 2005 and September 2014 in Department of Interventional Neuroradiology of Beijing Tiantan Hospital. Clinical and angiographic data were reviewed and evaluated.

Results: All patients were treated by the IT technique. That meant the dissecting artery and aneurysm segments were completed occlusion. After the procedure, the angiography demonstrated that all the dissecting artery and aneurysm segments were completed occlusion. Follow-up angiography was performed at 3–6 months or 12–18 months after the endovascular treatment (median 8 months), 14 patients had a good recovery. Re-canalization occurred in one patient whose aneurysm involved in bilateral vertebral arteries and the two third of the middle-lower BA. After the second treatment, the patient died by the ventricular tachycardia.

Conclusions: The IT technique is a technically feasible and safe alternative for the treatment of BA dissecting aneurysms, but it is not necessarily the safest or most definitive treatment modality. The ideal treatment of the huge dissecting aneurysms involving the BA remains debatable and must be investigated on a case-by-case basis.

Key words: Basilar Artery; Endovascular Treatment; Huge Dissecting Aneurysms; Internal Trapping Technique

INTRODUCTION

Dissecting aneurysms involving the basilar artery (BA) have a worse prognosis than a dissection limited to the vertebral artery (VA), but little is known about the clinical course and prognosis. The clinical manifestations of dissecting aneurysms involving the BA are more varied than those for VA dissecting aneurysms, including subarachnoid hemorrhage (SAH), ischemia, and brain stem compression. The patients presenting with BA dissecting aneurysms have a high rate of morbidity and mortality, indicating the need for early treatment.^[1-3]

Endovascular treatment of intracranial aneurysms has undergone remarkable advancement with the development of various detachable coils and the technique, but the endovascular strategies for BA dissecting aneurysms are

controversial and challenging because the structure is complex and its natural history, treatment, and outcome of the treatment are not as defined as for intracranial ordinary aneurysms. Stent-assisted detachable coil embolization has offered new reliable options to some patients with dissecting aneurysms. Some cases have reported that the use of stent-within-stent technique or stent alone can promote the thrombosis in predominantly dissecting aneurysms. However, all patients suffered complications, such as recurrences or re-canalization, re-bleeding, neurologic deficit, and its maintenance of anti-platelet medication.^[4-6] The use of flow-diverting devices has gained momentum as a curative approach in the treatment of complex proximal anterior circulation intracranial aneurysms. Posterior circulation huge dissecting aneurysms have a particularly aggressive natural history. To date, no one approach has been shown to be comprehensively effective or low risk.^[7-10] In 2007, we had reported two cases with huge dissecting aneurysms involving the BA treated by the internal trapping (IT)

Access this article online

Quick Response Code:



Website:
www.cmj.org

DOI:
10.4103/0366-6999.160539

Address for correspondence:

Dr. Xin-Jian Yang,
Department of Interventional Neuroradiology, Beijing Neurosurgical
Institute and Beijing Tiantan Hospital, Capital Medical University,
No. 6, Tiantan Xili, Dongcheng District, Beijing 100050, China
E-Mail: msq1216@sina.com

technique.^[11] So far, it has rarely been reported. In this report, we retrospectively studied 15 patients treated by the IT technique and evaluated our experience using endovascular approaches for huge dissecting aneurysms involving the BA.

METHODS

Clinic material

We retrospectively analyzed 15 patients with the huge dissecting aneurysms involving the BA, who were treated by IT technique between September 2005 and September 2014. The series consisted of 10 males and 5 females, ranging in age from 13 to 64 years (mean 46.7 years). Each patient underwent preoperative planar images examination, including computed tomography (CT) scanning or magnetic resonance (MR) imaging, and sometimes CT/MR angiography. Before treatment procedure, all patients underwent digital subtraction angiography (DSA) to confirm the diagnosis and to assist treatment decision-making.

All patients met the following inclusion criteria: (1) Clinical symptoms and/or signs relevant to the huge dissecting aneurysms involving the BA, mainly including

ischemic stroke, SAH or other presentations caused by the mass effect of the lesions, such as dysarthria, dysphagia, ataxia, tetraparesis, forced laughing and crying or numbness of the limbs; (2) radiologic (CT/MR) and/or angiographic evidence (CT/MR angiography or conventional angiography) to diagnose the huge dissecting aneurysms, including intimal flap, intramural hematoma, double-lumen, pearl-and-string sign, and retention of contrast medium in the involved segment of the parent vessel; (3) the maximum diameter of the aneurysm was larger than 25 mm, or the diseased segment of parent artery was estimated to be longer than 25 mm. Exclusion criteria included: (1) definitively traumatic or iatrogenic dissecting aneurysms, or lesions clearly related to vasculitis or fibromuscular dysplasia (because these lesions were thought to be another pathologic process and were not the focus of the present study); (2) incidentally found asymptomatic huge dissecting aneurysms or the huge dissecting aneurysms were not involving the BA; (3) the lesions were not “huge” according to the criteria mentioned above; (4) the lesions were treated with reconstructive technique. Clinical presentation and preoperative DSA are shown in Table 1.

Table 1: Clinical and imaging characteristics of 15 patients with huge dissecting aneurysms involving the BA

Case number	Sex	Age (years)	Clinical presentation	SAH	CT and/or MR	Preoperative DSA
1	Male	59	Ataxia, dysarthria, dysphagia, numbness of left limbs	No	Yes	Dissecting aneurysm of middle-lower BA, bilateral AICA and VA involved; right PCoA was prominent
2	Female	31	Transient unconscious, dysarthria, tetraparesis, forced laughing and crying, bilateral weakness of limbs	Yes	Yes	Dissecting aneurysm of middle-upper BA and distal to bilateral AICA; bilateral PCoA were prominent
3	Female	39	Ataxia, bucking in the drinking water	No	Yes	Dissecting aneurysm of middle-lower BA, bilateral AICA involved; bilateral PCoA were prominent
4	Male	13	Ataxia, dysarthria, dysphagia	No	Yes	Dissecting aneurysm of middle-lower BA, bilateral AICA involved; bilateral PCoA were not prominent
5	Female	19	Headache, left limbs weakness	No	Yes	Dissecting aneurysm of lower BA, the distal of bilateral VA involved; bilateral PCoA were prominent
6	Male	47	Transient unconscious, headache, nausea, vomiting, alalia	Yes	Yes	Dissecting aneurysm of the middle BA; left PCoA was prominent
7	Male	58	Headache, intermittent vertigo, numbness of left limbs	No	Yes	Dissecting aneurysm of middle-lower BA, bilateral AICA and right VA involved; bilateral PCoA were prominent
8	Female	50	Sudden headache, transient unconscious, nausea, vomiting	Yes	Yes	Dissecting aneurysm of upper BA; bilateral PCoA were prominent
9	Male	63	Headache, intermittent vertigo	No	Yes	Dissecting aneurysm of middle BA; bilateral PCoA were prominent
10	Male	63	Headache, nausea, transient unconscious, dysphagia	Yes	Yes	Dissecting aneurysm of middle-lower BA, bilateral AICA and VA involved; right PCoA was prominent
11	Male	59	Right hemi-facial spasm	No	Yes	Dissecting aneurysm of lower BA, right VA involved; bilateral PCoA were prominent
12	Male	62	Intermittent headache, bucking in the drinking water	No	Yes	Dissecting aneurysm of the middle BA; Bilateral PCoA were prominent
13	Female	56	Intermittent vertigo	No	Yes	Dissecting aneurysm of middle-lower BA, bilateral AICA and left VA involved; bilateral PCoA were prominent
14	Male	64	Bucking in the drinking water, tetraparesis	No	Yes	Dissecting aneurysm of middle BA; bilateral PCoA were prominent
15	Male	18	Headache, nausea, vomiting, intermittent vertigo	Yes	Yes	Dissecting aneurysm of middle-lower BA, bilateral AICA involved; bilateral PCoA were prominent

CT: Computed tomography; MR: Magnetic resonance; SAH: Subarachnoid hemorrhage; DSA: Digital subtraction angiography; BA: Basilar artery; AICA: Anterior inferior cerebellar artery; VA: Vertebral artery; PCoA: Posterior communicating artery; PICA: Posterior inferior cerebellar artery.

Treatment protocol and endovascular techniques

All patients underwent four-vessel angiography in advance of endovascular treatment. The size of the posterior communicating artery (PCoA) was pay close attention. One patient with PCoAs less than 1 mm was evaluated by test occlusion for 20–30 min by using two nondetachable silicone balloons in the bilateral VA. At the time of test occlusion, the neurologic evaluation was conducted by a neurologist. All involved aneurysms judged by a multidisciplinary team were not satisfactorily treatable by standard endovascular or stent-assisted technique. The protocol was approved by the Ethics Committee of Beijing Tiantan Hospital, and written informed consent was obtained from all patients or their guardians.

All patients were treated under the induction of general anesthesia and full systemic heparinization in the procedure. One 6F femoral sheath was introduced into half lateral femoral artery. Cerebral angiography was performed to evaluate three-dimensional (3D) morphologic features of the aneurysm and parent vessel, and the size of the PCoA. Then a micro-catheter was navigated into the proximal part of the dissecting aneurysm. Large 3D-coil was adjusted carefully to make a basket inside the aneurysm and the parent vessel. Then, more coils were detached in the dissecting aneurysm. Finally, the last coils were deployed extending from an aneurysm to the adjacent normal BA or VA segments and occluded the normal BA or VA segments. At the end of the procedure, the catheter systems were completely withdrawn, and the femoral sheath was removed. Hemostasis at the femoral puncture sites was achieved using either manual pressure or a percutaneous arterial closure device. The patients were monitored in the Intensive Care Unit before recovering from general anesthesia. Follow-up angiography was performed at 3–6 months or 12–18 months after the endovascular treatment.

All patients received an intravenous heparin load of 3000–5000 IU immediately after guiding catheter placement and then 1000 IU every hour during the procedure. Following the treatment, the patients were maintained heparinization for 24 h and kept the activated partial thromboplastin time in 1.5–2 times normal, and then were changed by subcutaneous injection of low molecular heparin for 3–10 days.

RESULTS

All patients were treated by the IT technique. That meant the dissecting artery and aneurysm segments were completed occlusion. After the procedure, the complete angiography demonstrated that all the dissecting artery and aneurysm segments were completed occlusion. After the patients had recovered from general anesthesia, two patients felt the clinical symptom disappeared, nine patients felt the clinical symptom partly disappeared, and four patients felt no any change. Follow-up angiography and clinical outcome for all patients at 3–6 months, or 12–18 months (median, 8 months) were available; there were 14 patients who had a good

recovery. The bilateral carotid artery angiography revealed that the upper part of the BA could be stained by bilateral PCoA and confirmed the complete occlusion of the total dissection [Figure 1]. We found the compensated dilatation of the size of PCoA in one patient who's PCoA was less than 1 mm in initial treatment. Re-canalization occurred in one patient whose aneurysm involved in bilateral vertebral arteries and the two third of the middle-lower BA. At an early stage of the study, we had reported this case.^[11] In the initial operation, due to the distance of the posterior inferior cerebellar artery (PICA), a small amount of dissection just distal to the PICA was left. The patient fell into coma one morning 6 weeks after the initial treatment. Emergent angiography showed that dissection re-canalized at the posterior part originating from a residual dissection on the left VA. After the second treatment, the patient died by the ventricular tachycardia.

DISCUSSION

Dissecting aneurysms involving the BA generally originates from dissection of the VA with upward extension. Huge dissecting aneurysms involving the BA are extremely rare. The radiological features of the BA dissection are rather complicated. But subarachnoid hemorrhage occurred in 40–60% of these patients.^[12] The mortality rate of BA dissection aneurysms was 30–50% and a good recovery in only 25% of patients.^[3,13] Wakhloo *et al.*^[14] found a higher re-canalization rate in posterior circulation aneurysms following stent or stent-assisted coiling (33% vs. 6%). The studies concerning stent alone in treating large and giant aneurysms are still limited. Pavlisa *et al.*^[15] reported their experiences in treating large or giant aneurysms by the sole stent. In their series, positive response to stent occurred in five of seven patients, but complete occlusion of the aneurysms were only observed in two patients. Meanwhile, aneurysms in two of seven patients ruptured after the procedure, and one patient died as a result of treatment, which was out of the author's expectation. The use of flow-diverting devices has gained momentum as a curative approach in the treatment of complex proximal anterior circulation intracranial aneurysms. Posterior circulation huge dissecting aneurysms have a particularly aggressive natural history. To date, no approach has been shown to be comprehensively effective or low risk.^[7-10] The IT technique (complete occlusion of dissected arterial and aneurysm segments) to treat the dissecting aneurysms involving the BA had rarely been reported. Peluso *et al.*^[16] reported only 2 cases treated by the IT technique without clinical sequelae. In our report, there were 15 patients treated by the IT technique, and 14 patients had excellent or good recovery. Re-canalization occurred in one patient whose aneurysm involved in bilateral vertebral arteries and the two-thirds of the middle-lower BA. In this patient, the coils were deployed inside the aneurysm on the lower BA and the junction of the two vertebral arteries first, until the dissection on the right VA just distal to the PICA was completely embolized. Then the guiding catheter

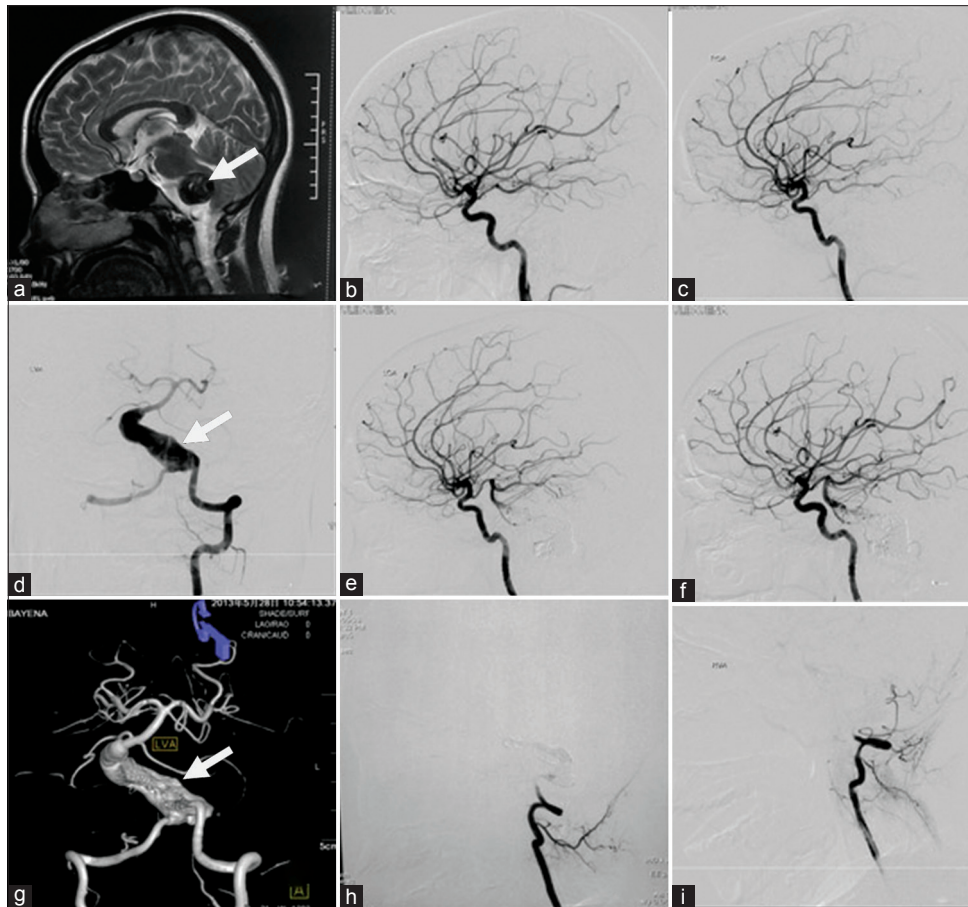


Figure 1: A 19-year-old woman had headache and left limbs weakness for 20 days. Magnetic resonance imaging revealed mass effect on the brainstem (a). Cerebral angiography showed a huge dissecting aneurysm of lower basilar artery (BA), proximal to the bilateral anterior inferior cerebellar artery, and the distal of bilateral vertebral artery (VA) involved (d and g). The internal carotid artery angiography showed that bilateral posterior communicating artery (PCoA) was prominent (b and c). After the operation, a vertebral angiogram showed occlusion of the dissecting aneurysm and proximal aneurysm with patency of the bilateral VA (h and i). The upper part of the BA could be visualized by bilateral PCoA (e and f) (the arrows showed the lesion part).

was moved to the left VA, and the left VA was occluded with coils, but a small amount of dissection just distal to the PICA was left. The patient fell into a coma one morning 6 weeks after the initial treatment. Emergent angiography showed that the dissecting aneurysm had re-canalized at the posterior part through the left VA. The patient awoke after the second intervention treatment and regained the ability to speak and cough. But 2 days after the second treatment, the patient died by the ventricular tachycardia.^[11]

Though the IT technique is effective in the treatment of huge dissecting aneurysms involved the BA, but strict indication and management after operation must be executed. When we designed the treatment with the parent artery occlusion, there were four technical considerations.

1. To keep brain stem perforators and make the patient safe after BA occlusion. The BA has two sets of pontine branches:^[2] first, a minute median set arteries at right angles to the parent artery, and enters the median sulcus of the pons along its length; second, a transverse set, which runs laterally and subdivides into smaller branches which penetrate the ventral surface of the

pons in a segmental fashion. These anastomoses could ensure the blood supply when one or more of the vessels were occluded for any reason, but the compensation course needs times, if the patient had an acute BA occlusion, the clinical outcome might be different. In our cases, it was highly likely that many of the brainstem perforators incorporated into the aneurysm sac were occluded by thrombus at the time of diagnosis and that the perforating artery territories involved were already supplied by collateral circulation. So we thought it is safety to make the occlusion of the BA

2. The size of PCoA is the key factor deciding whether the operation is done. The area critical to consciousness in man is supplied by the penetrating branches of the BA and the thalamus perforating branches of the posterior communicating and posterior cerebral arteries. In determining the safety of BA occlusion, the most important factor to be taken into account is the presence and the size of the PCoA. One study reported^[17] that when the size of PCoA was larger than 1 mm on angiography, the procedure was safe. In our study, ten patients' PCoAs in both sides were the presence and the

size of PCoA was larger than 1 mm on angiography, and four patients' PCoAs of one side were less than 1 mm. One patient with PCoA of both sides less than 1 mm was evaluated by test occlusion for 20–30 min by using two nondetachable silicone balloons in the bilateral VA. At the time of test occlusion, the neurologic evaluation was conducted by a neurologist, and the patients could tolerate it. Then after operation and 6 months, the compensated dilatation of the size of PCoA was found

3. To occlude only a proximal part of the lesion or the whole lesion. To date, endovascular approach of the BA dissection frequently relies upon the occlusion of the VA (s), which can be performed as selective unilateral occlusion of VA to reduce the blood pressure, and in turn, minimize the risk of re-bleeding, or perform a bilateral occlusion of VAs to induce flow reversal.^[18-20] However, there are several limitations to both these approaches. On one hand, the growth of the lesion might be observed due to incomplete obstruction of unilateral occlusion. On the other hand, bilateral intervention may cause disastrous consequences if the re-bleeding was due to a standstill of retrograde flow. In our experience, complete occlusion of the dissecting artery and aneurysm segments with coils could prevent re-bleeding safely and effectively without significant procedural complications, and had a good follow-up outcome. Then because of the economic reasons, we only embolized the proximal part compactly, and the aneurysm and the distal part loosely. Hence, this method could make thrombogenesis step by step and decrease the mass effect of the coils. The complications can seldom occur
4. The key point of the IT technique is occluding the enough length of the aneurysm and the dissecting artery. The study showed that^[21] the elastic plate defect is the main reason for the formation of the dissecting aneurysm. The vessel lumen and the pseudo-aneurysm communicate through the fracture of the elastic plate. We can see the stenosis in the proximal part of the aneurysm in DSA. Hence, we must occlude the aneurysm and the stenosis to the normal artery. If we only occlude the aneurysm, the blood fluid will impact the fracture of the elastic plate, and the aneurysm will recur. If we only occlude the part of stenosis, the blood fluid from the posterior artery will continue to impact the aneurysm and the aneurysm will rupture. In our patients, a patient with vertebra-basilar dissecting aneurysm received the embolism of the aneurysm and the parent artery. Because the left PICA is near to the aneurysm, we cannot embolize the left VA to the normal artery. Then the postoperative recurrence led to the patient's death after the second operation.

In conclusion, the IT technique is a technically feasible and safe alternative for the treatment of BA dissecting aneurysms but is not necessarily the safest or most definitive treatment modality. The ideal treatment of the huge dissecting aneurysms involving the BA remains debatable

and must be investigated on a case-by-case basis in terms of the availability of collateral flow, the anatomy in terms of aneurysm size, type, and location. A study with a larger population and longer follow-up is necessary for validation of the efficacy of this treatment modality.

REFERENCES

1. Drake CG, Peerless SJ. Giant fusiform intracranial aneurysms: Review of 120 patients treated surgically from 1965 to 1992. *J Neurosurg* 1997;87:141-62.
2. Tsuura M, Terada T, Yokote H, Matsumoto H, Hyoutani G, Kubo K, *et al.* Endovascular treatment for vertebral dissecting aneurysm presenting with subarachnoid hemorrhage. *Interv Neuroradiol* 1999;5 Suppl 1:203-6.
3. Yoshimoto Y, Hoya K, Tanaka Y, Uchida T. Basilar artery dissection. *J Neurosurg* 2005;102:476-81.
4. Wang Y, Yang X, Youxiang L, Shiqing M, Chuhan J, Zhongxue W, *et al.* Treatment of symptomatic fusiform aneurysm in basilar artery by stenting following coiling technique. *Turk Neurosurg* 2014;24:44-7.
5. Zhao KJ, Zhao R, Huang QH, Xu Y, Hong B, Fang YB, *et al.* The interaction between stent(s) implantation, PICA involvement, and immediate occlusion degree affect symptomatic intracranial spontaneous vertebral artery dissection aneurysm (sis-VADA) recurrence after reconstructive treatment with stent(s)-assisted coiling. *Eur Radiol* 2014;24:2088-96.
6. Zhao KJ, Fang YB, Huang QH, Xu Y, Hong B, Li Q, *et al.* Reconstructive treatment of ruptured intracranial spontaneous vertebral artery dissection aneurysms: Long-term results and predictors of unfavorable outcomes. *PLoS One* 2013;8:e67169.
7. Meckel S, McAuliffe W, Fiorella D, Taschner CA, Phatouros C, Phillips TJ, *et al.* Endovascular treatment of complex aneurysms at the vertebrobasilar junction with flow-diverting stents: Initial experience. *Neurosurgery* 2013;73:386-94.
8. van Oel LI, van Rooij WJ, Sluzewski M, Beute GN, Lohle PN, Peluso JP. Reconstructive endovascular treatment of fusiform and dissecting basilar trunk aneurysms with flow diverters, stents, and coils. *AJNR Am J Neuroradiol* 2013;34:589-95.
9. Siddiqui AH, Abl AA, Kan P, Dumont TM, Jahshan S, Britz GW, *et al.* Panacea or problem: Flow diverters in the treatment of symptomatic large or giant fusiform vertebrobasilar aneurysms. *J Neurosurg* 2012;116:1258-66.
10. Ertl L, Holtmannspötter M, Patzig M, Brückmann H, Fesl G. Use of flow-diverting devices in fusiform vertebrobasilar giant aneurysms: A report on periprocedural course and long-term follow-up. *AJNR Am J Neuroradiol* 2014;35:1346-52.
11. Yang X, Mu S, Lv M, Li L, Wu Z. Endovascular treatment of huge dissecting aneurysms involving the basilar artery. Experience and lessons from two cases. *Interv Neuroradiol* 2007;13:369-80.
12. Ruecker M, Furtner M, Knoflach M, Werner P, Gotwald T, Chemelli A, *et al.* Basilar artery dissection: Series of 12 consecutive cases and review of the literature. *Cerebrovasc Dis* 2010;30:267-76.
13. Raphaeli G, Collignon L, De Witte O, Lubicz B. Endovascular treatment of posterior circulation fusiform aneurysms: Single-center experience in 31 patients. *Neurosurgery* 2011;69:274-83.
14. Wakhloo AK, Mandell J, Gounis MJ, Brooks C, Linfante I, Winer J, *et al.* Stent-assisted reconstructive endovascular repair of cranial fusiform atherosclerotic and dissecting aneurysms: Long-term clinical and angiographic follow-up. *Stroke* 2008;39:3288-96.
15. Pavlisa G, Ozretic D, Murselovic T, Pavlisa G, Rados M. Sole stenting of large and giant intracranial aneurysms with self-expanding intracranial stents-limits and complications. *Acta Neurochir (Wien)* 2010;152:763-9.
16. Peluso JP, van Rooij WJ, Sluzewski M, Beute GN. Aneurysms of the vertebrobasilar junction: Incidence, clinical presentation, and outcome of endovascular treatment. *AJNR Am J Neuroradiol* 2007;28:1747-51.

17. Kang HS, Oh CW, Han MH, Byun HS, Han DH. Treatment of a sequential giant fusiform aneurysm of the basilar trunk. *Korean J Radiol* 2005;6:125-9.
18. Wang Q, Leng B, Song D, Chen G. Fusiform aneurysms of the vertebrobasilar arterial trunk: Choice of endovascular methods and therapeutic efficacy. *Acta Neurochir (Wien)* 2010;152:1467-76.
19. Kai Y, Hamada J, Morioka M, Yano S, Hamasaki K, Ushio Y. Successful treatment of a ruptured dissecting basilar artery aneurysm. Case report. *J Neurosurg* 2004;100:1072-5.
20. Taha MM, Sakaida H, Asakura F, Maeda M, Toma N, Yamamoto A, *et al.* Endovascular management of vertebral artery dissecting aneurysms: Review of 25 patients. *Turk Neurosurg* 2010;20:126-35.
21. Mizutani T, Kojima H, Asamoto S, Miki Y. Pathological mechanism

and three-dimensional structure of cerebral dissecting aneurysms. *J Neurosurg* 2001;94:712-7.

Received: 10-12-2014 **Edited by:** Xin Chen

How to cite this article: Mu SQ, Yang XJ, Li YX, Jiang CH, Wu ZX. Endovascular Treatment of the Huge Dissecting Aneurysms Involving the Basilar Artery by the Internal Trapping Technique: Technical Note. *Chin Med J* 2015;128:1916-21.

Source of Support: This work was supported by grants from the National Science Foundation of China (No. 81220108007, 81171079, 81371315 and 81471167) and Special Research Project for Capital Health Development (No. 2014-1-1071). **Conflict of Interest:** None declared.