



Classification and management options for prosthetic joint infection

Antonio Pellegrini¹, Virginia Suardi², Claudio Legnani³

¹IRCCS Istituto Ortopedico Galeazzi, Centre for Reconstructive Surgery and Osteoarticular Infections, Milan, Italy; ²Università degli Studi di Milano, Milan, Italy; ³IRCCS Istituto Ortopedico Galeazzi, Sport Traumatology and Minimally Invasive Surgery Center, Milan, Italy

Contributions: (I) Conception and design: A Pellegrini; (II) Administrative support: IRCCS Istituto Ortopedico Galeazzi; (III) Provision of study materials or patients: All authors; (IV) Collection and assembly of data: C Legnani, V Suardi; (V) Data analysis and interpretation: All authors; (VI) Manuscript writing: All authors; (VII) Final approval of manuscript: All authors.

Correspondence to: Antonio Pellegrini, MD, IRCCS. Istituto Ortopedico Galeazzi, Centre for Reconstructive Surgery and Osteoarticular Infections, Milan, Italy. Email: antonio.pellegrini@grupposandonato.it

Abstract: Periprosthetic joint infection (PJI) is one of the major complications following arthroplasty implantation. Management of PJIs is a challenge for surgeons and various classification systems have been introduced, which consider variables such as onset of symptoms, pathogenesis and clinical manifestation. In an attempt to overcome the shortcomings which may limit their usefulness in borderline cases, a new classification system focusing on the topography of the infectious process has been proposed. This theory relies on the identification of the exact location of the bacterial colonization thus allowing to decide between a conservative or a more radical intervention irrespectively of the timing. The use of nuclear medicine device like radiolabelled white blood cells (WBC) scan could lead the path in identifying pathogenetic processes and their exact location thus guiding orthopaedic surgeons to the most appropriate diagnosis and treatment options. Currently management relies on debridement, antibiotics and implant retention (DAIR), which is traditionally performed at early stages, 1- or 2-stage revision arthroplasty which is commonly limited to chronic cases. Reports have demonstrated similar rates of infection recurrence following one and two-stage revisions, and the use of one-stage revision surgery is gaining popularity. More recently, satisfying results following partial implant retention during revision total arthroplasty for septic failures have been reported. In addition, in severe cases, definitive articulating antibiotic spacer, excision arthroplasty, arthrodesis or amputation can be performed.

Keywords: Periprosthetic joint infections (PJIs); classification; management; topography

Received: 02 May 2020; Accepted: 10 September 2020; Published: 15 January 2022.

doi: 10.21037/aoj-20-86

View this article at: <http://dx.doi.org/10.21037/aoj-20-86>

Classification of prosthetic joint infections

Classification schemes for periprosthetic joint infections (PJIs) have been shown to be beneficial in terms of predicting the most appropriate treatment strategy.

The most widely accepted classification of periprosthetic infections of total joint replacements has been proposed by Coventry (1) and divides the occurrence of the infection into three stages: stage I (acute, within the first three months); stage II (more than 3 months after surgery); stage

III (2 years after infection) (Table 1). Perhaps the most frequently cited classification of PJI is the one formulated by Tsukayama *et al.* (2) which proposed a system which categorized infections into four groups (Table 2):

- ❖ Positive intra-operative cultures;
- ❖ Early postoperative infection occurring before 4 weeks;
- ❖ Late chronic infection (>4 weeks), and;
- ❖ Acute hematogenous infection.

A similar system was proposed by Toms *et al.* (3), who

Table 1 Classification of PJI according to Coventry *et al.*

	Type I	Type II	Type III
Presentation	Acute postoperative infection	Late chronic infection	Late hematogenous infection
Definition	Acute infection within the first 30 days after surgery	Chronic indolent infection presenting more than 30 days after surgery	Presenting beyond 2 years

PJI, periprosthetic joint infection.

Table 2 Classification of PJI according to Tsukayama *et al.*

	Stage I	Stage II	Stage III	Stage IV
Timing	Positive intraoperative culture	Early postoperative infection	Acute hematogenous infection	Late (chronic) infection
Clinical presentation	More than 2 positive intraoperative cultures	Infection occurring within first month	Hematogenous seeding of site of previously well-functioning prosthesis	Chronic indolent clinical course; infection present for more than 30 days

PJI, periprosthetic joint infection.

Table 3 PJI patterns according to Pellegrini *et al.*

	Type I	Type II	Type III	Type IV
Presentation	Acute postoperative infection	Acute postoperative infection	Chronic infection	Chronic infection
Location	Joint space	Bone/implant interface	Joint space	Bone/implant interface

PJI, periprosthetic joint infection.

otherwise consider early postoperative infections those being detected <6 weeks. Similarly, Cui *et al.* classified infection into four types according to onset of symptoms and positivity to intra-operative cultures (4).

Zimmerli *et al.* (5), distinguish between early PJIs (within 3 months postoperatively), delayed (3 to 24 months) or late (more than 24 months). A period of 3 months after surgery as the cut-off between acute or not has been mentioned also by Parvizi *et al.* (6). Recent recommendations reported by Osmon *et al.* (7) have achieved widespread acceptance internationally.

The timing of intervention is important. A short duration of symptoms is commonly considered the best prognostic factor in terms of eradication of infection (8,9). However, clarifications are needed in borderline cases, as the cut-off of an acute PJI ranges between 0–4 weeks (2) and 0–3 months (5,6). Based on available literature, robust scientific evidence correlating the duration of symptoms with the clinical outcome is lacking.

For these reasons a comprehensive seven point PJI classification has been proposed by Romanò *et al.* (10). This

classification system focuses on several issues including the host status, responsible microorganisms, bone and soft tissue defects, aetiopathogenesis, and anatomical and pathological features, from acute, with rapid-onset pain, swelling and wound purulence with or without systemic features of infection, to chronic, with serious discomfort, decreased movement and presence of sinus tract.

This system seems intuitive as, given that multiple factors influence PJI, it is illogical that timing alone influences management and outcomes.

More recently, in order to address ambiguities arising in current guidelines ant to encompass the cases which do not conform to the available classification systems, a different perspective has been introduced (11) (*Table 3*).

This new classification proposal focuses on the identification of different patterns of infection based on the topography of the infectious process: this theory relies on the identification of the exact location of the bacterial colonization and provides guidance for the treating surgeons, allowing them to decide between a conservative or a more radical intervention irrespectively of the timing (11).

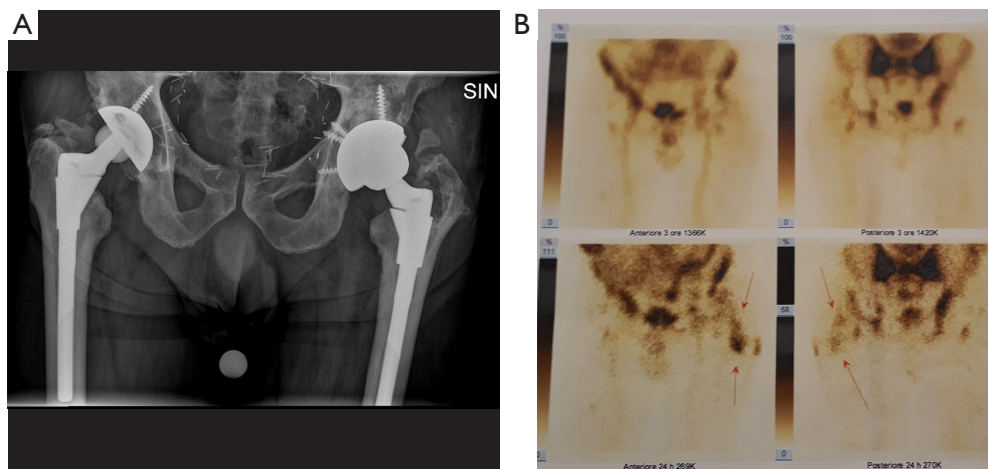


Figure 1 Radiolabeled white blood cells (WBC) imaging documenting the location of the infection in the joint space (red arrows).

In order to accurately localize the focus of infection contemporary imaging modalities such as nuclear scanning may be used; which may allow to improve localization and to better understand PJI patterns compared to conventional radiographs. Radiolabeled white blood cells (WBC) imaging, possesses the accuracy to distinguish between septic and aseptic loosening (12-14). Single-photon emission computed tomography (SPECT) is currently overtaking planar scintigraphy with a more detailed 3D localization (15), and the recent introduction of integrated SPECT/CT has allowed a more precise anatomic localization (16).

With this idea in mind, by using radiolabeled WBC by SPECT/CT to accurately localize the focus of infection, three different patterns can be identified:

- ❖ Infection involving the joint space (*Figure 1*);
- ❖ Infection involving the bone-implant interface (*Figure 2*);
- ❖ Infection involving both compartments (*Figure 3*).

This new approach, by taking advantage of recent nuclear imaging modalities, could improve current management of PJIs allowing useful selection criteria enhancing therapeutic strategies (*Figure 4*).

Management options

Several factors related to the host, infecting species and the surgeon influence the choice of treatment. Irrespective of the classification used the management should focus on eradicating the infection and restoring the pain free function of the affected limb. At present, treatment strategies for PJIs are based on the progression of the infectious process

and clinical involvement. Long term antibiotic suppression therapy is an option if surgical treatment it precluded (17).

Current surgical management relies on debridement, antibiotics and implant retention (DAIR), which is traditionally performed at early stages following the onset of symptoms, 1- or 2-stage revision arthroplasty which is usually limited to chronic stages. In addition, in severe cases, definitive articulating antibiotic spacer (shoulder), excision arthroplasty (hip), arthrodesis or amputation (knee) can be performed.

Typically, DAIR is considered to be the treatment of choice in patients with a short duration of symptoms, which allows implant preservation, good functional outcomes and shorter hospital stays (18-26).

A 2-stage exchange strategy is commonly considered to be the 'gold standard' for the management of PJI, since it is advocated to provide effective infection eradication, although it is a complex surgical procedure usually which can itself result in bone and soft tissue damage (27).

The one-stage approach possesses the advantages of avoiding multiple major invasive surgical procedures and prolonged hospitalization however it needs strict criteria to be applied as it has to be performed in healthy patients Type A hosts (1) with healthy soft tissues and with minimal or moderate bone loss and in whom the infecting organism and the antibiotic sensitivities are known.

Several authors have reported similar rates of infection recurrence following one and two-stage revisions (28-32), and the use of one-stage revision surgery is gaining popularity.

Recently, satisfying results following partial implant

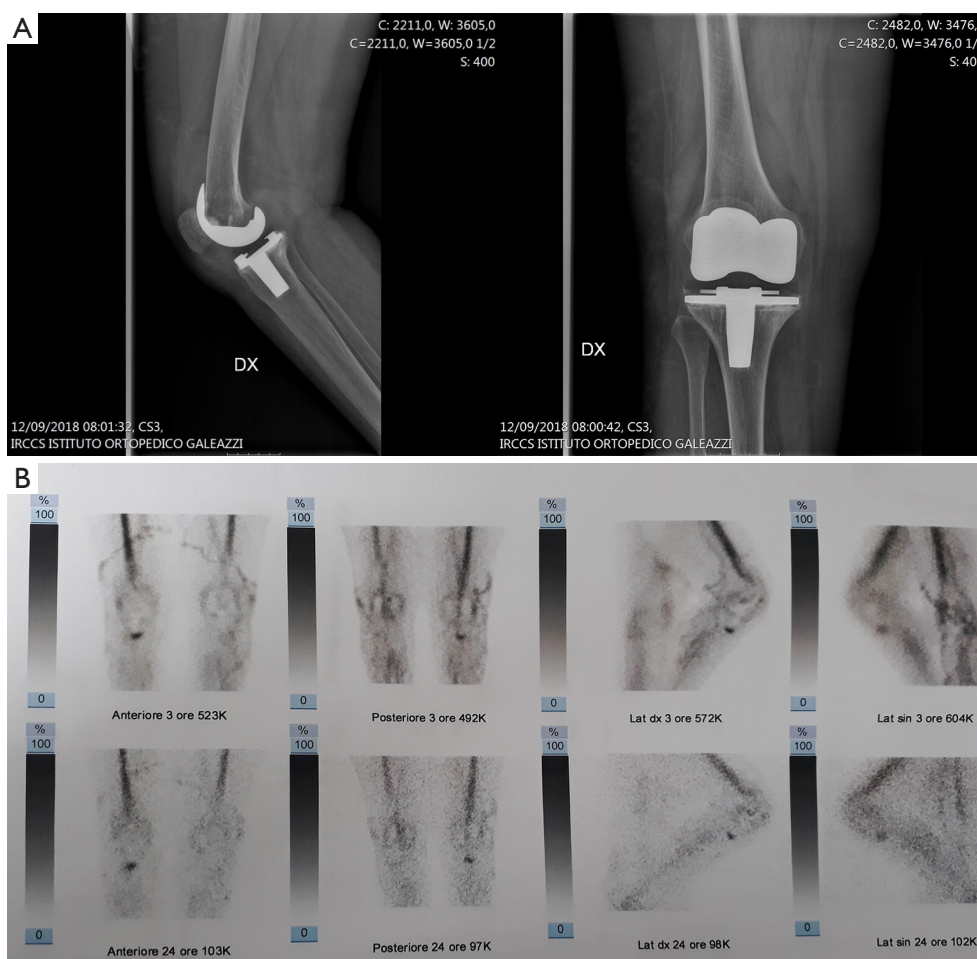

Figure 2 Radiolabeled white blood cells (WBC) imaging documenting the location of the infection at the bone-implant interface.

retention during revision total arthroplasty for septic failures have been reported (33-36).

In a study by Ekpo *et al.* (33), a success rate of 89.4% (17 out of 19) has been reported at a minimum of 2 years follow-up after partial revision arthroplasty (range, 2–11 years). Similarly, a low reinfection rate (6.6%) has been reported by Morley *et al.* (34) 6.8 years following partial hip revision surgery. El-Husseiny *et al.* (36) reviewed 18 patients with infected THAs treated with selective implant retention at a minimum of 5 years follow-up (range, 5–9.9 years). Three patients (16.6%) had recurrent infection at the site of the prosthesis. Postoperative average Harris hip score was 78 (range, 46–89). These positive outcomes may demonstrate that bacteria have not invaded all implant components, and that the identification of the exact location of the infection may allow selective implant retention (11).

The use of a permanent cement spacer and resection

arthroplasty may be considered viable treatment options in elderly, low-demand patient with severe medical comorbidities, as well as patients with limited bone stock, poor soft tissue coverage, or infections due to highly resistant organisms in whom surgery is deemed too high risk (37-41).

Similarly arthrodesis represents a salvage option for the septic prosthetic knee joint infection once multiple revision procedures have been exhausted providing acceptable functionality and satisfactory quality of life when bone stock is insufficient (40,41).

In case no measures to salvage a functional TKA can be pursued, knee arthrodesis or above-knee amputation should be considered as salvage procedures to eradicate the infectious process, and sometimes saves the patients' life. Knee arthrodesis may allow limb preservation and residual joint functionality in absence of sufficient bone stock (42).

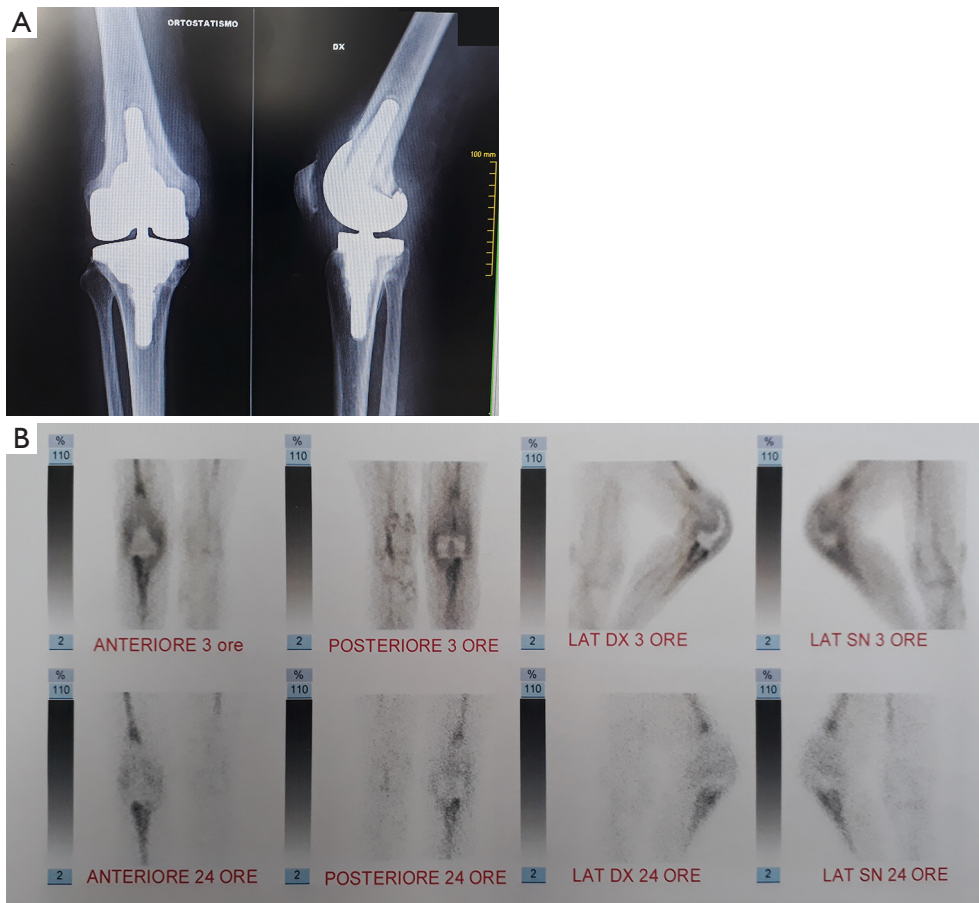


Figure 3 Radiolabeled white blood cells (WBC) imaging showing infection involvement of both compartments.

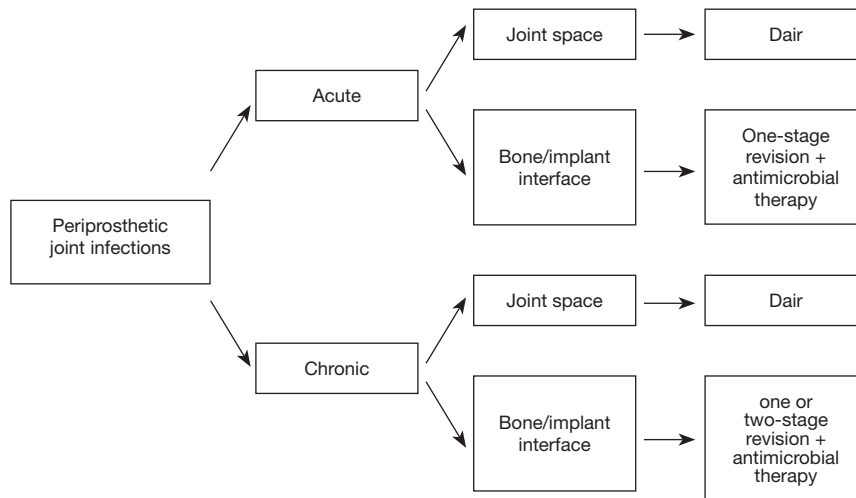


Figure 4 New classification treatment algorithm proposal focusing on the topography of the infectious process.

Amputation should be the last option considered in presence of serious and permanent tissue damage, although may be appropriate in selected cases (43,44).

Conclusions

The classification of PJI can be used to guide clinicians with therapeutic decision making. There are however several classification systems which vary in their definition of what constitutes an acute infection as well as what prognostic factors are important in patients with PJI. Multicentre prospective randomized controlled trials are required to help to define these important issues.

Acknowledgments

Funding: None.

Footnote

Provenance and Peer Review: This article was commissioned by the Guest Editors (Nemandra A. Sandiford, Massimo Francescini and Daniel Kendoff) for the series “Prosthetic Joint Infection” published in *Annals of Joint*. The article has undergone external peer review.

Conflicts of Interest: All authors have completed the ICMJE uniform disclosure form (available at <http://dx.doi.org/10.21037/aoj-20-86>). The series “Prosthetic Joint Infection” was commissioned by the editorial office without any funding or sponsorship. The authors have no other conflicts of interest to declare.

Ethical Statement: The authors are accountable for all aspects of the work in ensuring that questions related to the accuracy or integrity of any part of the work are appropriately investigated and resolved.

Open Access Statement: This is an Open Access article distributed in accordance with the Creative Commons Attribution-NonCommercial-NoDerivs 4.0 International License (CC BY-NC-ND 4.0), which permits the non-commercial replication and distribution of the article with the strict proviso that no changes or edits are made and the original work is properly cited (including links to both the formal publication through the relevant DOI and the license). See: <https://creativecommons.org/licenses/by-nc-nd/4.0/>.

References

1. Coventry MB. Treatment of infections occurring in total hip surgery. *Orthop Clin North Am* 1975;6:991-1003.
2. Tsukayama DT, Estrada R, Gustilo R. Infection after total hip arthroplasty. A study of the treatment of one hundred and six infections. *J Bone Joint Surg Am* 1996;78:512-23.
3. Toms AD, Davidson D, Masri BA, et al. The management of peri-prosthetic infection in total joint arthroplasty. *J Bone Joint Surg Br* 2006;88:149-55.
4. Cui Q, Mihalko WM, Shields JS, et al. Antibiotic-impregnated cement spacers for the treatment of infection associated with total hip or knee arthroplasty. *J Bone Joint Surg Am* 2007;89:871-82.
5. Zimmerli W, Trampuz A, Ochsner PE. Prosthetic-joint infections. *N Engl J Med* 2004;351:1645-54
6. Parvizi J, Adeli B, Zmistowski B, et al. Management of periprosthetic joint infection: the current knowledge: AAOS exhibit selection. *J Bone Joint Surg Am* 2012;94:e104.
7. Osmon DR, Berbari EF, Berendt AR, et al. Executive summary: diagnosis and management of prosthetic joint infection: clinical practice guidelines by the Infectious Diseases Society of America. *Clin Infect Dis* 2013;56:1-10.
8. Romanò CL, Manzi G, Logoluso N, et al. Value of debridement and irrigation for the treatment of peri-prosthetic infections. A systematic review. *Hip Int* 2012 Suppl 8:S19-24.
9. Azzam KA, Seeley M, Ghanem E, et al. Irrigation and debridement in the management of prosthetic joint infection: traditional indications revisited. *J Arthroplasty* 2010 25:1022-7.
10. Romanò CL, Romano D, Logoluso N. Bone and joint infection on adults: a comprehensive classification proposal. *Eur Orthop Traumatol* 2011;1:207-17.
11. Pellegrini A, Legnani C, Meani E. A new perspective on current prosthetic joint infection classifications: introducing topography as a key factor affecting treatment strategy. *Arch Orthop Trauma Surg* 2019;139:317-22.
12. Palestro CJ. Radionuclide Imaging of Musculoskeletal Infection: A Review. *J Nucl Med* 2016;57:1406-12.
13. Palestro CJ. Nuclear medicine and the failed joint replacement: past, present, and future. *World J Radiol* 2014;6:446-8.
14. Signore A, Sconfienza LM, Borens O, et al. Consensus document for the diagnosis of prosthetic joint infections: a joint paper by the EANM, EBJIS, and ESR (with

- ESCMID endorsement). *Eur J Nucl Med Mol Imaging* 2019;46:971-88.
15. van der Bruggen W, Bleeker-Rovers CP, Boerman OC, et al. PET and SPECT in osteomyelitis and prosthetic bone and joint infections: a systematic review. *Semin Nucl Med* 2010;40:3-15.
 16. Kim HO, Na SJ, Oh SJ, et al. Usefulness of adding SPECT/CT to 99mTc hexamethylpropylene amine oxime (HMPAO)-labeled leukocyte imaging for diagnosing prosthetic joint infections. *J Comput Assist Tomogr* 2014;38:313-9.
 17. Prendki V, Sergent P, Barrelet A, et al. Efficacy of indefinite chronic oral antimicrobial suppression for prosthetic joint infection in the elderly: a comparative study. *Int J Infect Dis.* 2017;60:57-60.
 18. Silva M, Tharani R, Schmalzried TP. Results of direct exchange or debridement of the infected total knee arthroplasty. *Clin Orthop Relat Res* 2002;404:125-31.
 19. Deirmengian C, Greenbaum J, Lotke PA, et al. Limited success with open debridement and retention of components in the treatment of acute *Staphylococcus aureus* infections after total knee arthroplasty. *J Arthroplasty* 2003;18:22-6.
 20. Flierl MA, Culp BM, Okroj KT, et al. Poor Outcomes of Irrigation and Debridement in Acute Periprosthetic Joint Infection With Antibiotic-Impregnated Calcium Sulfate Beads. *J Arthroplasty* 2017;32:2505-7.
 21. Romanò C, Logoluso N, Drago L, et al. Role for irrigation and debridement in periprosthetic infections. *J Knee Surg* 2014;27:267-72.
 22. Lizaaur-Utrilla A, Gonzalez-Parreno S, Gil-Guillen V, et al. Debridement with prosthesis retention and antibiotic therapy vs two-stage revision for periprosthetic knee infection within 3 months after arthroplasty: a case-control study. *Cin Microbiol Infect* 2015;21:851.e11-7.
 23. Urish KL, Bullock AG, Kreger AM, et al. A Multicenter Study of Irrigation and Debridement in Total Knee Arthroplasty Periprosthetic Joint Infection: Treatment Failure Is High. *J Arthroplasty* 2018;33:1154-9.
 24. Gardner J, Gioe TJ, Tatman P. Can this prosthesis be saved? Implant salvage attempts in infected primary TKA. *Clin Orthop Relat Res* 2011;469:970-6.
 25. Fehring TK, Odum SM, Berend KR, et al. Failure of irrigation and debridement for early postoperative periprosthetic infection. *Clin Orthop Relat Res* 2013;471:250-7.
 26. Mont MA, Waldman B, Banerjee C, et al. Multiple irrigation, debridement, and retention of components in infected total knee arthroplasty. *J Arthroplasty* 1997;12:426-33.
 27. Berend KR, Lombardi AV Jr, Morris MJ, et al. Two-stage treatment of hip periprosthetic joint infection is associated with a high rate of infection control but high mortality. *Clin Orthop Relat Res* 2013;471:510-8.
 28. Buechel FF, Femino FP, D'Alessio J. Primary exchange revision arthroplasty for infected total knee replacement: a longterm study. *Am J Orthop (Belle Mead NJ)* 2004;33:190-8.
 29. Jenny JY, Barbe B, Gaudias J, et al. High infection control rate and function after routine one-stage exchange for chronically infected TKA. *Clin Orthop Relat Res* 2013;471:238-43.
 30. Wongworawat MD. Clinical faceoff: One- versus two-stage exchange arthroplasty for prosthetic joint infections. *Clin Orthop Relat Res* 2013;471:1750-3.
 31. Nagra NS, Hamilton TW, Ganatra S, et al. One-stage versus two-stage exchange arthroplasty for infected total knee arthroplasty: a systematic review. *Knee Surg Sports Traumatol Arthrosc* 2016;24:3106-14.
 32. Pellegrini A, Legnani C, Macchi V, et al. Two-stage revision shoulder prosthesis vs. permanent articulating antibiotic spacer in the treatment of periprosthetic shoulder infections. *Orthop Traumatol Surg Res* 2019;105:237-40.
 33. Ekpo TE, Berend KR, Morris MJ, et al. Partial two-stage exchange for infected total hip arthroplasty: a preliminary report. *Clin Orthop Relat Res* 2014;472:437-48.
 34. Morley JR, Blake SM, Hubble MJ, et al. Preservation of the original femoral cement mantle during the management of infected cemented total hip replacement by two-stage revision. *J Bone Joint Surg Br* 2012;94:322-7.
 35. Lee YK, Lee KH, Nho JH, et al. Retaining well-fixed cementless stem in the treatment of infected hip arthroplasty. *Acta Orthop* 2013;84:260-4.
 36. El-Husseiny M, Haddad FS. The Role of Highly Selective Implant Retention in the Infected Hip Arthroplasty. *Clin Orthop Relat Res* 2016;474:2157-63.
 37. Pellegrini A, Legnani C, Macchi V, et al. Management of periprosthetic shoulder infections with the use of a permanent articulating antibiotic spacer. *Arch Orthop Trauma Surg* 2018;138:605-9.
 38. Fink B, Sevelde F. Periprosthetic Joint Infection of Shoulder Arthroplasties: Diagnostic and Treatment Options. *Biomed Res Int* 2017;2017: 4582756
 39. Fleck EE, Spangehl MJ, Rapuri VR, et al. An articulating antibiotic spacer controls infection and improves pain and

- function in a degenerative septic hip. *Clin Orthop Relat Res* 2011;469: 3055-64.
40. Ablitt WP, Ascione T, Bini S, et al. Hip and Knee Section, Outcomes: Proceedings of International Consensus on Orthopedic Infections. *J Arthroplasty* 2019;34:S487-95.
 41. Balato G, Rizzo M, Ascione T, et al. Re-infection rates and clinical outcomes following arthrodesis with intramedullary nail and external fixator for infected knee prosthesis: a systematic review and meta-analysis. *BMC Musculoskelet Disord* 2018;19:361.
 42. Wu CH, Gray CF, Lee GC. Arthrodesis should be strongly considered after failed two-stage reimplantation TKA. *Clin Orthop Relat Res* 2014;472:3295-304.
 43. Gehrke T, Alijanipour P, Parvizi J. The management of an infected total knee arthroplasty. *Bone Joint J* 2015; 97-B:20-9.
 44. Hawi N, Kendoff D, Citak M, et al. Septic single-stage knee arthrodesis after failed total knee arthroplasty using a cemented coupled nail. *Bone Joint J* 2015;97-B:649-53.

doi: 10.21037/aoj-20-86

Cite this article as: Pellegrini A, Suardi V, Legnani C. Classification and management options for prosthetic joint infection. *Ann Joint* 2022;7:3.