

Swelling in the Floor of the Mouth: A Diagnostic Dilemma

Ginni Datta, Ankita Yadav¹

Departments of ENT and ¹Head and Neck Surgery, MMDU, Ambala, Haryana, India

Abstract

Epidermoid cysts are abnormal structures originating from abnormal ectoderm and are benign and slow growing. These are found anywhere in the body. They arise during embryonic fusion due to entrapment of epithelial remnants and sometimes due to faulty implantation of the epithelium. The cysts can be epidermoid (squamous epithelium), true dermoid (skin appendages), and teratoid (all germ layers). They are usually diagnosed by fine-needle cytological aspiration and require imaging to plan line of treatment. Diagnostic dilemma is always an issue as cystic lesions are commonly found in the head-and-neck region. Here, we present a case of large epidermoid cyst involving sublingual and submandibular region.

Keywords: Epidermoid cyst, fine needle aspiration cytology, plunging ranula

INTRODUCTION

Epidermoid, dermoid and teratoid cysts are cystic malformations with squamous epithelium lining. They are classified as epidermoid (squamous epithelium), dermoid (skin adnexa), and teratoid (tissue as muscle, cartilage, and bone).^[1,2] They are gradually progressing, benign lesions, which arise from abnormal ectoderm. A simple cyst is lined with squamous epithelium and has no other adnexal structures with or without keratinous material. Epidermal cysts could be found anywhere in the body, head and neck (7%) and oral cavity (1.6%).^[3-5] The most common site is the floor of the mouth, followed by the lips, tongue, and buccal mucosa.^[6,7] Diagnosis is made by imaging assisted by fine-needle aspiration and excisional biopsy. The head-and-neck region is a common site for different types of clinically similar and comparable lesions, hence making diagnosis difficult, thus complicating decision making regarding the line of treatment.

Epidermoid cysts present with male predilection, most commonly seen in the age group of 15 and 35 years but can present in any age group. They are gradually progressive benign masses, which can cause pressure symptoms such as dysphagia and dyspnea when large in size.^[3] The patient can present with unusual symptoms such as pain, respiratory distress and speech disorder when involving the lower lip, upper lip, or oral cavity.^[6] Head-and-neck is an unusual site for epidermoid cysts thus having a high chance for misdiagnosis.

Here, we discuss managing strategies and problems faced while treating a case of an epidermoid cyst which was misleading in its clinical and radiographical profile.

CASE REPORT

A 24-year-old male patient presented to the outpatient department with a right-sided neck swelling for 8–9 months. The swelling was insidious in onset and gradually progressive in nature, started as the size of a pea and progressed to present size. He noticed a swelling on the right side floor of the mouth after a period of 2 months from the initial swelling in the neck. He gave no history of pain, discharge from swelling, difficulty swallowing, difficulty breathing, and no association with fever. Medical and dental history was not significant.

On examination

Extraorally swelling was found in the right submandibular region, round in shape measuring approximately 5 cm × 3 cm in dimension [Figure 1]. On palpation, it was nontender without local rise in temperature, freely mobile, and no fixity

Address for correspondence: Dr. Ankita Yadav,
D-102 The Villas, DLF Phase 2, Gurugram - 122 002, Haryana, India.
E-mail: dr.ankitayadav12@gmail.com

Received: 03-12-2019

Revised: 12-01-2020

Accepted: 07-02-2020

Published: 08-06-2020

Access this article online

Quick Response Code:



Website:
www.amsjournal.com

DOI:
10.4103/ams.ams_263_19

This is an open access journal, and articles are distributed under the terms of the Creative Commons Attribution-NonCommercial-ShareAlike 4.0 License, which allows others to remix, tweak, and build upon the work non-commercially, as long as appropriate credit is given and the new creations are licensed under the identical terms.

For reprints contact: WKHLRPMedknow_reprints@wolterskluwer.com

How to cite this article: Datta G, Yadav A. Swelling in the floor of the mouth: A diagnostic dilemma. *Ann Maxillofac Surg* 2020;10:258-61.

were observed to the underlying structure. On inspection, the skin was normal in color and texture and was pinchable.

Intraoral examination revealed a swelling on the right side floor of the mouth not crossing midline measuring approximately 3 cm × 1 cm. The swelling was cystic in consistency, fluctuant, compressible, and nontender; tongue mobility was normal.

Fine-needle aspiration cytology (FNAC) of the submandibular swelling was done; findings were suggestive of a sebaceous cyst. Ultrasonography (USG) feature of the neck was suggestive of a dermoid cyst.

Contrast-enhanced computed tomography (CECT) of the neck [Figure 2a-c] showed a large nonenhancing well-circumscribed cystic lesion in the floor of the mouth involving right sublingual space and extending into the right submandibular space with the presentation of a plunging ranula.

Enucleation of the cyst was done by a submandibular approach with the removal of the involved submandibular gland under general anesthesia, along with an intraoral approach removing all adhesions along the lesion and removing sublingual gland delivered through a submandibular approach [Figure 3].

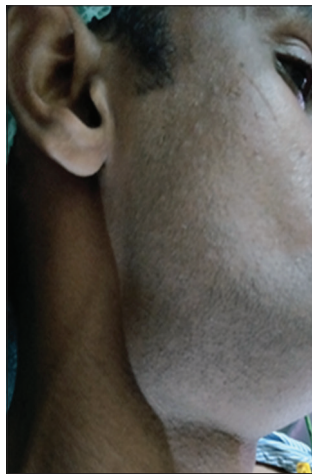

Figure 1: Extraoral swelling

The specimen received measured 3 cm × 2.5 cm in dimension [Figure 4], yellow in color, and doughy consistency on palpation. Gross examination showed cheesy material inside with a thin external capsule [Figure 5].

On histopathological examination

Chronic inflammatory cells were seen in the cystic lining and connective tissue capsule under high-power microscope (×40), with staining hematoxylin and eosin (H and E) [Figure 6].

A hematoxylin and Eosin stained section of the cyst under 4x magnification was seen to be lined by keratinized stratified squamous epithelium, with an excess amount of keratin in the lumen. Chronic inflammatory cells were found in connective-tissue capsule (no skin appendages visualized) [Figure 7]. Histopathological examination was suggestive of the dermoid cyst.

DISCUSSION

Neck masses are a common presentation to an otorhinolaryngologist. In the adult population, 80% of nonthyroid masses are neoplastic. Of these, 75% account for metastatic masses. In children below 15 years, 90% of masses are benign out of which 55% are congenital. Epidermoid cysts in the form of cutaneous lesions most commonly occur in the scalp, face, and trunk. As seen in older and in recent literature, epidermoid cysts and dermoid cysts in the deeper planes are less common and account for only 1.6-6.9%.^[3] In a retrospective study of 89 children, a majority of 58.88% cases were dermoid cyst and only 13.33% were epidermoid cyst.^[7] In a study conducted by New and Erich at the Mayo clinic on 1495 cases of dermoid cysts, only 24 were intraoral, in the floor of the mouth and most commonly reported in ovaries and testicles (80%) and about 7% seen in head and neck.^[8,9] They are quite uncommon in the oral cavity, comprising <0.01% of all oral cysts.^[9-11] Epidermoid cysts are benign cysts seen anywhere in the body, most commonly seen at embryonic fusion sites.

Epidermoid cysts in the floor of the mouth occur due to epithelial remnants getting entrapped in the course of midline closure of the second and third branchial arches during

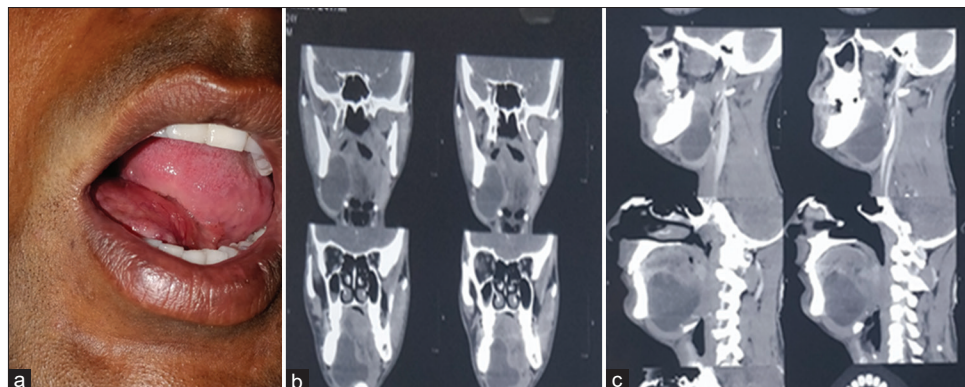


Figure 2: (a) Intraoral swelling, (b) Axial view showing nonenhancing mass, (c) Sagittal view nonenhancing right submandibular, sublingual region

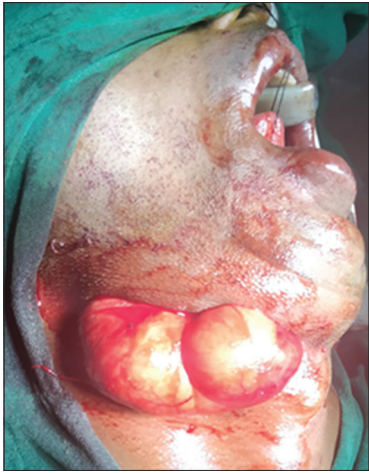

Figure 3: Intraoperatively showing two cystic swellings delivered via the submandibular approach

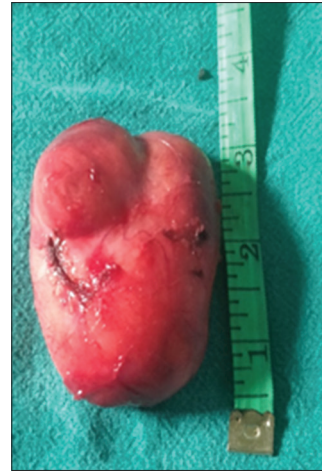

Figure 4: Specimen measuring 3 cm × 2 cm

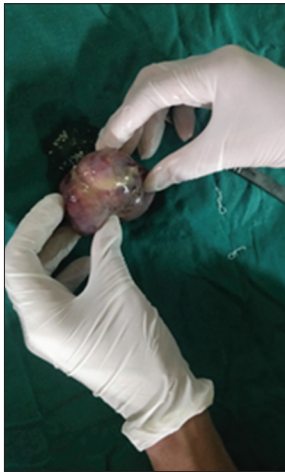

Figure 5: Cheesy material inside the swelling

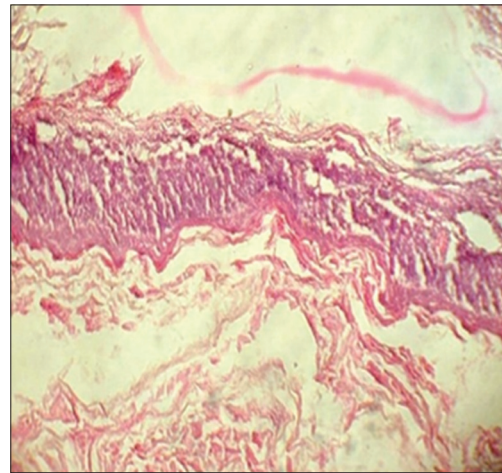


Figure 6: Histopathological slides

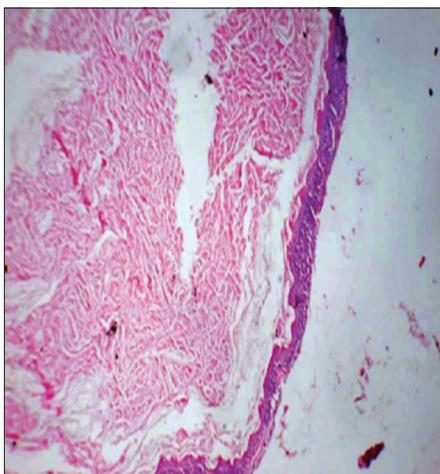


Figure 7: Histopathological slides

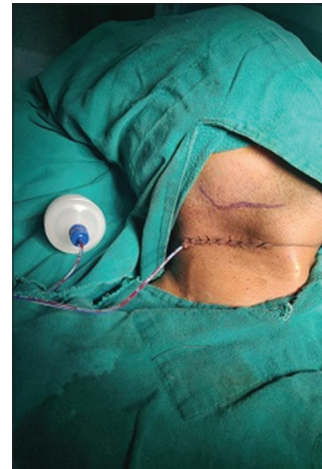

Figure 8: Post operative picture showing the incision with drain *in situ*

3rd–5th week of gestation. It can also be due to ectodermal differentiation of multipotent cells which have been pinched off during anterior neuropore closure or can be a thyroglossal duct cyst variant. Irrespective of the etiology, such cystic swellings

remain unnoticed until it produces a mechanical obstruction, as seen in our patient. Epidermoid cysts can be of two types based on their origin, i.e., congenital or acquired, but both are the same clinically as well as histopathologically. Age group is no bar but mainly seen between 15 and 35 years of age

with male predominance. Although most common site here is the midline of the floor of cavity, occasionally involving the buccal mucosa, lips, tongue, uvula, temporomandibular joint dermal graft, etc., because of the above mentioned, mylohyoid muscles pushes the tongue which causes symptoms such as dysphagia, dyspnea, and dysphonia, while below it causes swelling below the chin.

Epidermoid cysts on palpation have dough-like consistency or fluctuant and cyst-like consistency, with contents being cheesy to the liquefied substance with cyst wall of 2–6 mm thickness,^[5] as clearly seen in our patient. In confirming the diagnosis and classification of cyst imaging modalities play a key role. The initial line of investigation is USG. In our patient, USG was suggestive of dermoid cyst, whereas fine-needle aspiration was suggestive of sebaceous cyst. The head-and-neck region swelling presents with wide range of differential diagnosis. To confirm the diagnosis, we planned a CECT scan for the patient. Epidermoid cysts are well-defined cyst with multiple echogenic nodules in the cyst. CECT scan gives an appearance of the unilocular cyst with hypoattenuating homogeneous cyst with multiple hypoattenuating fat densities giving a sack of marble appearance. The CECT scan in our patient was suggesting of plunging ranula which added to the confusion in confirming the diagnosis. CECT helped in differentiating vascular lesions such as capillary hemangioma, arterial malformation, and venous malformation. Treatment comprises total surgical excision, the approach is decided based on the site of the cyst with respect to the muscle plane in the floor of the mouth either intraorally (small sublingual lesion above the mylohyoid muscle) or externally (cervical approach for large submandibular or submental lesions below the geniohyoid).^[3] A combined approach (intraoral & cervical) may be considered in large lesions, typically presenting as dumbbell. The computed tomography (CT) imaging of the patient did not clearly guided us for the approach to take as it was a dumbbell-shaped cyst occupying the floor of the mouth and submandibular gland. Clinically and radiologically, we were in favor of plunging ranula, as it is more commonly encountered entity than an epidermoid cyst.

CONCLUSION

Epidermoid cysts of the head-and-neck origin are rare findings and hence likely to be misdiagnosed. The chances of misdiagnosis are manifold due to unusual and misleading

clinical presentation. We have found preoperative FNAC more informative and guiding. CT scan is a necessity to guide the anatomical plane, nature of the surgery, and plan surgery. Here, we present a simple case of a epidermoid cyst which was initially diagnosed as lipoma, FNAC was suggestive of a dermoid cyst, and CT suggestive of plunging ranula later turned out to be an epidermoid cyst, so the varied and extraordinary presentation of epidermoid cysts is challenging and entertaining for the otorhinolaryngology clinicians.

Declaration of patient consent

The authors certify that they have obtained all appropriate patient consent forms. In the form the patient(s) has/have given his/her/their consent for his/her/their images and other clinical information to be reported in the journal. The patients understand that their names and initials will not be published and due efforts will be made to conceal their identity, but anonymity cannot be guaranteed.

Financial support and sponsorship

Nil.

Conflicts of interest

There are no conflicts of interest.

REFERENCES

1. De Ponte FS, Brunelli A, Marchetti E, Bottini DJ. Sublingual epidermoid cyst. *J Craniofac Surg* 2002;13:308-10.
2. Meyer I. Dermoid cysts (dermoids) of the floor of the mouth. *Oral Surg Oral Med Oral Pathol* 1955;8:1149-64.
3. Jham BC, Duraes GV, Jham AC, Santos CR. Epidermoid cyst of the floor of the mouth: A case report. *J Can Dent Assoc* 2007;73:525-8.
4. Pereira CM, Gasparetto PF, de Lucena Botelho T. Atypical appearance of epidermoid cyst in tongue's ventral surface. *RSBO* 2011;8:240-2.
5. Mirza S, Fadl S, Napaki S, Abualruz A. Case report of complicated epidermoid cyst of the floor of the mouth: Radiology-histopathology correlation. *Qatar Med J* 2014;2014:12-6.
6. Handa U, Kumar S, Mohan H. Aspiration cytology of epidermoid cyst of terminal phalanx. *Diagn Cytopathol* 2002;26:266-7.
7. Armon N, Shamay S, Maly A, Margulis A. Occurrence and characteristics of head cysts in children. *Eplasty* 2010;10:e37.
8. Koca H, Seckin T, Sipahi A, Kazanc A. Epidermoid cyst in the floor of the mouth: Report of a case. *Quintessence Int* 2007;38:473-7.
9. Ozan F, Polat HB, Ay S, Goze F. Epidermoid cyst of the buccal mucosa: A case report. *J Contemp Dent Pract* 2007;8:90-6.
10. Pancholi A, Raniga S, Vohra PA, Vaidya V. Midline submental epidermoid cyst: A rare case. *Internet J Otorhinolaryngol* 2006;4:1-5.
11. Kandogan T, Koç M, Vardar E, Selek E, Sezgin O. Sublingual epidermoid cyst: A case report. *J Med Case Rep* 2007;1:87.