

Short Communication

Renal lesions in leptin receptor-deficient medaka (*Oryzias latipes*)

Shinichi Chisada^{1*} and Akihiko Sugiyama²

¹ Department of Hygiene and Public Health, Kyorin University School of Medicine, 6-20-2 Shinkawa, Mitaka-shi, Tokyo 181-8611, Japan

² Faculty of Veterinary Medicine, Okayama University of Science, 1-3 Ikoinooka, Imabari-shi, Ehime 794-8555, Japan

Abstract: The aim of this study was to elucidate the renal lesions of leptin receptor-deficient medaka showing hyperglycemia and hypoinsulinemia and to evaluate the usefulness of the medaka as a model of diabetic nephropathy. Leptin receptor-deficient medaka at 20 and 30 weeks of age showed hyperglycemia and hypoinsulinemia; they also showed a higher level of plasma creatinine than the control medaka. Histopathologically, dilation of glomerular capillary lumina and of afferent/efferent arterioles was observed in leptin receptor-deficient medaka at 20 weeks of age, and then glomerular enlargement with cell proliferation and matrix expansion, formation of fibrin cap-like lesions, glomerular atrophy with Bowman's capsule dilation, and renal tubule dilation were observed at 30 weeks of age. These histopathological characteristics of leptin receptor-deficient medaka were similar to the characteristics of kidney lesions of human and rodent models of type II diabetes mellitus, making leptin receptor-deficient medaka a useful model of diabetic nephropathy. (DOI: 10.1293/tox.2019-0021; J Toxicol Pathol 2019; 32: 297–303)

Key words: hyperglycemia, leptin receptor-deficient medaka, nephropathy

Diabetic nephropathy (DN) is one of the serious microvascular complications of diabetes mellitus and is the main cause of end-stage renal failure around the world^{1–3}. Its symptoms appear around 10 years after the onset of diabetes mellitus. Many treatments have been tried, but no fundamental treatment has yet been found. Not only better treatments but also preventive methods are urgently needed worldwide. Therefore, full understanding of the development and progression of DN is a prerequisite.

Animal models are powerful tools for understanding pathogenetic mechanisms. Models used in current DN research partially show the pathological changes of human DN and contribute to understanding the pathological characteristics⁴. However, the models fail to show the structural features of advanced human disease because most have been developed in different ways, surgically, pharmacologically, and/or genetically modified, from the actual process in humans^{5, 6}, although diabetic complications progress as pathogenic lesions with increasing age. There are few animals suitable for elucidating the progressive pathological changes that occur with increasing age.

The kidney is one of the controllers of fluid homeo-

stasis⁷. Diabetes mellitus, hypertrophy, albuminuria, and other factors damage the kidney and result in progressive nephropathy in humans^{8, 9}. Among animal models showing DN, streptozotocin-induced rodents, high-fat diet-induced mice, Ins2 Akita mice, NOD mice, *db/db* mice, and New Zealand obesity mice have been frequently used⁵. They show some of the characteristic lesions of humans with DN. Although the ZDF rat and the *cp/cp* rat are also animals with leptin-receptor deficiency and exhibit hyperglycemia, some of these rats do not always show hyperglycemia, and in others, glucose tolerance improves with aging¹⁰, due to the high ability of their islet beta-cells to secrete insulin, which is an innate characteristic of rats¹¹. To use rats as a model of DN, rats that are congenitally hypertensive¹⁰ or have undergone transgenic modification must be used¹². Since there are also various differences in metabolism and compensatory functions among mouse strains, they show different characteristics of DN⁵. Therefore, researchers have carefully taken their characteristics into account and effectively used model animals to extrapolate the findings to humans.

The medaka kidney is well characterized and is anatomically and functionally similar to human and rodent kidneys¹³. Genetic approaches, the method of targeting induced local lesions in the genome (TILLING)¹⁴, targeted mutagenesis using transcription activator-like effector nucleases (TALENs)¹⁵, and the clustered regularly interspaced short palindromic repeats (CRISPR)/CRISPR-associated (CAS) system¹⁶ have been successful, and rearing conditions have been established experimentally¹⁷. These approaches make it possible to analyze various phenotypes at the laboratory level. It has been expected that medaka would be used in the development of human disease models that display patho-

Received: 28 February 2019, Accepted: 11 May 2019

Published online in J-STAGE: 10 June 2019

*Corresponding author: S Chisada

(e-mail: chisada@ks.kyorin-u.ac.jp)

©2019 The Japanese Society of Toxicologic Pathology

This is an open-access article distributed under the terms of the Creative Commons Attribution Non-Commercial No Derivatives

(by-nc-nd) License. (CC-BY-NC-ND 4.0: <https://creativecommons.org/licenses/by-nc-nd/4.0/>).



logical changes of human disease, along with other experimental animals.

Leptin is a peptide hormone secreted by adipose tissue in mammals and by the liver in fish^{18–20}. It has been shown to play a key role in the maintenance of energy homeostasis through the regulation of food intake, glucose metabolism, and a range of physiological functions^{21, 22}. Leptin- or leptin receptor-deficient rats and mice spontaneously develop hyperphagia, which leads to obesity, and they display several type II diabetes mellitus-like characteristics^{23, 24}. In the case of small fish research, Alvarez *et al.* induced thinning of the retina in zebrafish to a slight degree by immersion in glucose solution²⁵. The fish showed no significant changes in other tissues. Some researchers also used zebrafish and induced hyperglycemia by the artificial manipulation of genes. Adult fish with hyperglycemia showed pathological changes in the retina, but not in the kidneys^{26, 27}.

Previously, we succeeded in producing medaka that were homozygous for leptin receptor gene mutation [leptin receptor-deficient (LRD) medaka] by the TILLING method²⁸. Furthermore, we demonstrated that LRD medaka showed hyperglycemia and hypoinsulinemia, resulting in histopathological changes of eyeballs that were similar to the histopathologic characteristics in the ocular lesions of diabetic cataract and retinopathy in rodents^{29, 30}. The retinopathy in medaka was induced noninvasively only by increased feeding. The pathological changes were mainly caused by microvascular changes in the retina. Therefore, we presumed that our rearing method would also lead to characteristics in LRD medaka kidneys equivalent to the histopathologic ones in rodents with DN.

The purpose of the present study was to clarify the histopathologic characteristics of the lesions of LRD medaka equivalent to those in DN in humans and rodent models and to evaluate the usefulness of the LRD medaka as a model of DN. This will contribute to the development of a novel diabetic model with structural features of advanced human disease.

In the present study, CAB/KYOTO-substrain medaka (*Oryzias latipes*) were used as the wild type strain (control medaka). Medaka with a homozygous leptin receptor gene mutation (LRD medaka) were produced by the TILLING method as described previously²⁸. Fish were maintained at 25 to 26°C with a 14:10 h (light:dark) cycle in a recirculating aquaculture system equipped with carbon filtration and biofiltration. They were fed a standard feed for freshwater fish (particle size <0.25 mm and <0.36 mm, protein >50.0%, fat >10.0%, fiber <3.0%, ash <16.0%, Ca >2.00%, phosphate >1.50%; Otohime A and B1, Marubeni Nissin Feed Co., Ltd., Tokyo, Japan). The experiment was performed following the guidelines of the Animal Research Committee of Kyorin University (approval number 218 in 2018).

Fish were weighed, and their kidneys were examined histopathologically (n=6, 6, and 11 at 10, 20, and 30 weeks of age, respectively). All sampling was conducted to have an almost equal sex ratio. The sampling schedule was designed to obtain LRD medaka with normal and abnormal blood glucose levels. LRD medaka show hyperglycemia at 12–15

weeks of age and over. Fish were euthanized using 0.003% eugenol (FA100, Tanabe Seiyaku Co., Ltd., Osaka, Japan), and blood was collected from the main artery and vein. The fasting plasma glucose levels were measured using a portable glucose meter (Nipro CareFast Meter and test stripes, Nipro, Tokyo, Japan; n=6 and 6 at 20 and 30 weeks of age, respectively). The postprandial plasma insulin levels were measured by a method described previously³¹ (n=6 and 6 at 20 and 30 weeks of age, respectively). The creatinine levels in the blood were measured using a LabAssay™ Creatinine Kit (Wako Pure Chemical Industries, Ltd., Osaka, Japan; n=6 and 6 at 20 and 30 weeks of age, respectively). The fish were then fixed *in toto* in Bouin's fluid overnight before postfixation with 10% neutral buffered formalin, embedded in paraffin, cut into sagittal sections, and routinely stained with hematoxylin-eosin.

All values are expressed as means ± standard error (SE). Comparisons of differences between the control medaka and the LRD medaka were analyzed using Excel Toukei 2015 statistical software (SSRI Co., Ltd., Tokyo, Japan). The data from the two groups were analyzed using the *F*-test. When variances were homogeneous, Student's *t*-test was used. Welch's *t*-test was used when variances were not homogeneous. *P* values of <0.01 were considered significant.

The body weights of the LRD medaka were higher than those of the control medaka (Table 1). Although fasting blood glucose levels tended to be relatively high in LRD medaka at 10 weeks of age, there was no significant difference between control and LRD medaka. At 20 and 30 weeks of age, LRD medaka demonstrated hyperglycemia (Table 2). Plasma insulin levels in LRD medaka at 20 and 30 weeks of age were significantly lower than those in control medaka (Table 3). Our most recent research indicates that hypoinsulinemia in LRD medaka would be caused by changes in gene expressions involved in insulin secretion, not a decrease in the number of beta cells and/or their death by apoptosis (unpublished data). This suggested that LRD medaka developed hyperglycemia and hypoinsulinemia at 20 or more weeks of age. Plasma creatinine levels were significantly higher in LRD medaka at 20 and 30 weeks of age than in control medaka (Table 4). This suggested that, in LRD medaka, kidney function failed at 20 or more weeks of age.

No remarkable histopathological changes were observed in the kidneys of any of the six 10-week-old medaka (Fig. 1). The glomerular capillary lumina and the afferent/efferent arterioles were dilated in kidneys of two of the six 20-week-old medaka (Fig. 2). The following histopathological changes occurred in the kidneys of four of eleven 30-week-old medaka: glomerular enlargement with mesangial cell proliferation and matrix expansion (2 of 4 fish; Fig. 3a), formation of fibrin cap-like lesions (2 of 4 fish; Fig. 3a), dilation of the glomerular capillaries (Fig. 3b) and afferent/efferent arterioles (3 of 4 fish; Fig. 3a), glomerular atrophy with Bowman's capsule dilation (4 of 4 fish; Fig. 3a and b), and renal tubule dilation (4 of 4 fish; Fig. 3c). No remarkable lesions in the tubulointerstitium, which are characteristic of chronic kidney disease (CKD) and diabetic

Table 1. Body Weight

Age (weeks)	Control (mg)	Leptin receptor-deficient medaka (mg)
10	77.83 ± 4.77	128.50 ± 8.16
20	282.17 ± 14.77	411.00 ± 5.28
30	527.50 ± 43.16	654.83 ± 51.65

Values are expressed as the mean ± SE.

Table 3. Postprandial Plasma Insulin Level

Age (weeks)	Control (mg/dL)	Leptin receptor-deficient medaka (mg/dL)
20	171.33 ± 1.67	78.00 ± 4.16**
30	171.00 ± 5.51	70.00 ± 3.21**

Values are expressed as the mean ± SE. **Significantly different from the control group at $P < 0.01$ (Student's *t*-test).

Table 2. Fasting Blood Glucose Level

Age (weeks)	Control (mg/dL)	Leptin receptor-deficient medaka (mg/dL)
10	48.17 ± 3.55	62.00 ± 3.79
20	52.67 ± 2.72	129.50 ± 11.00**
30	54.33 ± 5.33	151.50 ± 7.24**

Values are expressed as the mean ± SE. **Significantly different from the control group at $P < 0.01$ (Student's *t*-test).

Table 4. Plasma Creatinine Level

Age (weeks)	Control (mg/dL)	Leptin receptor-deficient medaka (mg/dL)
20	0.93 ± 0.03	1.50 ± 0.08**
30	1.07 ± 0.03	1.67 ± 0.10**

Values are expressed as the mean ± SE. **Significantly different from the control group at $P < 0.01$ (Student's *t*-test).

kidney disease (DKD) model animals, were observed. Lesions were observed in both male and female animals, and the frequency of glomerular atrophy with Bowman's capsule dilation and renal tubule dilation was higher in male animals than in female animals.

In DN, the kidneys exhibit morphologic changes, from mild ischemic lesions to characteristic features of mesangial expansion, fibrin cap, mesangiolysis, and concomitant tubular basement membrane thickening, which are seen in the early phase of human DN, and ultimately exhibit global glomerulosclerosis with interstitial fibrosis and tubular atrophy^{32, 33}. Just before developing DN, diabetic humans are in a pathophysiologic stage, a so-called silent phase, in which glomerular filtration rates (GFRs) are increased to levels approximately 50% greater than normal, but they can return to normal³⁴. In the glomeruli, vascular tones of the afferent and efferent arterioles determine the hemodynamics and control the internal pressure of Bowman's capsule, and expansion of afferent/efferent arterioles increases the GFR³⁵. Previous research using C57BL/6J *db/db* and C57BL/KsJ *db/db* mice demonstrated that the model mice also showed an increase in GFR with hyperglycemia³⁶. Some LRD medaka at 20 or more weeks of age showed dilation of the afferent and efferent arterioles in the glomeruli. Taking into account previous reports, it was presumed that glomerular hyperfiltration occurred in LRD medaka at 20 or more weeks of age and that the afferent and efferent arterioles in the medaka may be changed due to control of the internal pressure of Bowman's capsule. Since all LRD medaka at 20 or more weeks of age showed hyperglycemia, it was thought that some medaka might be in a silent phase of DN.

In some LRD medaka at 30 weeks of age, glomerular atrophy with Bowman's capsule dilation was observed. This has been rarely described in the pathological diagnosis criteria of DN^{32, 33}. However, glomerular atrophy with Bowman's capsule dilation was reported as a characteristic lesion in an experiment using *eNOS* (*endothelial nitric oxide synthase*) gene knockout mice³⁷. It has been shown that eNOS is expressed in the renal endothelium and tubules³⁸,

and it has a role in protecting the kidney from ischemic injury^{39, 40}. In 2009, Tessari *et al.* measured the activity of nitric oxide synthesis in patients with DN and reported that the patients showed lower synthesis⁴¹. Therefore, in some LRD medaka at 30 weeks of age, the function of eNOS might be weaker, or the kidneys might have suffered ischemic injury beyond their ability to produce eNOS.

The pathological diagnosis criteria of DN include concomitant tubular basement membrane thickening with disease progression^{32, 33}. Although some LRD medaka at 30 weeks of age showed renal tubule dilation (Fig. 3) and their epithelium became atrophic (Fig. 3b and c) or disappeared (Fig. 3a and c), there was no thickening of the basement membrane in the tubules. In various renal diseases, atubular glomeruli (AG) have been described^{42, 43}. AG have open circulation but no tubular attachment and are presumably non-functioning⁴⁴. The neighboring glomerulus shows expansion of a glomerular tuft or atrophy of the glomerular tuft with Bowman's capsule expansion⁴⁵. AG were first reported in research involving patients with type 1 diabetes^{46, 47}, and then characteristic lesions of AG were also identified in patients with type 2 diabetes⁴⁵. In model mice, *eNOS* gene knockout mice showed AG with glomerular atrophy with Bowman's capsule dilation⁴⁸. Furthermore, in *db/db* mice, AG notably appeared with genetic loss of function of the *eNOS* gene^{5, 49}. Considering previous reports, it was presumed that glomeruli in some LRD medaka at 30 weeks of age would change to AG due to deterioration of *eNOS* gene function.

Albuminuria reflects widespread vascular damage and injuries to glomerular and epithelial tubular cells^{50, 51}. In AG, epithelial cells with no brush borders, which appear to be flattened cells, were observed in some cases, whereas no epithelial cells were observed in the tubules in others⁴⁷. The observed tubules also showed abnormal features with dilated and/or atrophic tubules. Similar tubular changes were observed in some LRD medaka at 30 weeks of age (Fig. 3). Although it is difficult to collect urine from medaka, a higher level of plasma creatinine in LRD medaka at 30 weeks

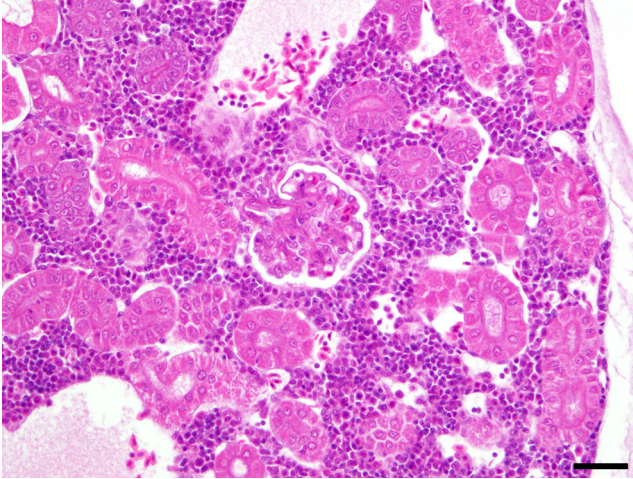


Fig. 1. Hematoxylin-eosin (HE) image of the kidney in a 10-week-old medaka. No remarkable histopathological changes are observed. Bar represents 30 μ m.

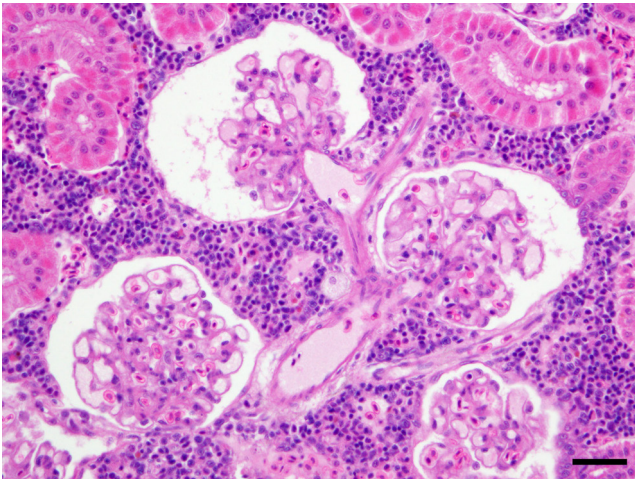


Fig. 2. Hematoxylin-eosin (HE) image of the kidney in a 20-week-old medaka. Glomerular capillary lumina and afferent/efferent arterioles are dilated. Bar represents 30 μ m.

of age (Table 4) indicated decreased renal function in the medaka. Given these data, it was possible that the fish developed albuminuria. This was suggested by the formation of fibrin cap-like lesions. In LRD medaka at 30 weeks of age, fibrin cap-like lesions were formed outside glomerular tufts (Fig. 3a). This lesion is not a specific finding in diabetic glomerulosclerosis, and similar lesions are recognized in focal glomerulosclerosis, sclerosing glomerulus, and lupus nephritis in patients. A common pathophysiologic feature in these diseases is albuminuria, and their presence correlates with the amount of albuminuria⁵². In human DN, the fibrin cap is observed at a comparatively advanced stage^{32, 33}. Therefore, this suggests that some LRD medaka at 30 weeks of age would develop albuminuria due to decreased renal function caused by chronic hyperglycemia, resulting in renal tubule dilation with/without epithelial cells.

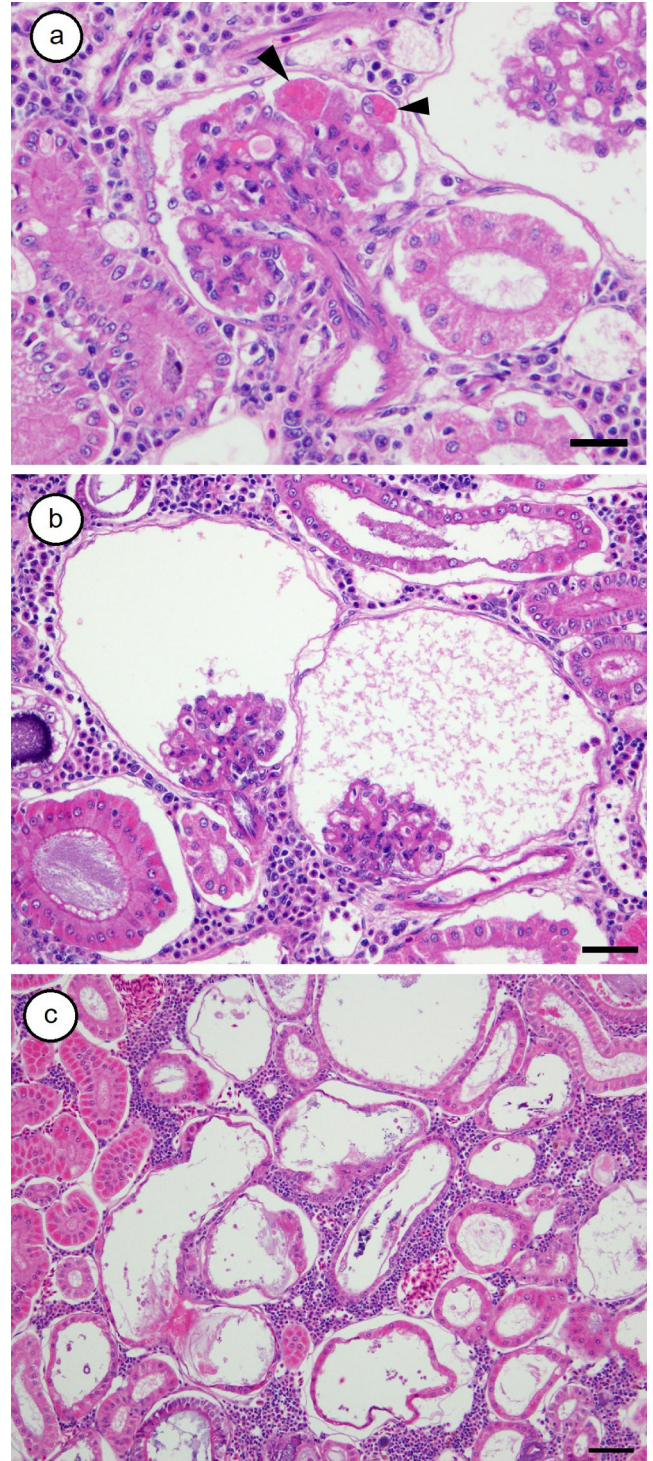


Fig. 3. Hematoxylin-eosin (HE) images of the kidney in a 30-week-old medaka. Glomerular enlargement with mesangial cell proliferation and matrix expansion and formation of fibrin cap-like lesions (arrowheads), and glomerular atrophy with Bowman's capsule dilation (a), glomerular atrophy with Bowman's capsule dilation and renal tubular dilation (b), and widespread renal tubular dilation (c). Bars represent 20 μ m (a), 30 μ m (b), or 50 μ m (c).

Dilation of glomerular capillary lumina was recognized in LRD medaka at 20 and 30 weeks of age, and glo-

merular enlargement with mesangial cell proliferation and matrix expansion was observed in LRD medaka at 30 weeks of age. These are recognized from the early phase in human DN^{32, 33}, and they are some of the most specific histological features of DN. They are also observed in many rodent models⁵. In addition, *db/db* mice showed decreased renal function and mesangial expansion, with a fibrin cap²⁴. Streptozotocin-induced animals also showed hyperglycemia and renal function degeneration, which induced mesangial expansion and hypertrophy of glomeruli with dilation of glomerular capillary lumina⁵³. Nonobese diabetic (NOD) mice also showed similar features. Studies using the NOD mouse model have supported the role of advanced glycosylation end products (AGE) in the pathogenesis of mesangial proliferation^{54–57}. Although it was presumed that dilation of glomerular capillary lumina might be caused by an increased amount of glomerular filtration, mesangial proliferation in LRD medaka at 30 weeks of age might develop because of AGE due to chronic hyperglycemia. A study using SHR (spontaneous hypertensive)/*N-cp* (*corpulent*, which is a recessive mutation in *leptin receptor* gene) rats and *cp/cp* rats demonstrated that the *cp/cp* rats showed mild glomerular changes but that the SHR/*N-cp* rats developed mesangial proliferation and albuminuria. From this study, the possibility of LRD medaka at 30 weeks of age being hypertensive could not be ruled out.

The pathological changes in DN are characterized by not only hyperglycemia and hypertension but also inflammation and infiltration of macrophages^{58, 59}. Some reports showed that it was difficult for leptin signaling-deficient animals to show an inflammatory response⁶⁰ because the leptin signaling pathway has a partial role in inflammation, infiltration of macrophages, and fibrogenic responses^{60, 61}. In LRD medaka, there is loss of function of the leptin signaling pathway with no lipid abnormality²⁸. Furthermore, the fish did not show an increased number of new blood vessels in the retina²⁹, which is assumed to occur after the inflammatory response. Thus, we have concluded that the reason that not all hyperglycemic LRD medaka showed renal lesions would be their lack of leptin signaling.

Lack of an inflammatory response regulated by leptin signaling would provide incidental advantages. The pathogenesis of human DN is complex and remains incompletely understood. One of the major reasons for this is that the progressive pathological changes are caused by various mechanisms including inflammation, glycation, receptor for advanced glycosylation end products (RAGE) activation and hypertension, as well as others⁸. Analysis of LRD medaka would contribute to a clear understanding of the development of renal lesions independent of an inflammatory response regulated by leptin signaling. Furthermore, LRD medaka are among the animals suitable for elucidating the progressive pathological changes without surgical, pharmacological, and/or genetic modification, as well as the process in humans. LRD medaka also have a different characteristic from rodents with leptin-receptor deficiency reproductive ability. The fish are fertile with normal gonadal development in both males and females, whereas rodents

with leptin-receptor deficiency exhibit delayed pubertal development and both male and female infertility²³. Therefore, it is easier to maintain the fish than the rodents. Based on the frequency of renal lesions in LRD medaka (>30%), 30 fish are needed to analyze 10 fish with renal lesions. This would be easily performed because the annual rearing cost of 1 medaka is lower than that of a rodent, and 8 fish can be reared in 1 rearing tank.

In conclusion, the following changes were mainly observed in LRD medaka at 20 and 30 weeks of age: dilation of the glomerular capillaries and afferent/efferent arterioles, glomerular enlargement, glomerular atrophy with Bowman's capsule dilation, and renal tubule dilation. The histopathological characteristics in the kidneys were microvascular changes induced by hyperglycemia that were similar to those in diabetic patients^{62–64} and rats⁶⁵. Some were characteristics that meet the pathological classification criteria^{32, 33}, and others were features of AG that have been described in various renal diseases^{42, 43}. In the present experiment, the amount of feeding was only controlled for medaka. Therefore, it was suggested that the LRD medaka model is useful for analyzing lesions that develop with aging and feeding, and this is a novel model with lesions of DN and AG.

Declaration of Conflicting Interests: The authors have no conflicts of interest to declare.

Acknowledgments: The authors would like to thank Ms. Naomi Matsunaga for her help in the rearing of medaka. They are also grateful to NBRP Medaka (<https://shigen.nig.ac.jp/medaka/>) for providing LRD medaka. Insulin measurement was supported by the NIBB Collaborative Research Program.

References

1. Satirapoj B, and Adler SG. Prevalence and management of diabetic nephropathy in Western countries. *Kidney Dis (Basel)*. 1: 61–70. 2015. [Medline] [CrossRef]
2. Aldukhayel A. Prevalence of diabetic nephropathy among Type 2 diabetic patients in some of the Arab countries. *Int J Health Sci (Qassim)*. 11: 1–4. 2017. [Medline]
3. Tomino Y, and Gohda T. The prevalence and management of diabetic nephropathy in Asia. *Kidney Dis (Basel)*. 1: 52–60. 2015. [Medline] [CrossRef]
4. Betz B, and Conway BR. Recent advances in animal models of diabetic nephropathy. *Nephron Exp Nephrol*. 126: 191–195. 2014. [Medline] [CrossRef]
5. Breyer MD, Böttinger E, Brosius FC 3rd, Coffman TM, Harris RC, Heilig CW, Sharma K. AMDCC. Mouse models of diabetic nephropathy. *J Am Soc Nephrol*. 16: 27–45. 2005. [Medline] [CrossRef]
6. Brosius FC 3rd, and Alpers CE. New targets for treatment of diabetic nephropathy: what we have learned from animal models. *Curr Opin Nephrol Hypertens*. 22: 17–25. 2013. [Medline]
7. Spitzer A. The role of the kidney in sodium homeostasis during maturation. *Kidney Int*. 21: 539–545. 1982. [Medline]

- line] [CrossRef]
8. Molitch ME, DeFronzo RA, Franz MJ, Keane WF, Mogensen CE, Parving HH, Steffes MW. American Diabetes Association. Nephropathy in diabetes. *Diabetes Care*. **27**(Suppl 1): S79–S83. 2004. [Medline] [CrossRef]
 9. Van Buren PN, and Toto R. Hypertension in diabetic nephropathy: epidemiology, mechanisms, and management. *Adv Chronic Kidney Dis*. **18**: 28–41. 2011. [Medline] [CrossRef]
 10. Michaelis OEH IV, and Hansen CT. The spontaneous hypertensive/NIH-corpulent rat: a new rodent model for the study of non-insulin-dependent diabetes mellitus and its complications. *ILAR J*. **32**: 19–22. 1990. [CrossRef]
 11. Russell JCS, Shillabeer G, Bar-Tana J, Lau DC, Richardson M, Wenzel LM, Graham SE, and Dolphin PJ. Development of insulin resistance in the JCR:LA-cp rat: role of triacylglycerols and effects of MEDICA 16. *Diabetes*. **47**: 770–778. 1998. [Medline] [CrossRef]
 12. Conway BR, Rennie J, Bailey MA, Dunbar DR, Manning JR, Bellamy CO, Hughes J, and Mullins JJ. Hyperglycemia and renin-dependent hypertension synergize to model diabetic nephropathy. *J Am Soc Nephrol*. **23**: 405–411. 2012. [Medline] [CrossRef]
 13. Watanabe N, Kato M, Suzuki N, Inoue C, Fedorova S, Hashimoto H, Maruyama S, Matsuo S, and Wakamatsu Y. Kidney regeneration through nephron neogenesis in medaka. *Dev Growth Differ*. **51**: 135–143. 2009. [Medline] [CrossRef]
 14. Taniguchi Y, Takeda S, Furutani-Seiki M, Kamei Y, Todo T, Sasado T, Deguchi T, Kondoh H, Mudde J, Yamazoe M, Hidaka M, Mitani H, Toyoda A, Sakaki Y, Plasterk RH, and Cuppen E. Generation of medaka gene knockout models by target-selected mutagenesis. *Genome Biol*. **7**: R116. 2006. [Medline] [CrossRef]
 15. Ansai S, Sakuma T, Yamamoto T, Ariga H, Uemura N, Takahashi R, and Kinoshita M. Efficient targeted mutagenesis in medaka using custom-designed transcription activator-like effector nucleases. *Genetics*. **193**: 739–749. 2013. [Medline] [CrossRef]
 16. Ansai S, and Kinoshita M. Targeted mutagenesis using CRISPR/Cas system in medaka. *Biol Open*. **3**: 362–371. 2014. [Medline] [CrossRef]
 17. Kinoshita M, Murata K, Naruse K, and Tanaka M. *Medaka: biology, management, and experimental protocols*. Wiley-Blackwell, Ames. 2009.
 18. MacDougald OA, Hwang CS, Fan H, and Lane MD. Regulated expression of the obese gene product (leptin) in white adipose tissue and 3T3-L1 adipocytes. *Proc Natl Acad Sci USA*. **92**: 9034–9037. 1995. [Medline] [CrossRef]
 19. Zhang Y, Proenca R, Maffei M, Barone M, Leopold L, and Friedman JM. Positional cloning of the mouse obese gene and its human homologue. *Nature*. **372**: 425–432. 1994. [Medline] [CrossRef]
 20. Halaas JL, Boozer C, Blair-West J, Fidahusein N, Denton DA, and Friedman JM. Physiological response to long-term peripheral and central leptin infusion in lean and obese mice. *Proc Natl Acad Sci USA*. **94**: 8878–8883. 1997. [Medline] [CrossRef]
 21. Banks WA, Coon AB, Robinson SM, Moinuddin A, Shultz JM, Nakaoka R, and Morley JE. Triglycerides induce leptin resistance at the blood-brain barrier. *Diabetes*. **53**: 1253–1260. 2004. [Medline] [CrossRef]
 22. Pellemounter MA, Cullen MJ, Baker MB, Hecht R, Winters D, Boone T, and Collins F. Effects of the obese gene product on body weight regulation in ob/ob mice. *Science*. **269**: 540–543. 1995. [Medline] [CrossRef]
 23. Coleman DL. Obese and diabetes: two mutant genes causing diabetes-obesity syndromes in mice. *Diabetologia*. **14**: 141–148. 1978. [Medline] [CrossRef]
 24. Wang B, Chandrasekera PC, and Pippin JJ. Leptin- and leptin receptor-deficient rodent models: relevance for human type 2 diabetes. *Curr Diabetes Rev*. **10**: 131–145. 2014. [Medline] [CrossRef]
 25. Alvarez Y, Chen K, Reynolds AL, Waghorne N, O'Connor JJ, and Kennedy BN. Predominant cone photoreceptor dysfunction in a hyperglycaemic model of non-proliferative diabetic retinopathy. *Dis Model Mech*. **3**: 236–245. 2010. [Medline] [CrossRef]
 26. Gleeson M, Connaughton V, and Arneson LS. Induction of hyperglycaemia in zebrafish (*Danio rerio*) leads to morphological changes in the retina. *Acta Diabetol*. **44**: 157–163. 2007. [Medline] [CrossRef]
 27. Heckler K, and Kroll J. Zebrafish as a model for the study of microvascular complications of diabetes and their mechanisms. *Int J Mol Sci*. **18**: 2002. 2017. [Medline] [CrossRef]
 28. Chisada SI, Kurokawa T, Murashita K, Ronnestad I, Taniguchi Y, Toyoda A, Sakaki Y, Takeda S, and Yoshiura Y. Leptin receptor-deficient (knockout) medaka, *Oryzias latipes*, show chronic up-regulated levels of orexigenic neuropeptides, elevated food intake and stage specific effects on growth and fat allocation. *Gen Comp Endocrinol*. **195**: 9–20. 2013. [Medline]
 29. Chisada SI, Hirako A, and Sugiyama A. Ocular lesions in leptin receptor-deficient medaka (*Oryzias latipes*). *J Toxicol Pathol*. **31**: 65–72. 2018. [Medline] [CrossRef]
 30. Shoda T, Shinohara M, Takahashi T, Miyajima K, Kakehashi A, and Miyakawa Y. Histopathological features of diabetic ocular complications in the spontaneously diabetic torii rat. *J Toxicol Pathol*. **20**: 179–183. 2007. [CrossRef]
 31. Andoh T, and Nagasawa H. Development of a time-resolved fluoroimmunoassay for insulins and its application to monitoring of insulin secretion induced by feeding in the barfin flounder, *Verasper moseri*. *Gen Comp Endocrinol*. **125**: 365–374. 2002. [Medline] [CrossRef]
 32. Tervaert TW, Mooyaart AL, Amann K, Cohen AH, Cook HT, Drachenberg CB, Ferrario F, Fogo AB, Haas M, de Heer E, Joh K, Noël LH, Radhakrishnan J, Seshan SV, Bajema IM, Bruijn JA. Renal Pathology Society. Pathologic classification of diabetic nephropathy. *J Am Soc Nephrol*. **21**: 556–563. 2010. [Medline] [CrossRef]
 33. Haneda M, Utsunomiya K, Koya D, Babazono T, Moriya T, Makino H, Kimura K, Suzuki Y, Wada T, Ogawa S, Inaba M, Kanno Y, Shigematsu T, Masakane I, Tsuchiya K, Honda K, Ichikawa K, Shide K. Joint Committee on Diabetic Nephropathy. A new classification of diabetic nephropathy 2014: a report from Joint Committee on Diabetic Nephropathy. *J Diabetes Investig*. **6**: 242–246. 2015. [Medline] [CrossRef]
 34. Stockand JDS, and Sansom SC. Regulation of filtration rate by glomerular mesangial cells in health and diabetic renal disease. *Am J Kidney Dis*. **29**: 971–981. 1997. [Medline] [CrossRef]
 35. Ito S, and Abe K. Contractile properties of afferent and efferent arterioles. *Clin Exp Pharmacol Physiol*. **24**: 532–535.

1997. [\[Medline\]](#) [\[CrossRef\]](#)
36. Gärtner K. Glomerular hyperfiltration during the onset of diabetes mellitus in two strains of diabetic mice (c57bl/6j db/db and c57bl/ksj db/db). *Diabetologia*. **15**: 59–63. 1978. [\[Medline\]](#) [\[CrossRef\]](#)
 37. Forbes MS, Thornhill BA, Park MH, and Chevalier RL. Lack of endothelial nitric-oxide synthase leads to progressive focal renal injury. *Am J Pathol*. **170**: 87–99. 2007. [\[Medline\]](#) [\[CrossRef\]](#)
 38. Han KH, Lim JM, Kim WY, Kim H, Madsen KM, and Kim J. Expression of endothelial nitric oxide synthase in developing rat kidney. *Am J Physiol Renal Physiol*. **288**: F694–F702. 2005. [\[Medline\]](#) [\[CrossRef\]](#)
 39. Kashiwagi M, Shinozaki M, Hirakata H, Tamaki K, Hirano T, Tokumoto M, Goto H, Okuda S, and Fujishima M. Locally activated renin-angiotensin system associated with TGF- β 1 as a major factor for renal injury induced by chronic inhibition of nitric oxide synthase in rats. *J Am Soc Nephrol*. **11**: 616–624. 2000. [\[Medline\]](#)
 40. Yamashita J, Ogata M, Itoh M, Yamasowa H, Shimeda Y, Takaoka M, and Matsumura Y. Role of nitric oxide in the renal protective effects of ischemic preconditioning. *J Cardiovasc Pharmacol*. **42**: 419–427. 2003. [\[Medline\]](#) [\[CrossRef\]](#)
 41. Tessari P, Cecchet D, Cosma A, Vettore M, Coracina A, Million R, Iori E, Puricelli L, Avogaro A, and Vedovato M. Nitric oxide synthesis is reduced in subjects with type 2 diabetes and nephropathy. *Diabetes*. **59**: 2152–2159. 2010. [\[Medline\]](#) [\[CrossRef\]](#)
 42. Marcussen N. Atubular glomeruli and the structural basis for chronic renal failure. *Lab Invest*. **66**: 265–284. 1992. [\[Medline\]](#)
 43. Marcussen N. Atubular glomeruli in chronic renal disease. *Curr Top Pathol*. **88**: 145–174. 1995. [\[Medline\]](#) [\[CrossRef\]](#)
 44. Marcussen N. Tubulointerstitial damage leads to atubular glomeruli: significance and possible role in progression. *Nephrol Dial Transplant*. **15**(Suppl 6): 74–75. 2000. [\[Medline\]](#) [\[CrossRef\]](#)
 45. White KE, Marshall SM, and Bilous RW. Prevalence of atubular glomeruli in type 2 diabetic patients with nephropathy. *Nephrol Dial Transplant*. **23**: 3539–3545. 2008. [\[Medline\]](#) [\[CrossRef\]](#)
 46. Najafian B, Crosson JT, Kim Y, and Mauer M. Glomerulotubular junction abnormalities are associated with proteinuria in type 1 diabetes. *J Am Soc Nephrol*. **17**(Suppl 2): S53–S60. 2006. [\[Medline\]](#) [\[CrossRef\]](#)
 47. Najafian B, Kim Y, Crosson JT, and Mauer M. Atubular glomeruli and glomerulotubular junction abnormalities in diabetic nephropathy. *J Am Soc Nephrol*. **14**: 908–917. 2003. [\[Medline\]](#) [\[CrossRef\]](#)
 48. Nakagawa T, Sato W, Glushakova O, Heinig M, Clarke T, Campbell-Thompson M, Yuzawa Y, Atkinson MA, Johnson RJ, and Croker B. Diabetic endothelial nitric oxide synthase knockout mice develop advanced diabetic nephropathy. *J Am Soc Nephrol*. **18**: 539–550. 2007. [\[Medline\]](#) [\[CrossRef\]](#)
 49. Zhao HJ, Wang S, Cheng H, Zhang MZ, Takahashi T, Fogo AB, Breyer MD, and Harris RC. Endothelial nitric oxide synthase deficiency produces accelerated nephropathy in diabetic mice. *J Am Soc Nephrol*. **17**: 2664–2669. 2006. [\[Medline\]](#) [\[CrossRef\]](#)
 50. Deckert T, Feldt-Rasmussen B, Borch-Johnsen K, Jensen T, and Kofoed-Enevoldsen A. Albuminuria reflects wide-spread vascular damage. The Steno hypothesis. *Diabetologia*. **32**: 219–226. 1989. [\[Medline\]](#) [\[CrossRef\]](#)
 51. Fang L, Xie D, Wu X, Cao H, Su W, and Yang J. Involvement of endoplasmic reticulum stress in albuminuria induced inflammasome activation in renal proximal tubular cells. *PLoS One*. **8**: e72344. 2013. [\[Medline\]](#) [\[CrossRef\]](#)
 52. Laufer A, and Stein O. The exudative lesion in diabetic glomerulosclerosis. *Am J Clin Pathol*. **32**: 56–61. 1959. [\[Medline\]](#) [\[CrossRef\]](#)
 53. Susztak K, Böttinger E, Novitsky A, Liang D, Zhu Y, Ciccone E, Wu D, Dunn S, McCue P, and Sharma K. Molecular profiling of diabetic mouse kidney reveals novel genes linked to glomerular disease. *Diabetes*. **53**: 784–794. 2004. [\[Medline\]](#) [\[CrossRef\]](#)
 54. He CJ, Zheng F, Stitt A, Striker L, Hattori M, and Vlassara H. Differential expression of renal AGE-receptor genes in NOD mice: possible role in nonobese diabetic renal disease. *Kidney Int*. **58**: 1931–1940. 2000. [\[Medline\]](#) [\[CrossRef\]](#)
 55. Schreyer SAW, Wilson DL, and LeBoeuf RC. C57BL/6 mice fed high fat diets as models for diabetes-accelerated atherosclerosis. *Atherosclerosis*. **136**: 17–24. 1998. [\[Medline\]](#) [\[CrossRef\]](#)
 56. Sharma K, and Ziyadeh FN. Renal hypertrophy is associated with upregulation of TGF- β 1 gene expression in diabetic BB rat and NOD mouse. *Am J Physiol*. **267**: F1094–F01. 1994. [\[Medline\]](#)
 57. Pankewycz OG, Guan J-X, Bolton WK, Gomez A, and Benedict JF. Renal TGF- β regulation in spontaneously diabetic NOD mice with correlations in mesangial cells. *Kidney Int*. **46**: 748–758. 1994. [\[Medline\]](#) [\[CrossRef\]](#)
 58. Ina K, Kitamura H, Okeda T, Nagai K, Liu ZY, Matsuda M, and Fujikura Y. Vascular cell adhesion molecule-1 expression in the renal interstitium of diabetic KKAY mice. *Diabetes Res Clin Pract*. **44**: 1–8. 1999. [\[Medline\]](#) [\[CrossRef\]](#)
 59. Nakamura A, Shikata K, Hiramatsu M, Nakatou T, Kitamura T, Wada J, Itoshima T, and Makino H. Serum interleukin-18 levels are associated with nephropathy and atherosclerosis in Japanese patients with type 2 diabetes. *Diabetes Care*. **28**: 2890–2895. 2005. [\[Medline\]](#) [\[CrossRef\]](#)
 60. Ma KL, Zhang Y, Liu J, Wu Y, Hu ZB, Ruan XZ, and Liu BC. Establishment of an inflamed animal model of diabetic nephropathy. *Int J Biol Sci*. **10**: 149–159. 2014. [\[Medline\]](#) [\[CrossRef\]](#)
 61. Honda H, Ikejima K, Hirose M, Yoshikawa M, Lang T, Enomoto N, Kitamura T, Takei Y, and Sato N. Leptin is required for fibrogenic responses induced by thioacetamide in the murine liver. *Hepatology*. **36**: 12–21. 2002. [\[Medline\]](#) [\[CrossRef\]](#)
 62. Lee PS, and Poh KK. Endothelial progenitor cells in cardiovascular diseases. *World J Stem Cells*. **6**: 355–366. 2014. [\[Medline\]](#) [\[CrossRef\]](#)
 63. Yiu KH, and Tse HF. Specific role of impaired glucose metabolism and diabetes mellitus in endothelial progenitor cell characteristics and function. *Arterioscler Thromb Vasc Biol*. **34**: 1136–1143. 2014. [\[Medline\]](#) [\[CrossRef\]](#)
 64. Altabas V. Diabetes, endothelial dysfunction, and vascular repair: what should a diabetologist keep his eye on? *Int J Endocrinol*. **2015**: 848272. 2015. [\[Medline\]](#) [\[CrossRef\]](#)
 65. Wang Y-X, Brooks DP, and Edwards RM. Attenuated glomerular cGMP production and renal vasodilation in streptozotocin-induced diabetic rats. *Am J Physiol*. **264**: R952–R956. 1993. [\[Medline\]](#)