



Case report

Drainage and analysis of suprachoroidal fluid in a patient with acute systemic lupus erythematosus



James A. Stefater, Dean Elliott, Leo A. Kim*

Retina Service, Department of Ophthalmology, Massachusetts Eye and Ear Infirmary, Harvard Medical School, Boston, MA, USA

ARTICLE INFO

Article history:

Received 31 May 2016

Received in revised form

5 October 2016

Accepted 9 November 2016

Available online 14 November 2016

Keywords:

Choroidal effusion

Lupus choroidopathy

Light's criteria

Exudative

Transudative

ABSTRACT

Purpose: To describe a case of a patient with acute systemic lupus erythematosus (SLE) causing choroidal effusions and to report a novel technique for evaluation of the choroidal fluid which sheds light on effusion pathogenesis.

Observations: A 37 year-old woman was referred for decreased vision, eye pain and shortness of breath. The patient had bilateral angle closure glaucoma from choroidal effusions and bilateral pleural effusions. Work-up revealed new onset acute SLE. A technique for obtaining suprachoroidal fluid is described, and the fluid was analyzed using Light's criteria and found to be exudative in nature.

Conclusions and importance: There has been speculation as to pathogenesis of choroidal effusions in a variety of conditions, and many authors believe the most likely process to be transudative. The exudative nature of the fluid in our patient suggests that choroidal effusions in acute SLE are likely caused by inflammation, and not secondary to hypoalbuminemia or another transudative process. Similar analyses of suprachoroidal fluid in other disease processes may help elucidate the underlying pathogenesis and may possibly guide treatment.

© 2016 The Authors. Published by Elsevier Inc. This is an open access article under the CC BY-NC-ND license (<http://creativecommons.org/licenses/by-nc-nd/4.0/>).

1. Introduction

Choroidal effusions are associated with several systemic conditions including systemic lupus erythematosus (SLE),^{1–3} leukemia,⁴ lymphoma,⁵ IgA nephropathy,⁶ HIV,⁷ and idiopathic pulmonary arterial hypertension.⁸ The presence of choroidal effusions is a major cause of ocular morbidity and the precise mechanisms by which they develop remain unknown. In general, choroidal effusions occur when fluid collects in the potential space between the choroid and the sclera, either by transudative or exudative forces. Transudative causes include hemodynamic (due to hypotony) and oncotic (due to hypoalbuminemia/hypoproteinemia) processes, while exudative causes include inflammatory and neoplastic processes (due to increased vascular permeability). In the case presented here, we analyze suprachoroidal fluid from a patient with acute SLE using Light's criteria to help determine the etiology of fluid collection.⁹

2. Case report

A 37 year-old African-American woman with no past medical history presented to an outside ophthalmologist with 8 days of blurry vision, pain in both eyes and 2 days of shortness of breath. She was diagnosed with bilateral acute angle closure glaucoma and underwent laser peripheral iridotomy to the left eye. Several days later, the patient was admitted to the hospital for worsening shortness of breath. The patient's ocular and systemic condition continued to worsen prompting transfer of care to our institution. The patient did not report using any medications. Review of systems was notable for a 30 pound weight gain over the past 3 weeks.

Examination revealed visual acuity of 20/400 OU, elevated intraocular pressure (39 mm Hg OD, 38 mm Hg OS), injected conjunctival blood vessels (Fig. 1A), and narrow anterior chamber angles (Fig. 1B) OU. There was a small patent iridotomy OS. 360-degree choroidal effusions were present in both eyes (Fig. 2). Physical examination revealed decreased breath sounds in both bases and 3+ pitting edema in both legs (Fig. 3A).

Chest X-ray (Fig. 3B) and subsequent chest CT revealed large pleural effusions, and urinalysis was remarkable for 3+ protein. Given the patient's age, gender, ethnicity and ocular and systemic findings, the diagnosis of SLE was strongly considered. A

* Corresponding author. Massachusetts Eye and Ear Infirmary, Harvard Medical School, 243 Charles Street, Boston, MA 02114, USA.

E-mail address: Leo_Kim@meei.harvard.edu (L.A. Kim).

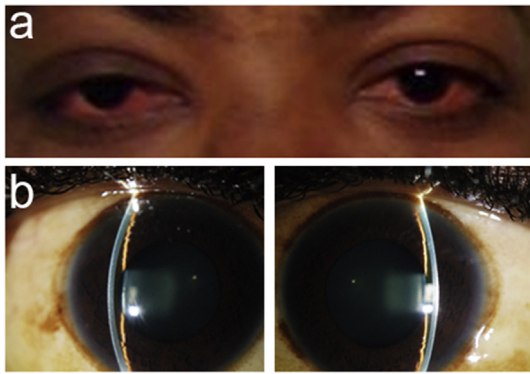


Fig. 1. Exam findings from the patient at presentation. (a) mild periorbital edema with bilateral conjunctival injection and (b) narrow anterior chamber angles as demonstrated with the slit-beam.

thoracentesis was performed, and the fluid was analyzed using Light's criteria (protein and LDH).⁹ It was consistent with an exudative process. In addition, laboratory workup revealed positive blood tests for anti-nuclear antibody, anti-Smith antibody, and double-stranded DNA antibody. The patient was diagnosed with acute SLE with pulmonary and ocular involvement.

Meanwhile, despite aggressive medical therapy which included maximal pressure lowering drops, cycloplegia, high dose prednisone and cyclophosphamide, the patient's vision remained poor, intraocular pressures remained markedly elevated, and the

choroidal effusions enlarged (Fig. 4). Of note, the patient was unable to tolerate oral acetazolamide given her coincident renal failure. Given the patient's worsening state, the choroidal effusions were drained. A partial-thickness scleral window with a posterior flap was made (Fig. 5A). A slit and then a small full-thickness scleral hole was made within the window and the suprachoroidal fluid was allowed to slowly percolate onto the everted flap (Fig. 5B). As the fluid slowly accumulated, it was aspirated from the surface of the flap with a 30 gauge needle attached to a tuberculin syringe and sent for analysis. The suprachoroidal fluid from both eyes was similar in composition, and using Light's criteria, it was exudative (Table 1).

Two weeks after initiation of therapy, the patient had resolution of respiratory function and peripheral edema. At 2 months post-operatively, visual acuity was 20/20 OU, with resolution of all abnormal ocular findings.

3. Discussion

In this case, choroidal effusions with secondary angle closure glaucoma were the presenting manifestations of acute SLE. While choroidal effusions are known to occur occasionally in SLE,¹ little is known about the mechanisms that facilitate fluid accumulation in the suprachoroidal space. In an attempt to understand this process, several authors have analyzed suprachoroidal fluid in other contexts. In idiopathic chorioretinal effusions, Wilson et al. found high protein level in the subretinal fluid but normal protein in the suprachoroidal fluid.¹⁰ In contrast, in uveal effusion syndrome,

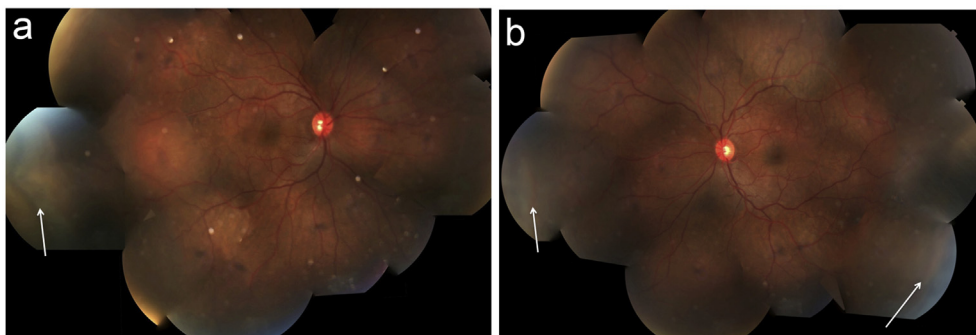


Fig. 2. Fundus photography showing 360-degree choroidal effusions with visible ora (arrows) in the right eye (a) and left eye (b).

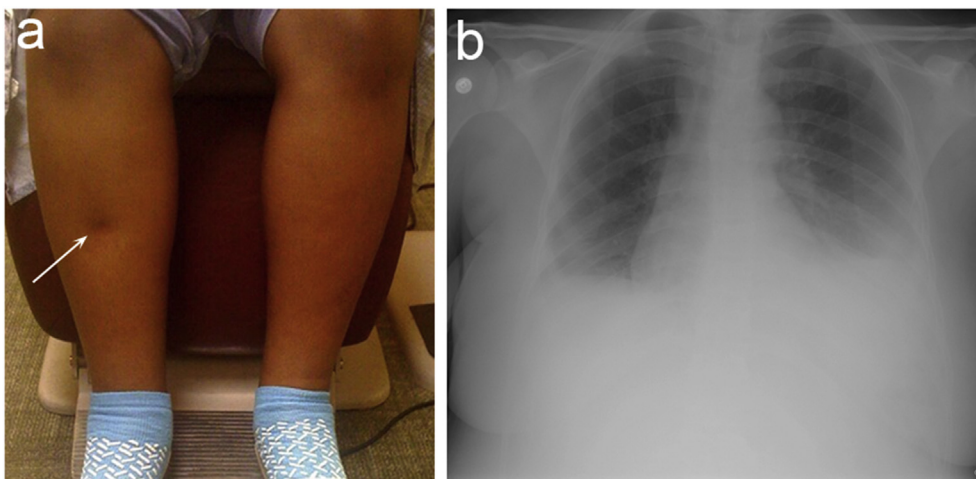


Fig. 3. (a) Bilateral lower leg pitting edema (arrow) and (b) chest X-ray showing bilateral pleural effusions.

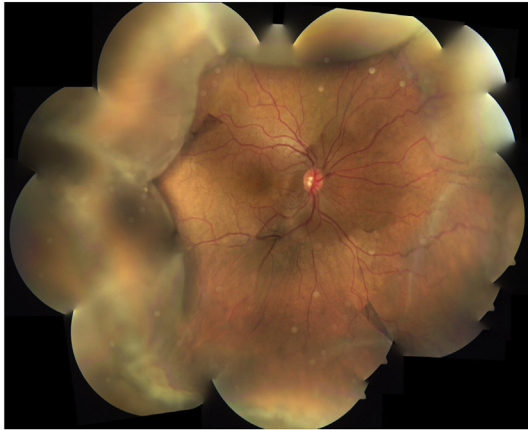


Fig. 4. Fundus photography showing posterior progression of the choroidal effusions in the right eye.

Jackson et al. found high protein concentration in the suprachoroidal fluid.¹¹

In the work here, suprachoroidal fluid was meticulously collected from both eyes of a patient with acute SLE and analyzed using Light's criteria. The criteria were originally developed to help internists distinguish transudative from exudative pleural effusions.⁸ The same criteria have been applied to abnormal fluid collections obtained from other areas of the body, including ascites. By comparing fluid protein and LDH concentrations with serum values, one can ascertain the nature of the fluid accumulation. The fluid is considered exudative if at least one of the following criteria is met: the fluid-to-serum protein ratio is greater than 0.5, the fluid-to-serum LDH ratio is greater than 0.6, or the fluid LDH level is at least 2/3 the serum LDH upper-limit-of-normal.⁸ In the case of our patient's pleural fluid, one criterion was satisfied consistent

with an exudative pleural effusion. The choroidal fluid from both eyes was frankly exudative, satisfying all three criteria (Table 1).

These results shed light on the pathogenesis of choroidal effusions in the context of our patient's acute systemic condition. She was frankly hypoalbuminemic secondary to her protein-losing nephropathy, which would suggest a possible transudative etiology for her choroidal effusions. The hypoalbuminemia is the accepted cause of the patient's profound pitting edema; however, patients with low serum protein from other causes do not typically develop choroidal effusions. Based on the nature of the suprachoroidal fluid analysis presented here, we suggest the choroidal effusions in acute SLE are most likely related to localized inflammation of the choroid, and it is possible that fluid accumulation may be more likely in the setting of low serum protein. The etiology of the nephropathy is thought to be related to immune complex deposition with localized inflammation and glomerular dysfunction. It is therefore possible that the choroid is a primary target of immune complex deposition and not simply responding to the low oncotic pressure.

4. Conclusions

The case reported here and the use of Light's criteria to assess the suprachoroidal fluid suggest that choroidal effusions in SLE are exudative in nature. We suggest that choroidal effusion fluid be sent for Light's criteria from a wide range of disease processes. Analysis will shed light on the etiology of many choroidal effusive diseases and help guide development of future non-surgical management.

Patient consent

The patient provided oral consent for publication of personal identifying information including medical record details and photographs.

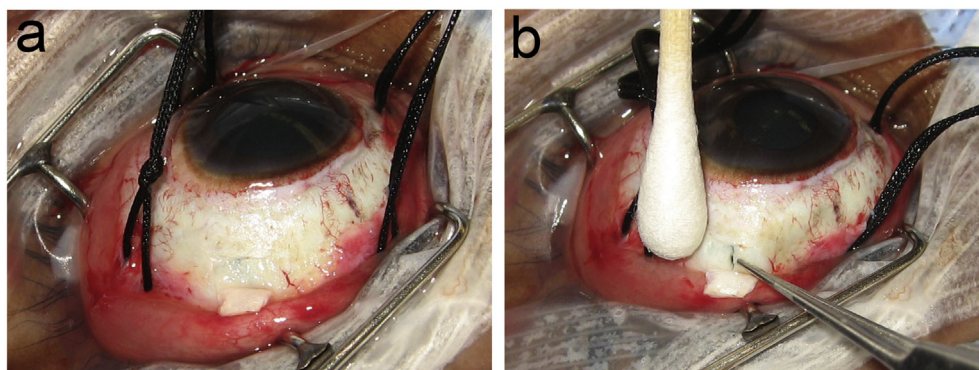


Fig. 5. Surgical drainage of the choroidal effusion from the left eye. (a) Isolation of the extraocular muscles with silk suture and creation of a partial thickness scleral flap, and (b) after creating a small slit, and a tiny hole within the slit, suprachoroidal fluid was allowed to percolate onto the flap which was collected incrementally with a tuberculin syringe.

Table 1

Components of Light's criteria in serum, pleural fluid, and suprachoroidal fluid of both eyes.

	Serum	Pleural fluid	Choroidal fluid OD	Choroidal fluid OS	Criteria for exudative effusions (at least 1 of 3)
Protein (g/dL)	5.4	2.9	3.4	3.4	
LDH (U/L)	235	60	187	154	
Fluid to serum protein ratio		*0.54	*0.63	*0.63	>0.5
Fluid to serum LDH ratio		0.26	*0.80	*0.66	>0.6
Fluid LDH/LDH upper-limit-of-normal		0.27	*0.84	*0.69	>0.67

Ratios consistent with exudative fluids are marked with an asterisk (note that only one of the three criteria must be met for a fluid to be considered exudative). The upper limit of normal for LDH was 222 U/L.

Funding

L.A.K. was supported by the NEI/NIH grant K12-EY16335.

Conflict of interest

The authors have no financial disclosures.

Authorship

All authors attest that they meet the current ICMJE criteria for Authorship.

Author's contributions

JAS, DE and LAK researched and wrote the manuscript; DE and LAK made the diagnosis, performed the surgery, and managed the treatment.

Acknowledgements

None.

References

1. Wisotsky BJ, Magat-Gordon CB, Puklin JE. Angle-closure glaucoma as an initial presentation of systemic lupus erythematosus. *Ophthalmology*. 1998;105:1170–1172.
2. Han YS, Min Yang C, Lee SH, Shin JH, Moon SW, Kang JH. Secondary angle closure glaucoma by lupus choroidopathy as an initial presentation of systemic lupus erythematosus: a case report. *BMC Ophthalmol*. 2015;15:148.
3. Lavina AM, Agarwal A, Hunyor A, Gass JD. Lupus choroidopathy and choroidal effusions. *Retina*. 2002;22:643–647.
4. Patel AV, Miller JB, Nath R, et al. Unilateral eye findings: a rare herald of acute leukemia. *Ocul Oncol Pathol*. 2016;2:166–170.
5. Cristol SM, Baumbatt JG, Icasiano E, Grajewski AL, Olivier MM, Parrish RK. Bilateral acute angle-closure associated with systemic lymphoma: a report of 2 cases. *J Glaucoma*. 2011;20:115–117.
6. Pavlin CJ, Easterbrook M, Harasiewicz K, Foster FS. An ultrasound bio-microscopic analysis of angle-closure glaucoma secondary to ciliochoroidal effusion in IgA nephropathy. *Am J Ophthalmol*. 1993;116:341–345.
7. Nash RW, Lindquist TD. Bilateral angle-closure glaucoma associated with uveal effusion: presenting sign of HIV infection. *Surv Ophthalmol*. 1992;36:255–258.
8. Akduman L, Del Priore LV, Kaplan HJ, Meredith T. Uveal effusion syndrome associated with primary pulmonary hypertension and vomiting. *Am J Ophthalmol*. 1996;121:578–580.
9. Light RW, Macgregor MI, Luchsinger PC, Ball WC. Pleural effusions: the diagnostic separation of transudates and exudates. *Ann Intern Med*. 1972;77:507–513.
10. Wilson RS, Hanna C, Morris MD. Idiopathic chorioretinal effusion: an analysis of extracellular fluids. *Ann Ophthalmol*. 1977;9:647–653.
11. Jackson TL, Hussain A, Salisbury J, Sherwood R, Sullivan PM, Marshall J. Transscleral albumin diffusion and suprachoroidal albumin concentration in uveal effusion syndrome. *Retina*. 2012;32:177–182.