



Case report

Persistent median artery in carpal tunnel syndrome for a patient with end stage renal disease after thrombosis of the left radiocephalic AV forearm graft: A case report



Abdulaziz S. AlModumeegh^{a,*}, Nouf A. AlOtaibi^b, Abduljabbar A. AlYamani^b,
Abdulelah A. AlDossari^b, Ali S. AlAmmari^b, Mohammed M. AlQattan^c

^a Plastic Surgery Department, Medical College Al-Imam Muhammad Ibn Saud Islamic University, Riyadh, Saudi Arabia

^b College of Medicine, King Saud University, Riyadh, Saudi Arabia

^c Division of Plastic Surgery and Hand Surgery, Department of Surgery, King Saud University, Riyadh, Saudi Arabia

ARTICLE INFO

Keywords:

Carpal tunnel syndrome
End stage renal disease
Arteriovenous loop graft
Hemodialysis
Superficial persistent median artery
Case report

ABSTRACT

Introduction & importance: Carpal tunnel syndrome (CTS) is the most common neuropathy in the world and is caused by compression of the median nerve. It has many known risk factors, including hemodialysis and a persistent median artery (PMA), which can be an incidental finding during carpal tunnel release (CTR).

Case presentation: A 65-year-old woman with end-stage renal disease (ESRD) on dialysis for seven months presented with typical signs and symptoms of carpal tunnel syndrome. Nerve conduction studies (NCS) displayed severe neuropathy. Upon carpal tunnel release (CTR) a rare superficial non-calcified persistent median artery critical to the circulation of the hand was found. The patient's symptoms resolved completely within four weeks of the operation.

Clinical discussion: The PMA is a relatively common anomaly and could cause carpal tunnel syndrome by: directly pressing the median nerve, thrombosing, or in the setting of an aneurysm. Although usually found deep to the flexor retinaculum, the PMA could also be found superficially. It can be critical to the blood supply of the hand and should therefore be dealt with carefully.

Conclusion: Surgeons should be aware of the possibility of finding a PMA when performing CTR. The PMA could be deep or superficial to the transverse carpal ligament. Where possible, the PMA should be preserved. Especially if its contributions to the blood supply of the hand are undetermined.

1. Introduction

Carpal tunnel syndrome (CTS) is caused by compression of the median nerve at the wrist joint. CTS is considered the most common mononeuropathy in the world [1] which affects approximately 5% of the population [2]. Although often idiopathic, there are many known risk factors including diabetes, hypothyroidism, and dialysis related amyloidosis. End stage renal disease (ESRD) and hemodialysis can cause CTS due to B2-microglobulin deposition. It can also be due to venous hypertension in the limb with the arteriovenous fistula (AVF) [3]. The prevalence among patients on hemodialysis was found to be as high as 31% [4]. The usual incidence of CTS is notable after 10 years of dialysis [5].

The hand is typically supplied by the ulnar and radial arteries.

However, in few anomalous cases the median artery fails to regress during fetal development. Therefore, such individuals have a viable median artery. The prevalence of persistent median artery (PMA) was found to be approximately 3% [6]. Although ultrasound can be used for the diagnosis of CTS, it is not a standard of care preoperatively in open carpal tunnel release (CTR) to detect the PMA [7].

This case report presents a 65-year-old woman with ESRD that developed CTS 7 months after starting hemodialysis on the ipsilateral side of the arterio-venous fistula and was found to have a PMA upon CTR. This case report has been reported in line with the SCARE Criteria [8].

* Corresponding author at: 8140 Abi Naim AlHaddad, Riyadh 13214-3174, Saudi Arabia.

E-mail address: AAlmodumeegh@imamu.edu.sa (A.S. AlModumeegh).

<https://doi.org/10.1016/j.ijscr.2021.106439>

Received 15 August 2021; Received in revised form 19 September 2021; Accepted 19 September 2021

Available online 21 September 2021

2210-2612/© 2021 The Authors. Published by Elsevier Ltd on behalf of IJS Publishing Group Ltd. This is an open access article under the CC BY-NC-ND license

(<http://creativecommons.org/licenses/by-nc-nd/4.0/>).

2. Case presentation

A 65-year-old woman was referred to the Plastic and Reconstructive Surgery outpatient clinic at King Khalid University Hospital due to gradual and progressive pain and numbness in the median nerve distribution of the left hand for three months. These symptoms were worse at night and were relieved by shaking her hand. On clinical examination, wasting in the thenar muscles of the left hand was found. She exhibited reduced sensation in the median nerve distribution of the left hand.

Tinel's sign and Phalen's test were positive on the left side. Motor function was preserved. Ulnar artery was palpable. Radial artery was not palpable as it was previously ligated. Allen test was performed to assess the integrity of the vascular anastomoses; the patient was found to have a complete palmar arch with ulnar domination.

Her medical history consisted of multiple medical conditions including type two diabetes, dyslipidemia, hypertension, morbid obesity, and ESRD. Her chronic kidney disease (CKD) was caused by recurrent renal stones six years ago. Her CKD progressed to ESRD seven months prior to her presentation to us, and hemodialysis was performed through a left radiocephalic arteriovenous (AV) fistula. Her graft malfunctioned due to acute thrombosis of the AV fistula three times and has been managed with thrombectomy each time. She also underwent radial artery ligation post-radial artery injury.

She was on three antihypertensive drugs: carvedilol, furosemide, and nifedipine. She was also on atorvastatin for dyslipidemia, linagliptin for diabetes, and sevelamer for her ESRD. She was a non-smoker, with no history of alcohol or illicit drug consumption. She had no known allergies. Her family history was not significant for similar presentations. And there were no known genetic diseases in her family.

Diagnosis of left CTS was confirmed by nerve conduction studies that revealed electrophysiological evidence of severe left median neuropathy at the wrist.

2.1. Surgical procedure

Intraoperatively, after incision of the skin and palmar fascia, a large, patent, non-calcified, pulsatile arterial vessel was encountered and this incidental finding was identified as a persistent median artery (palmar type). The median artery was mobilized radially to expose the transverse carpal ligament and to relieve pressure on the median nerve. The ligament was snipped and the median nerve was identified and protected. The ligament was released proximally and distally till the fat pad sign. Antebrachial fascia was released. The thumb blanched on intraoperative compression of the median artery. Indicating that the PMA was crucial to the blood supply of the thumb, as the radial artery was previously

ligated. The PMA remained undamaged.

The surgery was performed in a university hospital, the operator was a hand surgery fellow with six years of plastic surgery training. There were no deviations from the initial surgical management plan.

2.2. Post-operative course

No immediate postoperative complications were encountered. The hand was well perfused. The patient was discharged on the same day. The patient was seen at the clinic one week, two weeks, and four weeks following the procedure. She reported gradual improvement of symptoms and by the fourth week she reported complete resolution of pain and paresthesias. Regarding her perspective, she was happy with the procedure as her pain was completely relieved. Her hand was well perfused with a functioning graft. She was advised to continue dialysis and control her diabetes (Fig. 1).

3. Discussion

The flexor muscle tendons (9 tendons), their sheaths, and the median nerve all pass through the carpal tunnel. Because the carpal tunnel walls are inflexible, any thickening of the components may compress the median nerve and its branches. A PMA when increased to 3 mm diameter (in situations such as the presence of an internal thrombus, aneurysm, or calcified plaque) could be an independent risk factor for CTS [9].

Thrombosis of the median artery causing CTS can present with the typical symptoms of paresthesia and pain. However an additional finding of swelling of the hand can be found [10]. Acute onset of CTS symptoms in young patients post-trauma could be a sign of PMA thrombosis [11]. Diagnosis can be made by ultrasound of the PMA displaying absent blood flow distal to the point of occlusion [10]. The most common risk factor appears to be trauma [11]. Ligation and excision can be performed if the radial and ulnar arteries are patent and provide adequate perfusion. However, if the PMA is critical to perfusion of the hand, bypassing of the artery with a vein graft may be an alternative [9].

The PMA and bifid median nerve often coexist, and the persistent median vein travels parallel to the PMA at times. Preoperative ultrasonography is required because their positional relation in the carpal tunnel is unknown. An anomalous PMA that penetrates the median nerve, according to Singla et al. [12], may compress the nerve and create symptoms of proximal median neuropathy. Ischemia in the nerve may be caused by the compressive force of the pulsing artery that pierces the nerve [12].

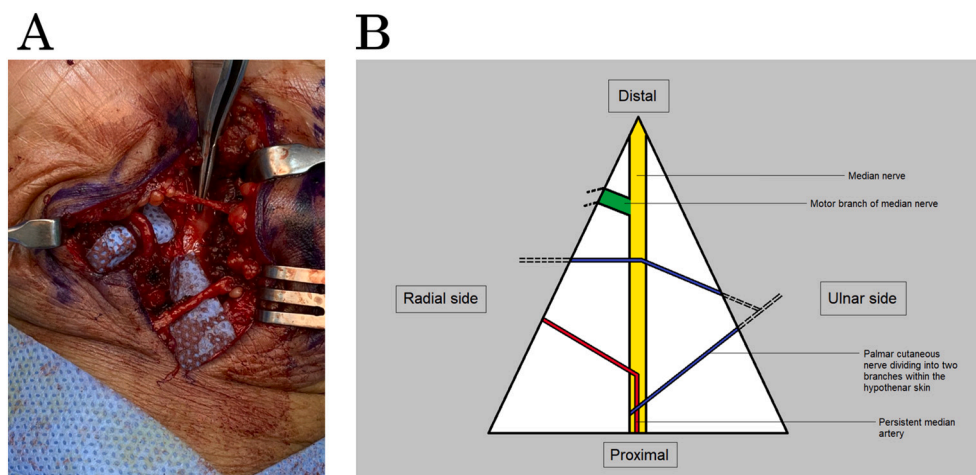


Fig. 1. (A) An intraoperative picture of the patient's left wrist. (B) An explanatory diagram of the anatomy of the patient's wrist.

Awareness of the operating surgeon about this variation to avoid iatrogenic injury is crucial. We have demonstrated through this report that this artery was encountered directly in the line of a standard approach to a carpal tunnel decompression. We recommend a careful step-by-step approach to this procedure, keeping in mind that this variation could present itself at any time.

Many studies showed that the palmar type of the PMA almost always passes deep to the flexor retinaculum when it is present [13,14]. In our case, the PMA was located above the flexor retinaculum beneath the site of incision. To the best of our knowledge, this has only been reported twice previously [15,16]. Thus, surgeons should be aware of the possibility of occurrence of the PMA and the relation of this rare variant to the median nerve within the carpal tunnel when planning surgical procedures, as the artery can be easily injured causing intra- or postoperative bleeding [17].

Hemodialysis patients are more likely to develop CTS after 10 years of dialysis [5]. In this case, signs and symptoms developed 7 months after starting dialysis. Some authors have suggested excision of the PMA to prevent possible thrombosis and persistence of CTS, others recommend its preservation and translocation [18,19].

4. Conclusion

When CTR is performed, surgeons should be aware of the significant possibility of finding a PMA. Although normally found deep to the transverse carpal ligament, it could be superficial to it. In our opinion, in the cases of CTS associated with PMA, the artery should be preserved, especially if its contributions to the blood supply of the hand are undetermined. Knowledge of anatomic variations of the PMA and its contribution to the formation of the superficial palmar arch is of great clinical significance. Mainly to prevent injury during planning and conducting surgeries within the wrist region and the carpal tunnel to avoid any possible complications.

Consent

Written informed consent was obtained from the patient for publication of this case report and accompanying images. A copy of the written consent is available for review by the Editor-in-Chief of this journal on request.

Provenance and peer review

Not commissioned, externally peer-reviewed.

Ethical approval

Approval granted from Institutional Review Board at Al-Imam Muhammad Ibn Saud Islamic University.

Funding

None.

Guarantor

Abdulaziz Almodumeegh.

Research registration number

N/a.

CRedit authorship contribution statement

Abdulaziz Almodumeegh: Conceptualization, Writing - Review & editing, Supervision
 Nouf Alotaibi, Abduljabbar Alyamani, Abdulelah Aldossari, Ali Alammari: Methodology, Investigation, Writing - Original draft
 Mohammed Alqattan: Conceptualization, Writing - Review & editing, Supervision.

Declaration of competing interest

None declared.

References

- [1] L. Padua, D. Coraci, C. Erra, C. Pazzaglia, I. Paolasso, C. Loreti, P. Caliandro, L. D. Hobson-Webb, Carpal tunnel syndrome: clinical features, diagnosis, and management, *Lancet Neurol.* 15 (2016) 1273–1284, [https://doi.org/10.1016/S1474-4422\(16\)30231-9](https://doi.org/10.1016/S1474-4422(16)30231-9).
- [2] I. Atroshi, C. Gummesson, R. Johnsson, E. Ornstein, J. Ranstam, I. Rosén, Prevalence of carpal tunnel syndrome in a general population, *JAMA* 282 (1999) 153–158, <https://doi.org/10.1001/jama.282.2.153>.
- [3] I. Kocyigit, A. Unal, A. Guney, E. Mavili, K. Deniz, M. Kocyigit, M. Sipahioğlu, E. Eroglu, B. Tokgoz, A.I. Gunal, O. Oymak, Carpal tunnel release surgery and venous hypertension in early hemodialysis patients without amyloid deposits, *Sci. World J.* 2013 (2013), 481348, <https://doi.org/10.1155/2013/481348>.
- [4] S. Tharwat, M.K. Nassar, Clinical and ultrasonographic screening for carpal tunnel syndrome in hemodialysis patients, *Kidney Res. Clin. Pract.* 39 (2020) 213–220, <https://doi.org/10.23876/j.krcp.20.011>.
- [5] F. Gejyo, I. Narita, Current clinical and pathogenetic understanding of beta2-m amyloidosis in long-term haemodialysis patients, *Nephrology (Carlton)* 8 (Suppl) (2003) S45–S49, <https://doi.org/10.1046/j.1440-1797.8.s.10.x>.
- [6] K. Osiak, P. Elnazir, A. Mazurek, A. Pasternak, Prevalence of the persistent median artery in patients undergoing surgical open carpal tunnel release: a case series, *Transl. Res. Anat.* 23 (2021), 100113, <https://doi.org/10.1016/j.tria.2021.100113>.
- [7] J.E. Tulipan, A.M. Ilyas, Carpal tunnel syndrome surgery: what you should know, *Plast. Reconstr. Surg. – Glob. Open.* 8 (2020), e2692, <https://doi.org/10.1097/GOX.0000000000002692>.
- [8] SCARE Group, R.A. Agha, T. Franchi, C. Sohrabi, G. Mathew, A. Kerwan, The SCARE 2020 guideline: updating consensus Surgical CAse REport (SCARE) guidelines, *Int. J. Surg. Lond. Engl.* 84 (2020) 226–230, <https://doi.org/10.1016/j.ijsu.2020.10.034>.
- [9] S.J. Beran, R.M. Friedman, M. Kassir, Recurrent digital ischemia due to thrombosis of the persistent median artery, *Plast. Reconstr. Surg.* 99 (1997) 1169–1171, <https://doi.org/10.1097/00006534-199704000-00042>.
- [10] D.W. Bartels, A.Y. Shin, Surgical excision of a thrombosed persistent median artery causing carpal tunnel-like symptoms: a case report, *JBJS Case Connect.* 10 (2020), e2000139, <https://doi.org/10.2106/JBJS.CC.20.00139>.
- [11] C. Balakrishnan, M.F. Smith, P. Puri, Acute carpal tunnel syndrome from thrombosed persistent median artery, *J. Emerg. Med.* 17 (1999) 437–439, [https://doi.org/10.1016/s0736-4679\(99\)00011-6](https://doi.org/10.1016/s0736-4679(99)00011-6).
- [12] R.K. Singla, N. Kaur, G.S. Dhiraj, Prevalence of the persistent median artery, *J. Clin. Diagn. Res.* 6 (2012) 1454–1457, <https://doi.org/10.7860/JCDR/2012/4218.2531>.
- [13] M. Patnaik, S. Paul, Persistent median artery of the forearm and palm: a cadaver study into its origin, course, fate and clinical significance, *Ital. J. Anat. Embryol.* 121 (2016), <https://doi.org/10.13128/IJAE-18348>.
- [14] M. Rodriguez-Niedenführ, J.R. Sañudo, T. Vázquez, L. Nearn, B. Logan, I. Parkin, Median artery revisited, *J. Anat.* 195 (1999) 57–63, <https://doi.org/10.1046/j.1469-7580.1999.19510057.x>.
- [15] J. Butt, A. Ahluwalia, A. Dutta, Incidental finding of a persistent median artery (palmar type) during a routine carpal tunnel decompression: a case report, *Ann. R. Coll. Surg. Engl.* 99 (2017) e204–e205, <https://doi.org/10.1308/rcsann.2017.0088>.
- [16] A.M. Feintisch, H.S. Ayyala, R. Dathiashvili, An anatomic variant of persistent median artery in association with carpal tunnel syndrome: case report and review of the literature, *J. Hand Surg. Asian-Pac.* 22 (2017) 523–525, <https://doi.org/10.1142/S0218810417720388>.
- [17] R. Haladaj, G. Wysiadecki, Z. Dudkiewicz, M. Polguy, M. Topol, Persistent median artery as an unusual finding in the carpal tunnel: its contribution to the blood supply of the hand and clinical significance, *Med. Sci. Monit. Int. Med. J. Exp. Clin. Res.* 25 (2019) 32–39, <https://doi.org/10.12659/MSM.912269>.
- [18] Y. Tsuruo, T. Ueyama, T. Ito, S. Nanjo, H. Gyoubu, K. Satoh, Y. Iida, S. Nakai, Persistent median artery in the hand: a report with a brief review of the literature, *Anat. Sci. Int.* 81 (2006) 242–252, <https://doi.org/10.1111/j.1447-073X.2006.00150.x>.
- [19] T. Barfred, A.P. Højlund, K. Bertheussen, Median artery in carpal tunnel syndrome, *J. Hand Surg.* 10 (1985) 864–867, [https://doi.org/10.1016/s0363-5023\(85\)80163-5](https://doi.org/10.1016/s0363-5023(85)80163-5).