

Concomitant leiomyosarcoma of the right kidney and squamous cell carcinoma of the cervix – an unusual clinical presentation

Tobe Momah,¹ Vasantha Kondamudi,¹
 Sherly Abraham,¹ Dhanan Etwaru,²
 Ahulwalia Meena,³ Arnold Teo,²
 Phillip Xiao⁴

¹Department of Family Medicine,

²Department of Urology, ³Department of Hematology/Oncology, ⁴Department of Pathology, The Brooklyn Hospital, Brooklyn, NY, USA

Abstract

We report a case of right-sided leiomyosarcoma of the kidney with concomitant poorly differentiated squamous cell carcinoma of the cervix diagnosed one month after radical nephrectomy in a previously healthy female patient. This is the first reported case of concomitant leiomyosarcoma of the kidney and squamous cell carcinoma of the cervix, and the diagnosis, clinical presentation, prognosis, and treatment are discussed.

Case Report

Our patient is a 53-year-old African American female with no significant past medical, surgical, or family history who presented to our facility with a three-month complaint of right flank pain that was localized, gradually worsening, and graded as 7/10 by her. She is P3003, married, and had undergone a Papanicolaou (PAP) smear with an uneventful outcome (according to her) three years prior to presentation.

A computerized tomography (CT) scan of the abdomen showed an 11.7×10×8 cm right flank mass (Figure 1) consistent with a large exophytic mass highly suspicious for a renal cell neoplasm. A subsequent CT scan of the head, chest, abdomen, and pelvis was negative for any obvious metastases.

Our patient underwent a right radical nephrectomy five days after admission with positive pathology for a 9 cm high-grade leiomyosarcoma (Figure 2), showing extensive areas of necrosis and vascular invasion. Our patient was discharged on postoperative day 4 in a stable condition, and she opted for a herbal remedy rather than chemoradiation therapy. On postoperative day 30, our patient

presented to the emergency room (ER) with persistent vaginal bleeding for 11 days; on physical examination, a bulky cervical mass of 7×8 cm with bilateral parametrial infiltration extending to the pelvic wall was seen and biopsied. Histopathology of the mass confirmed a diagnosis of poorly differentiated squamous cell carcinoma of the cervix, stage IIIB. A repeat CT scan of the chest, abdomen, and pelvis with contrast revealed no obvious metastases and a 7.9×6.8 cm heterogeneous soft tissue mass within the lower uterine segment (Figure 3), which a pelvic sonogram confirmed by showing a 6.4×6.9×7.7 cm cervical growth.

Our patient underwent definitive radiation therapy for the squamous cell carcinoma of the cervix, receiving a total of 74.1 Gy in less than four months, and attempted brachytherapy. She re-presented to the ER nine months later with marked anemia (hemoglobin: 5.1 mg/dL), generalized weakness, and poor functional status. A repeat CT scan and sonogram of the abdomen showed multiple metastases in the right flank with possible distant metastases in the liver. She also complained of severe back pain, and eventually passed away one week after re-admission.

Discussion

This is the first reported case of concomitant leiomyosarcoma of the kidney and squamous cell carcinoma of the cervix. The definitive diagnosis of both conditions requires surgical sampling and a high index of suspicion at inception. Our patient had no known risk factors for cervical cancer such as cigarettes, promiscuity, human papilloma virus (HPV) infection, human immunodeficiency virus (HIV) disease, or prior abnormal PAP smears. Her rapidly progressive cervical carcinoma mass was, possibly, a result of a latent HPV infection that her immune compromised status (secondary to her first primary – the leiomyosarcoma of the right kidney) exacerbated.

Leiomyosarcoma of the kidney is a very rare neoplasm with only about 190 cases published in the medical literature,¹ and among renal sarcomas accounts for 50-60% of cases.² The United States National Cancer Institute (NCI) Surveillance, Epidemiology and End Result (SEER) program¹ documented 112 cases in the NCI chronology between 1973 and 2006, while about 47 cases have so far been reported in Japan. There was a preponderance of female cases in the SEER study with a 58% majority and most of them occurred between the fourth and sixth decades of life.³ In comparison, the incidence of squamous cell carcinoma of the cervix has been declining

Correspondence: Tobe Momah, Department of Family Medicine, The Brooklyn Hospital Center, 121 Dekalb Ave, Brooklyn, NY, 11201, USA.
 E-mail: tobemomah@yahoo.com

Key words: leiomyosarcoma, squamous cell carcinoma, kidney, cervix.

Received for publication: 28 April 2010.

Revision received: 13 September 2010.

Accepted for publication: 20 September 2010.

This work is licensed under a Creative Commons Attribution 3.0 License (by-nc 3.0).

©Copyright T. Momah et al., 2010
 Licensee PAGEPress, Italy
 Hematology Reports 2010; 2:e7
 doi:10.4081/hr.2010.e7

steadily owing to the effect of widespread screening for premalignant cervical changes by cervical cytology (PAP smear).⁴ In 2006, only 9710 women were diagnosed with cervical cancer (of which 85-90% were of the squamous cell variety) in the United States with 3700 mortalities.⁴

Initial presenting symptoms of leiomyosarcoma mimic renal cell carcinoma and include flank mass, pain, and hematuria⁵ with the right side twice as involved as the left side.⁶ This makes radiological diagnosis of leiomyosarcoma difficult, with postoperative pathological investigation the only way to make a definitive diagnosis. In like vein, only a histopathological specimen can definitively diagnose cervical cancer, and the fact that our patient had a negative PAP smear three years before current diagnosis calls into question the new ACOG recommendation to screen asymptomatic healthy females once every three years.⁷ Even though the guidelines make provision for more regular screening in immune-compromised patients,⁷ the clinical presentation by our patient, although typical of cervical cancer (which includes vaginal bleeding and pelvic pain), could be easily missed on the basis of a recent normal PAP smear.

Treatment of renal leiomyosarcoma has been restricted to surgical, wide resection but recent reports of regression with adjuvant irradiation and chemotherapy⁸ may soon change this.^{2,8} The most effective chemotherapy regimens currently in use include doxorubicin, actinomycin D, cyclophosphamide, and vincristine.³ Other interventions include adjunctive irradiation with 5000 rads and a synergy of gemcitabine and docetaxel in metastatic disease.³ High-stage cervical cancers (stages II-IV) are treated by chemoradiation using cisplatin, 40 mg/m² weekly, and external radiation treatment with brachyther-

apy. Response rates to chemotherapy are approximately 50% (partial and complete), using multiple-agent regimens containing cisplatin, and 20-70% for radiation therapy depending on the stage.⁴ Surgery is often used

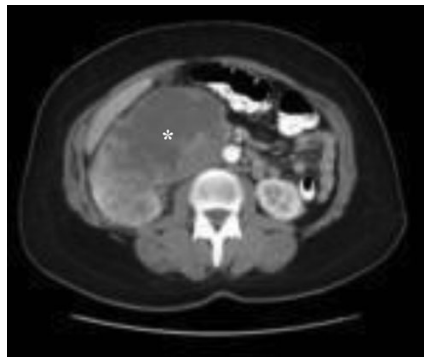


Figure 1. Right-sided kidney mass on computer tomography scan.

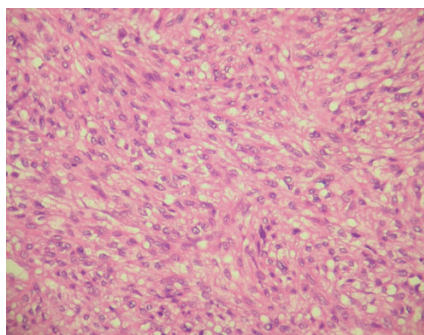


Figure 2. Histopathology of a high-grade leiomyosarcoma of the kidney (high-power; hematoxylin and eosin stain).

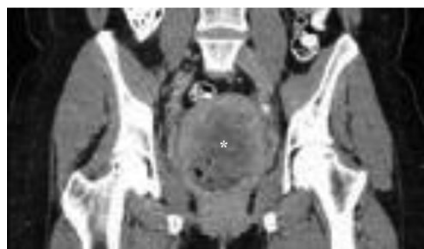

Figure 3. Cervical mass on computer tomography scan.

for treating stage IB and early stage IIA carcinomas of the cervix and include radical hysterectomy and pelvic exenteration with five-year survival rates of 50% or better.⁴ Our patient with stage IIIB cervical cancer had a prognosis of between 25% and 50%.⁴

The prognosis for renal leiomyosarcoma is related to its grade with intermediate- and high-grade lesions showing an aggressive course with significant mortality (<25% survival at 5 years)⁹ and low-grade lesions less than 5 cm in size a better prognosis.¹⁰ Our patient had a high-grade lesion greater than 5 cm with vascular invasion, and thus had an unfavorable prognosis. Leiomyosarcomas are characterized by rapid growth rate, frequent metastases, and high local and systemic recurrence rates,^{2,11-13} while cervical cancer is rarely found in advanced stages in the United States because of the cervical screening tools that have been in place since the 1950s.⁴ Cervical cancer is staged from stage I through IV and the prognosis is dependent on the size of the lesion and the stage at which the patient presents.⁴

Our patient underwent nephrectomy for the right-sided leiomyosarcoma of the kidney and became immune-compromised, which led to the rapid progression of the squamous cell carcinoma of the cervix. She presented with vaginal bleeding even though she had normal prior PAP smears and responded rapidly to irradiation of the cervix. In patients with leiomyosarcoma of the kidney, a concomitant squamous cell carcinoma of the cervix may occur and each primary malignancy must be treated individually, noting that a second primary may be secondary to the first primary with an immune-compromised status.

References

1. Kendal W. The comparative survival of renal leiomyosarcoma. *Can J Urol* 2007;14:3435-42.
2. Sharma D, Pradhan S, Aryya C, Shukla V. Leiomyosarcoma of kidney - a case report with long term result after radiotherapy and chemotherapy. *Int Urol Nephrol*

2007;39:397-400.

3. Kadikoy H, Haque W, Topkara V, Frome A, Hayes T. Bilateral leiomyosarcoma of the kidney with family history of kidney cancer. *Can J Urol* 2009;16:4847-9.
4. Jhingran A, Levenback C. Malignant diseases of the cervix: microinvasive and invasive carcinoma: diagnosis and management. In: Katz VL, Lentz GM, Lobo RA, Gershenson DM, eds. *Comprehensive Gynecology*. 5th edn. New York: Mosby (Elsevier), 2007.
5. Choudhury M, Singh S, Pujani M, Pathania O. A case of leiomyosarcoma of kidney clinically and radiologically misdiagnosed as renal cell carcinoma. *Indian J Cancer* 2009;46:241-3.
6. Selli C, Stefani P, Carcangiu M, Turini D. Leiomyosarcoma of the kidney: Report of two cases with common angiographic findings. *Cardiovasc Intervent Radiol* 1982;5:275-8.
7. American College of Obstetricians and Gynecologists. *Cervical Cytology Screening*. ACOG Practice Bulletins # 109. *Obstet Gynecol* 2009;114:1409-20.
8. Kouichirou O, Hideo O, Hiroshi H, et al. Leiomyosarcoma of the kidney: CT and MR appearance. *J Comput Assist Tomogr* 1993;17:656-8.
9. Rakowsky E, Barzilay J, Schujman E. Leiomyosarcoma of kidney. *Urology* 1987; 29:68-70.
10. Grasso M, Fortuna F, Blanco S, Crippa S, Bella D. Spontaneous rupture of renal leiomyosarcoma in a 45 year old woman. *Arch Esp Urol* 2004;57:870-2.
11. Deyrup A, Montgomery E, Fisher C. Leiomyosarcoma of the kidney: a clinicopathological study. *Am J Surg Pathol* 2004; 28:178-83.
12. Dominici A, Mondaini N, Nesi G, Travaglini V, Di Cello V, Rizzo M. Cystic leiomyosarcoma of the kidney: An unusual clinical presentation. *Urol Int* 2000;65: 229-31.
13. Demir A, Yazici C, Eren F, Tokeri L. Case report: Good prognosis in leiomyosarcoma of the kidney. *Int Urol Nephrol* 2007;39:7-10.