

DWI/ADC in Differentiation of Benign from Malignant Focal Liver Lesion

Elma Jahic¹, Amela Sofic¹, and Azra Husic Selimovic²

¹Clinic of Radiology, Clinical Center of Sarajevo University, Sarajevo, Bosnia and Herzegovina

²Institute of Gastroenterology, Clinical Center of Sarajevo University, Sarajevo, Bosnia and Herzegovina

Corresponding author: ass. prof. Amela Sofic, MD, PhD. Clinic of Radiology UKCS Sarajevo, Bolnička 25, 71000 Sarajevo, Bosnia and Herzegovina. E-mail: amelasofic@yahoo.com

doi: 10.5455/aim.2016.24.244-247

ACTA INFORM MED. 2016 AUG; 24(4): 244-247

Received: MAY 18, 2016 • Accepted: JUN 24, 2016

ABSTRACT

Material and methods: The study was of prospective-retrospective character. It was carried out at the AKH in Vienna (Austria), where 100 patients with focal liver lesions were included in the study. All patients underwent the routine MR sequences on appliances 1,5 and 3T (Siemens, Germany): T1, T2, HASTE, VIBE, and a DWI with three b values (b 50, b 300 b 600 s/mm²) and ADC map with ROI (regions of interest). The numerical value of ADC map was calculated, where n = 100 liver lesions, by two independent radiologists. **Results:** On the basis of matching the PH finding statistically we get DWI accuracy of 96.8% for the assessment of liver lesions. The average numerical value of ADC in benign hepatic lesions (FNH, Hemangiomas) in our study amounted to 1.88 (1.326 to 2.48) x10³ mm²/s, while the value of malignant liver lesions (HCC, CCC, CRCLM) were significantly lower and amounted to 1.15 (1.024 to 1.343) x10³ mm²/s (Figure 2). Differences between the mean ADC of benign and malignant lesions showed a statistically significant difference with p <0.0005. In our research, we get cut-off for the ADC value of 1,341x10³ mm²/s, which proved to be the optimal parameter for differentiation between benign and malignant lesions. **Conclusion:** Measuring ADC values with DWI as an additional MRI tool can help in oncological practice by distinguishing normal liver parenchyma from focal lesions, and in differentiating benign from malignant liver lesions, particularly in cases where administration of contrast is not possible.

Key words: diffusion weighted imaging, apparent diffusion coefficient, focal liver lesions.

1. INTRODUCTION

Using the current modalities radiologists are now able to provide clinical information related to the pathology of the liver parenchyma. Routine clinical cases have become more demanding and complex, especially because of the growing number of therapeutic procedures in the treatment of focal liver lesions. Due to its high contrast resolution DWI as part of MRI protocol has a growing importance in oncological imaging (1). So far, DWI has been able to detect certain alterations in microarchitecture of liver parenchyma and therefore has the potential to improve the characterization of focal liver lesions (2, 3).

2. MATERIALS AND METHODS

The study was of prospective-retrospective character. It was carried out at the AKH in Vienna (Austria), where 100 patients with focal liver lesions were included in the study. All patients underwent the routine MR sequences

on appliances 1,5 and 3T (Siemens, Germany): T1, T2, HASTE, VIBE, and a DWI with three b values (b 50, b 300 b 600 s/mm²) and ADC map with ROI (regions of interest). The numerical value of ADC map was calculated, where n = 100 liver lesions, by two independent radiologists. The difference of numerical means of ADC between benign and malignant lesions was also calculated. All evaluated lesions went through pathohistological verification.

The concurrence in assessing lesions by two independent radiologists (A and B) when it comes to single-shot T2-weighted fast SE and DWI MRI (b 50, b 300 b and 600 s/mm²) was analyzed. The concurrence in assessing lesions of different types of PH by the same radiologist (A) when it comes to single-shot T2-weighted fast SE and DWI sequences was evaluated.

For the statistical analysis of the obtained data software package SPSS for Windows (version 19.0, SPSS Inc., Chicago, Illinois, USA) and Microsoft

© 2016 Elma Jahic, Amela Sofic, and Azra Husic Selimovic

This is an Open Access article distributed under the terms of the Creative Commons Attribution Non-Commercial License (<http://creativecommons.org/licenses/by-nc/4.0/>) which permits unrestricted non-commercial use, distribution, and reproduction in any medium, provided the original work is properly cited.

Excel (version 11th Microsoft Corporation, Redmond, WA, USA) were used.

3. RESULTS

Gender structure of the respondents in our study was balanced: 52% of men develop compared to 48% of women, with no statistically significant difference ($\chi^2 = 0.182, p = 0.670$). The youngest patient was 19 and the oldest 82 years.

Kendall's tau-b coefficient of concordance showed a statistically significant correlation ($p < 0.0005$) between MRI DWI findings and PH findings of hepatic lesions. PH finding confirmed MRI DWI diagnosis by: hemangioma in 11/12 (92%), by FNH (focal nodular hyperplasia) in 6/10 (60%), in patients with metastatic colorectal cancer (CRC) in 1/1 (100%), the cholangiocellular carcinoma (CCC) in 12/12 (100%) and hepatocellular carcinoma (HCC) in 20/22 (91%) patients (Figure 1). On the basis of matching the PH finding statistically we get DWI accuracy of 96.8% for the assessment of liver lesions. Single-shot T2-weighted fast SE and DWI MRI (b 50, b 300 b 600 s / mm²) were compared by two independent radiologists (A and B) in the assessment of liver lesions in which the Kappa coefficient (Measure of Agreement Kappa = 0.864) showed a statistically significant approval ($p < 0.0005$). But comparing a single-shot T2-weighted fast SE and DWI by one radiologist (A) in the assessment of liver lesions Kendall's tau-b coefficient of agreement (matching) did not show statistically significant matching ($b = 0.119, p = 0.437$). This is manifests in favor of detection by DWI, which detected more liver lesions, of total n = 100 liver lesions n = 18 were not detected on T2 w, which were confirmed by PH. From a total of n = 18 missed hepatic lesions that were not detected in T2 sequences, DWI detected n = 17 (94.4%). From a total of n = 82 detected focal liver lesions on T2w number, n = 81 (96.8%) was detected on DWI. The largest number of focal lesions 8/18 (44%) that were not detected on the T2w sequences, the PH verified as HCC, 4/18 (22%) as FNH, 3/18 (17%) as meta CRC, 2/18 (11%) hemangioma and 1/18 (5%) CCC. (Figure 1)

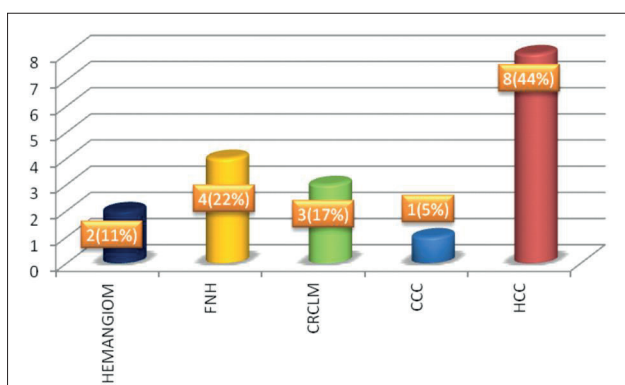


Figure 1. Frequency of changes that were detected on DWI, but not single-shot T2-weighted fast SE

By measuring the ADC value of each lesion individually we got different results between different types of lesions. The average numerical value of ADC in benign hepatic lesions (FNH, Hemangiomas) in our study amounted to $1.88 (1.326 \text{ to } 2.48) \times 10^{-3} \text{ mm}^2/\text{s}$, while the value of malignant liver lesions (HCC, CCC, CRCLM) were significantly lower and amounted to $1.15 (1.024 \text{ to } 1.343) \times 10^{-3} \text{ mm}^2/\text{s}$ (Figure

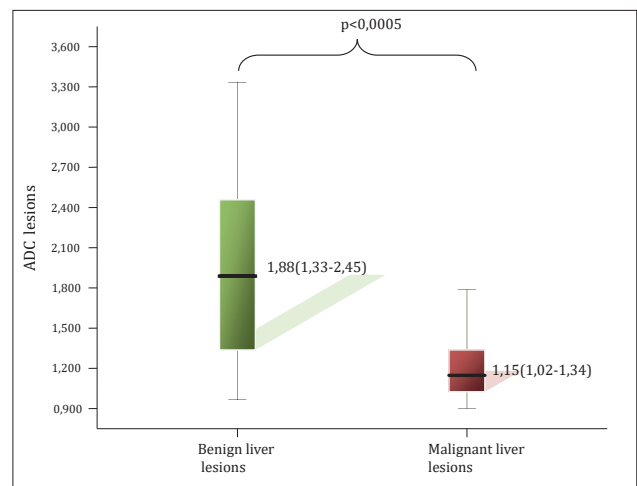


Figure 2. The difference of ADC average values of benign and malignant lesions of the liver. Average values of ADC for benign lesions amounted to $1.88 (1.326 \text{ to } 2.48) \times 10^{-3} \text{ mm}^2/\text{s}$. Average values of ADC for malignant lesions amounted to $1.15 (1.024 \text{ to } 1.343) \times 10^{-3} \text{ mm}^2/\text{s}$

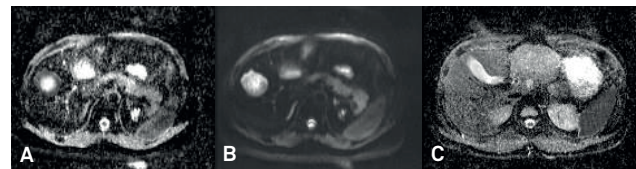


Figure 3. Metastatic lesion of CRC: a) ADC: $1,1 \times 10^{-3} \text{ mm}^2/\text{s}$; b) MR DWI black blood-b value=50sec/mm²; c) ADC :FNH in the left lobe of the liver $1,3 \times 10^{-3} \text{ mm}^2/\text{s}$

2). Differences between the mean ADC of benign and malignant lesions showed a statistically significant difference with $p < 0.0005$. In our research, we get cut-off for the ADC value of $1,341 \times 10^{-3} \text{ mm}^2/\text{s}$, which proved to be the optimal parameter for differentiation between benign and malignant lesions.

4. DISCUSSION

Diffusion figures (average image between images obtained with three diffusion gradient coefficient) is displayed for each b value together with ADC folder. Image with high b value determines whether areas of limited diffusion, which appear as high intensity. Visual estimation of DWI images, including those with high b values (greater than 500sec / mm²), can help in distinction between solid and cystic lesions. Both benign and malignant changes can maintain a high signal intensity with increasing b values, which makes characterization only on the basis of diffusion images difficult. Visual assessment of only diffusion image can lead to false positives because most of benign lesions will appear bright on T2 weighted images and partial volume effect of other structures, which occurs in the cellular benign lesions such as focal nodal hyperplasia-FNH, adenoma, abscess. False negative results can occur in the metastatic mucus-producing tumor, which can mimic cystic lesions, necrotic primary or secondary tumor processes, and image artifacts that may obscure the lesion (4). Problems with DWI may arise when benign lesions have a restriction of diffusion, cystic lesions can imitate necrotic malignant lesions.

In addition to the visual intensity of the signal being assessed (qualitatively) with ADC maps it is necessary to measure the coefficient of diffusion which expresses an average numerical value for each voxel (quantitative $\times 10^{-3} \text{ mm}^2/\text{s}$),

setting the ROI on the place of pathological changes. Diffusion coefficient is connected with mobility of water molecules, which reflects the characteristics of the tissue. Cysts and hemangiomas have the highest ADC values due to the relatively unrestricted diffusion of water molecules within their content, while HCC, metastases and FNH show the lowest value, primarily because of its high cellularity (Figure 3). Therefore there is no overlapping between the ADC values of cysts and solid lesions. However, more important clinical problem is distinguishing metastases from hemangiomas, as hemangiomas may exhibit atypical contrast retention, similarly to the hypervascular metastasis or may be hyalinized and therefore exhibit decreased signal intensity on T2 sequences. Necrotic metastases may show marked hyperintensity on T2 signal imitating hemangiomas (Figure 4). ADC values of metastases and hemangiomas are significantly different with regard to their properties, but to some extent overlappings are possible. Also some overlap between FNH and adenomas is possible. ADC/DWI MRI of liver lesions has been researched significantly with focus on comparing DWI with different MRI techniques (standard breath-hold T2-weighted, breathhold, respiratory triggered, MnDPDP MR imaging, T2-weighted turbo spinecho sequences, etc.) (5-12). Regardless of the possible overlap between malignant and benign hepatic lesions and the non-uniformity in the cut-off value for normal liver parenchyma, according to the literature, ADC value of liver metastases is in the range of $0,94-2,85 \times 10^{-3} \text{ mm}^2/\text{s}$ and the normal liver parenchyma $0,69-2,28 \times 10^{-3} \text{ mm}^2/\text{s}$. Each course has its own scan parameters (breath-hold, respiratory triggered, and navigator echo techniques) and different ADC values, and therefore different cut-off (13). Nevertheless, DWI/ADC is of great benefit because the measurement of the coefficient of diffusion—ADC values may represent a valorization factor in monitoring the oncological therapy (14).

In our study, we demonstrated that the ADC map is reliable in distinguishing benign (hemangioma, FNH) from malignant lesions (HCC, CCC, CRC metastases). Based on the obtained average ADC value of benign hepatic lesions of $1.88 (1.326 \text{ to } 2.48) \times 10^{-3} \text{ mm}^2/\text{s}$ and malignant liver lesions of $1.15 (1.024 \text{ to } 1.343) \times 10^{-3} \text{ mm}^2/\text{s}$ statistical testing showed a statistically significant difference ($p < 0.0005$). The obtained cut-off ADC value between benign and malignant lesions is $1,341 \times 10^{-3} \text{ mm}^2/\text{s}$ and DWI accuracy in the overall differentiation of liver lesions of 96.8%. Taouli and Koh on the work of review report the results of various studies in which the value of ADC cut-off ranged from $1:47 \times 10$ to $1.63 \times 10^{-3} \text{ mm}^2/\text{s}$, which can be used for optimal differentiation of benign from malignant lesions (15). Cut-off ADC value that we get from $1,341 \times 10^{-3} \text{ mm}^2/\text{s}$ is slightly lower than the average of the above study, but higher than the one of Cieszanowski et al which was $1.25 \times 10^{-3} \text{ mm}^2/\text{s}$ (16). Filipe et al. used the cut-off value of $1,43 \times 10^{-3} \text{ mm}^2/\text{s}$ when differentiating benign from malignant lesions and have concluded that the ADC value of malignant lesions is significantly lower compared to benign lesions (17). Testa et al. they obtained the results that showed statistically significant difference between benign and malignant lesions with the cut-off value of $1,2 \times 10^{-3} \text{ mm}^2/\text{s}$, and the accuracy of 71% (18). There are several possible reasons that explain these differences, including

the use of different hardware, the lack of standardized protocols for image acquisition (using different b values), different methods for calculating ADC and different population of patients. The growing use and importance of DWI will certainly with future development contribute to uniformity of parameters for image acquisition.

5. CONCLUSION


Measuring ADC values with DWI as an additional MRI tool can help in oncological practice by distinguishing normal liver parenchyma from focal lesions, and in differentiating benign from malignant liver lesions, particularly in cases where administration of contrast is not possible.

• Declaration of interests: The authors declare no conflict of interests.

REFERENCES

1. Theilmann RJ, Borders R, Trouard TP, Xia G, Outwater E, Ranger-Moore J, Gillies RJ, Stopeck A. Changes in water mobility measured by diffusion MRI predict response of metastatic breast cancer to chemotherapy. *Neoplasia*. 2004; 6(6): 831-7.
2. Szafer A, Zhong J, Anderson AW, Gore JC Diffusion-weighted imaging in tissues: theoretical models. *NMRBiomed*. 1995; 8: 289-96.
3. Ichikawa T, Haradome H, Hachiya J, Nitatori T, Araki T. Diffusion-weighted MR imaging with a singleshot echoplanar sequence: detection and characterization of focal hepatic lesions. *Am J Roentgenol*. 1998; 170: 397-402.
4. Bharwani N, Koh DM, Diffusion-weighted imaging of the liver: an update. *Cancer imaging*. 2013; 13(2): 171-185.
5. Namimoto T, Yamashita Y, Sumi S, Tang Y, Takahashi M. Focal liver masses: characterization with diffusion-weighted echo-planar MR imaging. *Radiology*. 2004; 739-44.
6. Parikh T, Drew SJ, Lee VS, et al. Focal liver lesion detection and characterization with diffusion-weighted MR imaging: comparison with standard breath-hold T2-weighted imaging. *Radiology*. 2008; 246: 812-22.
7. Kwee TC, Takahara T, Koh DM, Nieuwstein RA, Lujten PR. Comparison and reproducibility of ADC measurements in breathhold, respiratory triggered, and free-breathing diffusion-weighted MR imaging of the liver. *J Magn Reson Imaging*. 2008; 28: 1141-8.
8. Taouli B, Sandberg A, Stemmer A, et al. Diffusion-weighted imaging of the liver: comparison of navigator triggered and breathhold acquisitions. *J Magn Reson Imaging*. 2009; 30: 561-8.
9. Koh DM, Brown G, Riddell AM, et al. Detection of colorectal hepatic metastases using MnDPDP MR imaging and diffusion weighted imaging (DWI) alone and in combination. *Eur Radiol* 2008; 18: 903-10.
10. Bruegel M, Gaa J, Waldt S, et al. Diagnosis of hepatic metastasis: comparison of respiration-triggered diffusion-weighted echoplanar MRI and free T2-weighted turbo spinecho sequences. *AJR Am J Roentgenol*. 2008; 191: 1421-9.
11. Gourtsoyianni S, Papanikolaou N, Yarmenitis S, Maris T, Karantanis A, Gourtsoyannis N. Respiratory gated diffusion-weighted imaging of the liver: value of apparent diffusion coefficient measurements in the differentiation between most common encountered benign and malignant focal liver lesions.

- Eur Radiol. 2008; 18: 486-92.
12. Kim T, Murakami T, Takahashi S, Hori M, Tsuda K, Nakamura H. Diffusion-weighted single-shot echo-planar MR imaging for liver disease. *AJR Am J Roentgenol.* 1999; 173: 393-8.
 13. Goshima S, Kanematsu M, Kondo H, Yokoyama R, Kajita K, Tsyge Y, et al. Diffusion-weighted imaging of liver: optimizing b values for the detection and characterization of benign and malignant lesions. *J Magn Reson Imaging.* 2008; 28: 691-7.
 14. Bruegel M, Holzapfel K, Gaa J, Woertler K, Waldt S, Kiefer B, et al. Characterization of focal liver lesions by ADC measurements using a respiratory triggered diffusion-weighted single-shot echo-planar MR imaging technique. *Euro Radiol.* 2008; 18: 477-85.
 15. Taouli B, Koh DM. Diffusion-weighted imaging of the liver. *Radiology.* 2010; 254: 47-66.
 16. Cieszanowski A, Anysz-Grodzicka A, Szeszkowski W, Kaczynski B, Maj E, Gornicka B, et al. Characterization of focal liver lesions using quantitative techniques: comparison of apparent diffusion coefficient values and T2 relaxation times. *Eur Radiol.* 2012; 25: 14-24.
 17. Filipe JP, Semedo LC, Lopes JC, Marques MC, Alves FC. Diffusion-weighted imaging of the liver: usefulness of ADC values in the differential diagnosis of focal lesions and effect of ROI methods in ADC measurements. *Magnetic Resonance Materials in Physics, Biology and Medicine.* 2013; 26: 303-12.
 18. Testa ML, Chojniak R, Sene LS, Damascena AS, et al. Is DWI/ADC a useful tool in the characterization of focal hepatic lesions suspected of malignancy? *Plos One.* 2014; 9(7): e101944.


COMMITTEE ON PUBLICATION ETHICS
Sign in

Home
About COPE
Resources
Cases
Become a member
Members
Events
News & Opinion
Contact Us

Promoting integrity in research publication

COPE is a forum for editors and publishers of peer reviewed journals to discuss all aspects of publication ethics. It also advises editors on how to handle cases of research and publication misconduct. [Read more about COPE...](#)

Tweet
Recommend
597 people recommend this. Be the first of your friends.

Join here

What are the benefits of COPE membership?

All Latest
Latest Cases
Latest News
Upcoming Events

RESOURCE

Digest July issue: Author impersonating corresponding author

Case of the month plus news, events and advice.

Read more

NEWS

Results of COPE Council election

Thanks to everyone who voted. Read more about our 8 new Council members.

CASE

Paper B plagiarised paper A

What to do if a journal does not respond?

NEWS

Submit a case: August COPE Forum

Submit a case for discussion at the August Forum. Deadline 20 July

NEWS

Register now: North American Seminar

Register for COPE's North American Seminar, free for COPE members. The...

Resources

- Code of Conduct
- Guidelines
- Sample letters
- Flowcharts
- Discussion documents

Cases

All the cases COPE has discussed since its inception in 1997 have been entered into a searchable database. This database now contains over 500 cases together with the advice

eLearning

COPE's eLearning course on publication ethics. Individual modules designed to give editors a deeper understanding about publication ethics and practical guidance about how to

This month's COPE Digest

This past month has been busy for COPE Council members and Trustees. COPE held its annual strategy meeting in mid-June with three days of meetings among the Trustee Board, wider