

## Short Communications

# Republication: Two Premature Neonates of Congenital Syphilis with Severe Clinical Manifestations‡

Moe Akahira-Azuma\*†, Mai Kubota†, Shinichi Hosokawa, Masao Kaneshige, Noriko Yasuda, Noriko Sato and Takeji Matsushita

Received 16 March, 2015 Accepted 12 May, 2015 Published online 11 June, 2015

**Abstract:** Congenital syphilis (CS) is a public health burden in both developing and developed countries. We report two cases of CS in premature neonates with severe clinical manifestations; Patient 1 (gestational age 31 weeks, birth weight 1423 g) had disseminated idiopathic coagulation (DIC) while Patient 2 (gestational age 34 weeks and 6 days, birth weight 2299 g) had refractory syphilitic meningitis. Their mothers were single and had neither received antenatal care nor undergone syphilis screening. Both neonates were delivered via an emergency cesarean section and had birth asphyxia and transient tachypnea of newborn. Physical examination revealed massive hepatosplenomegaly. Laboratory testing of maternal and neonatal blood showed increased rapid plasma reagin (RPR) titer and positive *Treponema pallidum* hemagglutination assay. Diagnosis of CS was further supported by a positive IgM fluorescent treponemal antibody absorption test and large amounts of *T. pallidum* spirochetes detected in the placenta. Each neonate was initially treated with ampicillin and cefotaxime for early bacterial sepsis/meningitis that coexisted with CS. Patient 1 received fresh frozen plasma and antithrombin III to treat DIC. Patient 2 experienced a relapse of CS during initial antibiotic treatment, necessitating parenteral penicillin G. Treatment was effective in both neonates, as shown by reductions in RPR. Monitoring of growth and neurological development through to age 4 showed no evidence of apparent delay or complications. Without adequate antenatal care and maternal screening tests for infection, CS is difficult for non-specialists to diagnose at birth, because the clinical manifestations are similar to those of neonatal sepsis and meningitis. Ampicillin was insufficient for treating CS and penicillin G was necessary.

**Key words:** congenital syphilis, disseminated idiopathic coagulopathy (DIC), syphilitic meningitis, penicillin G

## INTRODUCTION

Congenital syphilis (CS) results from the vertical transmission of *Treponema pallidum* from a pregnant woman to the fetus, which can cause abortion, stillbirth, prematurity and low birth weight. Live neonates may be asymptomatic or have clinical manifestations due to multiple organ involvement, such as hepatosplenomegaly, sepsis, and meningitis [1–3].

The World Health Organization (WHO) recommends antenatal screening of syphilis and early treatment with penicillin to prevent CS [2, 4–6]. However, CS continues to be an important cause of neonatal mortality worldwide [7] and is a public health burden in both developing [8–11] and developed [12–16] countries.

In Japan, CS has been reported in the setting of inadequate antenatal care and treatment during pregnancy [12], but it is not widely known to general physicians. Here, we report in detail the care, treatment, and follow-up of two cases of premature neonates with severe clinical manifestations of CS whose mothers had not received adequate antenatal care in Japan.

## CASE 1

A female infant was born to a 24-year-old, gravida 5 para 5 mother who presented to the hospital just after entering labor. An emergency cesarean section was performed because of fetal heart distress. The mother had not received prenatal care, and gestational age was estimated

National Center for Global Health and Medicine, 1-21-1 Toyama, Shinjuku-ku, Tokyo 162-8655, Japan

\*Corresponding author:

Tel: +81-3-3202-7181

Fax: +81-3-3207-1038

E-mail: nth3son@yahoo.co.jp

†These authors contributed equally to this work

‡This article is based on a study that had been reported in the *Journal of the Japan Pediatric Society* 2014; 118: 1648–1653.

to be 31 weeks based on her last menstrual period.

At delivery, a decreased amount of amniotic fluid and meconium staining was noted. The infant had respiratory depression at birth, so positive-pressure ventilation and oxygen were administered. Apgar scores were 2 and 9 at 1 and 5 min, respectively. She was admitted to the neonatal intensive care unit (NICU) because of prematurity and birth asphyxia.

A more detailed history was taken from the mother. The mother was single and had multiple sex partners. She did not seek prenatal care for social and economic reasons.

The infant's vital signs on NICU admission were temperature 36.8°C, BP 41/20 mmHg, heart rate 145 bpm, respiratory rate 60 breaths/min, and SpO<sub>2</sub> 100% (FiO<sub>2</sub> 0.4). On physical examination, body weight was 1423 g and the infant was non-dysmorphic. Her anterior fontanel was not bulging. Auscultation did not reveal a heart murmur but relatively poor air entry was noted. Mild tachypnea and retraction were observed, and the abdomen was distended. No obvious rash was seen. A complete blood count re-

vealed a white blood cell (WBC) count of 20,580/ $\mu$ l, hemoglobin level (Hb) of 14.3 g/dl, and platelet (Plt) count of  $2.6 \times 10^4$ / $\mu$ l. The coagulation profile showed PT 31.0 s, PT 24.1%, and APTT 74.8 s, while fibrinogen was 320.0 mg/dl, antithrombin (AT) III 46.5%, FDP 12.6  $\mu$ g/l, and D-dimer was 5.6  $\mu$ /ml. CRP was increased to 8.95 mg/dl. Cerebrospinal fluid (CSF) showed a cell count of 15.2/ $\mu$ l (Neut 1.6/l, Lymph 13.6/l) and glucose level of 53 mg/dl. Chest and abdominal radiology revealed mild bilateral hila infiltration and enlarged liver and spleen. A diagnosis of transient tachypnea of newborn (TTN) and neonatal disseminated idiopathic coagulopathy (DIC) secondary to sepsis was made. She was placed on continuous positive airway pressure (CPAP) ventilation with oxygen administration. Ampicillin and cefotaxime (CTX) (both 200 mg/kg/day) were administered and gamma globulin (500 mg/kg/day) was given to treat severe sepsis. Platelets, fresh frozen plasma (FFP), ATIII, and factor XIII were given for DIC.

On postnatal day (PND) 3, the maternal test came

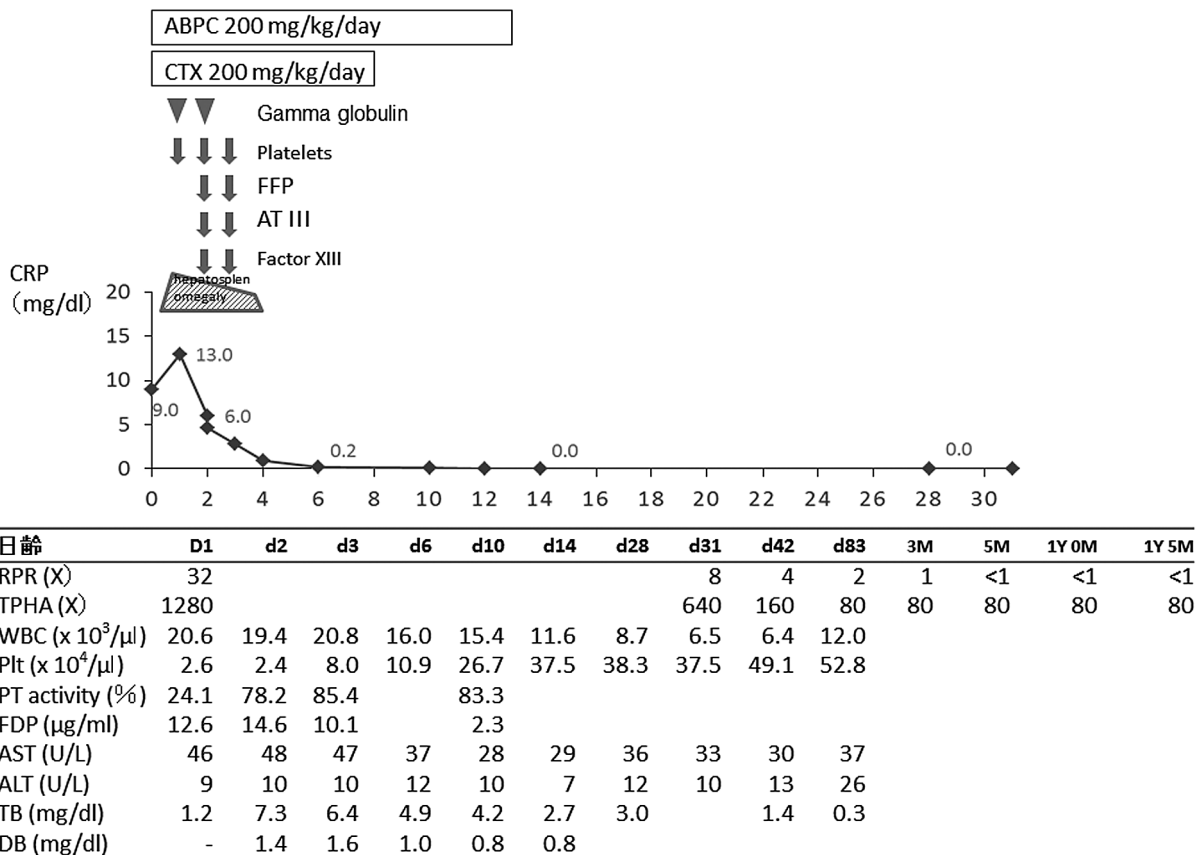


Fig. 1. Clinical course of Case 1  
 ABPC, ampicillin; CTX, cefotaxime; Plt, platelet transfusion; FFP, fresh frozen plasma; ATIII, antithrombin III; RPR, rapid plasma reagin; TPHA, *Treponema pallidum* hemagglutination

back, showing an increased rapid plasma reagin (RPR) titer of 32 and a *T. pallidum* hemagglutination (TPHA) titer of 5,120. The infant's syphilis test showed an RPR titer of 32, a TPHA titer of 1,280, fluorescent treponema antibody absorption (FTA-ABS) of 320, and positive IgM-FTA/ABS. CSF RPR was less than 1. These results indicated that the infant had CS. On PND 4, the hepatomegaly disappeared. Later, pathological examination of the placenta revealed chorioamnionitis, and large numbers of *T. pallidum* spirochetes were seen in villi and the umbilical vein on TPHA staining. Ampicillin seemed to be effective and was continued for 14 days, while CTX was ceased on PND 7 after determination of negative blood and CSF cultures. Cranial MRI and fundus examination demonstrated normal findings. At 5 months of age, RPR and TPHA were decreased to less than 1 and 80, respectively. At 6 months of age, auditory brainstem response (ABR) testing revealed normal findings. Growth and neurological development were within normal limits through to 4 years of age. Her height and weight were average. Developmental milestones of "holding neck steady", "sitting unsupported", "pulls to stand", "walks alone", and "mature jargon" were achieved at 3, 6, 10, 13, and 18 corrected months, respectively.

## CASE 2

A female neonate was born to a 22-year-old, gravida 3, para 1 mother via emergency cesarean section. The mother was single and came to the obstetrics clinic for antenatal care at 6 and 13 weeks of gestational age. However, she did not return to the clinic for routine prenatal care that included maternal infectious screening tests. At 34 weeks and 5 days of gestational age, the mother came to the obstetrics clinic complaining of lower abdominal pain and fever. The next day, she underwent cesarean section because of fetal distress. Immediately before the procedure, it was revealed that titers of RPR and TPHA were increased at 32 and 10,240 respectively, suggesting maternal syphilis infection. Ampicillin was administered immediately during the delivery.

On delivery, meconium-stained amniotic fluid was noted. Apgar score was 2 and 9 at 1 and 5 min, respectively. She was admitted to the NICU because of prematurity, birth asphyxia, and probable CS.

Figure 3 shows the clinical course of Patient 2. On NICU admission, her vital signs were temperature 37.4°C, BP 54/26 mmHg, heart rate 165 bpm, respiratory rate 56/min, and SpO<sub>2</sub> 97% (FiO<sub>2</sub> 0.3). Physical examination re-

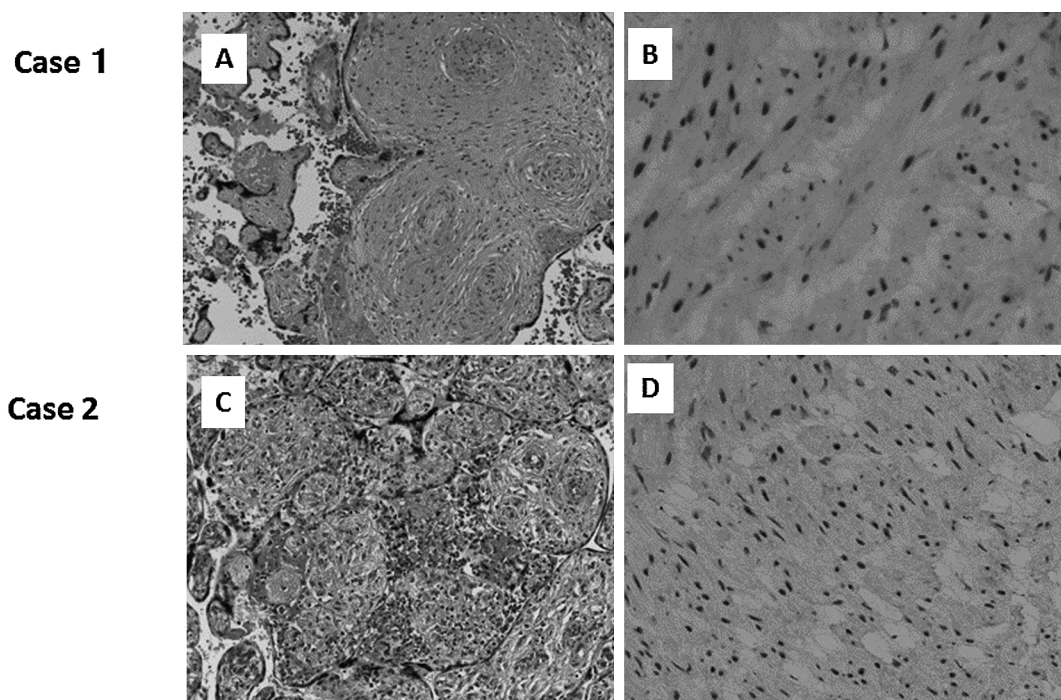


Fig. 2. Pathological findings in Cases 1 and 2

- A. Placenta with chorioamnionitis in Case 1 (HE stain, × 200).
- B. *Treponema pallidum* are present in the villi and umbilical vein in Case 1 (TPHA stain, × 400).
- C. Placenta with chorioamnionitis in Case 2 (HE stain, × 200).
- D. *T. pallidum* are seen in the villi and umbilical vein in Case 2 (TPHA stain, × 400).

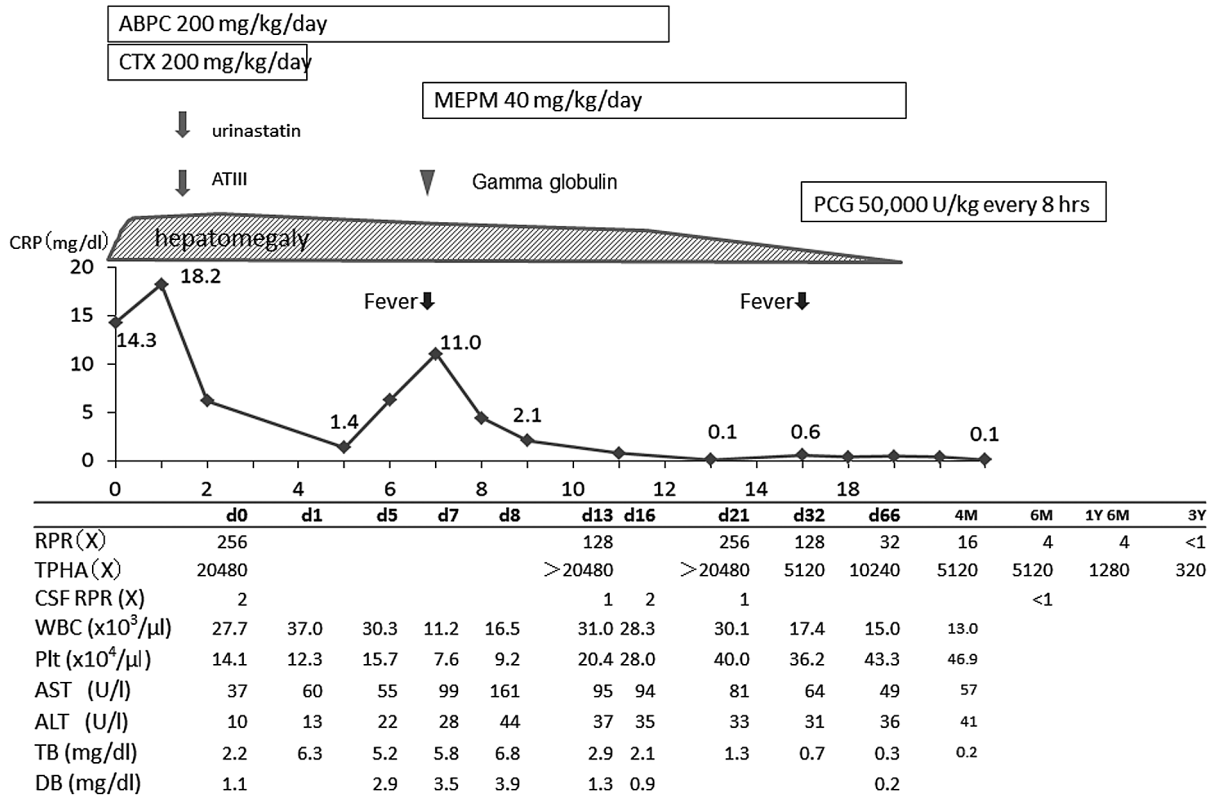


Fig. 3. Clinical course of Case 2  
 ABPC, ampicillin; CS, congenital syphilis; CTX, cefotaxime; MEPM, meropenem; PCG, penicillin G; ATIII, antithrombin III; RPR, rapid plasma regain; TPHA, *Treponema pallidum* hemagglutination

vealed a body weight of 2299 g. She was non-dysmorphic and the anterior fontanel was not bulging. Auscultation showed good air entry with mild retraction and nasal flaring, but no heart murmur was noted. Her abdomen was significantly distended. Laboratory data revealed the following: WBC count 40,160/μl (Seg 24%, Band 22%, Lymph 39%, Mono 10%), Hb 12.4 g/dl, and Plt 14.1 × 10<sup>4</sup>/μl. The coagulation profile was within normal limits. CRP was increased to 14.25 mg/dl. CSF showed a cell count of 30.9/μl (Neut 11.6/μl, Lymph 19.3/μl), glucose level of 60 mg/dl, and protein level of 48 mg/dl. Cord IgM was 343.5 mg/dl. The infant's syphilis tests showed the following results: RPR 256, TPHA 20,480, FTA-Abs 320, positive IgM-FTA/Abs, and CSF RPR 2. Chest and abdominal radiology revealed mild hila infiltration and enlarged liver and spleen. Cranial ultrasound showed normal findings. The infant was diagnosed with prematurity, low birth weight, TTN, CS, and syphilis meningitis. Many *T. pallidum* spirochetes were detected around the umbilical vein on TPHA staining.

The newborn was placed on CPAP and oxygen. Ampicillin and CTX (both 200 mg/kg/day) were administered

empirically for the treatment of CS, syphilis meningitis, and another possible bacterial infection. On PND 5, CTX was stopped after determination of negative blood and CSF cultures and only ampicillin was continued. However, the infant developed fever twice, on PND 6 and 16. During the first relapse on PND 6, she developed a fever of 38°C, coldness of the periphery, abdominal distension, and a rash on the chest and abdomen. After further work-up, necrotizing enterocolitis and new bacterial sepsis/meningitis were suspected. Meropenem (40 mg/kg/day × 14 days) and gamma globulin (500 mg/kg) were administered in addition to ampicillin, and ampicillin was ceased on PND 14 after clinical improvement was noted. The second episode of fever which was associated with an increased CSF cell count and positive CSF RPR on PND 16, led to a diagnosis of relapse of CS and syphilis meningitis. As this was the second relapse, penicillin G was administered according to the Centers for Disease Control and Prevention (CDC) guideline [17]. On PND 32, RPR decreased to 128 and the infant was improved clinically. Cranial MRI and fundus examination demonstrated normal findings.

Normal growth and neurological development were

observed through to 4 years of age. Her height and weight were between  $-1$  and  $-2$ SD. Developmental milestones of “holding head steady”, “sitting unsupported”, “pulls to stand”, “walks alone”, and “mature jargon” were achieved at 3, 6, 10, 13 and 18 corrected months, respectively.

## DISCUSSION

We report two cases of premature neonates with severe clinical manifestations of CS, namely, DIC in Patient 1 and syphilis meningitis in Patient 2. Both had hepatosplenomegaly on physical examination. The diagnosis was based on syphilis tests (RPR, TPHA, FTA-ABS, IgM-FTA/ABS) and detection of *T. pallidum* in the placenta by TPHA staining. Ampicillin was effective in Patient 1 but was not effective in Patient 2.

Despite the syphilis elimination campaign [4], the disease still poses a public health burden in both developing [8–11] and developed [12–16] countries. Syphilis screening is an important aspect of antenatal care because the timely diagnosis of syphilis is crucial to starting penicillin treatment early to achieve a good outcome [3]. In developing countries, access to healthcare, follow-up, and treatment are very difficult to achieve [8–11]. Even in developed countries, it is difficult to eliminate CS [12–16]. In Japan, a retrospective nationwide survey conducted between January 2006 and December 2008 revealed 25 cases of CS and 1.7 adjusted cases/100,000 live births in data obtained from 1183 of 2624 [45.1%] facilities that responded [12]. Stillbirth was not included in this survey. According to the annual report of the Ministry of Health, Labour and Welfare, Japan, 99.8% of pregnant women obtained antenatal care and CS screening in 2009. However, the diagnosis can still be missed in pregnant women in high-risk groups who do not receive adequate antenatal care for social or economic reasons, as occurred in both our cases. For Patient 2 who did receive initial antenatal care, the condition would have been detected if screening tests were carried out at the initial visit. However, in Japan, antenatal screening is performed only after pregnancy is confirmed by OB/GYN doctors and screening is carried out after obtaining health center’s document. Therefore, women who do not progress through the health system in the routine way can be missed, in part due to failings in the current system. Thus, physicians in Japan and other developed countries should be aware that neonates may be at risk of CS if their mothers have not received adequate antenatal screening; this is not just a problem affecting developing countries.

Confirmation of *T. pallidum* placental infection on pathological examination is especially helpful in making a

definitive diagnosis of CS [17–19]. In our two patients, *T. pallidum* infection in the placenta was confirmed after delivery. Physicians should preserve the placenta and immediately order pathology to check for *T. pallidum* infection when they suspect CS. Once a definitive diagnosis is made, treatment should be started without delay to minimize long-term sequelae.

According to WHO [2] and the CDC guideline [17], penicillin G intravenously or procaine penicillin intramuscularly for 10 days is the first choice of antibiotic treatment. There is insufficient evidence for the use of other antibiotics such as ampicillin, so penicillin G is preferable when ampicillin is used for the treatment of sepsis. Penicillin G was approved in 2013 in Japan [20], and ampicillin had been used for the treatment of syphilis and bacteria co-infection up until that point. CS relapsed twice in Patient 2, suggesting that ampicillin was insufficient for such severe cases. Although there is a higher concentration of ampicillin in the CSF in the presence of inflammation, its rate of permeation of the blood brain barrier is low, which could, in part, explain why it was effective in Patient 1 but not in Patient 2. Thus, penicillin should be the first-line antibiotic for CS, and additional antibiotics should be used when bacteria co-infection is suspected.

A recent study [21] investigated the clinical features and outcomes of children treated for CS. In 3 of the 12 registered deaths among live born infants, thrombocytopenia developed and subsequent lung or rectal hemorrhage resulted in death. In addition, 16 children developed neurological sequelae despite treatment. Among them, 9 had CSF abnormality and 8 developed neurological impairment. The study found that CS had a good outcome in most cases that were managed in accordance with standard guidelines. Symptomatic CS is more likely in premature than term infants [21, 22]. Both of our patients were premature with DIC or syphilis meningitis, but our intervention appears to have been adequate given their normal neurological development at 4 years of age.

In conclusion, inadequate antenatal care and an unclear antenatal history or maternal infection status may make it difficult for non-specialists to reach the correct diagnosis despite the presence of clinical manifestations. Ampicillin alone was insufficient in treating CS and it was necessary to use penicillin G, to which *T. pallidum* is the most sensitive.

## ACKNOWLEDGMENTS

We thank Dr. Kazutane Hoshimoto and Dr. Toru Igari for pathological readings.

### ROLE OF THE FUNDING SOURCE

This work was supported in part by Grants-in-Aid for Research from the National Center for Global Health and Medicine (26A-201).

### COMPETING INTERESTS

The authors declare that they have no conflicts of interest.

### REFERENCES

- Kliegman RM, Stanton BF, Geme JS, et al. Syphilis (*Treponema pallidum*). In: Patterson MJ, Davies HD, eds. Nelson Textbook of Pediatrics, 19th edition. Philadelphia: Elsevier Saunders; 2011. pp. 1016–1023.
- World Health Organization, Department of Reproductive Health and Research. Investment case for eliminating mother-to-child transmission of syphilis promoting better maternal and child health and stronger health systems. 2012. Available: [http://apps.who.int/iris/bitstream/10665/75480/1/9789241504348\\_eng.pdf](http://apps.who.int/iris/bitstream/10665/75480/1/9789241504348_eng.pdf) [accessed 22 February 2015]
- Qin J, Yang T, Xiao S, et al. Reported estimates of adverse pregnancy outcomes among women with and without syphilis: a systematic review and meta-analysis. *PLoS One* 2014; 9: e102203.
- World Health Organization, Department of Reproductive Health and Research. The global elimination of congenital syphilis: Rationale and strategy for action. 2007. Available: [http://whqlibdoc.who.int/publications/2007/9789241595858\\_eng.pdf](http://whqlibdoc.who.int/publications/2007/9789241595858_eng.pdf) [accessed 22 February 2015]
- Hawkes S, Matin N, Broutet N, et al. Effectiveness of interventions to improve screening for syphilis in pregnancy: a systematic review and meta-analysis. *Lancet Infect Dis* 2011; 11: 684–691.
- Gomez GB, Kamb ML, Newman LM, et al. Untreated maternal syphilis and adverse outcomes of pregnancy: a systematic review and meta-analysis. *Bull World Health Organ* 2013; 91: 217–226.
- Newman L, Kamb M, Hawkes S, et al. Global estimates of syphilis in pregnancy and associated adverse outcomes: analysis of multinational antenatal surveillance data. *PLoS Med* 2013; 10: e1001396.
- Shahrook S, Mori R, Ochirbat T, et al. Strategies of testing for syphilis during pregnancy. *Cochrane Database Syst Rev* 2014; 10: CD010385.
- Hong FC, Yang YZ, Liu XL, et al. Reduction in mother-to-child transmission of syphilis for 10 years in Shenzhen, China. *Sex Transm Dis* 2014; 41: 188–193.
- Reyna-Figueroa J, Esparza-Aguilar M, Hernández-Hernández Ldel C, et al. Congenital Syphilis, a Reemerging Disease in Mexico: Its Epidemiology During the Last 2 Decades. *Sex Transm Diseases* 2011; 38: 798–801.
- Cruz AR, Castrillón MA, Minotta AY, et al. Gestational and congenital syphilis epidemic in the Colombian Pacific Coast. *Sex Transm Dis* 2013; 40: 813–818.
- Torii Y, Kimura H, Ito Y, et al. Clinicoepidemiologic status of mother-to-child infections: a nationwide survey in Japan. *Pediatr Infect Dis J* 2013; 32: 699–701.
- CDC (Centers for Disease Control and Prevention). Sexually transmitted disease surveillance 2011. Available: <http://www.cdc.gov/std/stats11/surv2011.pdf> [accessed 22 February 2015]
- European Centre for Disease Prevention and Control. Annual epidemiological report 2014—Sexually transmitted infections, including HIV and blood-borne viruses 18 Feb 2015 Available: [http://www.ecdc.europa.eu/en/press/news/\\_layouts/forms/News\\_DispatchForm.aspx?List=8db7286c-fe2d-476c-9133-18ff4cb1b568&ID=1173](http://www.ecdc.europa.eu/en/press/news/_layouts/forms/News_DispatchForm.aspx?List=8db7286c-fe2d-476c-9133-18ff4cb1b568&ID=1173) [accessed 22 February 2015]
- Ortiz-Lopez N, Diez M, Diaz O, et al. Epidemiological surveillance of congenital syphilis in Spain, 2000–2010. *Pediatr Infect Dis J* 2012; 31: 988–990.
- Op de Coul EL, Hahné S, van Weert YW, et al. Antenatal screening for HIV, hepatitis B and syphilis in the Netherlands is effective. *BMC Infect Dis* 2011; 11: 185.
- CDC (Center for Disease Control and Prevention). Sexually transmitted diseases treatment guidelines 2010. *MMWR* 2010; 59: 36–39.
- Sheffield JS, Sánchez PJ, Wendel GD Jr, et al. Placental histopathology of congenital syphilis. *Obstet Gynecol* 2002; 100: 126–133.
- Guarner J, Southwick K, Greer P, et al. Testing umbilical cords for funisitis due to *Treponema pallidum* infection, Bolivia. *Emerg Infect Dis* 2000; 6: 487–492.
- Penicillin G [pharmaceutical interview form]. Tokyo: Meiji Seika; 2013.
- Lago EG1, Vaccari A, Fiori RM. Clinical features and follow-up of congenital syphilis. *Sex Transm Dis* 2013; 40: 85–94.
- Zhou Q, Wang L, Chen C, et al. A case series of 130 neonates with congenital syphilis: preterm neonates had more clinical evidences of infection than term neonates. *Neonatology* 2012; 102: 152–156.