

# Scapholunate Advanced Collapse Wrist – Keeping it Simple – A Case Report

Satvik N Pai<sup>1</sup>, Naveen Jeyaraman<sup>2</sup>, Tarun Jayakumar<sup>3</sup>, Madhan Jeyaraman<sup>2</sup>

## Learning Point of the Article:

Accurate diagnosis and grading of SLAC can be achieved with radiographic analysis alone, enabling early identification and successful treatment without the need for surgery in some cases.

## Abstract

**Introduction:** Scapholunate advanced collapse is a rare condition of progressive deformity, instability, and arthritis that affects the radiocarpal and mid-carpal joints of the wrist. It occurs as a result of injury to the scapholunate ligament being left untreated.

**Case Report:** We present the imaging of a 50-year-old woman who complained of pain in her right wrist for 2 years. Radiographs of the wrist revealed scapholunate diastasis (Terry Thomas Sign), arthritis of the radio-scaphoid joint, dorsal intercalated segment instability, radial styloid beaking, and proximal migration of capitate. We also demonstrate the measurement of radiological parameters such as scapholunate angle.

**Conclusion:** A complete in-depth radiological analysis can thus demonstrate several signs that can prevent missed diagnosis. Increased awareness regarding these radiological signs can avoid the unnecessary higher imaging modalities being performed.

**Keywords:** Scapholunate, collapse, wrist, radio-scaphoid joint.

## Introduction

Scapholunate advanced collapse (SLAC) is a term used to describe a degenerative wrist condition that exhibits progressive instability, deformity, and arthritis. This condition affects both the radiocarpal and mid-carpal joints in the wrist [1]. More specifically, the distinctive arthritic deformity and gradual loss of stability are the result of a prolonged and chronic separation between the lunate and scaphoid carpal bones [2]. SLAC wrist typically represents the final and most advanced stage that arises when a scapholunate ligament injury remains untreated [3, 4]. Epidemiological studies have shown that patients with SLAC wrist were more likely to be male, have a history of a traumatic injury, and be in the early fifth decade of life at the time of diagnosis [3, 5]. The diagnosis of SLAC is often missed or

inaccurately diagnosed as general wrist arthritis [6, 7]. We describe a case of SLAC wrist that demonstrates the identification and grading of SLAC enabling pertinent treatment.

## Case Report

A 50-year-old woman complained of pain in her right wrist for 2 years. The pain was dull aching and aggravated on lifting objects with her right hand. She had a history of falls on her outstretched right hand 4 years earlier. She had no pain in other joints. She had no other pre-existing medical conditions and was right-hand dominant. On examination, tenderness was present over the dorsal aspect of the radial half of the wrist. Range of movements of the wrist was limited with palmar flexion of 50°, dorsiflexion of 40°, ulnar deviation of 30°, and radial deviation of only 10°.

## Author's Photo Gallery



Dr. Satvik N Pai



Dr. Naveen Jeyaraman



Dr. Tarun Jayakumar



Dr. Madhan Jeyaraman

Access this article online

Website:  
www.jocr.co.in

DOI:  
<https://doi.org/10.13107/jocr.2023.v13.i12.4110>

<sup>1</sup>Department of Orthopaedic Surgery, HOSMAT Hospital, Bangalore, Karnataka, India,

<sup>2</sup>Department of Orthopaedics, ACS Medical College and Hospital, Dr MGR Educational and Research Institute, Chennai, Tamil Nadu, India,

<sup>3</sup>Department of Orthopaedics, KIMS-Sunshine Hospital, Hyderabad, Telangana, India.

**Address of Correspondence:**

Dr. Madhan Jeyaraman,

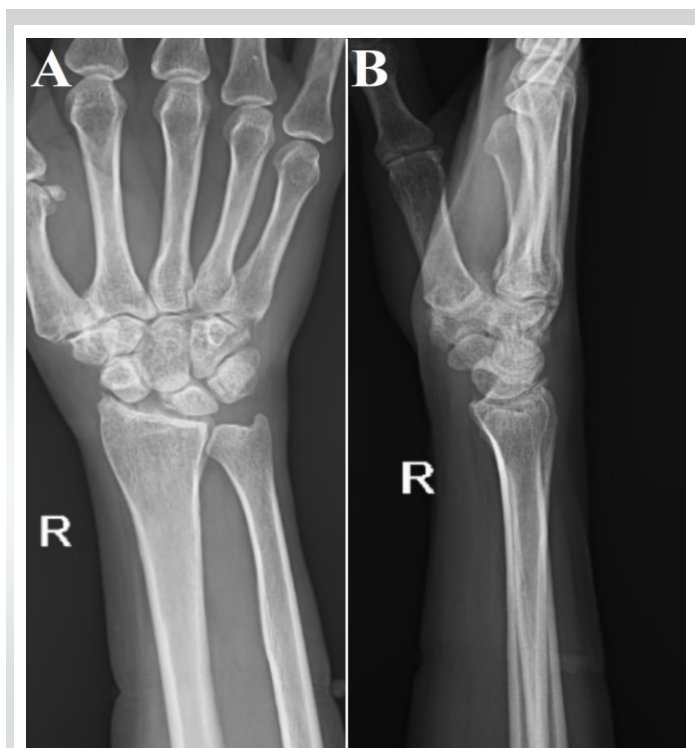Department of Orthopaedics, ACS Medical College and Hospital, Dr. MGR Educational and Research Institute, Chennai, Tamil Nadu, India.

**E-mail:** madhanjeyaraman@gmail.com

Submitted: 19/09/2023; Review: 07/10/2023; Accepted: November 2023; Published: December 2023

DOI: <https://doi.org/10.13107/jocr.2023.v13.i12.4110>

This is an open access journal, and articles are distributed under the terms of the Creative Commons Attribution-NonCommercial-ShareAlike 4.0 License <https://creativecommons.org/licenses/by-nc-sa/4.0/>, which allows others to remix, tweak, and build upon the work non-commercially, as long as appropriate credit is given and the new creations are licensed under the identical terms



**Figure 1:** (a) Anteroposterior radiograph of the wrist showing decreased radio-scaphoid joint space and increased scapholunate distance (Terry Thomas Sign). (b) Lateral radiograph of the wrist showing dorsal tilt of lunate, indicating the presence of dorsal intercalated segment instability.

Watson's scaphoid shift test was positive. Her grip strength was found to be 8 kg less than the contralateral side.

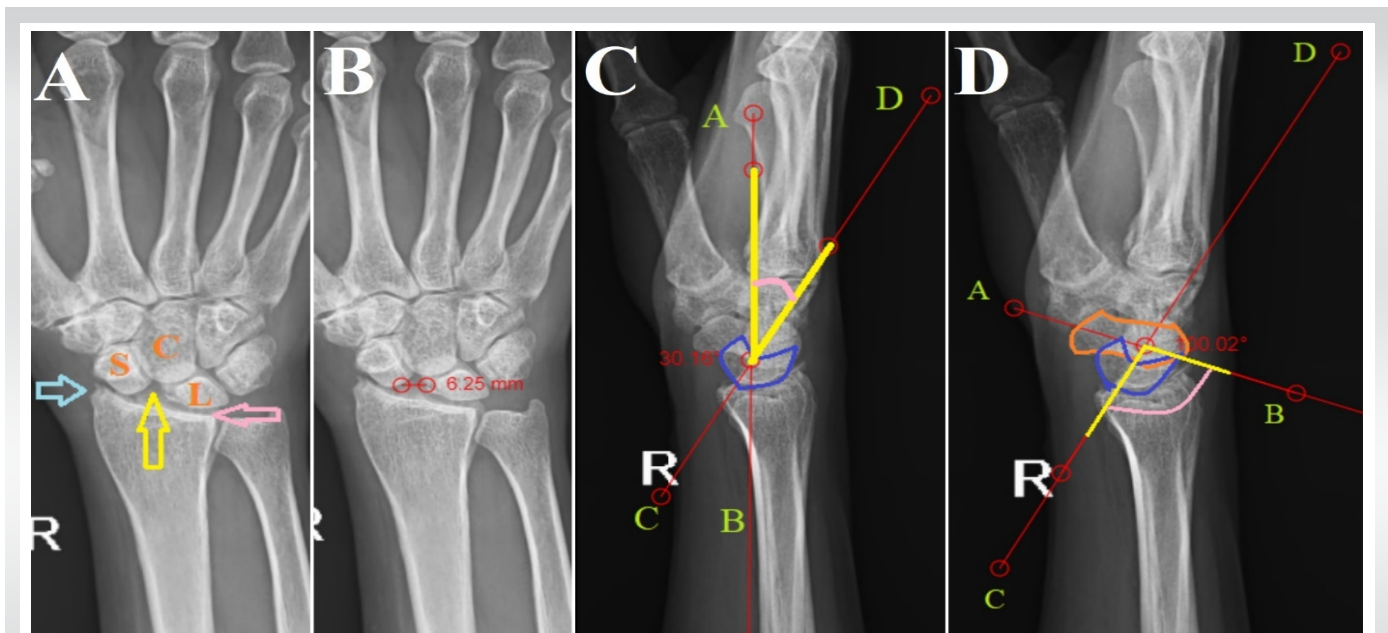
Her blood parameters including rheumatoid profile were found to be within normal limits. Radiographs of the wrist revealed scapholunate diastasis, arthritis of radio-scaphoid joint (Fig. 1a), and dorsal intercalated segment instability (DISI) (Fig. 1b). On further analysis of the radiographs, radial styloid beaking, and migration of capitate proximally into the space created by the scapholunate dissociation were also noted (Fig. 2a). Radiolunate joint space appeared normal. The scapholunate diastasis (Terry Thomas Sign) was measured and found to be 6.25 mm (Fig. 2b), which is normally supposed to be <3 mm. The lunate was found to be dorsally tilted about 30° from neutral (Fig. 2c), indicating the DISI deformity. The scapholunate angle was measured to be 100° (Fig. 2d), while it is normally expected to be between 30° and 60°. She was therefore diagnosed with SLAC. As per the Watson and Ballet classification of SLAC, it was classified as grade II, the radio-scaphoid joint was involved, but the capitulunate joint appeared normal [8]. She underwent conservative management with non-steroidal anti-inflammatory drugs for 2 months but only had partial relief of symptoms. She was then given a local corticosteroid injection and the wrist was splinted for 1 month. She had satisfactory pain relief allowing her to return to her normal activities. The range of movements of the wrist

improved to palmar flexion of 70°, dorsiflexion of 60°, ulnar deviation of 40°, and radial deviation of 15°. Correspondingly her grip strength also improved and was found to be only 5 kg less than the contralateral side when measured 1 month following the corticosteroid injection. This was sufficient for her to be able to carry on her routine daily activities and vocation without pain, and hence, no surgical intervention was performed during the 3 years of follow-up.

## Discussion

SLAC is a wrist condition characterized by progressive instability, deformity, and arthritis due to chronic separation between the lunate and scaphoid carpal bones. SLAC is often misdiagnosed [9]. Early and accurate diagnosis of SLAC is crucial to prevent worsening symptoms, preserve wrist function, and reduce the need for invasive treatments. SLAC can be diagnosed with simple radiographs of the wrist but is commonly misdiagnosed as general wrist arthritis or scaphoid non-union advanced collapse (SNAC) [10]. Not all wrist osteoarthritis represents SLAC patterns; in fact, less than half of wrist osteoarthritis fall into the category of SLAC arthritis [11]. SLAC and SNAC can also be differentiated without requiring a magnetic resonance imaging (MRI). SLAC involves both radiocarpal and mid-carpal joints with a widened scapholunate gap, while SNAC primarily affects the radioscaphoid joint with a widened scapholunate gap but maintains a relatively normal radiocarpal joint space [12]. Our case report demonstrates that a careful radiological analysis can thus be sufficient to diagnose SLAC. Although MRI does make diagnosis easier [13], other studies have shown the reliability of diagnosis of SLAC based on radiographs alone [14, 15].

There are several treatment options for SLAC with no clear consensus on the most appropriate treatment algorithm [16]. Conservative treatment options include non-steroidal anti-inflammatory medications and splinting. Less invasive treatment options such as corticosteroid injections or injections of amniotic membrane and umbilical cord particulate have also been explored [17, 18]. Four-corner arthrodesis and proximal row carpectomy are the most commonly done surgical techniques for the management of SLAC [19]. Newer individualized options, such as osteochondral grafting in combination with proximal row carpectomy, arthroscopic distal resection of the scaphoid [20], and arthroscopic interposition tendon arthroplasty have been introduced in recent times [21]. With the availability of so many treatment options, it becomes imperative that the surgeon uses a classification or grading system to guide the treatment. The Watson and Ballet classification system remains the most commonly used classification system for the SLAC wrist [22].



**Figure 2:** In-depth radiological analysis. (a) Radial styloid beaking (blue arrow), decreased joint space between scaphoid (s) and scaphoid fossa of the radius, diastasis between scaphoid and lunate (l) with proximal migration of capitate (c) into the space created by the scapholunate dissociation (yellow arrow) are noted. Joint space between lunate and radius (pink arrow) appears to be normal. (b) Distance between the mid-point of scaphoid and lunate measured to be 6.25 mm, which is above the normal limit of 3 mm. (c) Measurement of lunate dorsiflexion on lateral wrist radiograph. Line AB is drawn parallel to the vertical axis of the radius, and passing through the center of the lunate. Line CD is drawn along the mid-axis of the lunate (blue border). The angle between the two lines (pink) is the dorsal tilt of lunate, measured to be 30°. Dorsal tilt of lunate >10° indicates DISI. (d) Measurement of scapholunate angle. Line AB is drawn along the long axis of the scaphoid (orange border). Line CD is drawn along the mid-axis of the lunate (blue border). The angle formed between the two lines (pink) is the scapholunate angle. It is measured to be 100°. Scapholunate angle is normally between 30° and 60°.

This radiographic classification of SLAC wrist has proven to have moderate reliability and reproducibility, thus alleviating the necessity of an MRI [14].

### Conclusion

This case report demonstrates that the accurate diagnosis and grading of SLAC can be achieved with just clinical examination and radiographic analysis. If identified early, it can be managed successfully without the need for surgical procedures in some cases. This simple approach to the management of SLAC demonstrates that it can be effectively managed even by general

orthopedicians if awareness about it is increased and is picked up early.

### Clinical Message

1. SLAC occurs as a result of neglected scapholunate ligament injury
2. Radiographs show radial beaking, decreased radio-scaphoid joint space, scapholunate diastasis, and DISI deformity, while the radiolunate joint is typically spared
3. Identification of the signs on radiographs eliminates the need for higher imaging modalities.

**Declaration of patient consent:** The authors certify that they have obtained all appropriate patient consent forms. In the form, the patient has given the consent for his/ her images and other clinical information to be reported in the journal. The patient understands that his/ her names and initials will not be published and due efforts will be made to conceal their identity, but anonymity cannot be guaranteed.

**Conflict of interest:** Nil **Source of support:** None

### References

1. Lane R, Tafti D, Varacallo M. Scapholunate advanced collapse. In: StatPearls. StatPearls Publishing; 2023. Available from: <https://www.ncbi.nlm.nih.gov/books/NBK537124> [Last accessed on 2023 Sep 18].
2. Pomeranz SJ, Salazar P. Scapholunate advanced collapse. J Surg Orthop Adv 2015;24:140-3.
3. Ault DL, Mann DJ, Troutner AM, Kettner NW. Post-traumatic scapholunate advanced collapse of the wrist: A case report. J Chiropr Med 2018;17:128-34.
4. Pai SN, Kumar MM. Isolated lunate dislocation. BMJ Case



Rep 2022;15:e248917.

5. Murphy BD, Nagarajan M, Novak CB, Roy M, McCabe SJ. The epidemiology of scapholunate advanced collapse. *Hand (N Y)* 2020;15:23-6.
6. Lulan J, Marteau E, Bacle G. Wrist osteoarthritis. *Orthop Traumatol Surg Res* 2015;101:S1-9.
7. Wessel LE, Wolfe SW. Scapholunate instability: Current concepts in diagnosis and management classification and treatment considerations-part 2. *J Hand Surg Am* 2023;???:S0363-5023(23)00329-5.
8. Watson HK, Ballet FL. The SLAC wrist: Scapholunate advanced collapse pattern of degenerative arthritis. *J Hand Surg Am* 1984;9:358-65.
9. Tischler BT, Diaz LE, Murakami AM, Roemer FW, Goud AR, Arndt WF 3rd, et al. Scapholunate advanced collapse: A pictorial review. *Insights Imaging* 2014;5:407-17.
10. Trehan SK, Lee SK, Wolfe SW. Scapholunate advanced collapse: Nomenclature and differential diagnosis. *J Hand Surg Am* 2015;40:2085-9.
11. Miller A, Lutsky KF, Shearin J, Cantlon M, Wolfe S, Beredjiklian PK. Radiographic patterns of radiocarpal and midcarpal arthritis. *J Am Acad Orthop Surg Glob Res Rev* 2017;1:e017.
12. Kompoliti E, Prodromou M, Karantanias AH. SLAC and SNAC wrist: The top five things that general radiologists need to know. *Tomography* 2021;7:488-503.
13. Li AE, Lee SK, Rancy SK, Burge AJ, Potter HG, Wolfe SW. Comparison of magnetic resonance imaging and radiographs for evaluation of carpal osteoarthritis. *J Wrist Surg* 2017;6:120-5.
14. Vishwanathan K, Hearnden A, Talwalkar S, Hayton M, Murali SR, Trail IA. Reproducibility of radiographic classification of scapholunate advanced collapse (SLAC) and scaphoid nonunion advanced collapse (SNAC) wrist. *J Hand Surg Eur Vol* 2013;38:780-7.
15. Shah CM, Stern PJ. Scapholunate advanced collapse (SLAC) and scaphoid nonunion advanced collapse (SNAC) wrist arthritis. *Curr Rev Musculoskelet Med* 2013;6:9-17.
16. Strauch RJ. Scapholunate advanced collapse and scaphoid nonunion advanced collapse arthritis-update on evaluation and treatment. *J Hand Surg Am* 2011;36:729-35.
17. Kim SR. Successful treatment of scapholunate advanced collapse: A case report. *Clin Case Rep* 2019;7:1230-2.
18. Kiefhaber TR. Management of scapholunate advanced collapse pattern of degenerative arthritis of the wrist. *J Hand Surg Am* 2009;34:1527-30.
19. Kruse K, Fowler JR. Scapholunate advanced collapse: Motion-sparing reconstructive options. *Orthop Clin North Am* 2016;47:227-33.
20. Zhang Y, Gillis JA, Moran SL. Management of scapholunate advanced collapse and scaphoid nonunion advanced collapse without proximal row carpectomy or four corner fusion. *J Hand Surg Eur Vol* 2021;46:50-7.
21. De Villeneuve Bargemon JB, Merlini L, Mathoulin C, Levadoux M. Arthroscopic radiocarpal tendinous interposition for grade 2 scapholunate advanced collapse - surgical technique. *J Hand Surg Asian Pac Vol* 2022;27:889-94.
22. McLean A, Taylor F. Classifications in brief: Watson and ballet classification of scapholunate advanced collapse wrist arthritis. *Clin Orthop Relat Res* 2019;477:663-6.

**Conflict of Interest:** Nil  
**Source of Support:** Nil

**Consent:** The authors confirm that informed consent was obtained from the patient for publication of this case report

#### How to Cite this Article

Pai SN, Jeyaraman N, Jayakumar T, Jeyaraman M. Scapholunate Advanced Collapse Wrist – Keeping it Simple – A Case Report. *Journal of Orthopaedic Case Reports* 2023 December;13(12): 137-140.

