

# Targeted next-generation sequencing identifies two novel *COL2A1* gene mutations in Stickler syndrome with bilateral retinal detachment

XINHUA HUANG<sup>1\*</sup>, YING LIN<sup>1\*</sup>, CHUAN CHEN<sup>1,2\*</sup>, YI ZHU<sup>1,2\*</sup>, HONGBIN GAO<sup>3,4</sup>,  
TAO LI<sup>1</sup>, BINGQIAN LIU<sup>1</sup>, CANCAN LYU<sup>1,5</sup>, YING HUANG<sup>1</sup>, QINGXIU WU<sup>1</sup>,  
HAICHUN LI<sup>1</sup>, CHENJIN JIN<sup>1</sup>, XIAOLING LIANG<sup>1</sup> and LIN LU<sup>1</sup>

<sup>1</sup>State Key Laboratory of Ophthalmology, Zhongshan Ophthalmic Center, Sun Yat-sen University, Guangzhou, Guangdong 510060, P.R. China; <sup>2</sup>Department of Molecular and Cellular Pharmacology, University of Miami Miller School of Medicine, Miami, FL 33136, USA; <sup>3</sup>Department of Toxicology, School of Public Health and Tropical Medicine, Southern Medical University, Guangzhou, Guangdong 510515; <sup>4</sup>Guangdong Laboratory Animals Monitoring Institute, Key Provincial Laboratory of Guangdong Laboratory Animals, Guangzhou, Guangdong 510663, P.R. China; <sup>5</sup>Department of Ophthalmology, Bascom Palmer Eye Institute, University of Miami Miller School of Medicine, Miami, FL 33136, USA

Received February 2, 2018; Accepted June 19, 2018

DOI: 10.3892/ijmm.2018.3752

**Abstract.** Stickler syndrome is a group of inherited connective tissue disorders characterized by distinctive facial and ocular abnormalities, hearing loss and early-onset arthritis. The aim of the present study was to investigate the genetic changes in two Chinese patients with Stickler syndrome, manifested as bilateral retinal detachment and peripheral retinal degeneration. Complete ophthalmic examinations, including best-corrected visual acuity, slit-lamp examination and fundus examination, were performed. Genomic DNA was extracted from leukocytes of the peripheral blood collected from the patients, their unaffected family members and 200 unrelated control subjects from the same population. Next-generation sequencing of established genes associated with ocular disease was performed. A heterozygous collagen type II  $\alpha 1$  chain (*COL2A1*) mutation c.1310G>C (p.R437P) in exon 21 was identified in Family 1 and a heterozygous *COL2A1* mutation

c.2302-1G>A in intron 34 was identified in Family 2. The functional effects of the mutations were assessed by polymorphism phenotyping (PolyPhen) and sorting intolerant from tolerant (SIFT) analysis. The c.1310G>C mutation was predicted to damage protein structure and function, and the c.2302-1G>A mutation was predicted to result in a splicing defect. The findings of the current study expand the established mutation spectrum of *COL2A1*, and may facilitate genetic counseling and development of therapeutic strategies for patients with Stickler syndrome.

## Introduction

Stickler syndrome [Online Mendelian Inheritance in Man (OMIM) nos. 108300, 609508, 604841, 184840, 614134 and 614284], first reported in 1965 by Stickler *et al* (1), is a group of inherited connective tissue disorders, with an incidence of 1 in 10,000 (2,3). Stickler syndrome is frequently misdiagnosed due to its widely varied clinical manifestations, which may resemble other diseases (4,5). It commonly involves distinctive ocular and facial abnormalities, hearing loss and joint problems (3,6-8). Patients with Stickler syndrome typically present with shallow supraorbital ridges, hypoplastic short nose with anteverted nares, buphthalmic eyes, a flat hypoplastic midface with a depressed nasal bridge, long philtrum and micrognathia (9).

Stickler syndrome is caused by mutations in collagen genes during fetal development, and can be divided into various subtypes based on the clinical manifestations and underlying genetic mutations (10). The most common form, Type 1 Stickler syndrome, is caused by a collagen type II  $\alpha 1$  chain (*COL2A1*) mutation (OMIM no. 120140), and is characterized by membranous vitreous anomaly and megalophthalmos (11,12). Type 2 Stickler syndrome with

---

*Correspondence to:* Professor Xiaoling Liang or Professor Lin Lu, State Key Laboratory of Ophthalmology, Zhongshan Ophthalmic Center, Sun Yat-Sen University, 54 South Road, Guangzhou, Guangdong 510060, P.R. China  
E-mail: liangxlsums@qq.com  
E-mail: drlulinocular@126.com

\*Contributed equally

**Key words:** Stickler syndrome, collagen type II  $\alpha 1$  chain, mutation, retinal detachment, peripheral retinal degeneration, next-generation sequencing

an underlying collagen type XI  $\alpha 1$  chain (*COL11A1*) mutation (OMIM no. 120280) accounts for a minority of patients and presents with a typical beaded vitreous phenotype (13). Type 3 or non-ocular Stickler syndrome, caused by collagen type XI  $\alpha 2$  chain (*COL11A2*) mutation (OMIM no. 120290), often manifests as systemic malformations, including midface hypoplasia and osteoarthritis (14,15). Type 4 Stickler syndrome, caused by collagen type IX  $\alpha 1$  chain (*COL9A1*) or collagen type IX  $\alpha 2$  chain (*COL9A2*) mutation (OMIM no. 120210), is associated with sensorineural deafness, myopia, vitreoretinopathy and epiphyseal dysplasia (16).

Stickler syndrome can lead to a variety of ocular abnormalities, including vitreoretinal degeneration, retinal detachment, cataract, ocular hypertension and high myopia (17). The development of Stickler syndrome is progressive and can ultimately lead to blindness (3). The molecular mechanism of Stickler syndrome is not fully characterized. However, type 1 Stickler syndrome arises from aberrant type II collagen, which is the major collagen type synthesized in the adult human vitreous (18). Under physiological conditions, the strongly adherent collagen fibrils (typically types II, XI and IX) are interspersed in the extracellular matrix, which is predominantly composed of water and glycosaminoglycans. The interaction between collagen and hyaluronan, the most prevalent glycosaminoglycan in the vitreous, provides swelling pressure required to maintain the ocular structure (19). Mutation in the *COL2A1* gene can result in an abnormal fibrillar lamellar structure of the vitreous gel (20), disrupt collagen helices, alter fibrillogenesis and reduce collagen secretion (20,21).

Characterizing the Stickler syndrome phenotypes and identifying the underlying genetic mutations are initial steps to understand the disease pathogenesis and will be useful for future genetic counseling. The current study aimed to characterize the clinical presentation of two young patients with Stickler syndrome and bilateral retinal detachment, and to identify the genetic changes in these patients using targeted next-generation sequencing (NGS).

## Materials and methods

**Study subjects and clinical examinations.** Two patients from two different families presenting with bilateral retinal detachment and peripheral retinal degeneration were recruited in the present study. All experimental protocols were performed according to the guidelines approved by the Ethics Committee of Zhongshan Ophthalmic Center (Guangzhou, China), and in accordance with the Declaration of Helsinki. Informed consent was obtained from all subjects.

Complete ophthalmic examinations were performed at the Zhongshan Ophthalmic Center. The best-corrected visual acuity (BCVA) was measured using the ETDRS chart (Precision Vision, Woodstock, IL, USA). Anterior segment images were obtained using a BX 900 Slit Lamp (Haag-Streit, Bern, Switzerland). Anterior segment measurements were performed using Pentacam HR version 70700 (Oculus, Wetzlar, Germany). Fundus photography was performed using Heidelberg Retina Angiograph (Heidelberg Engineering, Heidelberg, Germany) or ultra-wide-field 200Tx Optos system (Optos plc, Dunfermline, UK). Optical coherence tomography (OCT) was performed by Cirrus HD OCT (Zeiss GmbH, Jena,

Germany). Physical examinations were performed to exclude systemic diseases. Venous blood samples from the patients, their unaffected family members and 200 unrelated control subjects from the same population were collected.

**Target capture, NGS and mutation validation.** NGS was used to identify the potential variants. The parameters used for whole exome sequencing have been described in our previous studies (22,23). Identified mutations were validated using conventional polymerase chain reaction (PCR)-based sequencing methods (24-29,23). Briefly, exons 21-22 and 33-34 of the *COL2A1* gene were amplified by PCR with respective primers (Table I). PCRs were conducted in 50  $\mu$ l total reaction volume using an ABI2720 system (Thermo Fisher Scientific, Inc., Waltham, MA, USA). The cycling conditions included one cycle at 94°C for 5 min, followed by 40 cycles at 94°C for 45 sec, 59-60°C for 45 sec, 72°C for 45 sec, and one cycle at 72°C for 10 min. The PCR products were sequenced in both directions using an ABI3730 Automated Sequencer (PE Biosystems, Foster City, CA, USA). The sequencing results were analyzed using Seqman (version 2.3; Technelysium Pty Ltd., Brisbane, Australia), and compared with the reference sequences in National Center for Biotechnology Information (NCBI) databases (26-28,30).

**Interpretation of the genetic variants.** To predict the effect of missense variants, polymorphism phenotyping (PolyPhen) and sorting intolerant from tolerant (SIFT) were used to predict the potential impact of an amino acid substitution on the protein structure and function, using physical and comparative considerations (23,31,32). Variants were predicted to be pathogenic when at least one of the two programs predicted deleterious effect of the amino acid substitution on the protein structure and function. The Human Gene Mutation Database ([hgmd.cf.ac.uk/ac/index.php](http://hgmd.cf.ac.uk/ac/index.php)) was used to screen mutations reported in previously published studies. HomoloGene ([ncbi.nlm.nih.gov/homologene](http://ncbi.nlm.nih.gov/homologene)) was used to assess the conservation of the altered amino acid residues across different species (22,33).

## Results

**Clinical presentations of the patients.** The patients reported in the present study were from the southern area of China (the family pedigrees are illustrated in Fig. 1). The clinical manifestations of Patient 1 in Family 1 (II:2 in Fig. 1A) are summarized in Table II. The patient was a 24-year-old female without a known familial history of ocular disease. The BCVA was 0.0 in the right eye and 0.2 in the left eye. Anterior segment photography demonstrated transparent lenses in both eyes. When Patient 1 was 21 years old, she exhibited a decreased vision in the left eye and retinal detachment of the left eye was diagnosed. Fundus photography revealed inferior retinal detachment and peripheral retinal degeneration (Fig. 2A). B-scan indicated localized retinal detachment (white arrow; Fig. 2B). OCT revealed a partially damaged macular area (Fig. 2C). Retinal detachment surgery was performed, and her vision improved. After one year, vision was decreased in the right eye and retinal detachment of the right eye without macular involvement was diagnosed. Fundus

Table I. Primers used for the amplification of *COL2A1* in the current study.

Gene	Exon	Forward (5'-3')	Reverse (5'-3')	Product size (bp)	Annealing temperature (°C)
<i>COL2A1</i>	21-22	GCCAAAGGATCTGCTGTGAG	GCCCTGTTAAGTCTCCTCCA	599	60
<i>COL2A1</i>	33-34	CCTGGGTCCTATGCTCCTG	AGCTTTGGTGAGAGGCTGTA	581	59

*COL2A1*, collagen type II  $\alpha 1$  chain.

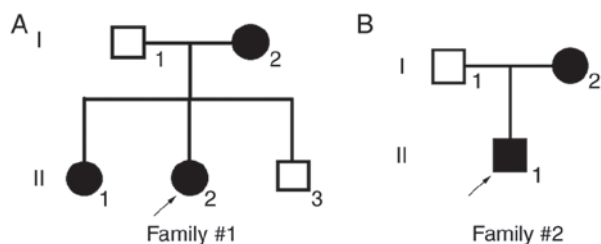


Figure 1. (A and B) Pedigrees of two Chinese families with Stickler syndrome. Square symbols denote males, and circle symbols denote females. The solid symbols indicate ophthalmologist-confirmed Stickler syndrome, and the open symbols indicate unaffected individuals. The arrows point to the proband.

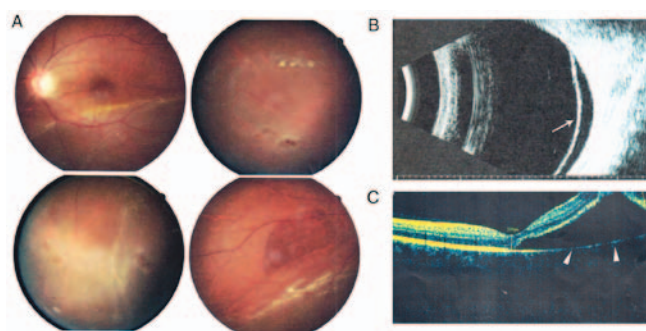


Figure 2. Clinical manifestation of the left eye of Patient 1 (II:2 in Family 1). (A) Fundus imaging shows inferior retinal detachment and peripheral retinal degeneration. (B) B-scan shows localized retinal detachment. (C) OCT shows a partially damaged macular area. OCT, optical coherence tomography.

imaging revealed inferior retinal detachment and peripheral retinal degeneration (Fig. 3A). B-scan indicated localized retinal detachment (white arrow; Fig. 3B). The elder sister of this patient (II:1) also exhibited myopia and peripheral retinal degeneration (Fig. 4).

Patient 2 in Family 2 (II:1 in Fig. 1B) was a 17-year-old male. Retinal detachment of the left eye and the right eye of Patient 2 was diagnosed at 14 and 17 years old, respectively. Following surgery, the BCVA was 0.7 in the right eye and 0.3 in the left eye. Fundus imaging revealed peripheral retinal scars (Fig. 5). The mother of patient 2 also had bilateral retinal detachment. The left eye of the mother was blind at birth and exhibited severe atrophy. Right retinal detachment was diagnosed at 30 years old. Patient 2 and the mother had cleft palate.

**Mutation screening and bioinformatics analysis of the mutations.** A novel heterozygous *COL2A1* mutation c.1310G>C

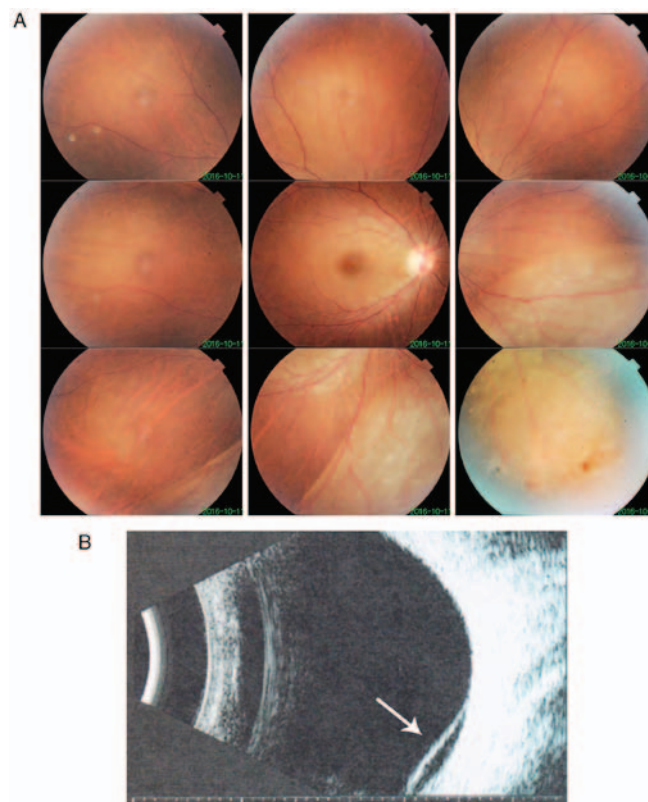


Figure 3. Clinical manifestation of the right eye of Patient 1 (II:2 in Family 1). (A) Fundus photography shows inferior retinal detachment and peripheral retinal degeneration. (B) B-scan displays localized retinal detachment.

(p.R437P) in exon 21 was identified in Family 1 (I:2, II:1, II:2; Table II, Figs. 6 and 7A). Multiple sequence alignment indicated that the arginine residue at position 437 of collagen type II  $\alpha 1$  chain is highly conserved (Fig. 7B). PolyPhen and SIFT predicted that this mutation is damaging (Fig. 7C). A novel heterozygous *COL2A1* mutation c.2302-1G>A in intron 34 was identified in Family 2 (I:2, II:1; Figs. 6 and 7A). This mutation is likely to result in a splicing defect as it occurs at the exon-intron border. These two mutations were not present in the unaffected family members and the other unrelated control subjects from the same population.

## Discussion

The clinical manifestation of Stickler syndrome is heterogeneous (3-5). Retinal detachment is the most severe consequence of Stickler syndrome (34), and there is a high incidence of blindness. Approximately 55-73% of Caucasian patients with a



Table II. Summary of clinical manifestations and mutations in Family 1.

Patient	Sex	Age	BCVA	Optometry	IOP	Lens/Cornea	Fundus	B-scan	OCT	Mutation	Clinical manifestation
I:1	M	48	OD:0.0(0.0); OS:0.0(0.0)	N/A	Normal	Normal	Normal	N/A	N/A	-	
I:2	F	45	OD:0.0(0.0); OS:0.0(0.0)	N/A	Normal	Normal	Normal	N/A	N/A	c.1310G>C (p.R437P)	
II:1	F	24	OD:0.7(0.0); OS:0.7(0.0)	OD:-4.25DS&-0.50DC; OS:-3.75DS&-1.00DC	Normal	Normal	Peripheral retinal degeneration	N/A	N/A	c.1310G>C (p.R437P)	
II:2	F	20	OD:2.0(0.0); OS:2.0(0.2)	OD:-3.00DS&-1.50DC; OS:-1.00DS&-1.00DC	Normal	Normal	Retinal detachment of the right eye	Retinal detachment	Retinal detachment	c.1310G>C (p.R437P)	
II:3	M	19	OD:0.0(0.0); OS:0.0(0.0)	N/A	Normal	Normal	Normal	N/A	N/A	-	

M, male; F, female; N/A, not available; BCVA, best-corrected visual acuity; IOP, intraocular pressure; OCT, optical coherence tomography.

clinical diagnosis of Stickler syndrome exhibit retinal detachment (35,36). Thus, Stickler syndrome should be considered and excluded if a patient presents with multiple peripheral degeneration spots in both eyes (37-40). In the current report, both patients exhibited sequential bilateral retinal detachment and multiple peripheral retinal degeneration at a young age. In Patient 1, the localized retinal detachment of the right eye did not extend to the macular area; thus, the visual impairment was less severe.

The diagnostic criteria for Stickler syndrome have not been well-established (5,10). Adult patients diagnosed with Stickler syndrome typically do not present with typical facial anomalies as children (41). In Family 2, the patient and his mother had cleft palate, which is an important clinical indicator of Stickler syndrome (6,37,42,43). Other typical extraocular collagenopathies include achondrogenesis, hypochondrogenesis and early onset osteoarthritis (44). However, diagnosing Stickler syndrome only based on clinical manifestations is often challenging. Genetic analysis, therefore, is an important tool for the diagnosis of Stickler syndrome, particularly in patients with myopia and peripheral retinal degeneration (12,39,45-47). Early diagnosis and close-follow up will help to decrease the incidence of the retinal detachment (3,38). Currently, the Cambridge prophylactic cryotherapy protocol has been demonstrated to be a safe intervention and can markedly reduce the risk of retinal detachment in patients with Stickler syndrome (48).

Although the affected patients in the present study had different genetic mutations, they exhibited similar clinical presentations of retinal detachment and degeneration. Previous studies have also reported that different mutations in *COL2A1* can lead to similar phenotypes, with various degrees of expressivity (42,49). The majority of *COL2A1* mutations identified in Stickler syndrome are loss-of-function mutations, as they are predicted to result in nonsense-mediated decay of transcripts (42). Splice site mutations, as identified in Family 2 in the current study, are commonly identified in Stickler syndrome, and are likely to cause unusual RNA isoforms with premature stop codons (42). Additionally, silent mutations in *COL2A1* can also result in splicing defects and reading frame shifts (50).

In summary, the present study characterized the clinical presentation of two Chinese families with Stickler syndrome, and identified two novel mutations in the *COL2A1* gene in the affected family members. These findings expand the known mutation spectrums of *COL2A1*, and may facilitate genetic counseling and development of therapeutic strategies for patients with Stickler syndrome.

**Acknowledgements**

Not applicable.

**Funding**

This study was supported by the National Natural Science Foundation of China (grant nos. 81500709, 81570862 and 81670872), Guangzhou Science and Technology Project (grant no. 2014Y2-00064), and the State Scholarship Fund from the China Scholarship Council.

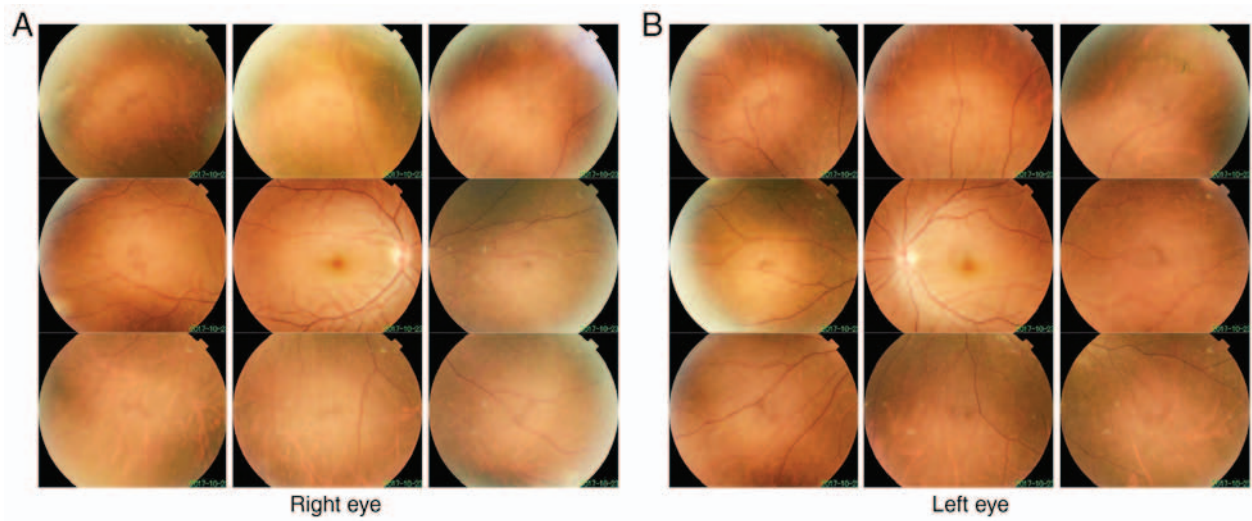


Figure 4. Clinical manifestation of the elder sister of Patient 1 (II:1 in Family 1). Fundus photography shows peripheral retinal degeneration in the upper temporal areas of (A) the right and (B) the left eye.

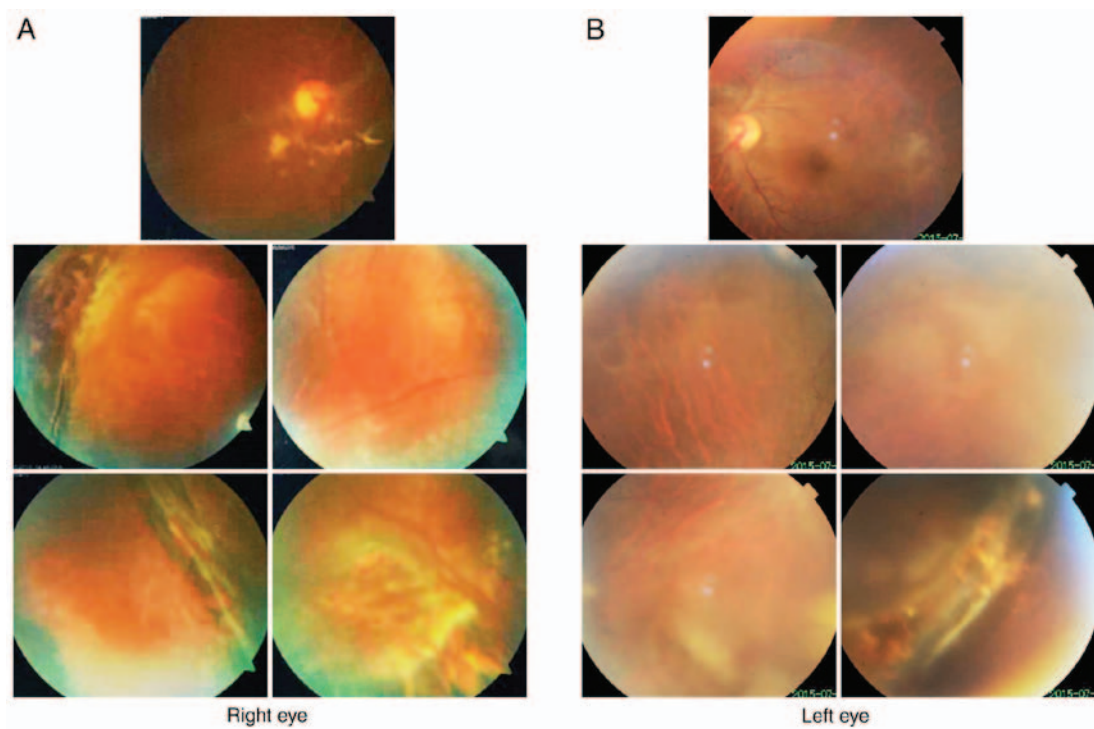


Figure 5. Clinical manifestation of Patient 2 (II:1 in Family 2). Fundus photography shows peripheral retinal scar in (A) the right and (B) the left eye.

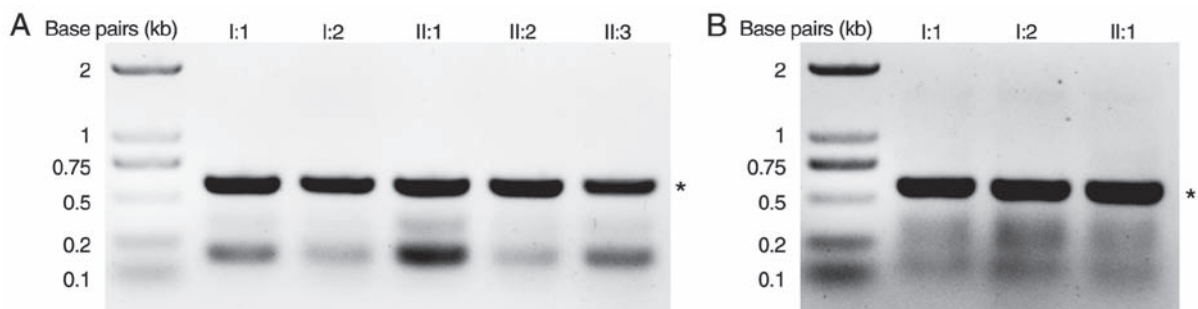


Figure 6. Amplification of exons 21-22 and 33-34 of the *COL2A1* gene by PCR. (A) Exons 21-22 in Family 1 were amplified by PCR, yielding a product of 599 bp (denoted next to the gel image by an asterisk). (B) Exons 33-34 in Family 2 were amplified by PCR, yielding a product of 581 bp (denoted next to the gel image by an asterisk). *COL2A1*, collagen type II  $\alpha 1$  chain; PCR, polymerase chain reaction.

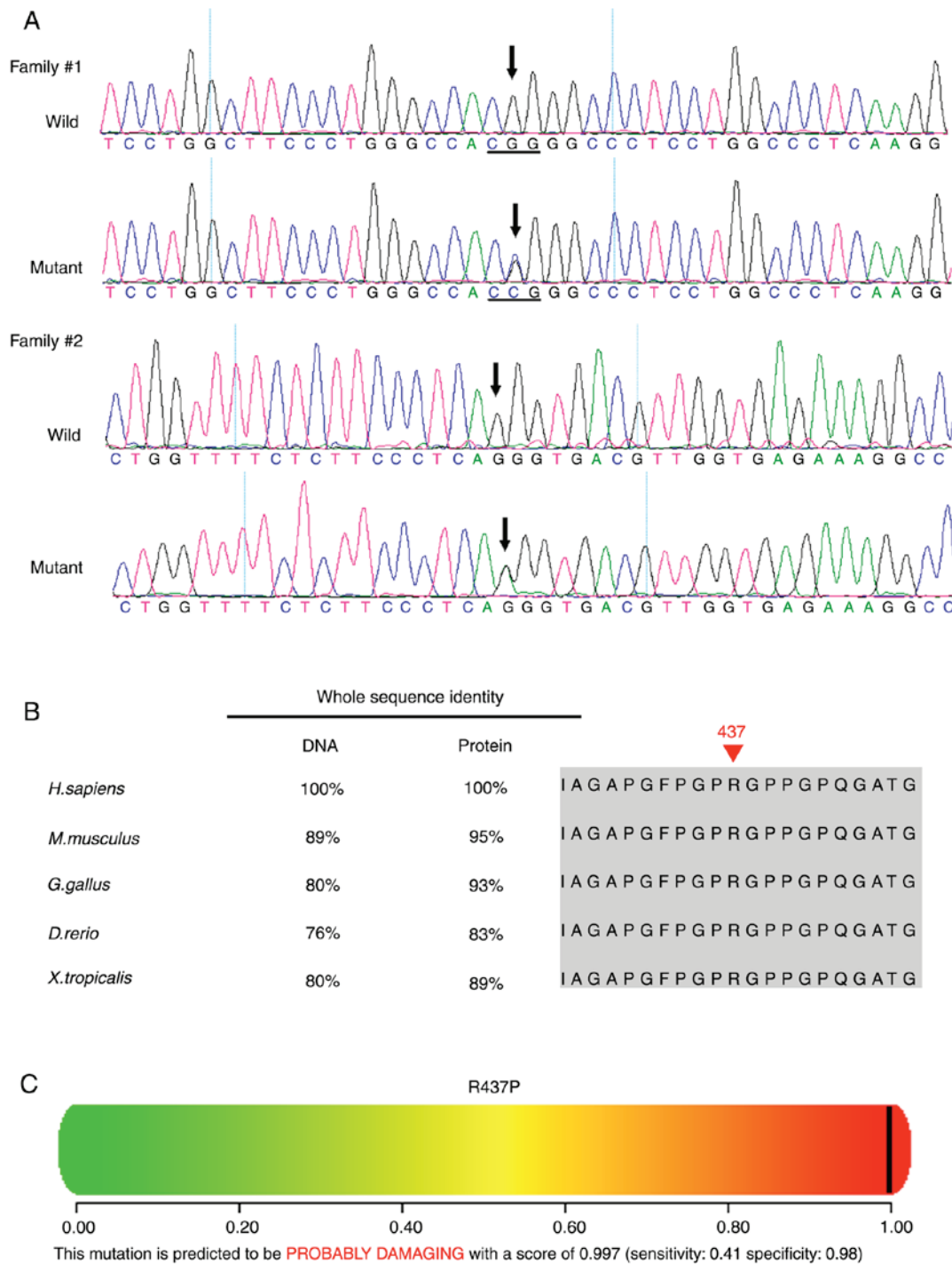


Figure 7. Genetic mutations identified in the two families. (A) A heterozygous *COL2A1* mutation c.1310G>C (p.R437P) in exon 21 was identified in Family 1 (I:2, II:1, II:2). A heterozygous *COL2A1* mutation c.2302-1G>A in intron 34 was identified in Family 2 (I:2, II:1). (B) Multiple sequence alignment of the *COL2A1* gene and collagen type II  $\alpha 1$  protein from different species. The red arrowhead indicates the location of the p.R437P mutation. The Arg 437 residue is highly conserved across species. (C) Polymorphism phenotyping predicts that the amino acid substitution p.R437P is damaging. *COL2A1*, collagen type II  $\alpha 1$  chain.

#### Availability of data and materials

The analyzed datasets generated during the study are available from the corresponding author on reasonable request.

#### Authors' contributions

XH, YL, TL, CJ, XL and LL analyzed and interpreted the patient data. HG, BL, CL, YH, QW and HL examined the patients and

performed PCR and gene sequence analysis. YL, CC and YZ interpreted the sequencing data, drafted the manuscript and revised it critically. All authors read and approved the final manuscript.

#### Ethics approval and consent to participate

All experimental protocols were approved by the ethics committee of Zhongshan Ophthalmic Center (Guangzhou, China). Informed consent was obtained from all subjects.



## Patient consent for publication

Not applicable.

## Competing interests

The authors declare that they have no competing interests.

## References

- Stickler GB, Belau PG, Farrell FJ, Joes JD, Pugh DG, Steinberg AG and Ward LE: Hereditary progressive arthro-ophthalmopathy. *Mayo Clin Proc* 40: 433-455, 1965.
- Robin NH, Moran RT and Ala-Kokko L: Stickler syndrome. In: *GeneReviews*<sup>®</sup> Adam MP, Ardinger HH, Pagon RA, *et al* (eds). Seattle, WA, 1993.
- Rishi P, Maheshwari A and Rishi E: Stickler syndrome. *Indian J Ophthalmol* 63: 614-615, 2015.
- Bennett JT and McMurray SW: Stickler syndrome. *J Pediatr Orthop* 10: 760-763, 1990.
- Aylward B, daCruz L, Ezra E, Sullivan P, MacLaren RE, Charteris D, Gregor Z, Bainbridge J and Minihan M: Stickler syndrome. *Ophthalmology* 115: 1636-1637, 2008.
- Snead MP, McNinch AM, Poulson AV, Bearcroft P, Silverman B, Gomersall P, Parfect V and Richards AJ: Stickler syndrome, ocular-only variants and a key diagnostic role for the ophthalmologist. *Eye (Lond)* 25: 1389-1400, 2011.
- Savasta S, Salpietro V, Spartà MV, Foadelli T, Laino D, Lobefalo L, Marseglia GL and Verrotti A: Stickler syndrome associated with epilepsy: Report of three cases. *Eur J Pediatr* 174: 697-701, 2015.
- Goyal M, Kapoor S, Ikegawa S and Nishimura G: Stickler syndrome type 1 with short stature and atypical ocular manifestations. *Case Rep Pediatr* 2016: 3198597, 2016.
- Faber J, Winterpacht A, Zabel B, Gnoinski W, Schinzel A, Steinmann B and Superti-Furga A: Clinical variability of Stickler syndrome with a COL2A1 haploinsufficiency mutation: Implications for genetic counselling. *J Med Genet* 37: 318-320, 2000.
- Ang A, Ung T, Puvanachandra N, Wilson L, Howard F, Ryalls M, Richards A, Meredith S, Laidlaw M, Poulson A, *et al*: Vitreous phenotype: A key diagnostic sign in Stickler syndrome types 1 and 2 complicated by double heterozygosity. *Am J Med Genet A* 143A: 604-607, 2007.
- Alexander P, Poulson A, McNinch A, Richards A and Snead M: Type I membranous anomaly in Stickler syndrome. *Ophthalmic Genet* 39: 147, 2018.
- Leung L, Hyland JC, Young A, Goldberg MF and Handa JT: A novel mutation in intron 11 of the COL2A1 gene in a patient with type 1 Stickler syndrome. *Retina* 26: 106-109, 2006.
- Richards AJ, Yates JR, Williams R, Payne SJ, Pope FM, Scott JD and Snead MP: A family with Stickler syndrome type 2 has a mutation in the COL11A1 gene resulting in the substitution of glycine 97 by valine in  $\alpha 1$  (XI) collagen. *Hum Mol Genet* 5: 1339-1343, 1996.
- Brunner HG, van Beersum SE, Warman ML, Olsen BR, Ropers HH and Mariman EC: A Stickler syndrome gene is linked to chromosome 6 near the COL11A2 gene. *Hum Mol Genet* 3: 1561-1564, 1994.
- Giedion A, Brandner M, Lecannellier J, Muhar U, Prader A, Sulzer J and Zweymüller E: Oto-spondylo-megaepiphyseal dysplasia (OSMED). *Helv Paediatr Acta* 37: 361-380, 1982.
- Van Camp G, Snoeckx RL, Hilgert N, van den Ende J, Fukuoka H, Wagatsuma M, Suzuki H, Smets RM, Vanhoenacker F, Declau F, *et al*: A new autosomal recessive form of Stickler syndrome is caused by a mutation in the COL9A1 gene. *Am J Hum Genet* 79: 449-457, 2006.
- Rose PS, Levy HP, Liberfarb RM, Davis J, Szymko-Bennett Y, Rubin BI, Tsilou E, Griffith AJ and Francomano CA: Stickler syndrome: Clinical characteristics and diagnostic criteria. *Am J Med Genet A* 138A: 199-207, 2005.
- Barat-Houari M, Sarrabay G, Gatinois V, Fabre A, Dumont B, Genevieve D and Touitou I: Mutation update for COL2A1 gene variants associated with type II collagenopathies. *Hum Mutat* 37: 7-15, 2016.
- Scott JE: The chemical morphology of the vitreous. *Eye (Lond)* 6: 553-555, 1992.
- Richards AJ, Baguley DM, Yates JR, Lane C, Nicol M, Harper PS, Scott JD and Snead MP: Variation in the vitreous phenotype of Stickler syndrome can be caused by different amino acid substitutions in the X position of the type II collagen Gly-X-Y triple helix. *Am J Hum Genet* 67: 1083-1094, 2000.
- Prockop DJ and Kivirikko KI: Collagens: Molecular biology, diseases, and potentials for therapy. *Annu Rev Biochem* 64: 403-434, 1995.
- Lin Y, Gao H, Chen C, Zhu Y, Li T, Liu B, Ma C, Jiang H, Li Y, Huang Y, *et al*: Clinical and next-generation sequencing findings in a Chinese family exhibiting severe familial exudative vitreo-retinopathy. *Int J Mol Med* 41: 773-782, 2018.
- Li T, Lin Y, Gao H, Chen C, Zhu Y, Liu B, Lian Y, Li Y, Zhou W, Jiang H, *et al*: Two heterozygous mutations identified in one Chinese patient with bilateral macular coloboma. *Mol Med Rep* 16: 2505-2510, 2017.
- Lin Y, Liang X, Ai S, Chen C, Liu X, Luo L, Ye S, Li B, Liu Y and Yang H: FGFR2 molecular analysis and related clinical findings in one Chinese family with Crouzon syndrome. *Mol Vis* 18: 449-454, 2012.
- Lin Y, Liu X, Yu S, Luo L, Liang X, Wang Z, Chen C, Zhu Y, Ye S, Yan H and Liu Y: PAX6 analysis of two sporadic patients from southern China with classic aniridia. *Mol Vis* 18: 2190-2194, 2012.
- Lin Y, Gao H, Ai S, Eswarakumar JVP, Chen C, Zhu Y, Li T, Liu B, Liu X, Luo L, *et al*: C278F mutation in FGFR2 gene causes two different types of syndromic craniosynostosis in two Chinese patients. *Mol Med Rep* 16: 5333-5337, 2017.
- Lin Y, Gao H, Ai S, Eswarakumar JVP, Zhu Y, Chen C, Li T, Liu B, Jiang H, Liu Y, *et al*: FGFR2 mutations and associated clinical observations in two Chinese patients with Crouzon syndrome. *Mol Med Rep* 16: 5841-5846, 2017.
- Lin Y, Li T, Gao H, Lian Y, Chen C, Zhu Y, Li Y, Liu B, Zhou W, Jiang H, *et al*: Bestrophin 1 gene analysis and associated clinical findings in a Chinese patient with Best vitelliform macular dystrophy. *Mol Med Rep* 16: 4751-4755, 2017.
- Lin Y, Ai S, Chen C, Liu X, Luo L, Ye S, Liang X, Zhu Y, Yang H and Liu Y: Ala344Pro mutation in the FGFR2 gene and related clinical findings in one Chinese family with Crouzon syndrome. *Mol Vis* 18: 1278-1282, 2012.
- Burland TG: DNASTAR's Lasergene sequence analysis software. *Methods Mol Biol* 132: 71-91, 2000.
- Adzhubei IA, Schmidt S, Peshkin L, Ramensky VE, Gerasimova A, Bork P, Kondrashov AS and Sunyaev SR: A method and server for predicting damaging missense mutations. *Nat Methods* 7: 248-249, 2010.
- Kumar P, Henikoff S and Ng PC: Predicting the effects of coding non-synonymous variants on protein function using the SIFT algorithm. *Nat Protoc* 4: 1073-1081, 2009.
- Lin Y, Li T, Ma C, Gao H, Chen C, Zhu Y, Liu B, Lian Y, Huang Y, Li H, *et al*: Genetic variations in Bestrophin 1 and associated clinical findings in two Chinese patients with juvenile onset and adult onset best vitelliform macular dystrophy. *Mol Med Rep* 17: 225-233, 2018.
- Ang A, Poulson AV, Goodburn SF, Richards AJ, Scott JD and Snead MP: Retinal detachment and prophylaxis in type 1 Stickler syndrome. *Ophthalmology* 115: 164-168, 2008.
- Wang X, Jia X, Xiao X, Li S, Li J, Li Y, Wei Y, Liang X and Guo X: Mutation survey and genotype-phenotype analysis of COL2A1 and COL11A1 genes in 16 Chinese patients with Stickler syndrome. *Mol Vis* 22: 697-704, 2016.
- Vilaplana F, Muiños SJ, Nadal J, Elizalde J and Mojal S: Stickler syndrome. Epidemiology of retinal detachment. *Arch Soc Esp Ophthalmol* 90: 264-268, 2015 (In English, Spanish).
- Antunes RB, Alonso N and Paula RG: Importance of early diagnosis of Stickler syndrome in newborns. *J Plast Reconstr Aesthet Surg* 65: 1029-1034, 2012.
- Wilson MC, McDonald-McGinn DM, Quinn GE, Markowitz GD, LaRossa D, Pacuraru AD, Zhu X and Zackai EH: Long-term follow-up of ocular findings in children with Stickler's syndrome. *Am J Ophthalmol* 122: 727-728, 1996.
- Watanabe Y, Ueda M and Adachi-Usami E: Retinal detachment in identical twins with Stickler syndrome type 1. *Br J Ophthalmol* 80: 976-981, 1996.
- Bowling EL, Brown MD and Trundle TV: The Stickler syndrome: Case reports and literature review. *Optometry* 71: 177-182, 2000.
- De Keyser TH, De Veuster I and Smets RM: Stickler syndrome: An underdiagnosed disease. Report of a family. *Bull Soc Belge Ophthalmol* 45-49, 2011.

42. Hoornaert KP, Vereecke I, Dewinter C, Rosenberg T, Beemer FA, Leroy JG, Bendix L, Björck E, Bonduelle M, Boute O, *et al*: Stickler syndrome caused by COL2A1 mutations: Genotype-phenotype correlation in a series of 100 patients. *Eur J Hum Genet* 18: 872-880, 2010.
43. Lee KH and Hayward P: Retrospective review of Stickler syndrome patients with cleft palate 1997-2004. *ANZ J Surg* 78: 764-766, 2008.
44. Parke DW: Stickler syndrome: Clinical care and molecular genetics. *Am J Ophthalmol* 134: 746-748, 2002.
45. Brown DM, Vandenberg K, Kimura AE, Weingeist TA, Sheffield VC and Stone EM: Novel frameshift mutations in the procollagen 2 gene (COL2A1) associated with Stickler syndrome (hereditary arthro-ophthalmopathy). *Hum Mol Genet* 4: 141-142, 1995.
46. Yoshida S, Yamaji Y, Kuwahara R, Yoshida A, Hisatomi T, Ueno A and Ishibashi T: Novel mutation in exon 2 of COL2A1 gene in Japanese family with Stickler Syndrome type I. *Eye (Lond)* 20: 743-745, 2006.
47. Higuchi Y, Hasegawa K, Yamashita M, Tanaka H and Tsukahara H: A novel mutation in the COL2A1 gene in a patient with Stickler syndrome type 1: A case report and review of the literature. *J Med Case Rep* 11: 237, 2017.
48. Fincham GS, Paisea L, Carroll C, McNinch AM, Poulson AV, Richards AJ, Scott JD and Snead MP: Prevention of retinal detachment in Stickler syndrome: The Cambridge prophylactic cryotherapy protocol. *Ophthalmology* 121: 1588-1597, 2014.
49. Kondo H, Matsushita I, Nagata T, Hayashi T, Kakinoki M, Uchio E, Kondo M, Ohji M and Kusaka S: Novel mutations in the COL2A1 gene in Japanese patients with Stickler syndrome. *Hum Genome Var* 3: 16018, 2016.
50. Richards AJ, Laidlaw M, Meredith SP, Shankar P, Poulson AV, Scott JD and Snead MP: Missense and silent mutations in COL2A1 result in Stickler syndrome but via different molecular mechanisms. *Hum Mutat* 28: 639, 2007.



This work is licensed under a Creative Commons Attribution-NonCommercial-NoDerivatives 4.0 International (CC BY-NC-ND 4.0) License.