

Case Report

---

# Coexistence of Idiopathic Intracranial Hypertension with Unilateral Duane Retraction Syndrome Type 1 in an Adult Female

Abdullah I. Almater<sup>a</sup> Jawaher Jehad Alwatban<sup>b</sup> Arwa Z. Alromaih<sup>a</sup>  
Motazz Alarfaj<sup>b, c</sup> Majed Al-Obailan<sup>a</sup>

<sup>a</sup>Department of Ophthalmology, College of Medicine, King Saud University, Riyadh, Saudi Arabia; <sup>b</sup>King Khaled Eye Specialist Hospital, Riyadh, Saudi Arabia; <sup>c</sup>Department of Ophthalmology, College of Medicine, Imam Abdulrahman Bin Faisal University, Dammam, Saudi Arabia

## Keywords

Duane retraction syndrome · Idiopathic intracranial hypertension · Pseudotumor cerebri

## Abstract

Idiopathic intracranial hypertension (IIH) is a poorly understood condition, and its presentation can coexist with other diseases. Simultaneous IIH and Duane retraction syndrome (DRS) type 1 have never been reported to coexist in an adult patient. Herein, we report a 32-year-old obese female with a history of chronic renal failure who had a renal transplant rejection 6 years prior to presentation and was treated with oral steroids and immunosuppressive medications. She began to experience signs and symptoms of increased intracranial pressure (morning headache and binocular horizontal diplopia) and had limited abduction of one eye on examination. The case was later diagnosed as IIH with DRS type 1.

© 2022 The Author(s).  
Published by S. Karger AG, Basel

## Introduction

Idiopathic intracranial hypertension (IIH), often referred to as benign intracranial hypertension, or pseudotumor cerebri is diagnosed by signs and symptoms of isolated increased intracranial pressure (ICP), normal CSF composition despite elevated ICP, and normal

neuroimaging with no other cause for increased ICP. The presence of papilloedema in an overweight female of a childbearing age is a typical presentation of IIH. Further observations on examination may include abducens nerve palsy that results from elevated ICP on the sixth cranial nerve. Abducens nerve palsy is frequently involved due to a benign process with complete recovery within weeks, yet caution is warranted at the time of diagnosis as it may mimic other pathologies. We report the first case of an adult patient simultaneously suffering from chronic renal failure, IIH, and Duane retraction syndrome (DRS) type 1. We highlight the importance of precise evaluation of the clinical signs of DRS and abducent palsy to optimize the management and overall outcome.

## Case Report

A 32-year-old female presented to the emergency department complaining of morning headache and binocular double vision more at distance for 1 week. Past medical history revealed renal transplant 6 years ago for an unknown cause. Similarly, the patient's uncle has undergone a renal transplant at a young age. She had been on multiple medications, including prednisolone 5 mg, azathioprine 50 mg, amlodipine, 20 mg omeprazole, sulfamethoxazole/trimethoprim 80, and valganciclovir 450 mg. The patient-reported recent weight gain of 10 kg in 1 month while taking high-dose steroid for renal transplant rejection. She denied any history of nausea, vomiting, tinnitus, or visual obscuration symptoms.

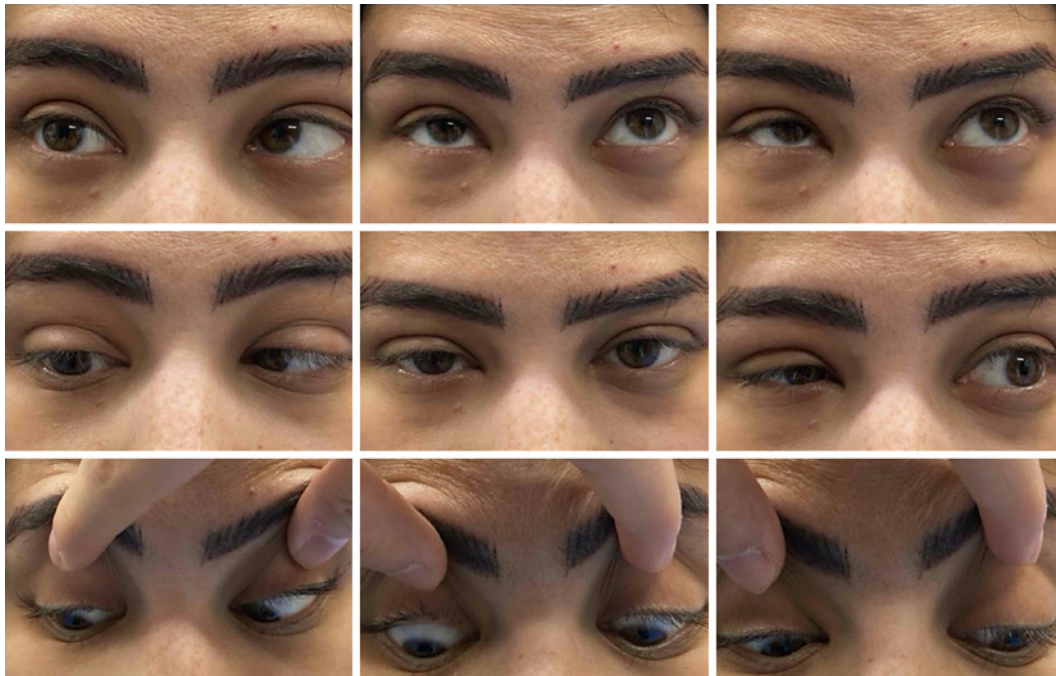
On general examination, she was found to have a cushingoid appearance (obese, short stature, and moon face). Ocular examination revealed a visual acuity of 20/20 and a colour vision of 15/15 in both eyes. Her pupils were reactive to light and near, and no afferent pupillary defect was noticed. Orthoptic examination demonstrated 14 and 16 prism dioptre of esotropia at near and distance, respectively. Her extraocular motility showed –4 limitation on the abduction of the right eye (shown in Fig. 1). Narrowing of the palpebral fissure and globe retraction was evident on adduction of the right eye (shown in Fig. 2). The clinical exam was compatible with unilateral sixth cranial nerve palsy and DRS type 1 in the right eye. Slit-lamp examination of the anterior segment was unremarkable. Her fundus examination showed grade 1 disc swelling and tortuous vessels in both sides and splinter haemorrhage in the right optic nerve.

Her 30-2 Humphrey visual field showed an enlarged blind spot in both eyes. Magnetic resonance imaging showed a bilateral increase in the width of the optic nerve sheaths. Magnetic resonance venography revealed patent cerebral veins and venous sinuses, with no stenosis or thrombosis. She underwent a lumbar puncture (LP), which revealed an opening pressure of 36 cm of water and normal CSF analysis.

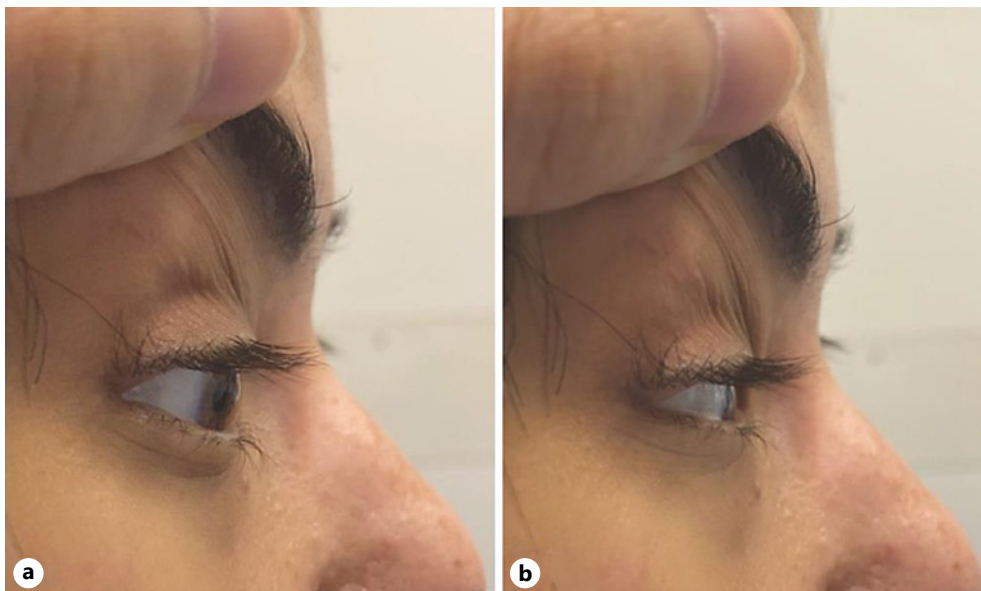
Based on the clinical presentation, physical examination, neuroimaging, and LP, the diagnosis of IIH with DRS type 1 was confirmed. She was started on furosemide 20 mg BID based on the recommendation of her nephrologist, and her symptoms, including headache and diplopia, improved significantly after beginning treatment and following therapeutic LP.

## Discussion

Patients with IIH often experience headaches and progressive vision loss. Diagnosis requires a thorough neurological examination and contrast-enhanced imaging to rule out an intracranial mass lesion. IIH, in this case, was presumed to be idiopathic; however, possible underlying factors could be suggested. Obesity, chronic renal failure, severe anaemia, the use



**Fig. 1.** A composite picture of the nine positions of gaze, showing right eye esotropia at primary position, limitation of abduction of the right eye, and narrowing of the palpebral fissure on adduction of the right eye.



**Fig. 2.** A side view picture of the right eye showing normal globe position in (a) and globe retraction with narrowing of the palpebral fissure on adduction in (b), compatible with the diagnosis of DRS type 1.

of corticosteroids, and withdrawal were identified as contributing factors. Patient-reported abrupt cessation of corticosteroid treatment may have caused renal transplant rejection, after which she continued to take steroids on a long-term basis. The sudden withdrawal of steroids is commonly associated with IIH. Moreover, IIH development on long-term use of

maintenance steroid therapy or increased dose has also been described [1]. Furthermore, IIH has also been linked to renal failure and renal transplant recipients in several studies [2, 3]. Because of the usage of corticosteroids, excessive weight gain, the presence of anaemia, and hypercoagulability, renal transplant patients are thought to be at increased risk [3]. Although this observation is intriguing, its clinical significance is unclear. In acute treatment, diuretics or spinal taps are frequently used to lower raised ICP. Carbonic anhydrase inhibitor (Diamox), an agent used to decrease CSF production, is not recommended for patients with renal failure due to gastrointestinal upset, acid-base imbalance, and the development of renal calculi. Concerning patients with IIH and renal transplants, furosemide has successfully lowered total body extracellular fluid [4].

In addition to highlighting a rarer association of IIH and chronic kidney failure, this case is also unique in that this patient had DRS type 1. In DRS, the lateral rectus muscle is abnormally innervated by the ocular nerve due to impaired development of the sixth cranial nerve. In DRS type I, there is marked restriction or the absence of abduction, normal or slightly defective adduction, narrowing of the palpebral fissure on adduction, widening of the palpebral fissure on abduction [5]. There is no evidence that IIH and DRS are related; however, there have been reports of IIH and DRS co-occurring in paediatric age group [2, 6]. Tillman et al. [6] reported the first association between pseudotumor cerebri, DRS type 1, and Goldenhar's syndrome in a young boy. Similarly, Behdad et al. [2] reported pseudotumor cerebri coexisting with bilateral DRS type I and nephropathic cystinosis in a young teenage girl. While our patient had renal transplant for unknown cause, the absence of ocular signs for cystinosis makes the possibility of nephropathic cystinosis in our case unlikely.

Distinguishing sixth cranial nerve palsy from Duane syndrome becomes crucial in such cases. Complete abducent nerve palsy and DRS type I share the common clinical feature of limited abduction, resulting from hypoplasia of the abducent nerve combined with minimal to no supply from the oculomotor nerve [5]. Conversely, the effect of ICP on sixth nerve palsy may cause decreased abduction and palpebral fissure widening in abduction but not globe retraction in adduction, which differentiates the two disorders. In this case, the patient reported significant improvement of headache and diplopia following therapeutic LP and initiating of diuretic, suggesting recovery of abducent nerve function. Surgery is reserved for cases with a primary position deviation, a significant face turn, marked globe retraction, or large up shoots or down shoot [3]. These symptoms were not present in this patient at the time of presentation.

## Conclusion

In summary, we report a case of a patient simultaneously suffering from chronic renal failure, IIH, and DRS type 1, which is likely coincidental but unique. Alternatively, IIH may be a rare clinical complication of chronic renal failure. In addition, this study highlights the importance of precise evaluation of the clinical signs of DRS and abducent palsy to optimize the management and overall outcome.

## Statement of Ethics

Written informed consent was obtained from the patients for publication of this case report and any accompanying images. Any sort of information that might reveal the patient's own identity has been completely avoided. This retrospective review of patient data did not require ethical approval in accordance with local/national guidelines.

## Conflict of Interest Statement

The authors have no conflicts of interest to declare.

## Funding Sources

The authors have no funding sources to disclose.

## Author Contributions

The authors confirm sole responsibility for the following: study conception and design, data collection, analysis and interpretation of results, and manuscript preparation. Dr. Abdullah I Almater and Dr. Jawaher Jehad Alwatban contributed to design, data collection, analysis and interpretation of results, and manuscript preparation. Dr. Arwa Z Alromaih contributed to data collection. Dr. Motazz A. Alarfaj contributed to data collection. Dr. Majed Al-Obailan contributed to the data acquisition and supervision of the study. All the authors approved the final version.

## Data Availability Statement

All data generated and analysed during this study are included in this article. Further enquiries can be directed to the corresponding author: Dr. Abdullah Almater.

## References

- 1 Walker AE, Adamkiewicz JJ. Pseudotumor cerebri associated with prolonged corticosteroid therapy: reports of four cases. *JAMA*. 1964;188(9):779–84.
- 2 Behdad B, Bagheri A, Tavakoli M, Pakravan M. Association of nephropathic cystinosis and pseudotumor cerebri with bilateral duane syndrome type I. *Neuroophthalmology*. 2014 Feb 7;38(2):74–7.
- 3 Obeid T, Awada A, Huraib S, Quadri K, Abu-Romeh S. Pseudotumor cerebri in renal transplant recipients: a diagnostic challenge. *J Nephrol*. 1997 Sep–Oct;10(5):258–60.
- 4 Sheth KJ, Kivlin JD, Leichter HE, Pan CG, Multauf C. Pseudotumor cerebri with vision impairment in two children with renal transplantation. *Pediatr Nephrol*. 1994 Feb;8(1):91–3.
- 5 Yüksel D, Orban de Xivry JJ, Lefèvre P. Review of the major findings about Duane retraction syndrome (DRS) leading to an updated form of classification. *Vision Res*. 2010 Nov 23;50(23):2334–47.
- 6 Tillman O, Kaiser HJ, Killer HE. Pseudotumor cerebri in a patient with Goldenhar's and Duane's syndromes. *Ophthalmologica*. 2002 Jul–Aug;216(4):296–9.