



The utility of wide-field optical coherence tomography angiography in diagnosis and monitoring of proliferative diabetic retinopathy in pregnancy

Philip H. Wright^a, Hagar Khalid^{b,c}, Pearse A. Keane^{b,*}

^a UCL Institute of Ophthalmology, London, UK

^b NIHR Biomedical Research Centre at Moorfields Eye Hospital NHS Foundation Trust and UCL Institute of Ophthalmology, London, UK

^c Ophthalmology Department, Faculty of Medicine, Tanta University, Tanta, Egypt

ARTICLE INFO

Keywords:

Diabetic retinopathy
Pregnancy
OCTA
FFA

ABSTRACT

Purpose: Diabetic retinopathy is an increasingly common complication of diabetes mellitus that benefits from early diagnosis and frequent monitoring, especially in pregnancy where there is a greater risk of progression. Fundus fluorescein angiography is currently the gold standard method of investigation for neovascularization. However, this has risks of unpleasant and potentially dangerous side effects, with an added theoretical risk to the fetus in pregnancy. Wide-field optical coherence tomography angiography (PLEX Elite 9000, Carl Zeiss Meditec, Inc. USA and DRI Swept Source OCT Triton, Topcon Medical Systems, Inc. USA) potentially offers a safer, faster and equally effective alternative method for diagnosis and monitoring of diabetic retinopathy in pregnant patients.

Observations: In the 3 cases reviewed from our clinic, we found that wide-field optical coherence tomography angiography was successfully used as an alternative to fundus fluorescein angiography in early diagnosis and ongoing monitoring of diabetic retinopathy in pregnant patients.

Conclusions and importance: Wide-field optical coherence tomography angiography can be considered as a useful alternative to fundus fluorescein angiography when reviewing pregnant diabetic retinopathy patients. This allows avoidance of any unpleasant and potentially dangerous side effects associated with fluorescein injection, and appears to be just as effective in diagnosis and detecting disease progression.

1. Introduction

Diabetic retinopathy (DR) is a common microvascular complication of diabetes mellitus that requires frequent monitoring, especially during pregnancy. Proliferative diabetic retinopathy (PDR) represents a severe progression of DR, with potentially sight threatening complications if left untreated.¹ Pregnancy appears to be an independent risk factor for the progression of DR.^{2,3} The risk of progression of DR during pregnancy is approximately double that of non-pregnancy, but this will be influenced by other risk factors.^{2,4} The other known risk factors for DR progression during pregnancy include the duration of diabetes diagnosis, greater severity of DR at conception, poor glycaemic control, hypertension, and pre-eclampsia.⁵ Treating PDR with laser pre-pregnancy appears to reduce the risk of progression during pregnancy.⁶ There have been studies suggesting regression of DR changes seen during pregnancy, but the results do not suggest regression of any proliferative changes that occur.^{7,8} The guidelines of the UK and

internationally strongly recommend early interventions to treat DR and prevent progression if seen in pregnancy.^{1,9} In the longer term, pregnancy as an event does not appear to have a significant effect on the eventual severity of DR and other microvascular diabetic complications.^{10,11}

Currently, fundus fluorescein angiography (FFA) remains the gold standard for investigation of retinal neovascularization (NV). However, it requires a fluorescein dye injection, and it has been established that fluorescein is able to cross the placenta, and therefore poses a theoretical risk to the fetus.¹² Safety data from fluorescein for injection are limited with regards to pregnancy.¹³ Consequently, the manufacturers recommend the use of fluorescein sodium for injection be avoided during pregnancy, “unless the benefit of the procedure is likely to exceed the risk”.¹³ To date, there have been no reports of teratogenic or fetotoxic effects from fluorescein for injection in animal studies, or in humans.¹² Even without the implication of placental crossing, fluorescein injections have known unpleasant side effects ranging from nausea to

* Corresponding author. 162 City Road, Old Street, London, EC1V 2PD, UK.

E-mail addresses: philip.wright5@nhs.net (P.H. Wright), hagar.khalid@nhs.net (H. Khalid), pearse.keane1@nhs.net (P.A. Keane).

<https://doi.org/10.1016/j.ajoc.2022.101280>

Received 20 November 2019; Received in revised form 13 December 2021; Accepted 13 January 2022

Available online 20 January 2022

2451-9936/© 2022 Published by Elsevier Inc. This is an open access article under the CC BY-NC-ND license (<http://creativecommons.org/licenses/by-nc-nd/4.0/>).

anaphylaxis.¹⁴

Optical coherence tomography angiography (OCTA) offers an alternative imaging modality without the need for fluorescein injection, with faster image acquisition times, making it safer and easily repeatable.¹⁵ Standard OCTA has been shown to be viable for use in detecting NV in PDR, with a limited field of view being one of the main limitations as it couldn't detect beyond the macula.¹⁵ As the technology has improved, wide-field OCTA (WF-OCTA) has been developed, allowing a field view of up to 80° of the fundus in a single image.¹⁶ This has been compared to FFA, showing a high sensitivity and specificity in detecting retinal nonperfusion areas and retinal NV.^{17,18}

In this case series, we highlight the potential utility of using the new, non-invasive WF-OCTA (PLEX Elite 9000, Carl Zeiss Meditec, Inc. USA and DRI Swept Source OCT Triton, Topcon Medical Systems, Inc. USA) as an alternative to using FFA in investigating and early diagnosing PDR in pregnant diabetic patients.

1.1. Image acquisition protocol

OCTA scans were obtained using the PLEX Elite 9000. It uses a swept-source laser with a wavelength of 1060nm. The scanning rate is 100000 A-scans per second, providing a transverse resolution of 20µm and an in-depth optical resolution of 6.3 µm. This instrument has an A-scan depth of 3.0mm in tissue (1536 pixels). The scanning protocol used was a 12 × 12mm OCTA montage, in which five 12 × 12mm OCTA data cubes positioned at predefined locations (central, superotemporal, superonasal, inferotemporal and inferonasal) were acquired. WF-OCTA en face montage was automatically generated with a total field of view up to 80°. To detect neovascularization, the vitreoretinal interface (VRI) segmentation and superficial retinal segmentation were used. The superficial retinal slab was defined as the volume between the internal limiting membrane (ILM) and the outer boundary of the inner plexiform layer. The VRI slab was defined with an inner boundary 200µm above the ILM and an outer boundary positioned on the ILM. We used automatic segmentation given by the device for diagnosis.¹⁶

2. Findings

2.1. Case 1

A 40 year-old female with type 1 diabetes mellitus diagnosed at age 14, referred to clinic at 15 weeks of pregnancy with bilateral moderate non proliferative diabetic retinopathy (NPDR), and non-clinically significant right diabetic macular oedema (DME). The DME was longstanding, stable, and under observation. Her best corrected visual acuity (BCVA) was 6/5 in both eyes.

Several months later, at 30 weeks of pregnancy, she reported a mild decrease in vision in her right eye. BCVA was recorded as 6/9 in the right eye, 6/4 in the left eye. Mild DME was ascertained on examination and OCT; it was deemed that there was no indication for treatment at the time. Interestingly, WF-OCTA was done the same day, and showed flat NVE in both eyes which changed the grading to PDR (Figs. 1 and 2).

Treatment options were discussed with her, and she opted for pan-retinal photocoagulation (PRP) to treat the NVE in both eyes. The first session of bilateral PRP was performed at 31 weeks of pregnancy, with no issues recorded. The second session of bilateral PRP was performed at 33 weeks of pregnancy, with no issues recorded. The mild intraretinal fluid in the right eye remained stable, with no DME in the left eye. Her last review was after an uneventful planned Cesarean section, with no evidence of activity or new vessels. BCVA was 6/5 in the right eye and 6/4 in the left eye. Both eyes had good PRP coverage, and no further treatment was deemed necessary. She was planned for review in 6–8 weeks.

2.2. Case 2

This case demonstrates progression of retinopathy during and after pregnancy despite treatment, with OCTA used to show the progression and development of NV. A 32 year-old female with a history of type 1 diabetes mellitus since 11 years of age, she was referred to clinic at 14 weeks of pregnancy. BCVA was 6/5 in both eyes. She had developed early PDR in the right eye and severe NPDR was noted in the left eye (Fig. 3a). The early PDR was treated by three sessions of pan-retinal photocoagulation (PRP) in two-weekly intervals. On follow-up, it was noted that she had developed DME in the right eye affecting her central vision (likely secondary to the PRP), with signs of worsening PDR in both eyes (Fig. 3b).

Her BCVA was noted as 6/18 in the right eye and 6/5 in the left eye. Urgent repeat PRP was advised with a plan for intravitreal anti-VEGF injections once she was postpartum. Timing of appointments meant fill in PRP was able to be done after she had a planned Cesarean section delivery. Anti-vascular endothelial growth factor (VEGF) injections were then deemed not required due to some spontaneous improvement in the DME post-partum (as this was likely secondary to the previous PRP).

When she was next seen, she had missed several clinic appointments. Her visual acuity was good, with unaided VA in the right eye of 6/5, unaided VA in the left eye of 6/4. However, in spite of previous treatment, new NVD was seen in the right eye on OCTA and the left eye still had severe NPDR (Fig. 3c). She underwent further PRP in the right eye for this, and continued to be regularly reviewed. Over time she went on to develop high risk PDR in both eyes, which was clearly evident on WF-

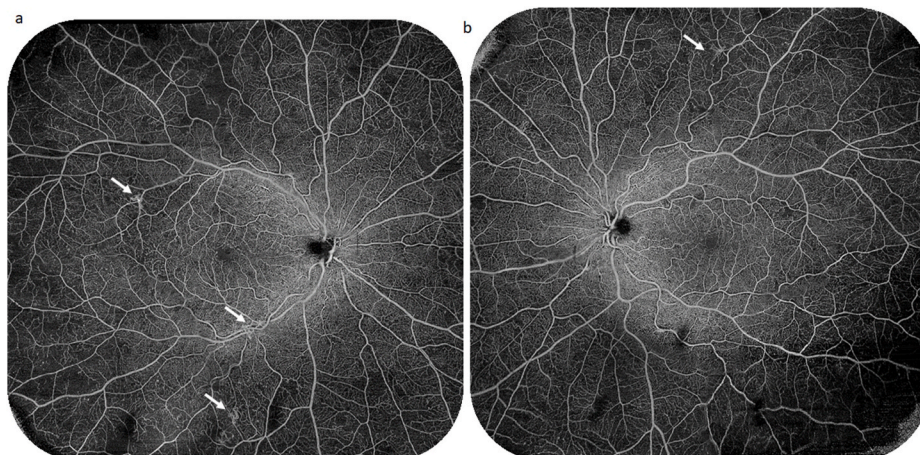


Fig. 1. WF-OCTA of Case 1 right (a) and left (b) eyes at the superficial capillary plexus slab showing multiple areas of non-perfusion and flat NVE (white arrows).

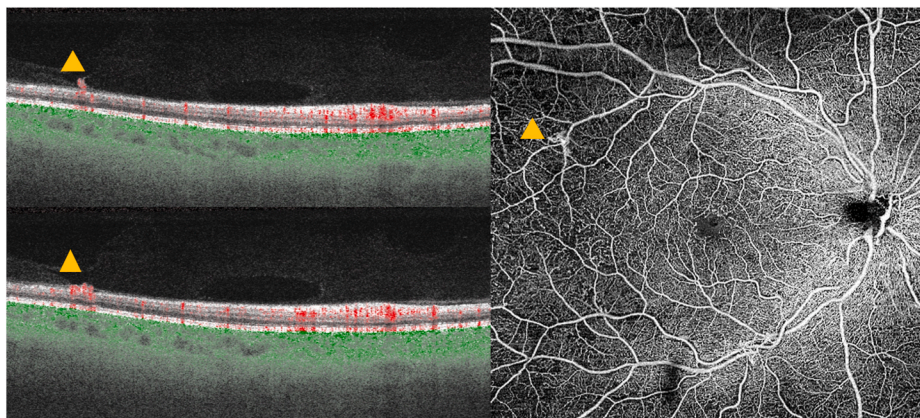


Fig. 2. Central 12 × 12 mm OCTA-B scans and *en face* OCTA at the superficial capillary plexus slab of Case 1 demonstrating a preretinal hyperreflective lesion with evident flow signals corresponding to the flat NVE seen on the *en face* OCTA (yellow arrowheads). (For interpretation of the references to color in this figure legend, the reader is referred to the Web version of this article.)

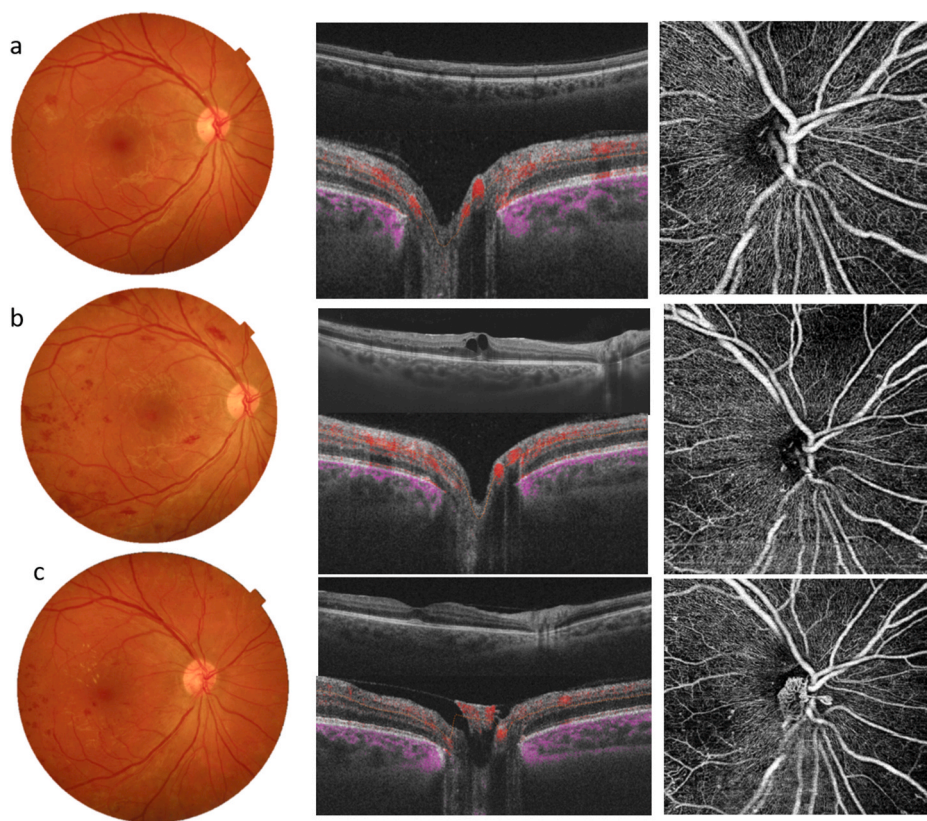


Fig. 3. Three consecutive visits of Case 2: a) color fundus photography demonstrating small NVE at the lower arcade which is seen as preretinal hyperreflective material in the OCT- B scan with no evident NVD in the *en face* OCTA or OCTA-B scans. b) Five months later, despite treatment, the diabetic retinopathy progresses as seen on color photography and the patient developed centre involving macular oedema with no evident NVD on *en face* OCTA or OCTA-B scan. c) Nine months later, the macular oedema resolved, however the patient developed NVD which is evident on *en face* OCTA and on OCTA-B scans as preretinal hyperreflective material bridging the physiological cup with evident flow signals. (Images acquired by Topcon OCT instrument (DRI OCT-1 Triton, Topcon, Tokyo, Japan)). (For interpretation of the references to color in this figure legend, the reader is referred to the Web version of this article.)

OCTA (Figs. 4 and 5).

2.3. Case 3

A 32 year-old female with a longstanding history of type 1 diabetes mellitus, referred to clinic at 20 weeks pregnant from the diabetic retinopathy screening service after noting some changes of moderate NPDR. Her BCVA was 6/6 in both eyes. This was confirmed by clinical examination and WF-OCTA which couldn't detect any early neovascularization (Fig. 6). This demonstrates a baseline WF-OCTA image of NPDR. Follow up was arranged for when she will be 32 weeks pregnant, to detect any progression as early as possible.

3. Discussion and conclusion

In the above described cases, we demonstrated the possibility of using WF-OCTA as a viable alternative to FFA in pregnant patients for investigating and monitoring DR. In cases 1 and 2 this allowed prompt diagnosis and commencement of treatment for PDR. Management of DR in pregnancy poses a range of challenges, including the logistics of the patient having to attend multiple appointments in a short space of time, potential rapid progression of DR, and the pregnancy acting as a relative contraindication to certain investigations and treatments.⁵ This adds a diagnostic challenge in subtle cases with changes not obvious on retinal photographs if FFA cannot be used due to patient allergy, intolerance, severe renal impairment, or theoretical risks to the fetus.

Treatment of PDR during pregnancy should be with laser pan-retinal

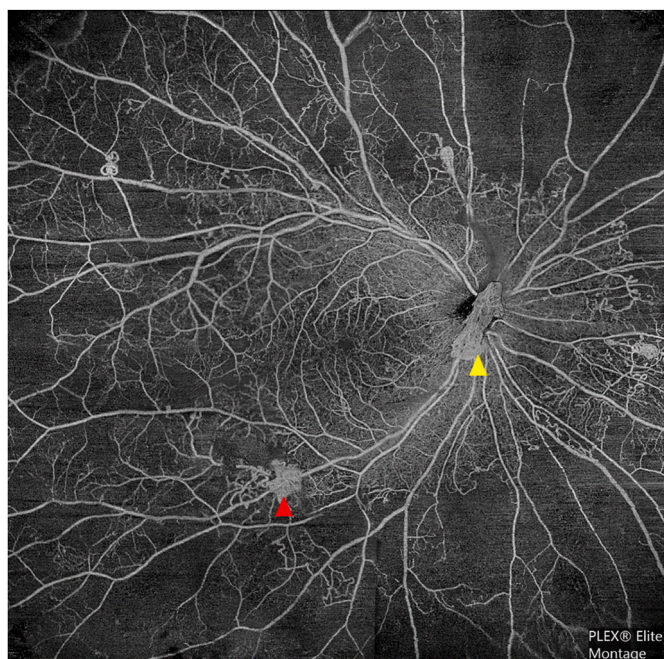


Fig. 4. WF-OCTA of the superficial capillary plexus slab of Case 2 right eye illustrating large areas of non perfusion (ANP) multiple NVE at the edge of the ANP (red arrowhead) and NVD (yellow arrowhead). (For interpretation of the references to color in this figure legend, the reader is referred to the Web version of this article.)

photocoagulation as early as possible, as per UK and international guidelines.⁹ It has been observed that up to 81% of patients who developed PDR during pregnancy also progressed post-partum, lending weight to the argument of treating early with laser instead of waiting for any potential regression postpartum.¹⁹ This also reinforces the need for frequent review, again as advised by UK guidelines.⁹

In the above cases, early detection of PDR changes during pregnancy with WF-OCTA meant appropriate treatment was able to start quickly, leading to a good outcome in case 1, but progression continued both during pregnancy and post-partum despite appropriate treatment in case 2. WF-OCTA continued to be useful in cases 2 and 3 for ongoing

monitoring of disease progression after the initial diagnosis. Irrespective of pregnancy, WF-OCTA would likely be useful for DR diagnosis and monitoring in patients who cannot have FFA due to coexisting moderate to severe renal impairment.

Cases 1 and 2 went on to have planned Cesarean section deliveries, but it should be noted that treatment for PDR during pregnancy is not a contraindication to normal vaginal delivery.⁹

Limitations of WF-OCTA include field size - it is still less than the UWF-FA, which can cover up to 200° of the fundus. WF-OCTA is a relatively new imaging modality to be used in this way, and the images require careful interpretation and knowledge of imaging artifacts to avoid misdiagnosis. WF-OCTA is still reliant on patient factors such as clear media and an ability to fixate, so will be limited if these are impaired.

The overall impression is that WF-OCTA is a very useful addition to the diagnostic tools available in investigating DR in pregnancy. This is particularly relevant as the need for early PDR detection and treatment is paramount.

Patient consent

Consent to publish the case report was not obtained. This report does not contain any personal information that could lead to the identification of the patient. Approval for data collection and analysis was obtained from the Institutional Review Board at Moorfields (ROAD17/031). The study adhered to the tenets set forth in the Declaration of Helsinki.

Funding

The research was supported by the National Institute for Health Research (NIHR) Biomedical Research Centre based at Moorfields Eye Hospital NHS Foundation Trust and UCL Institute of Ophthalmology. The views expressed are those of the author(s) and not necessarily those of the NHS, the NIHR or the Department of Health.

Authorship

All authors attest that they meet the current ICMJE criteria for Authorship.

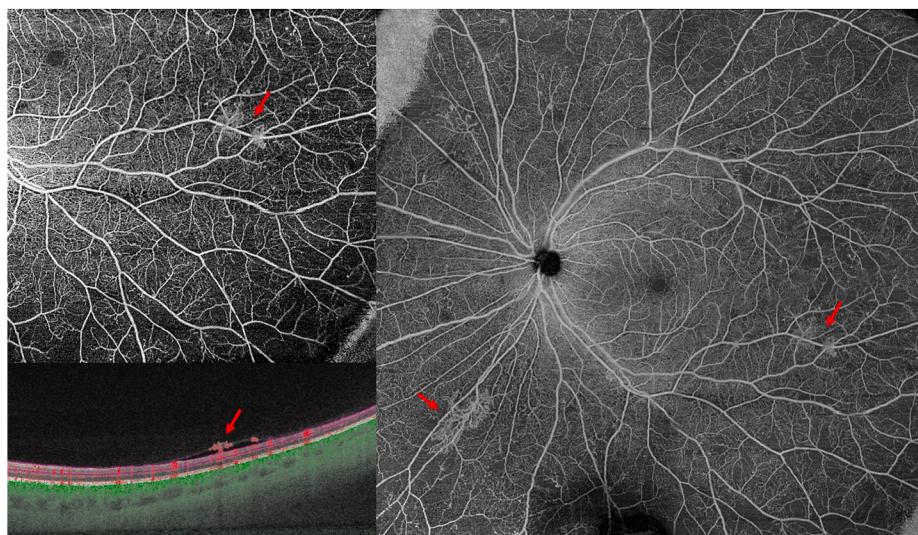


Fig. 5. WF-OCTA of the superficial capillary plexus slab of Case 2 left eye illustrating scattered areas of non perfusion (ANP) and multiple NVE (red arrows). *En face* OCTA of the infero-temporal quadrant shows NVE which corresponds to the preretinal hyperreflective material with evident flow signals (red arrows). (For interpretation of the references to color in this figure legend, the reader is referred to the Web version of this article.)

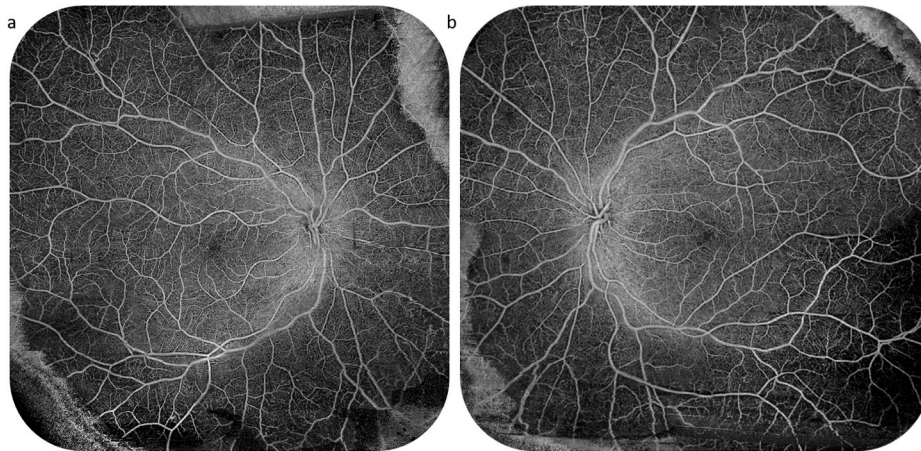


Fig. 6. WF-OCTA of the superficial capillary plexus slab of Case 3 right eye (a) and left eye (b), which confirmed the diagnosis of NPDR as no evidence of NVD or NVE could be detected in either image.

Declaration of competing interest

Dr. Keane has received speaker fees from Heidelberg Engineering, Topcon, Carl Zeiss, Meditec, Haag-Streit, Allergan, Novartis, Roche, and Bayer. He has served on advisory boards for Novartis and Bayer and has been an external consultant for DeepMind and Optos. Dr. Keane is supported by a United Kingdom (UK) National Institute for Health Research (NIHR) Clinician Scientist Award (NIHR-CS-2014-12-023). The following authors have no financial disclosures: PHW, HK.

Acknowledgements

None.

References

- Wong TY, Sun J, Kawasaki R, et al. Guidelines on diabetic eye care: the international council of ophthalmology recommendations for screening, follow-up, referral, and treatment based on resource settings. *Ophthalmology*. 2018;125(10):1608–1622.
- Effect of pregnancy on microvascular complications in the diabetes control and complications trial. The Diabetes Control and Complications Trial Research Group. *Diabetes Care*. 2000;23(8):1084–1091.
- Klein BE, Moss SE, Klein R. Effect of pregnancy on progression of diabetic retinopathy. *Diabetes Care*. 1990;13(1):34–40.
- Kitzmiller JL, Block JM, Brown FM, et al. Managing preexisting diabetes for pregnancy. *Summ Evid Consensus Recommend Care*. 2008;31(5):1060–1079.
- Morrison JL, Hodgson LA, Lim LL, Al-Qureshi S. Diabetic retinopathy in pregnancy: a review. *Clin Exp Ophthalmol*. 2016;44(4):321–334.
- Sunness JS. The pregnant woman's eye. *Surv Ophthalmol*. 1988;32(4):219–238.
- Ohr V. The influence of pregnancy on diabetic retinopathy with special regard to the reversible changes shown in 100 pregnancies. *Acta Ophthalmol*. 1984;62(4):603–616.
- Serup L. Influence of pregnancy on diabetic retinopathy. *Acta Endocrin Suppl (Copenh)*. 1986;277:122–124.
- Ghanchi F. Diabetic retinopathy guidelines working G. The royal college of ophthalmologists' clinical guidelines for diabetic retinopathy: a summary. *Eye (London, England)*. 2013;27(2):285–287.
- Chaturvedi N, Stephenson JM, Fuller JH. The relationship between pregnancy and long-term maternal complications in the EURODIAB IDDM Complications Study. *Diabet Med*. 1995;12(6):494–499.
- Gomes MB, Negrato CA, Almeida A, de Leon AP. Does parity worsen diabetes related chronic complications in women with type 1 diabetes? *World J Diabetes*. 2016;7(12):252–259.
- Halperin LS, Olk RJ, Soubrane G, Coscas G. Safety of fluorescein angiography during pregnancy. *Am J Ophthalmol*. 1990;109(5):563–566.
- Electronic Medicines Compendium - Fluorescein Sodium 100 mg/ml, Solution for Injection [04/07/2019]. Available from: <https://www.medicines.org.uk/emc/product/8829/smpc>.
- Kwan AS, Barry C, McAllister IL, Constable I. Fluorescein angiography and adverse drug reactions revisited: the Lions Eye experience. *Clin Exp Ophthalmol*. 2006;34(1):33–38.
- Onishi AC, Fawzi AA. An overview of optical coherence tomography angiography and the posterior pole. *Therapeut Adv Ophthalmol*. 2019;11, 2515841419840249.
- Khalid H, Schwartz R, Nicholson L, et al. Widefield optical coherence tomography angiography for early detection and objective evaluation of proliferative diabetic retinopathy. *Br J Ophthalmol*. 19 March 2020. <https://doi.org/10.1136/bjophthalmol-2019-315365>. Published Online First: .
- Hirano T, Kakihara S, Toriyama Y, Nittala MG, Murata T, Sadda S. Wide-field en face swept-source optical coherence tomography angiography using extended field imaging in diabetic retinopathy. *Br J Ophthalmol*. 2018;102(9):1199–1203.
- Sawada O, Ichiyama Y, Obata S, et al. Comparison between wide-angle OCT angiography and ultra-wide field fluorescein angiography for detecting non-perfusion areas and retinal neovascularization in eyes with diabetic retinopathy. *Graefes Arch Clin Exp Ophthalmol*. 2018;256(7):1275–1280.
- Chan WC, Lim LT, Quinn MJ, Knox FA, McCance D, Best RM. Management and outcome of sight threatening diabetic retinopathy in pregnancy. *Eye*. 2004;18:826–832.