


# Analysis of Metagenomic Next-Generation Sequencing (mNGS) in the Diagnosis of Herpes Simplex Virus (HSV) Encephalitis with Normal Cerebrospinal Fluid (CSF)

Zhijia Si<sup>1,\*</sup>, Lin Li<sup>2,\*</sup>, Jingzhe Han<sup>1</sup> 

<sup>1</sup>Department of Neurology, Harrison International Peace Hospital, Hengshui, Hebei, People's Republic of China; <sup>2</sup>Department of Pain, Harrison International Peace Hospital, Hengshui, Hebei, People's Republic of China

\*These authors contributed equally to this work

Correspondence: Jingzhe Han, Department of Neurology, Harrison International Peace Hospital, Hengshui, Hebei, 053000, People's Republic of China, Tel/Fax +86-318-2187209, Email hanjingzhe2017@sina.com

**Background:** Metagenomic next-generation sequencing (mNGS) is becoming increasingly extensive in diagnosing herpes simplex encephalitis (HSE). However, many HSE patients with normal cerebrospinal fluid (CSF) diagnosed by mNGS have been found during the clinical application. This study aimed to summarize and analyze the clinical characteristics, supplementary examinations, and prognosis of patients with HSE whose cerebrospinal fluid was confirmed to be normal by mNGS.

**Methods:** This retrospective study evaluated the clinical characteristics, auxiliary examinations, and patient prognosis of patients with HSE that were diagnosed by mNGS but had normal CSF. Clinical data collected included baseline information, signs and symptoms upon admission, and risk factors for infection. Auxiliary examinations included indirect immunofluorescence assay (IIF), cell-based assay (CBA), and CSF testing. Prognosis was evaluated based on hospital stay and patient survival.

**Results:** Seven of the nine patients (77.8%) experienced headaches, and four (44.4%) had a fever of 38°C or higher. The average leukocyte count in the CSF was  $2.6 \pm 2.3/L$ . According to the mNGS, the median sequence count of HSV was 2 (1, 16). Magnetic resonance imaging (MRI) revealed one bilateral temporal lobe lesion (11.1%), two isolated bilateral frontal lobe lesions (22.2%), and one bilateral cingulate gyrus lesion (11.1%). One patient (11.1%) was admitted to the intensive care unit and passed away in the hospital. The remaining patients (88.9%) had a positive prognosis upon discharge.

**Conclusion:** Patients with HSE who had normal CSF were typically middle-aged women with normal immune function. They showed typical HSE clinical features, such as fever, headache and epilepsy, that did not differ from those of other HSE patients. A normal CSF result is generally associated with a low viral load and the body's ability to mount an effective immune response. Most of these patients have a favorable prognosis.

**Keywords:** herpes simplex encephalitis, herpes simplex virus, cerebrospinal fluid, metagenomic next-generation sequencing, atypical clinical manifestations

## Introduction

Herpes simplex encephalitis (HSE) is an acute infectious disease of the central nervous system caused by herpes simplex virus (HSV), which mainly invades the temporal lobe, frontal lobe and limbic system, causing bleeding and necrotizing encephalitis.<sup>1,2</sup> HSV is a neurophilic double-stranded DNA virus that is classified into two distinct types: oral herpes (HSV-1) and genital herpes (HSV-2). Approximately three-quarters of HSE patients are caused by HSV-1.<sup>3</sup> HSE is recognized by its temporal and frontal lobe involvement, as well as elevated levels of white blood cells and protein in the cerebrospinal fluid, and discoloration in the form of red blood cells and yellowing. Early detection of frontotemporal lobar edema can be accomplished using magnetic resonance imaging (MRI), which may also reveal brain swelling. The

DNA PCR for HSV of the CSF is considered the standard gold test with a sensitivity of 94–98% and specificity of 98–100%.<sup>4</sup> Diagnosing HSE becomes easier when typical symptoms are accompanied by PCR results. However, many patients with atypical HSE may have normal cerebrospinal fluid leukocyte counts in clinical practice, making them susceptible to misdiagnosis as cerebral infarction or intracranial space-occupying lesions. Although viral isolation and PCR testing are considered the “gold standard” for HSE diagnosis, the limitations of these methods, such as the time-consuming nature of viral isolation and its low detection rate, and the limited ability of PCR testing to detect nucleic acid fragments, have restricted their clinical application. Hence, diagnosing atypical HSE can be a challenging task. Studies indicate that untreated HSE patients have a high mortality rate of up to 70%, but if treatment is initiated within four days of onset, the mortality rate can be reduced to 8%.<sup>5</sup> Thus, early diagnosis and treatment of HSE are crucial, as misdiagnosis or missed diagnosis can have serious consequences for patients. The increasing use of metagenomic next-generation sequencing (mNGS) in infectious disease diagnosis, due to its advantages, is becoming more widespread in clinical practice.<sup>6,7</sup> Since Guan first reported the research on mNGS in HSV1 and HSV2 in 2015,<sup>8</sup> mNGS has played a more critical role in diagnosing HSE. It is reported that a few HSE patients have no abnormal changes in CSF. In 2015, Rawal et al presented a case of HSVE in which the CSF analysis was standard, but the CSF PCR was positive for HSV1.<sup>9</sup> In 2011, Jakob et al reported five cases of HSVE in immunosuppressed patients who had received whole-brain irradiation for malignoma in Germany, where the CSF was normal.<sup>9</sup> In 2006, Avkan Oguz et al documented the same phenomenon in two immunocompetent patients in Turkey.<sup>10</sup> Nonetheless, such patients always exhibit an absence of typical clinical features and MRI findings of HSE, which presents a significant challenge for the early and definitive clinical diagnosis of the condition.

Given the broad range and rapid screening capabilities of mNGS for infectious encephalitis pathogens, it is a more reliable method than PCR and pathogen culture for the early identification of pathogens in cerebrospinal fluid in cases of normal infectious encephalitis. This study retrospectively examined the clinical features, auxiliary testing, and outcomes of HSE cases confirmed through mNGS with normal CSF. The aim was to enhance the understanding of atypical HSE, particularly in patients with normal CSF. The findings highlight the diagnostic utility of mNGS for HSE, and provide a theoretical foundation for the optimal timing of mNGS in patients suspected of having HSE. Additionally, the study offers guidance for accurate diagnosis, treatment, and improvement of patient prognosis in early-stage HSE.

## Materials and Methods

### Patients

This study retrospectively gathered clinical data from patients diagnosed with HSE who were hospitalized at our hospital from January 2017 to June 2021. The study was approved by the Ethics Committee of our hospital and was conducted in accordance with the 1964 Helsinki Declaration. Patients and their families were fully informed about the study’s purpose and content and provided written consent.

Patients were selected for this study based on the following criteria: (1) Suspected diagnosis of acute encephalitis with detection of human HSV1 viral sequences in the cerebrospinal fluid by NGS; (2) First cerebrospinal fluid analysis showing normal leukocyte count ( $\leq 8.0 \times 10^6/L$ ); (3) Completion of consultation and treatment according to standard protocols and follow-up for 1 to 3 months; (4) Obtainment of written informed consent from the patient and their family.

Exclusion criteria were: (1) CNS tumors; (2) Encephalitis complicated by multiple pathogen infections; (3) Autoimmune encephalitis; (4) Incomplete clinical data and non-standard case records; (5) Patients with a history of puncture injury.

### Clinical Data

The baseline characteristics that were recorded, including demographic information, the time and place of admission, risk factors for infection, and symptoms present upon admission, can offer crucial insights into the nature of the infection being studied. The patient underwent antiviral treatment and had cranial imaging and laboratory tests performed. The timing of the lumbar puncture and the cranial imaging were recorded upon admission.

The patient's outcome was classified into five categories using the Glasgow Outcome Scale (GOS), which include death, vegetative state, severe sequelae requiring daily assistance, moderate sequelae with independent living capability, and no or mild sequelae. The assessment of the outcome was conducted at the time of discharge and during follow-up visits at one and three months post-discharge. A GOS score of 4 or lower was considered an unfavorable outcome.

## Antibodies Detection

The indirect immunofluorescence assay (IIF) was utilized to detect autoimmune encephalitis antibodies. The cell-based assay (CBA) demonstrated high diagnostic specificity and sensitivity for the related encephalitis (RE). The initial dilution titers for CSF and serum testing were set at 1:1 and 1:10, respectively.

## NGS of CSF

CSF specimens (1–2 mL) were collected via lumbar puncture and immediately stored at  $-80^{\circ}\text{C}$  for 30 minutes prior to usage in NGS. The micro-sample genomic DNA extraction kit was employed to extract DNA from the CSF samples, which were then fragmented into fragments ranging from 200 to 300 bp with the help of a DNA-cutting ultrasonic crusher. The DNA fragments were subjected to quality control, where the size was checked using a 2100 biological analyzer. The presence of the DNA library was then detected by quantitative PCR.

The DNA libraries were constructed through a series of steps, including end-repair, A-tailing, adapter ligation, and PCR amplification, using an NGS library construction kit to prepare for NGS. The roller amplification technology was applied to increase the concentration of single-stranded circular DNA, resulting in the formation of DNA nanospheres. The DNA nanospheres were then loaded onto the sequencing chip and sequenced using the BGISEQ.50 sequencing platform (Genskey Medical Technology Co., Ltd., Beijing, China).

All species included in the curated pathogen reference databases were collected from books, such as the Manual of Clinical Microbiology, Diagnosis and Illustration of Clinical Microbiology, and NCBI RefSeq genome database. Strictly only one typical high-quality representative strain whose genome sequence was downloaded from the NCBI RefSeq genome database or NCBI GenBank genome database was selected for each species. Currently, our curated database contains 9855 bacterial genomes or scaffolds, 6926 whole genome sequences of viral taxa, 1582 whole genome sequences of fungal taxa, 312 whole genome sequences of parasites, 184 mycoplasma and 177 mycobacterium.

## Immunoserological

All patients were tested for specific HSV-IgG and HSV-IgM in blood and cerebrospinal fluid using enzyme-linked immunosorbent assay (ELISA). At the same time, double serum and double cerebrospinal fluid were used to observe HSV-1 antibodies dynamically. The diagnosis could be confirmed when the trend of antibody increase in double cerebrospinal fluid was elevated, the titer was above 1:80, the antibody titer increased more than four times during the disease for two or more times, and the ratio of antibodies in the blood and cerebrospinal fluid was  $< 40$ .

## Statistical Analyses

All statistical analyses were performed with SPSS (SPSS22.0). To describe baseline demographics, we used frequency distributions. Continuous nonparametric data were summarized using medians, interquartile ranges (IQRs), continuous variables conforming to normal distribution were represented by mean  $\pm$  standard deviation.

## Results

### Clinical Characteristics of the Patient

The clinical information of nine patients was meticulously documented. The patient population comprised three males (33.3%) and six females (66.7%), with an average age of  $40.0 \pm 17.7$  years. One patient (11.1%) had type 2 diabetes, while another (11.1%) had a history of long-term oral administration of hormones and azathioprine due to an autoimmune disease. Three patients (33.3%) reported a prodromal infection. Four patients (44.4%) had a history of lip herpes.

Three patients (33.3%) presented with seizures characterized as generalized tonic-clonic seizures, which were effectively controlled after admission. Seven patients (77.8%) reported experiencing headaches, with one patient (14.3%) presenting accompanying symptoms of nausea and vomiting. Four patients (44.4%) had a fever  $\geq 38$  °C. One patient (11.1%) was unconscious upon admission with a Glasgow Coma Scale (GCS) score of 3, while the remaining 8 patients (88.9%) were conscious, with a GCS score of 15. None of the patients exhibited any characteristic signs of HSE, such as personality changes, speech disorders, or sensory-motor abnormalities. Most of the symptoms were non-specific and typical of HSE. All patients showed negative results for meningeal irritation signs (Table 1).

## Laboratory Examination of the Patient

The mean white blood cell count (WBC) in routine blood tests was  $8.1 \pm 3.6 \times 10^{12}/L$ , with 2 patients (22.2%) presenting elevated levels. The average time elapsed from onset to lumbar puncture was  $137.0 \pm 110.0$  hours. The mean CSF pressure was  $176.7 \pm 40.3$  mmH<sub>2</sub>O, with 3 patients (33.3%) having elevated pressure. The average leukocyte count in the CSF was  $2.6 \pm 2.3/L$ , with no red blood cells present, indicating no evidence of typical hemorrhagic necrotic encephalitis.

The mean CSF protein was  $426.0 \pm 126.0$  mg/L, with 3 patients (33.3%) presenting elevated levels. The CSF glucose level was  $4.0 \pm 1.0$  mmol/L, with 1 patient (11.1%) having an elevated reading. The CSF chloride level was  $124.3 \pm 4.2$  mmol/L, with one patient (11.1%) having an increased level and two (22.2%) having decreased levels. The results of pathogen NGS of the CSF showed that the median copy sequence of HSV was 2 (1 to 16) (Table 2).

The unique reads of the identified viral genes ranged from 1 to 826. The coverage of identified viral genes ranged from 12% to 98%, with a depth value of 1.1 to 35, respectively (Table 3). Immunoserological testing showed 5 cases with positive cerebrospinal fluid HSV-IgM, 2 cases with serum/CSF  $<40$ , and 2 cases with recovery-specific HSV-IgG in double CSF samples, which increased more than four times.

## Analysis of MRI and EEG Results

The average time from admission to the performance of an MRI was  $21.8 \pm 24.6$  hours. Among the nine patients, one patient (11.1%) demonstrated bilateral temporal lobe lesions, while another patient (11.1%) showed bilateral cingulate

**Table 1** The Characteristics at Admission of Adult Patients with HSE

	Subgroup	Patient 1	P2	3	4	5	6	7	8	9
Age		31	71	17	56	15	42	39	47	42
Sex		M	F	F	F	F	F	M	F	M
Risk factors										
	Diabetes	-	+	-	-	-	-	-	-	-
	Immunosuppression	-	-	-	-	-	-	-	+	-
	Lips herpes	-	+	-	+	-	+	-	+	-
History of viral infections		-	+	-	+	-	-	-	+	-
Clinical presentation										
	Seizures	-	-	+	-	-	-	+	+	-
	Headache	+	-	+	+	+	+	-	+	+
	Nausea	-	-	-	-	+	-	-	-	-
	Personality changes	-	-	-	-	-	-	-	-	-
	Confusion	-	-	-	-	-	-	-	-	-
	GCS	15	15	15	15	15	15	15	13	15
	Fever ( $\geq 38.0^\circ\text{C}$ )	+	-	-	-	+	-	-	+	+
	Motor/sensory deficits	-	-	-	-	-	-	-	-	-

**Abbreviation:** GCS, Glasgow Coma Scale.

**Table 2** The Biochemical and Microbiological Analyses of the 9 Adult Patients

Patients		1	2	3	4	5	6	7	8	9
WBC count ( $\times 10^6/L$ , 4–10)		4.08	6.45	9.56	6.03	6.73	5.59	15.3	12	7.16
Cerebrospinal fluid analysis	Time to lumbar puncture (h)	159	96	33	384	146	168	72	8	168
	Pressure (mmH <sub>2</sub> O, 80–180)	160	140	250	140	150	200	160	160	230
	WBC ( $\times 10^6$ cells/L, $\leq 8$ )	1	2	1	3	1	4	8	1	2
	RBC ( $\times 10^6$ cells/L)	0	0	0	0	0	0	0	0	0
	Protein (mg/L, 150–450)	609	681	328	362	413	411	160	550	320
	Glucose (mmol/L, 2.5–4.5)	4.27	6.17	3.91	3.94	3.33	3.7	2.51	4.01	3.92
	Chloride (mmol/L, 120–130)	119.8	119.6	122.5	128.4	122.3	123.3	132.7	125	125

**Abbreviations:** WBC, White blood cells; RBC, red blood count.

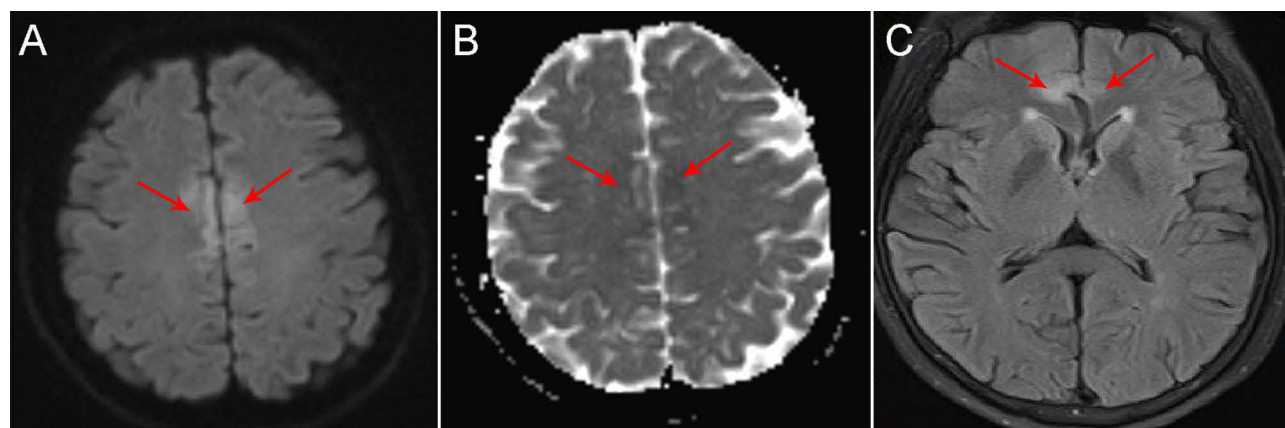
**Table 3** The Results of the NGS Analysis

Patient	The Number of Unique Reads	The Coverage of Identified Viral Genes Ranged	Depth Value
1	6	0.24%	1
2	10	0.4%	1
3	1	0.03%	1
4	22	0.8%	1
5	2	0.07%	1
6	2	0.07%	1
7	1	0.03%	1
8	826	44%	1
9	2	0.07%	1

gyrus lesions, as depicted in [Figure 1A](#) and [B](#). Additionally, two patients (22.2%) exhibited isolated bilateral frontal lobe lesions, as depicted in [Figure 1C](#). The MRIs of the remaining patients were unremarkable. An EEG was conducted on five patients (55.6%), and encephalitis changes were present in 80.0% of these patients ([Table 4](#)).

### Analysis of Treatment and Prognosis

All nine patients were given intravenous antiviral treatment, which included acyclovir, ganciclovir, and foscarnet, after admission. The average duration of antiviral drug treatment was  $21.8 \pm 24.6$  days. Three of the patients (33.3%) received



**Figure 1** The patient 8 and 4. The MRI results of patient 8 showed high DWI ((A), red arrow) and low ADC ((B), red arrow) in the Cingulate gyrus; The MRI results of patient 4 showed high FLAIR in the isolated bilateral frontal lobe ((C), red arrow).

**Table 4** The Result of Cranial Imaging and Electroencephalography in the 9 Adult Patients

Patients		1	2	3	4	5	6	7	8	9
MRI from time of admission (hours)		20	0	7	0	24	48	24	1	72
EEG findings		+	-	Normal	-	-	+	+	+	-
MRI	Hemorrhage	-	-	-	-	-	-	-	-	-
	Frontal lobe	-	-	-	+	-	-	+	+	-
	Temporal lobe	-	+	-	-	-	-	-	-	-
	Parietal lobe	-	-	-	-	-	-	-	+	-
	Occipital lobe	-	-	-	-	-	-	-	-	-
	Brainstem	-	-	-	-	-	-	-	-	-
	Cerebellum	-	-	-	-	-	-	-	-	-
	Other parts	-	-	-	-	-	-	-	-	-

**Abbreviations:** MRI, Magnetic Resonance Imaging; EEG, Electroencephalogram.

**Table 5** Summary of Treatment and Outcome of the 9 Adult Patients

Patient		1	2	3	4	5	6	7	8	9
Duration of acyclovir/valaciclovir treatment (days)		14	14	14	14	14	14	10	30	30
Steroid hormone		-	-	-	-	-	-	+	+	+
IVIG		-	-	-	-	-	-	-	+	-
ICU		-	-	-	-	-	-	-	+	-
Outcome	In-hospital mortality	-	-	-	-	-	-	-	+	-
	1-month mortality	-	-	-	-	-	-	-	+	-
	3-month mortality	-	-	-	-	-	-	-	+	-
	GOS at discharge	5	5	5	5	5	5	5	1	5
	GOS one month since discharge	5	5	5	5	5	5	5	1	5
	GOS three month since discharge	5	5	5	5	5	5	5	1	5

**Abbreviations:** IVIG, Intravenous Immunoglobulin; ICU, Intensive Care Unit; GOS, Glasgow Outcome Scale.

hormone therapy as part of their treatment. Patient 7 and 8 received a single dose of methylprednisolone 1g as pulse therapy, while patient 9 was given a daily dose of methylprednisolone 60mg for 5 days. One patient (11.1%) received treatment with intravenous immunoglobulin (IVIG) at a dose of 0.4g/kg for 5 days. Unfortunately, one patient (number 8, 11.1%) was admitted to the ICU for respiratory support and passed away during their hospitalization. The other patients who were discharged (88.9%) had a good prognosis (Table 5).

## Discussion

HSE is the most common cause of severe viral encephalitis, accounting for 10–20% of the annual encephalitis incidence rate.<sup>11</sup> Most adult herpes simplex encephalitis is caused by HSV-1, which can retrograde into the skull along the nerve to cause HSE.<sup>12</sup> HSE can occur at any age, with no significant seasonal. There are two peaks in 20 and 50, and there is no difference between genders.<sup>13</sup> Non-specific symptoms such as respiratory infection, fever, headache and fatigue are common before onset. Symptoms such as insomnia, abnormal personality or behaviour, convulsions or coma occur several days later.<sup>11,13,14</sup> Kapadia et al described the clinical characteristics and pathogenesis of adult HSE in 2020.<sup>15</sup> Avkan Oguz et al, 2006, documented the same in two immunocompetent patients in Turkey.<sup>16</sup>

The average age of nine patients in this study was  $40.0 \pm 17.7$  years, and the male-to-female ratio was 1:2, which was inconsistent with HSE reported. A study conducted in the United States on 272 patients with HSV infection showed that the average age of the patients was 59.9 years old, and the gender ratio was close to 1:1 (223 males vs 234 females).<sup>17</sup> In this study, non-specific HSE symptoms such as precursor infection, fever, headache and epilepsy were relatively common

in all patients. In comparison, specific clinical symptoms of HSE such as personality changes, speech disorder, abnormal behaviour and consciousness disorder, were relatively rare, which was considered to be related to the damage degree of HSV to brain tissue. Nausea and vomiting were rare, and harmful meningeal irritation was consistent with the clinical characteristics of HSE.<sup>18</sup> Clinical symptoms suggest that the HSE patients with normal CSF were always in the prime of life, and the injured level of neurons was lighter than classical HSE. Clinicians need to be aware that young female patients with standard cerebrospinal fluid tests may be underdiagnosed and misdiagnosed because they lack the typical clinical features of HSE.

The pressure of CSF can be increased typically and slightly and can be significantly increased in severe HSE patients. The number of nucleated cells in CSF of HSE was  $50\text{--}100 \times 10^6$ , which could be as high as  $1.0 \times 10^9$ . Lymphocytopenia was dominated, blood cells could be present, slightly or moderately elevated protein, and regular sugar and chloride.<sup>19</sup> In this study, the average time from onset to lumbar puncture was  $137.0 \pm 110.0$  hours, with a long interval, which may be related to mild clinical symptoms, delayed treatment or atypical clinical symptoms. CSF pressure was typically or slightly increased, accorded with CSF pressure changes of mild HSE. The number of blood cells in CSF of all patients was 0, indicating without hemorrhagic necrotic encephalitis. The mean number of CSF leukocytes was  $2.6 \pm 2.3/\text{L}$ , significantly lower than the previously reported changes of CSF leukocytes,<sup>19</sup> indicating a low degree of immune response. In addition, the change in CSF protein was consistent with HSE. One patient had an elevated CSF glucose level related to a previous diabetes history. The chloride of CSF was  $124.3 \pm 4.2$  mmol/L, and the decrease of chloride was considered to be related to the blood chlorine. Therefore, except for the number of leukocytes in CSF, the other CSF characteristics were consistent with previous reports of HSE. In our study, all patients were diagnosed with HSE by mNGS. The sequencing results showed that the median HSV copy sequence was 2 (1, 16). Although there was no study on the correlation between HSV copy sequences and HSE prognosis, mNGS only defined as abnormal was copy sequences  $\geq 1$  in CSF, indicating the low viral load in our patients. The degree of CSF response is generally related to viral load and the body's immune response-ability. The sequencing results confirmed the effect of viral load on CSF leukocytes. However, the copy sequences of patient 8 were 826, given the delayed exam time of mNGS, suggesting that the HSV load might be higher. However, the CSF were always normal during hospitalization, which might be related to the immune response ability inhibited by hormones and immunosuppressants. An average cerebrospinal fluid leukocyte count does not exclude a patient from having viral encephalitis, especially in the case of HSE. This is because the cerebrospinal fluid leukocyte count may be related to the body's immune response and the amount of virus. Instead, the final basis for a definitive diagnosis requires testing for the pathogen. In this study, we used the mNGS test for the early diagnosis of all HSE patients, and the results showed that this technique has an excellent diagnostic value for HSE.

MRI is the most sensitive examination method of HSE. Its lesions usually appear 2–3 days after the onset of symptoms, presenting bilateral symmetrical limbic lobe involvement, including the medial temporal lobe, insular cortex, lateral inferior frontal lobe and cingulate gyrus; Basal ganglia is not involved, while other parts of the brain and midbrain are rarely involved, which can be combined with bleeding.<sup>20</sup> All patients underwent MRI after or before admission, and the average time of MRI was  $21.8 \pm 24.6$ h. HSV primarily enters the skull retrogradely along the cranial nerve, so the temporal lobe and frontal lobe were the first affected. However, in this study, only 1 patient with temporal lobe, 2 patients with isolated bilateral frontal lobe and 1 with simple cingulate gyrus were found. Both temporal lobe and cingulate gyrus conformed to the MRI findings of HSE. The proportion of patients with normal MRI was high, and none showed hemorrhagic necrotic encephalitis in the early stage, indicating the degree of brain injury. However, HSE's isolated bilateral frontal lobe was rare.<sup>20</sup> The reason for isolated bilateral frontal lobe involvement in our patient is unknown, considering that it might be related to the cranial pathway of HSV. The patient with atypical MRI findings should be paid attention to because it is effortless to be misdiagnosed as tumors, venous sinus thrombosis and other diseases. EEG abnormalities accounted for 80% of HSE, and most patients are nonspecific changes. Patients with HSE with average cerebrospinal fluid cell counts also lack the typical MRI presentation, which may be related to the degree of damage to brain tissue by the pathogen. Therefore, a standard MRI display does not exclude the diagnosis of HSE. EEG combined with symptoms of frontotemporal lobe injury in HSE may be informative for diagnosing this group of patients.

The HSE prognosis is related to various factors, such as the application time of antiviral drugs, the patient's immunity, the body's toxic load, etc.<sup>21–23</sup> Although the improvement of diagnostic sensitivity helped us to improve the proficiency

of early detection and diagnosis of mild HSE patients, HSV is still always misdiagnosed and is the most common cause of fatal encephalitis. The overall mortality rate of untreated patients remained at 70%. Only 2.5% of the surviving patients recovered normal neurological function without appropriate treatment. The early diagnosis of the disease is crucial, and if treatment is started within 4 days of onset, the mortality can be reduced to 8%.<sup>19,24,25</sup> In this study, all patients were given antiviral treatment, mainly intravenous treatment, supplemented by oral treatment, 3 patients were given hormone treatment, 1 patient was given intravenous immunoglobulin treatment, and 1 patient was admitted to ICU for respiratory support treatment. Patient No.8 progressed rapidly after admission, presenting deep coma, high fever and status epilepticus. Re-examination of imaging showed diffuse intracranial haemorrhage. However, he was given active treatment and still died of cerebral hernia during hospitalization, suggesting that the patient with CSF deficiency inflammatory response caused by immunosuppressant had a poor prognosis. The other patients had a good prognosis after discharge, suggesting that through timely treatment, patients with low viral load and low inflammatory response in CSF may have a relatively good prognosis.

## Limitations

The sample size in this study is relatively small and might not be representative of the overall population. It is possible that the results obtained may not be generalizable to a larger population, due to the limited sample size and the selected population. Further studies with larger sample sizes are needed to validate the findings of this study and to provide more accurate and comprehensive results. Additionally, it would be helpful to follow up with the patients after their discharge to assess the long-term effects of the treatments and to evaluate the outcome of the disease. Overall, a larger and more comprehensive study would provide a better understanding of the clinical symptoms, imaging characteristics, and treatment outcomes in patients with HSE.

## Conclusion

In conclusion, this study highlights the importance of considering HSE as a potential diagnosis in patients with typical clinical symptoms of encephalitis, regardless of normal CSF and MRI findings. Clinicians should not rely solely on these traditional diagnostic tools, but instead consider the use of mNGS to detect the presence of pathogens in the cerebrospinal fluid. Early detection and prompt antiviral treatment, as well as careful monitoring of patients with concomitant EEG abnormalities and immunosuppression, is crucial for ensuring a good prognosis in HSE patients. Further research with a larger sample size is needed to further understand the clinical characteristics and outcomes of HSE patients with normal CSF and MRI findings.

## Abbreviations

mNGS, metagenomic next-generation sequencing; HSE, Herpes simplex encephalitis; HSV, herpes simplex virus; IIF, Indirect immunofluorescence assay; CBA, Cell-based assay; CSF, cerebrospinal fluid testing; IQRs, interquartile ranges.

## Data Sharing Statement

All the summarized and analyzed data during this study are included in this published article; the original data in this study are available from the corresponding author upon reasonable request.

## Ethics Approval and Consent to Participate

This study was approved by the Ethics Committees of the Harrison International Peace Hospital and was performed in accordance with the 1964 Helsinki declaration. The written informed consent was obtained from each participant.

## Acknowledgments

Zhijia Si and Lin Li should be regarded as co-first authors.

## Funding

There is no funding to report.



## Disclosure

The authors declare that they have no competing interests.

## References

- Mancini M, Caignard G, Charbonneau B, et al. Rel-dependent immune and central nervous system mechanisms control viral replication and inflammation during mouse herpes simplex encephalitis. *J Immunol.* 2019;202(5):1479–1493. doi:10.4049/jimmunol.1800063
- Zhang S-Y. Herpes simplex virus encephalitis of childhood: inborn errors of central nervous system cell-intrinsic immunity. *Hum Genet.* 2020;139(6):911–918. doi:10.1007/s00439-020-02127-5
- Hodgson J, Zuckerman M, Smith M. Development of a novel internal control for a real-time PCR for HSV DNA types 1 and 2. *J Clin Virol.* 2007;38(3):217–220. doi:10.1016/j.jcv.2006.12.014
- Steiner I, Benninger F. Manifestations of herpes virus infections in the nervous system. *Neurol Clin.* 2018;36(4):725–738. doi:10.1016/j.ncl.2018.06.005
- Gnann JW, Whitley RJ. Herpes simplex encephalitis: an update. *Curr Infect Dis Rep.* 2017;19(3):1–12. doi:10.1007/s11908-017-0568-7
- Simner PJ, Miller S, Carroll KC. Understanding the promises and hurdles of metagenomic next-generation sequencing as a diagnostic tool for infectious diseases. *Clin Infect Dis.* 2018;66(5):778–788. doi:10.1093/cid/cix881
- Hogan CA, Yang S, Garner OB, et al. Clinical impact of metagenomic next-generation sequencing of plasma cell-free DNA for the diagnosis of infectious diseases: a multicenter retrospective cohort study. *Clin Infect Dis.* 2021;72(2):239–245. doi:10.1093/cid/ciaa035
- Guan H, Shen A, Lv X, et al. Detection of virus in CSF from the cases with meningoencephalitis by next-generation sequencing. *J Neurovirol.* 2016;22(2):240–245. doi:10.1007/s13365-015-0390-7
- Jakob L, Metzler G, Chen K-M, Garbe C. Non-AIDS associated Kaposi's sarcoma: clinical features and treatment outcome. *PLoS One.* 2011;6(4):e18397. doi:10.1371/journal.pone.0018397
- Avkan-Oguz V, Yapar N, Erdenizmenli M, et al. Effects of community-acquired infections on fever, leukocyte count and length of stay in the elderly. *Saudi Med J.* 2006;27(3):368–372.
- Armangue T, Spatola M, Vlagea A, et al. Frequency, symptoms, risk factors, and outcomes of autoimmune encephalitis after herpes simplex encephalitis: a prospective observational study and retrospective analysis. *Lancet Neurol.* 2018;17(9):760–772. doi:10.1016/S1474-4422(18)30244-8
- Levitz RE. Herpes simplex encephalitis: a review. *Heart Lung.* 1998;27(3):209–212. doi:10.1016/S0147-9563(98)90009-7
- Whitley RJ. Viral encephalitis. *N Engl J Med.* 1990;323(4):242–250. doi:10.1056/NEJM199007263230406
- Jaquet P, De Montmollin E, Dupuis C, et al. Functional outcomes in adult patients with herpes simplex encephalitis admitted to the ICU: a multicenter cohort study. *Intensive Care Med.* 2019;45(8):1103–1111. doi:10.1007/s00134-019-05684-0
- Kapadia RK, Tyler KL, Pastula DM. Encephalitis in adults caused by herpes simplex virus. *CMAJ.* 2020;192(32):E919–E919. doi:10.1503/cmaj.191636
- Yapar N, Sezak N, Cavuş A, et al. Two cases of herpes encephalitis with normal cerebrospinal fluid findings. *Mikrobiyol Bul.* 2006;40(1–2):93–98.
- Hansen MA, Hasbun R. US hospitalizations and 60-day readmission rates associated with herpes simplex virus encephalitis: analysis of all cause readmissions and encephalopathy associated readmissions. *Clin Infect Dis.* 2022;74(7):1174–1182. doi:10.1093/cid/ciab613
- Studahl M, Lindquist L, Eriksson B-M, et al. Acute viral infections of the central nervous system in immunocompetent adults: diagnosis and management. *Drugs.* 2013;73(2):131–158. doi:10.1007/s40265-013-0007-5
- Koskiniemi M, Piiparinen H, Mannonen L, Rantalahti T, Vaheri A. Herpes encephalitis is a disease of middle aged and elderly people: polymerase chain reaction for detection of herpes simplex virus in the CSF of 516 patients with encephalitis. The Study Group. *J Neurol Neurosurg Psychiatry.* 1996;60(2):174–178. doi:10.1136/jnnp.60.2.174
- Bewersdorf JP, Koedel U, Patzig M, et al. Challenges in HSV encephalitis: normocellular CSF, unremarkable CCT, and atypical MRI findings. *Infection.* 2019;47(2):267–273. doi:10.1007/s15010-018-1257-7
- Stahl JP, Mailles A. Herpes simplex virus encephalitis update. *Curr Opin Infect Dis.* 2019;32(3):239–243. doi:10.1097/QCO.0000000000000554
- Quenelle DC, Birkmann A, Goldner T, et al. Efficacy of pritelivir and Acyclovir in the treatment of herpes simplex virus infections in a mouse model of herpes simplex encephalitis. *Antiviral Res.* 2018;149:1–6. doi:10.1016/j.antiviral.2017.11.002
- Gelfand JM. Autoimmune encephalitis after herpes simplex encephalitis: insights into pathogenesis. *Lancet Neurol.* 2018;17(9):733–735. doi:10.1016/S1474-4422(18)30279-5
- Redington JJ, Tyler KL. Viral infections of the nervous system, 2002: update on diagnosis and treatment. *Arch Neurol.* 2002;59(5):712–718. doi:10.1001/archneur.59.5.712
- Mendez MD. Herpes simplex encephalitis. In: *StatPearls.* Treasure Island (FL): StatPearls Publishing; 2023.

Infection and Drug Resistance

Dovepress

Publish your work in this journal

Infection and Drug Resistance is an international, peer-reviewed open-access journal that focuses on the optimal treatment of infection (bacterial, fungal and viral) and the development and institution of preventive strategies to minimize the development and spread of resistance. The journal is specifically concerned with the epidemiology of antibiotic resistance and the mechanisms of resistance development and diffusion in both hospitals and the community. The manuscript management system is completely online and includes a very quick and fair peer-review system, which is all easy to use. Visit <http://www.dovepress.com/testimonials.php> to read real quotes from published authors.

Submit your manuscript here: <https://www.dovepress.com/infection-and-drug-resistance-journal>