

A Sporadic Pediatric Case of Huge Intracranial Supratentorial Desmoid-type Fibromatosis

Naoya IMAI,¹ Naoyuki OHE,¹ Michio OZEKI,² Saori ENDO,² Shiho YASUE,²
and Toru IWAMA¹

¹*Department of Neurosurgery, Graduate School of Medicine, Gifu University, Gifu, Gifu, Japan*

²*Department of Pediatrics, Graduate School of Medicine, Gifu University, Gifu, Gifu, Japan*

Abstract

Desmoid-type fibromatosis (DTF) is a rare locally aggressive soft tissue neoplasm without metastatic potential. Here, we report a very rare sporadic case of an intracranial supratentorial extradural DTF measuring 82 mm in a 1-year-old girl, that recurred twice following surgery over the course of 16 months, requiring two other surgeries. In three surgeries, we resected a huge tumor with the dura which was thought to be tumor origin and removed this tumor infiltrated the frontal skull base by drilling widely. Furthermore, we treated the tumor invading the bone flap using liquid nitrogen for 20 minutes, and subsequently used it to perform a cranioplasty. This tumor has not recurred for past 8 months. DTF invading the skull base is prone to recurrence, and liquid nitrogen treatment is considered to be effective in pediatric patients, who need cranioplasty with tumor-infiltrating autologous bone flaps.

Keywords: pediatric, intracranial, desmoid-type fibromatosis

Introduction

Desmoid-type fibromatosis (DTF) is a locally aggressive myofibroblastic tumor characterized by infiltrative growth and a high probability of recurrence after surgery. However, it lacks metastatic potential.¹⁾ DTF usually arises in deep soft tissue in all areas of the body, but is rarely neoplastic. In particular, intracranial supratentorial DTF has been reported in only three cases.^{2–4)}

Here, we report a very rare pediatric case with a large and aggressive intracranial supratentorial extradural DTF, that recurred twice during the course of 16 months following surgery. Surgical curative resection is the best treatment for DTF; instead of artificial bone, we prefer to use autologous bone flaps with tumor infiltration for cranioplasty in pediatric cases. Liquid nitrogen has been reported to be effective for malignant bone and soft tumors that require bone reconstruction.⁵⁾ We treated the

DTF infiltrated bone flap using liquid nitrogen during the third surgery to prevent recurrence of the tumor that had invaded in the skull, and this tumor has not recurred for the past 8 months. Treatment using liquid nitrogen may also be an option for pediatric DTF invading the skull.

Case Report

A 1-year-old girl was presented with a 10-day history of nausea and vomiting but with no neurological deficits. Her past and family history was unremarkable. Magnetic resonance imaging (MRI) revealed a solitary Gadolinium (Gd) contrast-enhancing 82 mm intracranial extra-axial solid and cystic mass located in the right frontal region (Figs. 1a–1c). The computed tomography (CT) revealed that the tumor had infiltrated the right frontal bone (Fig. 1d). Angiography examination showed that the tumor was supplied exclusively by the middle meningeal artery. In the first operation, we confirmed an extradural tumor (Fig. 2a). Since the tumor was continuous to the convexity dura, we thought its origin was the frontal convexity dura. Hence, the tumor that infiltrated the skull was resected together with the adhered dura. We could not adequately remove the tumor

Received January 10, 2020; Accepted May 11, 2020

Copyright© 2021 by The Japan Neurosurgical Society This work is licensed under a Creative Commons Attribution-NonCommercial-NoDerivatives International License.

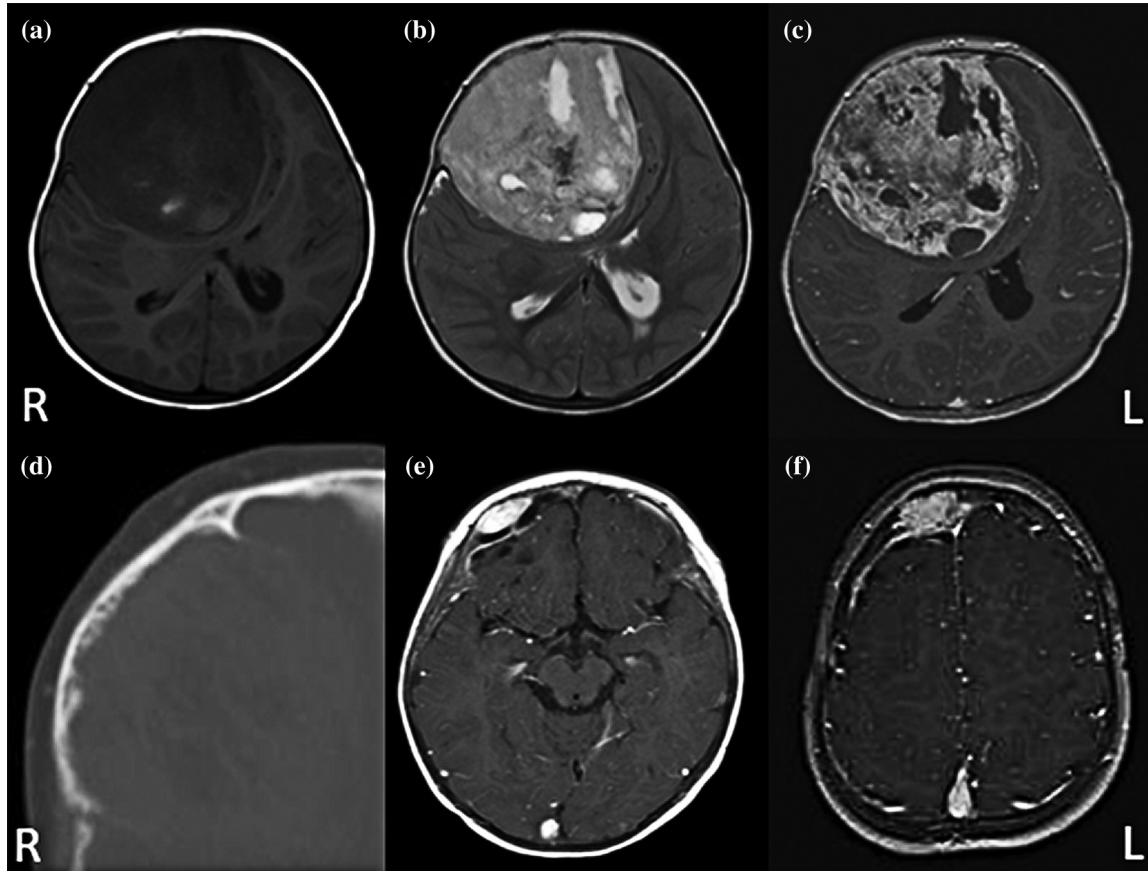


Fig. 1 Initial preoperative MR images of the tumor T1WI (a), T2WI (b), and Gd-enhanced T1WI (c). Initial preoperative bone level CT images of the tumor (d). Gd-enhanced MRI images of the tumor at first (e) and second recurrences (f). CT: computed tomography, Gd: gadolinium, MRI: magnetic resonance imaging, T1WI: T1-weighted image, T2WI: T2-weighted image.

invading the frontal skull, as the blood loss during removal of a large tumor would be exceed 1000 mL. Histopathological examination showed a proliferation of a band of spindle-shaped cells of uniform appearance (Fig. 3a), and the tumor was continuous with the dura (Fig. 3b). Mitotic figures were inconspicuous, and the MIB-1 labeling index was 5% (Fig. 3c). On immunohistochemical (IHC) analysis, the nuclei of the tumor cells were strongly positive for β -catenin (Fig. 3d), but were negative for S100 protein, EMA, CD34, STAT6, and MUC4. After 5 months from the first surgery, the tumor had recurred from the region where it had infiltrated the skull base (Fig. 1e). In the second operation, we performed wide excision by drilling until we exposed the normal bone; this was performed to remove the tumor that had infiltrated the frontal skull base (Fig. 2b). The tumor that had invaded the free bone flap (Fig. 2c) was removed by drilling as much as possible. However, 11 months after the second operation, the tumor recurred at the convexity and

not at the skull base (Fig. 1f). During the third surgery, evaluation suggested that the tumor may have recurred from the free bone flap. Therefore, after removing the tumor, we treated the bone flap using liquid nitrogen for 20 minutes (Fig. 2d), and subsequently performed a cranioplasty with it. After the third operation, this tumor has not recurred for the past 8 months.

Discussion

DTF is defined by the World Health Organization as a locally aggressive myofibroblastic neoplasm that usually arises in deep soft tissue. It is characterized by an infiltrative growth and a tendency toward local recurrence but lacks metastatic potential.¹⁾ DTF is rare, accounting for approximately 0.03% of all neoplasms and has an incidence of 2–4 per million per year.^{2,5)} In particular, intracranial supratentorial DTF is very rare and only three cases have been reported to date^{2–4)} (Table 1).

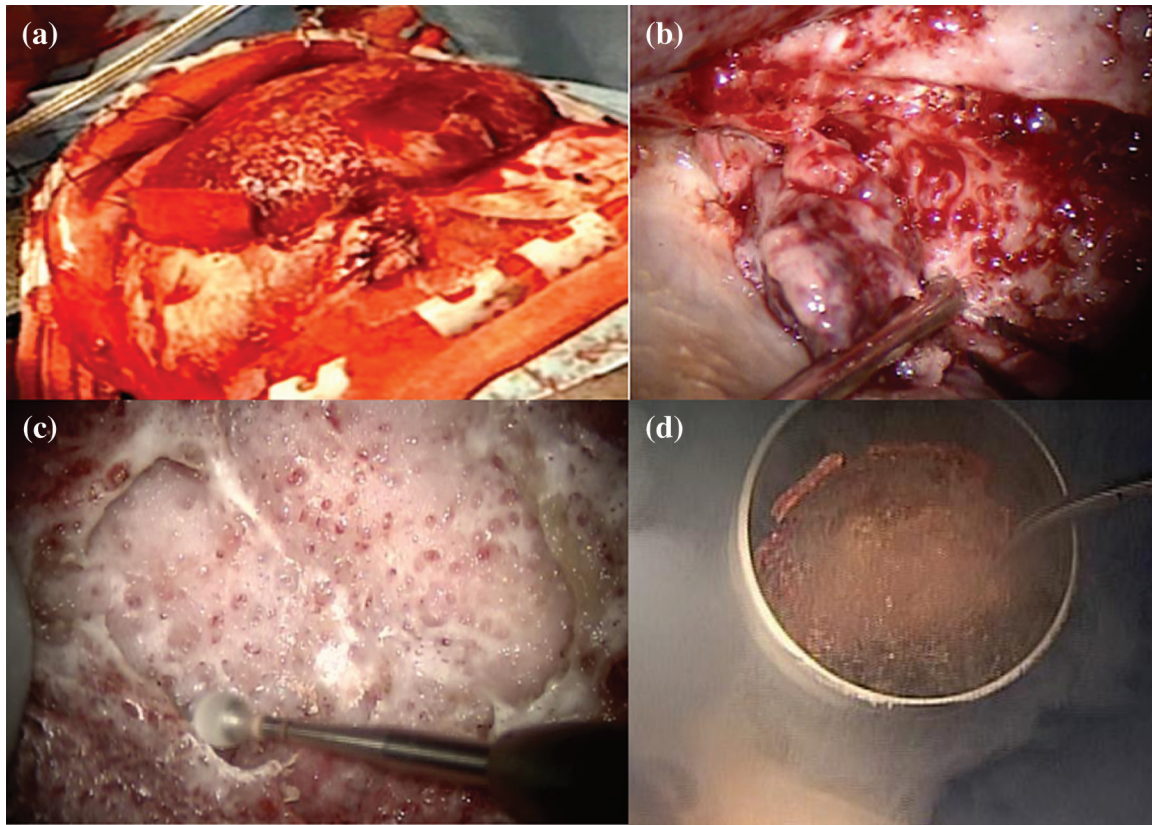


Fig. 2 Intraoperative photograph of the tumor at the time of craniotomy (a), tumor infiltrated to frontal skull base (b) and frontal bone flap (c), and (d) free bone flap infiltrated tumor treated with liquid nitrogen.

Table 1 Summary of previously reported intracranial supratentorial desmoid-type fibromatosis (DTF) cases.

Case no	Age	Gender	Site of DTF	Follow up	Treatment	Adjuvant therapy	Relapse	Family history	Reference
1	3	M	Frontal Extradural	12 months	Resection	No	No	FAP	10
2	1	M	Frontal Extradural	36 months	Total resection	No	No	No	8
3	11	M	Parietal Extradural	N.A.	Total resection	No	No	FAP	2
	14		Frontal Extradural		Total resection				
4	1	F	Frontal Extradural	20 months	Resection	No	5 months 14 months	No	Our case

DTF: desmoid-type fibromatosis, F: female, FAP: familial adenomatous polyposis, M: male, N.A.: not applicable.

Most DTF cases arise sporadically and up to 30% of patients have a history of antecedent trauma, surgical intervention,^{1,6)} and high-estrogen status. However, some may be associated with germline mutations such as familial adenomatous polyposis (FAP) syndrome and Gardner's syndrome. These cases of hereditary syndromes have a poorer prognosis than sporadic cases^{1,2,6)}

The different diagnosis of DTF is broad, encompassing both benign and malignant forms. For instance, DTF is sometimes histologically similar to keloids, nodular fasciitis, and low-grade fibromyxoid sarcomas.^{7,8)} However, it is the presence of nuclear β -catenin that supports a diagnosis of DTF.^{1,9)} Other differential diagnoses include intracranial infantile myofibromatosis, fibrous meningioma, and

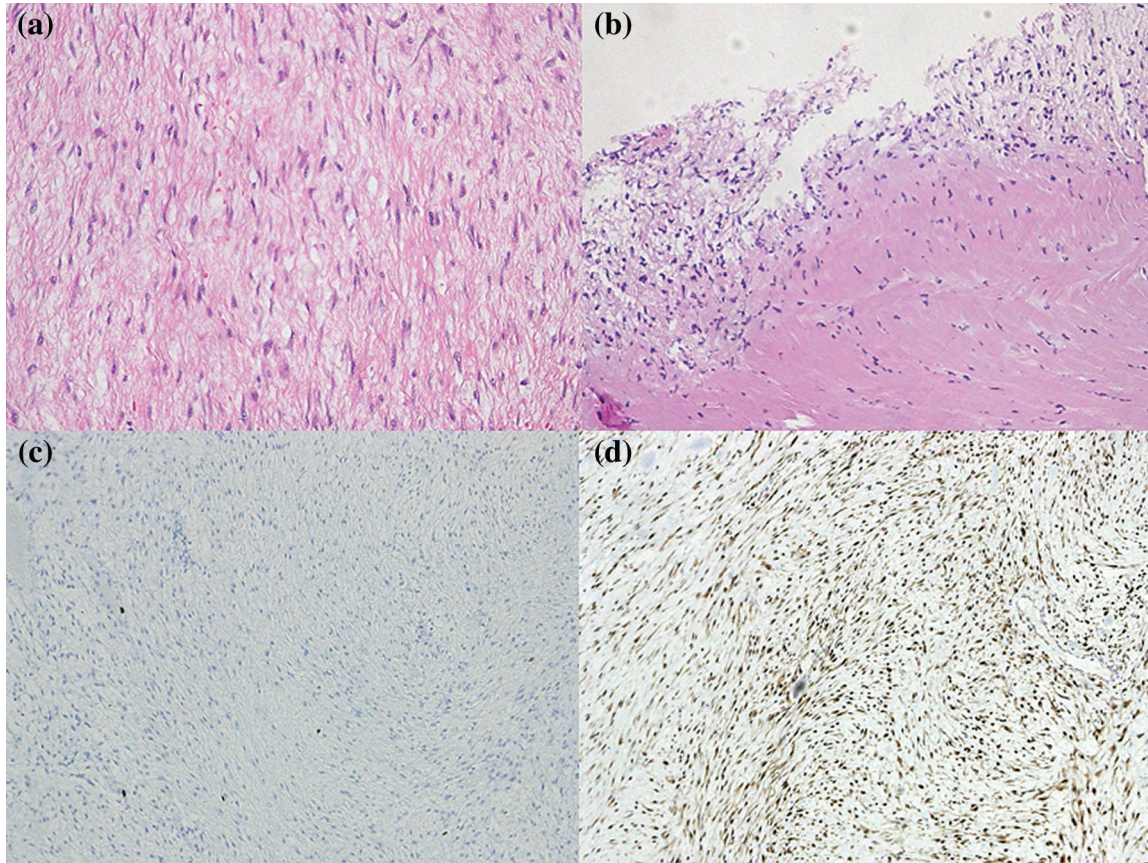


Fig. 3 Photomicrographs of hematoxylin–eosin stained sections of the tumor $\times 200$ (a), and the part where the tumor continued to the dura $\times 200$ (b), immunohistochemistry of MIB-1 $\times 40$ (c) and β -catenin $\times 40$ (d).

solitary fibrous tumor, all of which can be differentiated by IHC.

It is reported that local recurrence rates after the first initial management range from 20% to 40%. Risk factors include the patient's age (<37 years), large tumor size (>7 cm), and extra-abdominal or skull base tumor locations,^{3,10)} β -catenin gene (*CTNNB1*) mutations.⁶⁾ This case had the following risk factors for recurrence: the patient was 1-year old, the tumor was large (82 mm), was located at the base of the skull base, and possibly had *CTNNB1* gene mutations.

Since DTF is most likely to have infiltrative growth and a tendency toward local recurrence, it is important to resect the tumor with negative margins.^{3,11)} In the cases 1–3 (reported to date) presented in Table 1, the DTF tumors were located only at the convexity, and not the skull base. We deduced that there was no recurrence as curative resections were possible. Regarding adjuvant therapy, the efficacy of radiation therapy has not been established by large trials, while chemotherapy is controversial.¹²⁾ Reports indicate that chemotherapy with methotrexate and vinblastine is effective in

the patients with DTF regardless of *CTNNB1* mutation status.¹²⁾ As an additional treatment, liquid nitrogen has been reported to be effective for malignant bone and soft tumors that require bone reconstruction.⁵⁾ In this pediatric case, we intended to use an autologous bone flap instead of artificial bone for cranioplasty. Therefore, we performed a 20-minute liquid nitrogen treatment, which was considered sufficient to kill the tumor cells that had invaded the skull. DTF invading the skull base is prone to recurrence, and liquid nitrogen treatment is considered to be effective in pediatric patients who need cranioplasty with tumor-infiltrating autologous bone flaps.

Conflicts of Interest Disclosure

None

References

- 1) Fletcher CDM, Bridge JA, Hogendoorn PCW, Mertens F: *WHO Classification of Tumors of Soft Tissue and Bone*. Lyon, IARC Press, 2013

- 2) Chung KH, Charlton A, Arbuckle S, Chaseling R, Oowler BK: Metachronous multifocal desmoid-type fibromatoses along the neuraxis with adenomatous polyposis syndrome. *J Neurosurg Pediatr* 6: 372–376, 2010
- 3) Wang B, Ma J, Jin H: Infantile intracranial aggressive fibromatosis: report of two cases with a review of the literature. *Pediatr Neurosurg* 48: 181–186, 2012
- 4) Yazici N, Yalçın B, Soylemezoğlu F, et al.: Intracranial desmoid tumor with familial adenomatous polyposis coli. *Pediatr Neurosurg* 44: 140–143, 2008
- 5) Yamamoto N, Tsuchiya H, Tomita K: Effects of liquid nitrogen treatment on the proliferation of osteosarcoma and the biomechanical properties of normal bone. *J Orthop Sci* 8: 374–380, 2003
- 6) De Vloo P, De Vlioger J, Vander Poorten V, Sciot R, van Loon J, Van Calenbergh F: Desmoid tumors in neurosurgery: a review of the literature. *Clin Neurol Neurosurg* 129: 78–84, 2015
- 7) Lazar AJ, Tuvin D, Hajibashi S, et al.: Specific mutations in the beta-catenin gene (CTNNB1) correlate with local recurrence in sporadic desmoid tumors. *Am J Pathol* 173: 1518–1527, 2008
- 8) Novello M, Di Rocco C, Tamburrini G, et al.: Recurrent adult-type fibrosarcoma of the frontal bone in a child. *Childs Nerv Syst* 32: 1169–1173, 2016
- 9) Carlson JW, Fletcher CD: Immunohistochemistry for beta-catenin in the differential diagnosis of spindle cell lesions: analysis of a series and review of the literature. *Histopathology* 51: 509–514, 2007
- 10) Salas S, Dufresne A, Bui B, et al.: Prognostic factors influencing progression-free survival determined from a series of sporadic desmoid tumors: a wait-and-see policy according to tumor presentation. *J Clin Oncol* 29: 3553–3558, 2011
- 11) Melis M, Zager JS, Sondak VK: Multimodality management of desmoid tumors: how important is a negative surgical margin? *J Surg Oncol* 98: 594–602, 2008
- 12) Nishida Y, Tsukushi S, Urakawa H, et al.: Low-dose chemotherapy with methotrexate and vinblastine for patients with desmoid tumors: relationship to CTNNB1 mutation status. *Int J Clin Oncol* 20: 1211–1217, 2015

Corresponding author: Naoyuki Ohe, MD, PhD
Department of Neurosurgery, Graduate School of
Medicine, Gifu University, 1-1 Yanagido, Gifu, Gifu
501-1194, Japan.
e-mail: ohe@gifu-u.ac.jp