

Case Report

Successful Coronary Flow Restoration by Stent-Free Strategy Using the Pull-Back Method of Cutting Balloon in Spontaneous Coronary Artery Dissection

Esra Kaya, MD,^a Hiroshi Iwata, MD,^a Sakiko Miyazaki, MD,^a Peter C. Mattson,^b Kazuhisa Takamura, MD,^a Hiroki Nishiyama, MD,^a Iwao Okai, MD, PhD,^a Shinya Okazaki, MD,^a and Hiroyuki Daida, MD^a

^a Juntendo University Graduate School of Medicine, Department of Cardiovascular Medicine, Tokyo, Japan

^b Warren Alpert Medical School, Providence, Rhode Island, USA

ABSTRACT

This report describes a 46-year-old woman with ST-elevation myocardial infarction due to spontaneous coronary artery dissection. Because continuous chest pain and ST-segment elevation in electrocardiography indicated ongoing cardiac ischemia, the urgent revascularization strategy was used using a novel method of cutting balloon angioplasty, “the pull-back of inflated cutting balloon,” which led to the successful coronary flow restoration and complete healing of dissected coronary artery in 1 year. The pull-back of the inflated cutting balloon method is a useful therapeutic option in the treatment of patients with spontaneous coronary artery dissection with ongoing cardiac ischemia.


RÉSUMÉ

Le présent rapport décrit le cas d'une femme de 46 ans ayant subi un infarctus du myocarde avec élévation du segment ST dû à une dissection spontanée de l'artère coronaire (DSAC). Compte tenu de la douleur thoracique continue et de l'élévation du segment ST à l'électrocardiographie, signes indicateurs d'une ischémie cardiaque en cours, une revascularisation d'urgence a été employée à l'aide d'une nouvelle méthode d'angioplastie au ballon coupant. « La traction du ballon coupant gonflé » a permis en l'espace d'un an de restaurer avec succès le débit coronarien et d'obtenir une cicatrisation complète de l'artère ayant subi la déchirure. La méthode de traction du ballon coupant gonflé s'avère une option thérapeutique utile dans le traitement des patients présentant une DSAC associée à des symptômes d'ischémie cardiaque.

Spontaneous coronary artery dissection (SCAD) has been gathering attention as one of the most important causes of acute coronary syndrome, especially in young women. However, the treatment of SCAD has not been fully established.¹ In this report, we present a case of SCAD that was successfully revascularized by the fenestration method via the pull-back of an inflated cutting balloon without stenting.

Case

A 46-year-old, premenopausal woman without reproductive history, cardiovascular risk factors, cocaine use, malignant hypertension, and any connective tissue disease

presented to the emergency department with continuous chest pain. The day before, she had been referred to our institution for further evaluation of the T-wave inversion in the anterior (V1-V4) leads in electrocardiography. On presentation, her electrocardiography demonstrated ST-segment elevation in leads V5 and V6, with concomitant elevation of cardiac troponin T to 0.181 ng/mL and an apical wall motion abnormality of the left ventricle by echocardiography with an ejection fraction of 59% (Video 1 ; view video online). Emergency coronary angiography (CAG) via a left radial artery approach revealed a severe stenosis in the mid to distal portion of the left anterior descending (LAD) artery, in addition to significant compromise to coronary flow (thrombolysis in myocardial infarction flow grade 2) (Fig. 1) with no other atherosclerotic change in her coronary artery. On the basis of these findings, we diagnosed her with ST-elevation myocardial infarction due to spontaneous coronary artery dissection (SCAD) in the LAD, angiographically classified as type 2.² Because of her persistent chest pain and ST-segment elevation indicating ongoing ischemia, we performed intracoronary imaging followed by

Received for publication March 7, 2019. Accepted May 22, 2019.

Ethics Statement: This case report is following the CARE guideline.

Corresponding author: Dr Hiroshi Iwata, Juntendo University Graduate School of Medicine, Department of Cardiovascular Medicine, Hongo 2-1-1, Bunkyo, Tokyo, Japan 113-0033. Tel.: +81-3-3813-3111; fax: +81-3-5689-0627.

See page 215 for disclosure information.

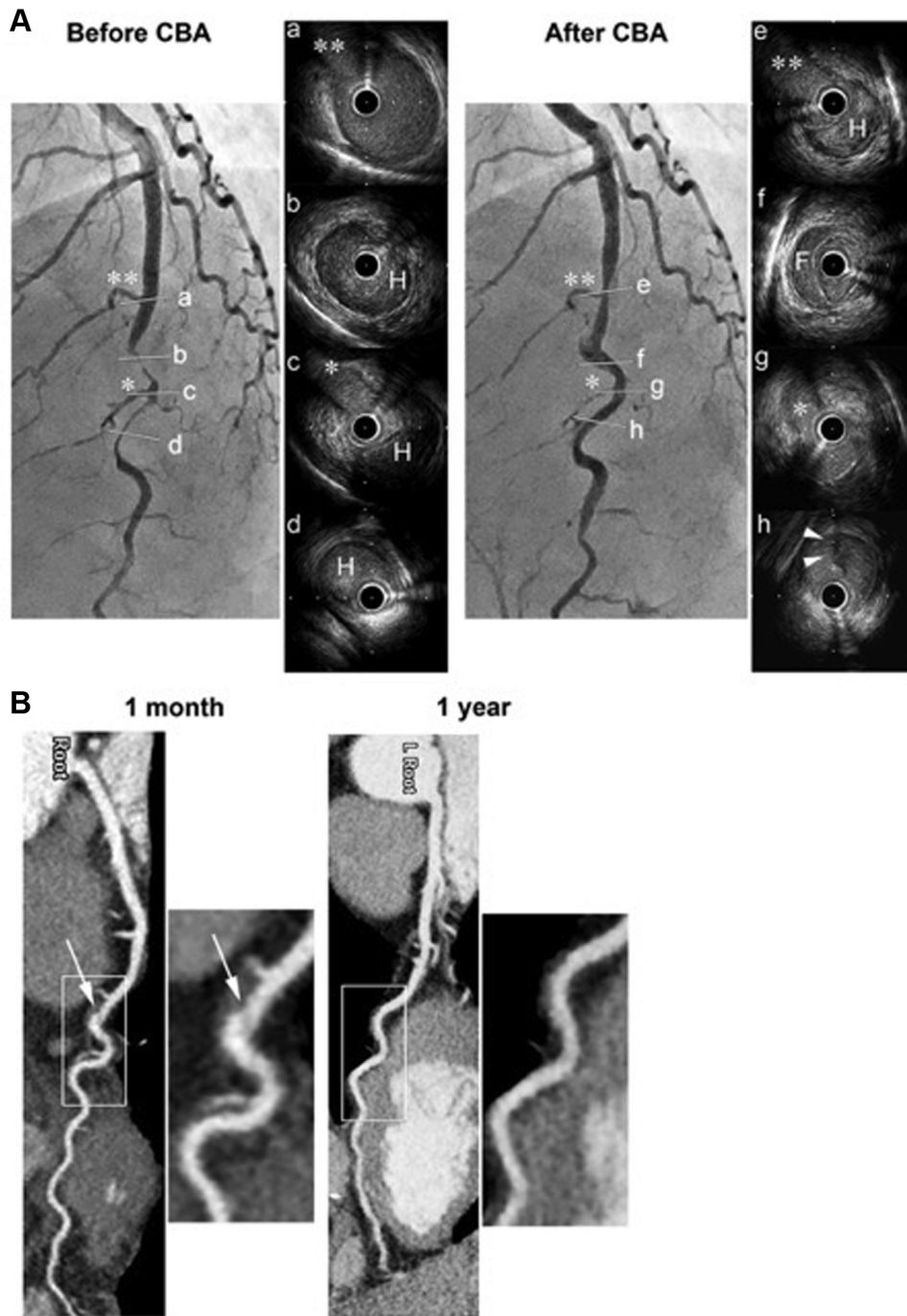



Figure 1. Angiograms and serial intravascular ultrasound (IVUS) images before and after the pull-back of an inflated cutting balloon and sequential coronary computed tomography angiograms in a spontaneous coronary artery dissection (SCAD) case. **(A)** Fenestration between true and false lumens by the pull-back method of inflated cutting balloon led to the decompression of intramural hematoma (IMH) and coronary flow restoration, even though the dissection slightly propagated to the proximal site. **(Arrowheads)** Intimal flap in the distal hematoma. F = false lumen; H = intramural hematoma. (*, **) Corresponding septal branches between angiograms and IVUS images. **(B)** Coronary computed tomography angiograms 1 month and 1 year later indicated appropriate healing process in the left anterior descending (LAD) artery. The residual intimal flap observed **(arrows)** at the 1-month time point was not detected 1 year later.

urgent percutaneous coronary intervention. After the careful crossing of a 0.014-inch guidewire (SION blue, ASAHI Intech, Seto, Japan), intravascular ultrasound (IVUS) (Altview, Terumo, Tokyo, Japan) demonstrated a massive

intramural hematoma (IMH) compressing the true lumen (Fig. 1A). A 2.5-mm cutting balloon (Flextome, 2.5 × 10 mm, Boston Scientific, MA) was inflated to 4 atm and pulled back in 3-mm increments over 3 periods.

Novel Teaching Points

- Spontaneous coronary artery dissection (SCAD) is one of the most important causes of acute coronary syndrome, especially in young women.
- However, the treatment of SCAD has not been established yet and is still under debate.
- For urgent restoration of coronary flow in patients with SCAD with ongoing cardiac ischemia, a novel stent-free strategy, the pull-back of inflated cutting balloon, might be an effective therapeutic option.

Immediately after inflation and the pull-back of the cutting balloon, coronary flow became restored to thrombolysis in myocardial infarction 3 with nearly complete resolution of acute coronary syndrome symptoms and ST-segment elevation. Moreover, IVUS showed intimal disruption and a significant reduction of IMH burden (Fig. 1A). This strategy was chosen before starting the procedure, because pull-back of the cutting balloon is deemed safer and more efficient compared with balloon inflation with higher pressure. Our goal of maintaining coronary flow led to the placement of an intra-aortic balloon pump for 24 hours after the procedure, although the patient was hemodynamically stable. Repeat echocardiography performed 3 days later showed no wall motion abnormality and a calculated ejection fraction recovered up to 67% (Video 2 ; view video online). A follow-up CAG 3 days later and a coronary computed tomography angiography at 1 month and 1 year (Fig. 1B) after the procedure demonstrated the appropriate healing process of coronary artery dissection.

Discussion

For patients with SCAD, expert opinions based on observational studies generally recommend conservative medical therapy, including beta-blockers and antiplatelets.³ This is recommended because dissected arteries spontaneously heal within 1 month in most cases (>70%),⁴ and the revascularization strategy may be associated with a higher failure rate (50%-70%), resulting in major adverse cardiac events.⁵ Nevertheless, when ongoing ischemia or hemodynamic instability is present, the revascularization strategy is required. In such cases, long stenting for complete coverage of the dissected lesion with 5- to 10-mm margins at both the proximal and the distal ends of the false lumen is recommended for avoiding IMH propagation. Recently, the usefulness of cutting balloon angioplasty is becoming recognized.⁶

Intracoronary imaging is an evolving technology for diagnosing SCAD. In a recent case report by Bresson et al.,⁷ optical coherence tomography was used to show IMH and false lumen progression in a patient with SCAD treated with the cutting balloon strategy. optical coherence tomography provides more detailed information with significantly higher resolution than IVUS. However, because this requires a volume (10-15 mL) of

contrast or low-molecular-weight dextran, it may be associated with elevated risk of the IMH propagation.

In this case, the dissected lesion occurred in the mid to distal LAD, and distal reference diameter size demonstrated by IVUS indicated that long stenting may not be appropriate.⁸ Therefore, we primarily tried to fenestrate the false lumen to the true lumen by the pull-back method of a modestly inflated cutting balloon fitted to the distal reference diameter. Stenting served as an alternative in case the coronary flow remained compromised even after this procedure. The coronary flow was successfully restored, and follow-up CAG and coronary computed tomography angiography revealed the nearly complete healing of the dissected LAD. In pursuing urgent coronary flow restoration in patients with SCAD with ongoing cardiac ischemia, this stent-free strategy aimed at fenestration by not only the inflation but also the pull-back of the inflated cutting balloon may be beneficial for treating decompressions by IMH. This leads to the restoration of coronary flow and a reduction in risk of IMH propagation through stent deployment.

Disclosures

The authors have no conflicts of interest to disclose.

References

1. Saw J, Mancini GBJ, Humphries KH. Contemporary review on spontaneous coronary artery dissection. *J Am Coll Cardiol* 2016;68:297-312.
2. Saw J, Mancini GB, Humphries K, et al. Angiographic appearance of spontaneous coronary artery dissection with intramural hematoma proven on intracoronary imaging. *Catheter Cardiovasc Interv* 2016;87:E54-61.
3. Alfonso F, Paulo M, Lennie V, et al. Spontaneous coronary artery dissection: long-term follow-up of a large series of patients prospectively managed with a "conservative" therapeutic strategy. *JACC Cardiovasc Interv* 2012;5:1062-70.
4. Hassan S, Prakash R, Starovoytov A, Saw J. Natural history of spontaneous coronary artery dissection with spontaneous angiographic healing. *JACC Cardiovasc Interv* 2019;12:518-27.
5. Lettieri C, Zavalloni D, Rossini R, et al. Management and long-term prognosis of spontaneous coronary artery dissection. *Am J Cardiol* 2015;116:66-73.
6. Alkhouli M, Cole M, Ling FS. Coronary artery fenestration prior to stenting in spontaneous coronary artery dissection. *Catheter Cardiovasc Interv* 2016;88:E23-7.
7. Bresson D, Calcaianu M, Lawson B, Jacquemin L. Coronary artery fenestration as rescue management of intramural haematoma with luminal compression. *Catheter Cardiovasc Interv* 2019;94:E17-9.
8. Saw J. Natural history of spontaneous coronary artery dissection: to stent or not to stent? *EuroIntervention* 2019;14:1353-6.

Supplementary Material

To access the supplementary material accompanying this article, visit the online version of the *Canadian Journal of Cardiology* at www.onlinecjc.ca and at <https://doi.org/10.1016/j.cjco.2019.05.008>.