



Preprocedural Ultrasound Estimates of Epidural Depth: Transverse Median Plane is Comparable to Paramedian Sagittal Oblique Plane in Non-Pregnant Patients

Mehmet Cantürk¹ , Nazan Kocaoğlu² , Meltem Hakkı¹ 

¹Department of Anaesthesiology and Reanimation, Kırşehir Ahi Evran University Training and Research Hospital, Kırşehir, Turkey

²Department of Anaesthesiology and Reanimation, Balıkesir University School of Medicine, Balıkesir, Turkey

Cite this article as: Cantürk M, Kocaoğlu N, Hakkı M. Preprocedural Ultrasound Estimates of Epidural Depth: Transverse Median Plane is Comparable to Paramedian Sagittal Oblique Plane in Non-Pregnant Patients. *Turk J Anaesthesiol Reanim* 2020; 48(1): 31-7.

Abstract

Objective: The aim of this study was to assess the accuracy and precision of the actual epidural depth (ND) and ultrasound (US) estimates of the distance from the skin to the epidural space in the transverse median plane (ED/TM) and paramedian sagittal oblique plane (ED/PSO) in patients who were not pregnant and who were undergoing unilateral inguinal hernia repair surgery under combined spinal epidural anaesthesia.

Methods: A total of 100 patients with the American Society of Anaesthesiology status I–III of either gender were recruited. All epidurals were inserted at the L3–4 intervertebral space, and the epidural needle was marked with a sterile marker. The ND was measured between the marker and the tip of the needle. The ED/TM and ED/PSO were assessed with a 2–5 MHz curved array probe at the L3–4 intervertebral space. The Pearson correlation coefficient and Lin's concordance correlation coefficient were used to assess the precision and the Bland–Altman test was used to assess the 95% limit of agreement.

Results: The ND was 48.98 ± 6.91 mm, the ED/PSO was 48.92 ± 6.91 mm and the ED/TM was 48.90 ± 6.91 mm. The Pearson correlation coefficient between ND and ED/PSO was 0.995 ($p < 0.001$) and 0.994 ($p < 0.001$) with ED/TM. Lin's concordance correlation coefficient for ND and ED/PSO was 0.995 (95%CI [confidence interval]: 0.992–0.997), and 0.993 for ND and ED/TM (95% CI: 0.990–0.996). The 95% limit of agreement between ND and ED/PSO was 0.70–1.37, and for ND and ED/TM, it was 0.79–1.54.

Conclusion: Preprocedural ultrasound (US) scanning in both planes provides reliable estimates for actual epidural depth in non-pregnant patient population.

Keywords: Epidural depth, paramedian sagittal oblique, transverse median, ultrasound

Introduction

Unilateral inguinal hernia repair surgery is usually done under combined spinal epidural anaesthesia (CSE). The epidural component is the most challenging part of the CSE procedure. Inaccurate identification of epidural space may lead to failed neuraxial anaesthesia, repeated needle insertions, patient discomfort, paraesthesia, inadvertent dural puncture, post-dural puncture headache and spinal cord injury.

Combined spinal epidural is performed with a so-called blind technique. Ultrasound (US) has become a complement for neuraxial anaesthesia (1). Preprocedural US scanning facilitates epidural needle placement (2-4) and the identification of the desired intervertebral space. Scout US scanning of neuraxis provides information on the point-of-needle insertion, estimated epidural depth and the needle trajectory. However, Halpern (5) reported that a total of 36 patient examinations with US are required to reliably identify the desired intervertebral space.

The accuracy between the actual epidural depth (ND) and the US-estimated skin-to-epidural-space depth (ED) in transverse median plane (TM) has been extensively studied (2, 6-19). Most of these studies were performed in parturients (2, 6, 7, 9, 10, 13, 14, 16, 17, 19). There are a limited number of studies assessing the ED in the paramedian sagittal oblique plane (PSO) at the lumbar (19) and thoracic region (20).

The PSO view provides a larger acoustic window than TM in parturients (19, 21, 22), but Sahota et al. (19) reported that the ED in both planes could be used interchangeably in parturients. This knowledge needs to be validated in the non-pregnant patient population.

In the present study, we hypothesised that ED in PSO is comparable with TM to estimate the preprocedural ND in the non-pregnant patient population at the lumbar level.

Methods

After an approval from the institutional review board, the study was approved by the Kırşehir Ahi Evran University Ethics Committee (2017-20/243, 12/26/2017), and it was prospectively registered at Australian New Zealand Clinical Trials Registry (ACTRN12618000585224). Written informed consent was obtained from all patients. This prospective observational study was prepared in accordance with the Declaration of Helsinki and strengthening the reporting of observational studies in epidemiology (STROBE) guidelines. A total of 100 patients aged >18 years, scheduled for unilateral inguinal hernia repair surgery under CSE and with the

American Society of Anesthesiologists' (ASA) physical status I–III of either gender were enrolled. Patients meeting one of the following criteria were excluded: the ASA physical status >III, previous spine or spinal canal surgery, vertebral canal deformity, any contraindication to neuraxial anaesthesia, anticoagulant drug medication, infection at the puncture site, age <18 years or >80 years and emergency cases.

Demographic data of the patients (age, height, weight, body mass index, ASA physical status) were recorded. Patients were monitored with electrocardiogram and pulse oximeter, and their blood pressure was monitored noninvasively. An intravenous line was secured for intravenous medication and hydration.

All patients underwent US scanning in the sitting position with a footstool under their feet. Knees, hips, the neck and lower back were flexed. The patient position was same during the US assessments and the CSE procedure. All US scanings were done with a 2–5 MHz curved array probe (Esaote Mylab30, Florence, Italy) before the CSE procedure under non-sterile conditions. The US scanning was done by the same anaesthesiologist (MC) who had 6 years of experience in neuraxial sonoanatomy at both TM and PSO for each patient at the L3–4 intervertebral space.

The US scanning started initially in PSO at the sacral region to visualise the hyperechoic continuous line of the sacrum. The curved array probe was located 2–3 cm laterally to midline and tilted medially to capture the PSO view image of the vertebral canal (Figure 1). In the PSO plane, we could observe the sacrum, spinous processes, ligamentum flavum, posterior duramater, cauda equina and anterior duramater as hyperechoic structures and subcutaneous tissue, muscle layers, epidural space and intrathecal space as hypoechoic structures. Once the sacrum was identified, the probe was moved cephalad to visualise the sawtooth-like appearance. The acoustic shadows represented the spinous processes, and the acoustic windows represented the intervertebral spaces. The US probe was moved cephalad until the L3–4 intervertebral space was centered. The monitor was frozen for further measurement of skin-to-epidural depth with the built-in calliper of the US device in millimetres. The skin was marked on both sides of the probe at midline to identify the level of L3–4 intervertebral space in the horizontal plane. After completion of ED measurements in PSO (ED/PSO), the probe was rotated to TM on the predetermined horizontal line at the L3–4 intervertebral space. The curved array probe was moved cephalad or caudad to visualise the spinous process. Once the spinous process was identified, the skin was marked on both sides of the probe in the midline. The skin marks were elongated as a vertical line to determine the midline. The US probe was tilted upwards

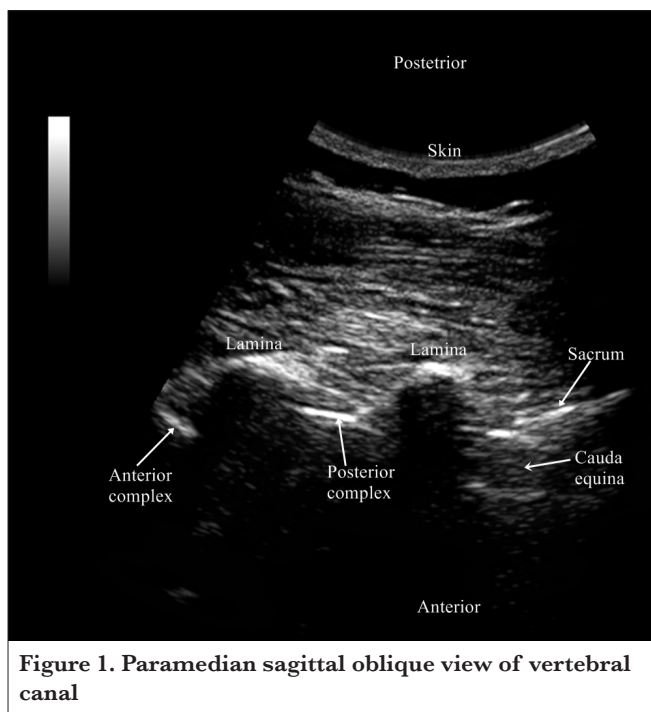


Figure 1. Paramedian sagittal oblique view of vertebral canal

or downwards to capture the best image for vertebral sonography (Figure 2) at L3–4 acoustic window. The hyperechoic structures observed in TM plane were the spinous process, articular processes, transverse processes, posterior complex (i.e., ligamentum flavum, posterior epidural space, posterior duramater) and anterior complex (i.e., anterior duramater and vertebral body). The monitor was frozen for the measurement of ED in TM (ED/TM). The intersection of lines obtained by the elongation of skin marks in PSO and TM determined the point of insertion for the epidural needle (BBraun, Melsungen AG, Melsungen, Germany). Both the ED/PSO and ED/TM were measured starting from the skin to the posterior border of the posterior complex with the built-in calliper of the US device in millimetres.

With the completion of the US assessments, the skin was prepared aseptically, and a sterile drape was wrapped on the back of the patient. The skin and subcutaneous tissue were infiltrated with 5 ml 2% lidocaine. The anaesthesiologist performing CSE was blinded for the ED but was informed about the insertion point for the epidural needle. The CSE procedure was performed by an anaesthesiologist that had more than 10 years of experience in neuraxial anaesthesia (NK, MH). The loss of resistance to the air technique with a midline approach at the L3–4 intervertebral space was used to identify the epidural space in all patients. The epidural needle was marked with a sterile marker following the identification of epidural space. The spinal needle was introduced to intrathecal space with the needle-through-needle technique. With the observation of free-flowing clear cerebrospinal fluid, 3 mL 0.5% hyperbaric bupivacaine was injected into the intrathecal space, and the spinal needle was withdrawn. The epidural catheter was located with 5 cm in the epidural space, and the epidural needle was removed. The actual ND was measured with a linear scale starting from the tip of the epidural needle to the sterile marker in millimetres. The spread

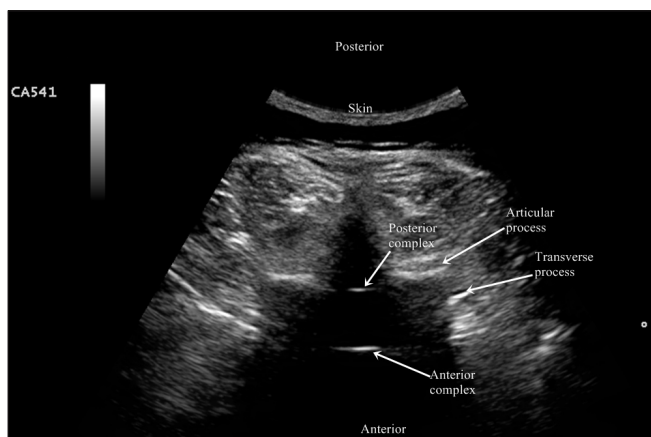


Figure 2. Transverse median plane view of the vertebral canal

of spinal anaesthesia was assessed with the loss of sensation to pain with the pinprick test in both midclavicular lines. Surgery was commenced when the sensory block level reached the T6 dermatome level.

The primary outcomes of the study were to determine the ND, ED/PSO and ED/TM at the L3–4 level in patients scheduled for unilateral inguinal hernia repair surgery under CSE. The objective of the study was to determine the precision and the accuracy between ND and ED in both planes at the L3–4 level in non-pregnant patients.

Statistical analysis

Normal distribution of data were analysed using the Shapiro–Wilk test. The normally distributed data were expressed as the mean±standard deviation (SD). Categorical variables were presented as percentages. The Pearson correlation coefficient and the paired t-test were used to analyse the precision between ND, ED/PSO and ED/TM. Lin’s concordance correlation coefficient (23, 24) was used to analyse the accuracy between the measurements. One sample t-test was used for the comparison of means. The mean difference between the measurements was calculated by subtracting ED/PSO or ED/TM from ND divided by two. The mean of measurements was calculated by the summation of the ED/PSO or ED/TM with the ND, divided by two. The mean difference of measurements was graphically plotted against the mean of measurements to obtain the Bland–Altman diagram (25, 26) presenting the 95% limit of agreement between the ND, ED/PSO and ED/TM.

The sample size was calculated based on a previous study reported by Arzola et al. (6). In that study, the correlation coefficient was 0.88 between ND and ED, and the mean difference was 0.01 ± 0.3 cm. We assumed a correlation coefficient of 0.90 and a SD of 0.1 mm. With an α error set at 0.05 and a β error of 0.1, 92 patients would be required. We enrolled 100 patients in the study to compensate for the probable dropouts.

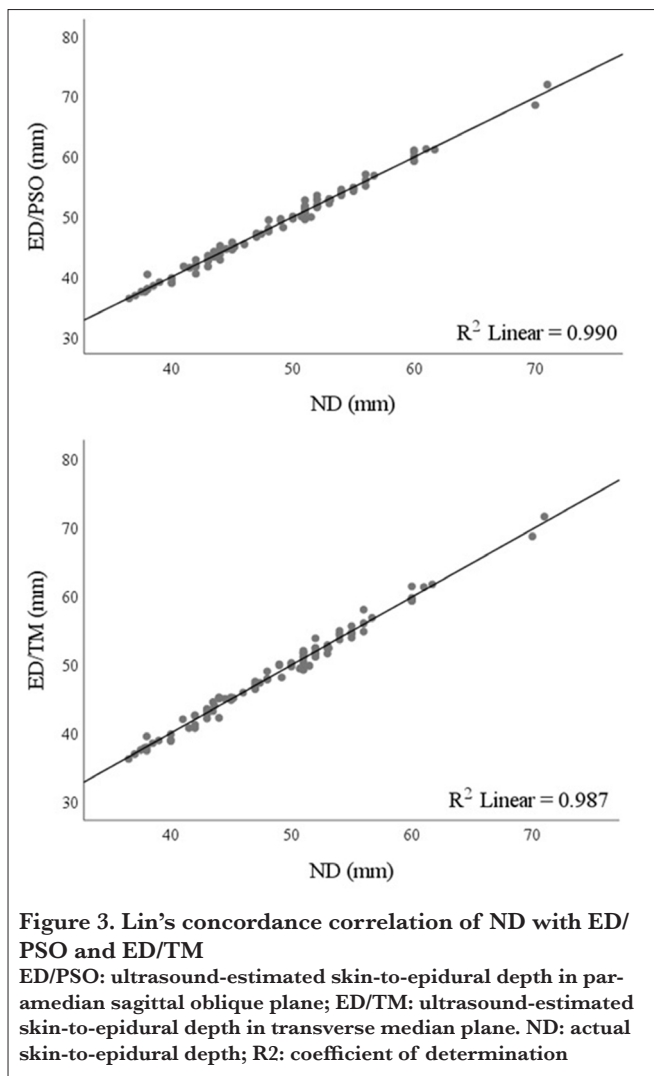
Results

A hundred of patients were enrolled in this study, and they were all considered for the analysis. There were no dropouts. The mean age of the patients was 49.33 ± 14.56 years, and the mean height was 168.66 ± 0.09 cm. The mean patient weight was 77.37 ± 12.25 kg. The mean BMI was 27.36 ± 4.91 kg m⁻². According to the ASA physical status classification, 49 patients were in the ASA physical status I, 40 in the ASA physical status II and 11 in the ASA physical status III. Thirty-four patients were female, and 66 were male. The mean ND was 48.98 ± 6.91 mm, the mean ED/PSO was 48.92 ± 6.91 mm and the mean ED/TM was 48.90 ± 6.91 mm (Table 1).

The Pearson correlation coefficient between the ND and ED/PSO was 0.995 ($r^2=0.990$, $p<0.001$). The concordance correlation coefficient between the ND and ED/PSO was

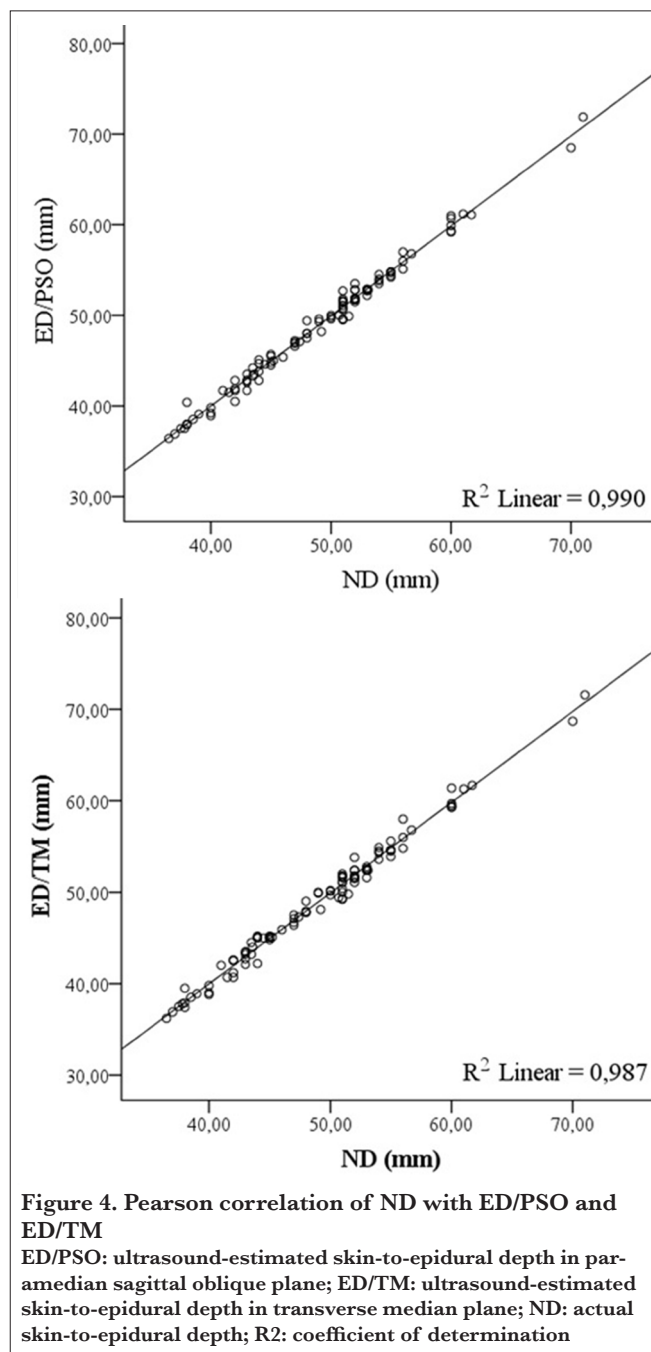
| | |
|---------------------------|-------------|
| ASA-PS I/II/III (n) | 49/40/11 |
| Gender (M/F) (n) | 66/34 |
| Age (y) | 49.33±14.56 |
| Weight (kg) | 77.37±12.25 |
| Height (cm) | 168.7±9.5 |
| BMI (kg m ⁻²) | 27.36±4.91 |
| ED/PSO (mm) | 48.92±6.91 |
| ED/TM (mm) | 48.90±6.91 |
| ND (mm) | 48.98±6.91 |

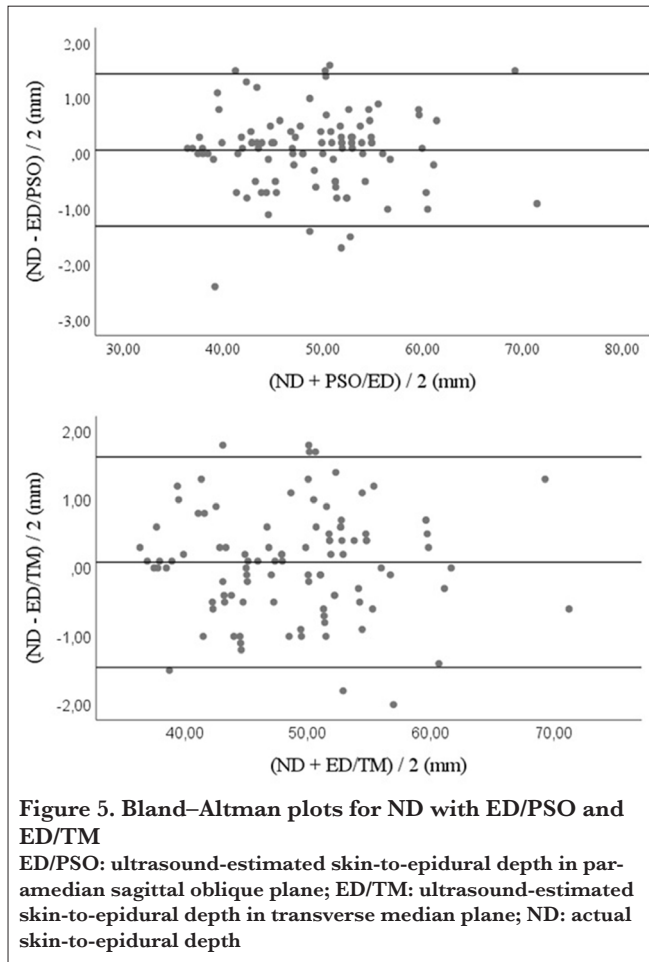
ASA-PS: American Society of Anaesthesiologists' physical status; M: male; F: female; BMI: body mass index; ED/PSO: ultrasound-estimated skin-to-epidural depth in paramedian sagittal oblique plane; ED/TM: ultrasound-estimated skin-to-epidural depth in transverse median plane; ND: actual skin-to-epidural depth. Values are expressed as the mean±standard deviation, except for ASA and gender.



0.995 (95% CI [confidence interval]: 0.992–0.997). The Pearson correlation coefficient between the ND and ED/TM was 0.994 ($r^2=0.988$, $p<0.001$). The concordance correlation coefficient between the ND and ED/TM was 0.993 (95%CI: 0.990–0.996). The Pearson correlation and Lin's concordance correlation plots are presented in Figures 3 and 4, respectively.

The mean difference of ND and ED/PSO was $0.07±0.70$ mm (95% limit of agreement: $-1.31-1.44$). The mean difference of ND and ED-TM was $0.08±0.79$ mm (95% limit of agreement: $-1.46-1.62$). The mean difference between the





ND and ED against the mean value of ND and ED were plotted on a Bland–Altman diagram (Figure 5) representing the upper and lower 95% limit of agreement between the ND and the ED measurements.

All patients underwent surgery under CSE. No patient needed conversion to general anaesthesia. The patients were followed up for probable early complications related to neuraxial anaesthesia until the postoperative 48th hour, and no complications were recorded.

Discussion

Our study results confirmed that the US estimates of ED measured in both PSO and TM have a strong correlation with ND at the L3–4 level in non-pregnant patients. Either ED/PSO or ED/TM can be used to facilitate the lumbar epidural insertion in patients undergoing unilateral inguinal hernia repair surgery under CSE.

The correlation of ND with ED/TM has been widely studied in the previous works (2, 6-17, 19, 27-29). Most of these studies were conducted on the pregnant patient population

(2, 6, 7, 9, 10, 13, 14, 16, 17, 19, 28), and there were a limited number of studies conducted on the non-pregnant patient population (9, 12, 15). In all these studies, the correlation between the ND and ED/TM presented a strong correlation. The precision and the accuracy between the ND and ED/TM in the present study were also in accordance with the results of the previous works.

The correlation of ND with the ED/PSO at the lumbar region in non-pregnant patient population has not been extensively studied. Grau et al. (22) have reported that paramedian plane provides an optimal window for US scanning of the lumbar vertebra in parturients and has presented a positive correlation between the actual epidural depth and the US estimated epidural depth in the paramedian sagittal plane. Khemka et al. (20) compared the ED in TM and PSO with the ND at the thoracic level in non-pregnant patient population and concluded that both planes provided comparable estimates for ND. In the present study, we assessed the correlation of ED/PSO with the ND in the non-obstetric patient population at the lumbar region. Our results presented almost an excellent precision and accuracy between the ND and ED/PSO at the lumbar region in the non-pregnant patient population.

Preprocedural US scanning in both TM and PSO provides reliable estimates of the ND. However, in obese patients and some of the elderly patients, age-related anatomical changes such as osteophytes render a limited acoustic window in TM. In these patients, the PSO view provides a larger acoustic window and a superior image quality (22, 30).

There were some limitations of the present study. Comparison of ED in PSO and TM were not analysed for different BMI groups, which could be the topic of another study. The second limitation of the study was that the US was done at the L3–4 intervertebral space to measure the ED/PSO and ED/TM in the present study. Further clinical trials assessing the ED at more than one lumbar segment are required to validate our results.

Conclusion

To conclude, both PSO and TM views at the lumbar region can be used interchangeably for preprocedural estimation of ND in the non-pregnant patient population. But we have to inform the clinicians that preprocedural knowledge of ED does not discard the use of the loss of resistance technique while performing epidurals.

Ethics Committee Approval: Ethics committee approval was received for this study from the ethics committee of Kırşehir Ahi Evran University (2017-20/243, 12/26/2017).

Informed Consent: Written informed consent was obtained from all patients who participated in this study.

Peer-review: Externally peer-reviewed.

Author Contributions: Concept – M.C.; Design – M.C., N.K., M.H.; Supervision – N.K., M.H.; Resources – M.C., N.K., M.H.; Materials – M.C., N.K., M.H.; Data Collection and/or Processing – M.C., N.K., M.H.; Analysis and/or Interpretation – M.C.; Literature Search – N.K., M.H.; Writing Manuscript – M.C.; Critical Review – N.K., M.H.

Conflict of Interest: The authors have no conflicts of interest to declare.

Financial Disclosure: The authors declared that this study has received no financial support.

References

- Marhofer P, Greher M, Kapral S. Ultrasound guidance in regional anaesthesia. *Br J Anaesth* 2005; 94: 7-17. [\[CrossRef\]](#)
- Grau T, Leipold RW, Conradi R, Martin E, Motsch J. Ultrasound imaging facilitates localization of the epidural space during combined spinal and epidural anesthesia. *Reg Anesth Pain Med* 2001; 26: 64-7. [\[CrossRef\]](#)
- Arzola C. Preprocedure ultrasonography before initiating a neuraxial anesthetic procedure. *Anesth Analg* 2017; 124: 712-3. [\[CrossRef\]](#)
- Tawfik MM, Atallah MM, Elkharroutly WS, Allakkany NS, Abdelkhalek M. Does preprocedural ultrasound increase the first-pass success rate of epidural catheterization before cesarean delivery? A randomized controlled trial. *Anesth Analg* 2017; 124: 851-6. [\[CrossRef\]](#)
- Halpern SH, Banerjee A, Stocche R, Glanc P. The use of ultrasound for lumbar spinous process identification: A pilot study. *Can J Anaesth* 2010; 57: 817-22. [\[CrossRef\]](#)
- Arzola C, Davies S, Rofaefel A, Carvalho JC. Ultrasound using the transverse approach to the lumbar spine provides reliable landmarks for labor epidurals. *Anesth Analg* 2007; 104: 1188-92. [\[CrossRef\]](#)
- Balki M, Lee Y, Halpern S, Carvalho JC. Ultrasound imaging of the lumbar spine in the transverse plane: the correlation between estimated and actual depth to the epidural space in obese parturients. *Anesth Analg* 2009; 108: 1876-81. [\[CrossRef\]](#)
- Chin KJ, Perlas A, Singh M, Arzola C, Prasad A, Chan V, et al. An ultrasound-assisted approach facilitates spinal anesthesia for total joint arthroplasty. *Can J Anaesth* 2009; 56: 643-50. [\[CrossRef\]](#)
- Cork RC, Kryc JJ, Vaughan RW. Ultrasonic localization of the lumbar epidural space. *Anesthesiology* 1980; 52: 513-6. [\[CrossRef\]](#)
- Currie JM. Measurement of the depth to the extradural space using ultrasound. *Br J Anaesth* 1984; 56: 345-7. [\[CrossRef\]](#)
- Ferre RM, Sweeney TW. Emergency physicians can easily obtain ultrasound images of anatomical landmarks relevant to lumbar puncture. *Am J Emerg Med* 2007; 25: 291-6. [\[CrossRef\]](#)
- Gnaho A, Nguyen V, Villevielle T, Frota M, Marret E, Gentili ME. Assessing the depth of the subarachnoid space by ultrasound. *Rev Bras Anesthesiol* 2012; 62: 520-30. [\[CrossRef\]](#)
- Grau T, Leipold RW, Conradi R, Martin E. Ultrasound control for presumed difficult epidural puncture. *Acta Anaesthesiol Scand* 2001; 45: 766-71. [\[CrossRef\]](#)
- Grau T, Leipold RW, Conradi R, Martin E, Motsch J. Efficacy of ultrasound imaging in obstetric epidural anesthesia. *J Clin Anesth* 2002; 14: 169-75. [\[CrossRef\]](#)
- Helayel PE, da Conceicao DB, Meurer G, Swarovsky C, de Oliveira Filho GR. Evaluating the depth of the epidural space with the use of ultrasound. *Rev Bras Anesthesiol* 2010; 60: 376-82. [\[CrossRef\]](#)
- Tran D, Kamani AA, Lessoway VA, Peterson C, Hor KW, Rohling RN. Preinsertion paramedian ultrasound guidance for epidural anesthesia. *Anesth Analg* 2009; 109: 661-7. [\[CrossRef\]](#)
- Vallejo MC, Phelps AL, Singh S, Orebaugh SL, Sah N. Ultrasound decreases the failed labor epidural rate in resident trainees. *Int J Obstet Anesth* 2010; 19: 373-8. [\[CrossRef\]](#)
- Chin KJ, Ramlogan R, Arzola C, Singh M, Chan V. The utility of ultrasound imaging in predicting ease of performance of spinal anesthesia in an orthopedic patient population. *Reg Anesth Pain Med* 2013; 38: 34-8. [\[CrossRef\]](#)
- Sahota JS, Carvalho JC, Balki M, Fanning N, Arzola C. Ultrasound estimates for midline epidural punctures in the obese parturient: paramedian sagittal oblique is comparable to transverse median plane. *Anesth Analg* 2013; 116: 829-35. [\[CrossRef\]](#)
- Khemka R, Rastogi S, Desai N, Chakraborty A, Sinha S. Comparison of ultrasound imaging in transverse median and parasagittal oblique planes for thoracic epidurals: A pilot study. *Indian J Anaesth* 2016; 60: 377-81. [\[CrossRef\]](#)
- Borges BC, Wieczorek P, Balki M, Carvalho JC. Sonoanatomy of the lumbar spine of pregnant women at term. *Reg Anesth Pain Med* 2009; 34: 581-5. [\[CrossRef\]](#)
- Grau T, Leipold RW, Horter J, Conradi R, Martin EO, Motsch J. Paramedian access to the epidural space: the optimum window for ultrasound imaging. *J Clin Anesth* 2001; 13: 213-7. [\[CrossRef\]](#)
- Crawford SB, Kosinski AS, Lin HM, Williamson JM, Barnhart HX. Computer programs for the concordance correlation coefficient. *Comput Methods Programs Biomed* 2007; 88: 62-74. [\[CrossRef\]](#)
- Lin L, Torbeck LD. Coefficient of accuracy and concordance correlation coefficient: new statistics for methods comparison. *PDA J Pharm Sci Technol* 1998; 52: 55-9.
- Bland JM, Altman DG. Statistical methods for assessing agreement between two methods of clinical measurement. *Lancet* 1986; 1: 307-10. [\[CrossRef\]](#)
- Bland JM, Altman DG. Measuring agreement in method comparison studies. *Stat Methods Med Res* 1999; 8: 135-60. [\[CrossRef\]](#)
- Perlas A, Chaparro LE, Chin KJ. Lumbar neuraxial ultrasound for spinal and epidural anesthesia: a systematic review and meta-analysis. *Reg Anesth Pain Med* 2016; 41: 251-60. [\[CrossRef\]](#)
- Sahin T, Balaban O, Sahin L, Solak M, Toker K. A randomized controlled trial of preinsertion ultrasound guidance for spinal anesthesia in pregnancy: outcomes among obese and lean parturients: ultrasound for spinal anesthesia in pregnancy. *J Anesth* 2014; 28: 413-9. [\[CrossRef\]](#)

29. Shaikh F, Brzezinski J, Alexander S, Arzola C, Carvalho JC, Beyene J, et al. Ultrasound imaging for lumbar punctures and epidural catheterisations: systematic review and meta-analysis. *BMJ* 2013; 346: f1720. [\[CrossRef\]](#)
30. Karmakar MK, Li X, Kwok WH, Ho AM, Ngan Kee WD. Sonoanatomy relevant for ultrasound-guided central neuraxial blocks via the paramedian approach in the lumbar region. *Br J Radiol* 2012; 85: e262-9. [\[CrossRef\]](#)