



ESC

European Society  
of Cardiology

# New interventional solutions in calcific coronary atherosclerosis: drill, laser, shock waves

Alessandra Laricchia<sup>1</sup> and Antonio Colombo<sup>1,2\*</sup>

<sup>1</sup>Interventional Cardiology Unit, GVM Care & Research Maria Cecilia Hospital, Cotignola, RA, Italy

<sup>2</sup>EMO-GVM, Centro Cuore Columbus, Milano, Italy

## KEYWORDS

Calcific lesions;  
Debulking;  
Optimal PCI;  
Intracoronary imaging

In the percutaneous treatment of coronary stenoses, it is essential to take into account the presence of calcifications as this influences the short- and long-term post-procedural outcomes. Today in the catheterization laboratory, there are several tools for the treatment of calcium; exploiting the different operating mechanisms, possibly even combining them together, is part of a modern approach to coronary angioplasty that aims to optimize results. To this end, each procedure must be properly planned and, in this perspective, intracoronary imaging (such as optical coherence tomography and intravascular ultrasound) is an essential aid to guide the procedure and show results.

## Introduction

The presence or absence of coronary calcifications can characterize atherosclerotic disease. However, angiography has a limited ability to detect the presence of calcium in the vessels. Conversely, computerized axial tomography (CT), optical coherence tomography (OCT), and intravascular ultrasound (IVUS) are more accurate visualization techniques.<sup>1-3</sup>

Whenever approaching coronary procedures, it is essential to take into account the presence of calcium and its amount. In fact, it increases the risk of dissections, makes the recanalization of total occlusions more complex and interferes with optimal stent expansion.<sup>4</sup> Moreover, it is known that in case of calcified lesions the risk of restenosis after an interventional procedure increases.<sup>5,6</sup> In addition, various studies have confirmed that the presence of coronary calcifications is an independent predictor of future adverse events.<sup>7,8</sup>

Thanks to the availability of new technologies and to their appropriate application, it is now possible to overcome many limitations given by the presence of calcifications. But above all, a correct procedural planning is the fundamental prerequisite that must guide modern coronary

intervention in order to implement the ideal solutions to overcome a problem before suffering its consequences.

The initial assessment with CT is undoubtedly useful and can provide additional data but does not replace intravascular imaging techniques, such as OCT and IVUS, which are essential during the interventional procedure.

## What intracoronary imaging needs to tell us

Proper intracoronary imaging should:

- identify the degree and extension of the calcifications and their localization (superficial vs. deep);
- distinguish calcium from fibrosis (they must be treated in different ways);
- provide the dimensions of the internal lumen of the vessel;
- identify the diameter of the vessel regardless of the reduction of the lumen caused by atherosclerotic disease; and
- evaluate the extent of atherosclerotic disease.

Having this information available, it is then possible to correctly plan the procedure.

However, in some cases of highly calcific lesions that impede the passage of the catheters imaging evaluation cannot be immediately carried out. It is therefore necessary to

\*Corresponding author. Email: ac84344@gmail.com

first dilate the lesion (by using dedicated systems to dig into the lesion, rotational atherectomy or Rotablator, Laser, high-pressure balloon) to allow the IVUS or OCT probe to cross it and provide us with the necessary information on how to proceed.

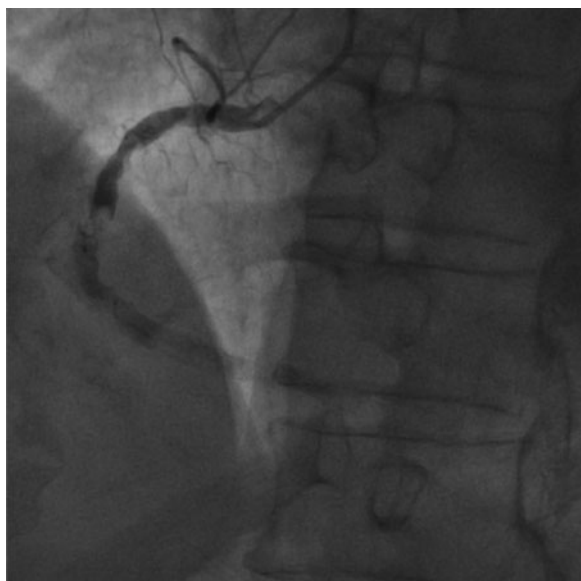### Treating a very calcified stenosis

The calcific occlusion of the right coronary artery shown in *Figure 1* will allow us to illustrate a modern approach to the treatment of calcific stenosis.

After advancing a coronary wire beyond the lesion with some difficulty, it was not possible to cross it with any balloon (including micro-balloons with a diameter of 0.80 mm). Therefore, a change in strategy was needed and it was decided to perform rotational atherectomy with Rotablator (Boston Scientific Scimed, Natick, MA, USA). However, the device is provided with a dedicated wire that is not suitable for crossing calcified lesions. Therefore, we used a micro-catheter to exchange the Rotawire with the previous one. In particular, we used a special micro-catheter with screwing system called Tornus (Asahi Intec.) to carry out this step. Once the Rotawire was positioned downstream of the stenosis, it was possible to proceed with this treatment.

### Rotational atherectomy or Rotablator

This system was introduced in vascular interventional more than 30 years ago and has remained almost unchanged.<sup>9</sup> The Rotablator consists of a catheter with a small olive of diameters from 1.25 to 2.5 mm (the maximum diameter that is used today in the coronary artery is 2 mm). This olive is covered with a patina of diamond granules and, turning at 180 000 rpm, exerts an ablation force on the calcium. Countless studies have been published on the additional utility of the Rotablator in the course of angioplasty.<sup>10,11</sup> However, today we can no longer think of the Rotablator as



**Figure 1** Sub-occlusive calcific stenosis in the middle tract of the right coronary artery.

a system with binary use (I use it or not use it); it is fundamental to understand that the Rotablator is only one of the tools available for the treatment of calcified lesions and, if in some cases its use is sufficient to obtain a satisfactory result, in other cases it constitutes only an initial adjuvant step to prepare the lesion for other interventions.

At this point, a modern approach to percutaneous coronary intervention takes advantage of imaging for subsequent choices. Therefore, going back to the procedure on the right coronary artery, after ablation with both 1.25 mm and 1.75 mm probes, we proceeded with IVUS to evaluate the result and decide about the next steps.

IVUS showed us that calcium had been successfully broken only in some sections, while in other areas the extension of the calcific ring still exceeded 180°. IVUS also revealed that vessel dimension exceeded 5 mm in diameter; as a consequence, even a 2 mm Rotablator probe would have been of little help to optimize the result and different decisions needed to be made.

The description of these aspects is not only a technical digression but also illustrate the high variability of the decision-making process and how it can be influenced by the information provided by intracoronary imaging. It is difficult to conceive a study where the treatment of calcified lesions takes into consideration only one technology such as rotational atherectomy. In fact, each tool has its own advantages and limitations and modern intervention must strive for optimal results using the combination of different methods. Simple dilatation with high-pressure balloons can be effective, but the results are not always guaranteed. For example, in some cases after positioning the stent across the lesion it dilates in a roughly asymmetrical way; in other cases using high pressures the segmental rupture of the vessel can occur and the implantation of a covered stent is necessary. Today, it is preferable to avoid these uncertainties and to evaluate the opportunity to use also new tools.

What we have seen at IVUS (*Figure 2*) therefore tells us that the calcium in the vessel needs further treatment. The most appropriate technique for this situation is the use of intravascular lithotripsy.

### Shockwave balloon

The Shockwave balloon (Shockwave Medical, Inc, Santa Clara, CA, USA) or intravascular lithotripsy is a balloon similar to coronary angioplasty balloons but equipped inside with crystals capable of emitting ultrasound at certain frequencies (*Figure 3*). The calcium rupture mechanism is not based on mechanical tissue damage (just inflate them at low pressures), but on a physical interaction due to the emission of pulsatile acoustic waves.<sup>12</sup> This technique is very similar to the lithotripsy used in urology and is in able to break calcium but not fibrosis (in these cases other systems are more effective). For coronary vessels balloons up to 4 mm in diameter are available, while larger ones are available for peripheral applications. Different studies have been done or are still in progress to evaluate the advantages of this method.<sup>13,14</sup>

In our case, we choose a 4 mm Shockwave balloon to be inflated where IVUS had reported the greatest extension of

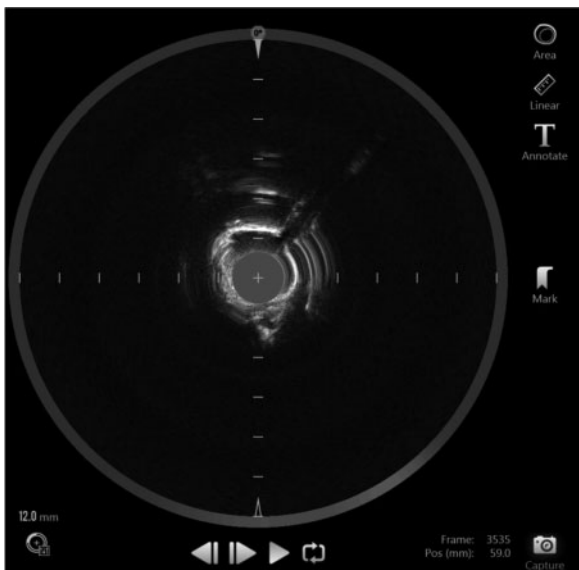


Figure 2 IVUS displays extensive surface calcifications.




Figure 3 Representation of a Shockwave balloon (Shockwave Medical, Inc, Santa Clara, CA, USA).

calcium. After treatment, a quick repeated IVUS evaluation finally confirmed the effective fracture of calcium.

At this point, we implanted the stent, post-dilated with a 6 mm non-compliant balloon. The final angiographic result was excellent (Figure 4) and also the final IVUS confirmed the good stent expansion with a very acceptable symmetry (Figure 5) in consideration of the extensive calcifications.

During this procedure, we therefore used various systems for the treatment of calcified lesions, and we experienced that a single tool is not always sufficient for the achievement of an optimal result. We also learned how fundamental is the information provided by intracoronary imaging to guide treatment and, in some cases (as in Figure 6, which shows the proximal tract of the right coronary artery), it is also useful to reassure us about lesions that, although being widely calcified, appear stable and with a suitable vessel lumen.

Among different imaging methods available, here we used IVUS. Even if OCT could provide more precise and immediate data, it is not the purpose of this article to digress into this subject.

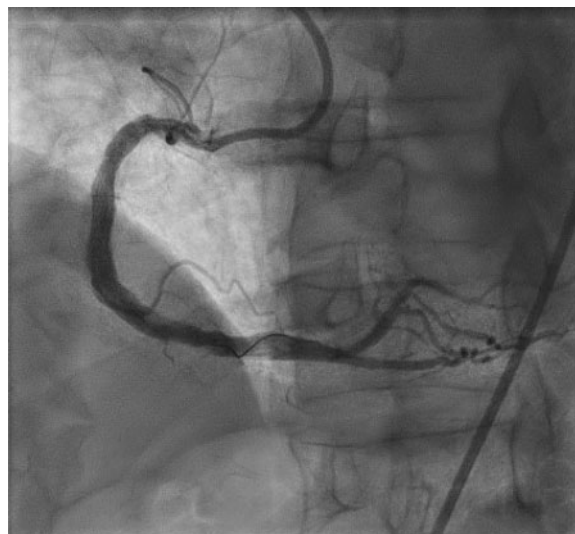

Figure 4 Final angiographic result after implantation and post-dilation of the stent on the right coronary artery.

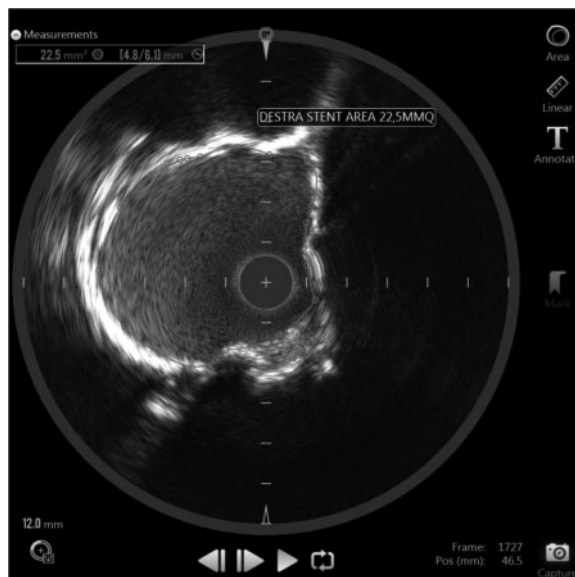
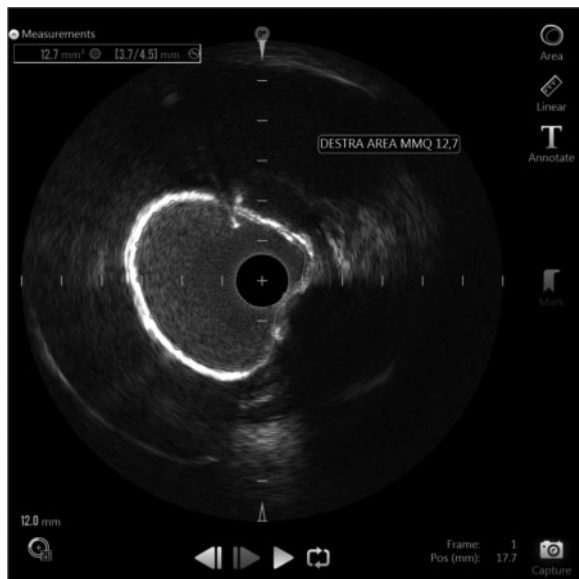


Figure 5 IVUS shows good stent expansion even in highly calcified areas.

Despite not used in the case described before, there are many other devices targeting calcified lesions, such as the laser, the cutting/scoring balloons and the very high-pressure balloons. These methods are also important and, in some cases, cannot be replaced by others.

### Laser

The most used laser system in vascular intervention is that of Excimer.<sup>15</sup> It is effective for fibrotic and moderately calcified plaques. Its ablation power is intensified by the simultaneous injection of contrast medium. Currently, the laser is mainly used in coronary intervention for the treatment of some intrastent restenosis and for stent under-expansion due to calcific plaque fibrosis.<sup>16,17</sup>



**Figure 6** IVUS shows that calcium should not always be treated; in this image the lumen is very large and the circumferential calcium represents a 'natural stent'.

## Cutting balloon, angioscupt, ultra high-pressure balloons

In some cases, lesion preparation requires the use of different systems. For example, the cutting balloons and the angioscupt are equipped with micro-blades on their surfaces with characteristic distribution and does not need high pressure of inflation; conversely, very high-pressure balloons reach up to 40 atm during inflation. However, examining the specific aspects that lead to decide between one and the other would force us to digress into an uninteresting technicality for the Clinical Cardiologist.

## Conclusions

Calcific stenoses can represent a problem only if not approached correctly. Many different devices can be employed at this purpose and the need to use one or multiple tools depends on baseline lesion assessment and the re-valuation of the results achieved. Angiography alone is not sufficient to guide the operator to the optimal result. Among the new available systems for interventional cardiologist, the Shockwave balloon represents an important and useful innovation.

We need prospective studies sufficiently articulated in procedural dynamics to demonstrate that, if properly treated, calcified stenoses no longer represent an element associated with reduced procedural and long-term success.

**Conflict of interest:** none declared.

## References

- Mintz GS, Popma JJ, Pichard AD, Kent KM, Satler LF, Chuang YC, Ditrono CJ, Leon MB. Patterns of calcification in coronary artery disease: a statistical analysis of intravascular ultrasound and coronary angiography in 1155 lesions. *Circulation* 1995;91:1959-1965.
- Agatston AS, Janowitz WR, Hildner FJ, Zusmer NR, Viamonte M, Detrano R. Quantification of coronary artery calcium using ultrafast computed tomography. *J Am Coll Cardiol* 1990;15:827-832.
- Kume T, Okura H, Kawamoto T, Yamada R, Miyamoto Y, Hayashida A, Watanabe N, Neishi Y, Sadahira Y, Akasaka T, Yoshida K. Assessment of the coronary calcification by optical coherence tomography. *EuroIntervention* 2011;6:768-772.
- Tan K, Sulke N, Taub N, Sowton E. Clinical and lesion morphologic determinants of coronary angioplasty success and complications: current experience. *J Am Coll Cardiol* 1995;25:855-865.
- Mattesini A, Di Mario C. Calcium: a predictor of interventional treatment failure across all fields of cardiovascular medicine. *Int J Cardiol* 2017;231:97-98.
- Onuma Y, Tanimoto S, Ruygrok P, Neuzner J, Piek JJ, Seth A, Schofer JJ, Richardt G, Wiemer M, Carrié D, Thuesen L, Dorange C, Miquel-Hebert K, Veldhof S, Serruys PW. Efficacy of everolimus eluting stent implantation in patients with calcified coronary culprit lesions: two-year angiographic and three-year clinical results from the SPIRIT II study. *Catheter Cardiovasc Interv* 2010;76:634-642.
- Kawaguchi R, Tsurugaya H, Hoshizaki H, Toyama T, Oshima S, Taniguchi K. Impact of lesion calcification on clinical and angiographic outcome after sirolimus-eluting stent implantation in real-world patients. *Cardiovasc Revascula Med* 2008;9:2-8.
- Madhavan MV, Tarigopula M, Mintz GS, Maehara A, Stone GW, Généreux P. Coronary artery calcification: pathogenesis and prognostic implications. *J Am Coll Cardiol* 2014;63:1703-1714.
- Ritchie JL, Hansen DD, Intlekofer MJ, Hall M, Auth DC. Rotational approaches to atherectomy and thrombectomy. *Z Kardiol* 1987;76(Suppl. 6):59-65.
- Abdel-Wahab M, Richardt G, Joachim Büttner H, Toelg R, Geist V, Meinertz T, Schofer J, King L, Neumann F-J, Khattab AA. High-speed rotational atherectomy before paclitaxel-eluting stent implantation in complex calcified coronary lesions: the randomized ROTAXUS (Rotational Atherectomy Prior to Taxus Stent Treatment for Complex Native Coronary Artery Disease) trial. *J Am CC Cardiovasc Interv* 2013;6:10-19.
- Abdel-Wahab M, Toelg R, Byrne RA, Geist V, El-Mawardy M, Allali A, Rheude T, Robinson DR, Abdelghani M, Sulimov DS, Kastrati A, Richardt G. High-speed rotational atherectomy versus modified balloons prior to drug-eluting stent implantation in severely calcified coronary lesions: the randomized prepare-CALC trial. *Circ Cardiovasc Interv* 2018;11:e007415.
- Brinton TJ, Ali ZA, Hill JM, Meredith IT, Maehara A, Illindala U, Lansky A, Göteborg M, Van Mieghem NM, Whitbourn R, Fajadet J, Di Mario C. Feasibility of Shockwave coronary intravascular lithotripsy for the treatment of calcified coronary stenoses. *Circulation* 2019;139:834-836.
- Ali ZA, Nef H, Escaned J, Werner N, Banning AP, Hill JM, De Bruyne B, Montorfano M, Lefevre T, Stone GW, Crowley A, Matsumura M, Maehara A, Lansky AJ, Fajadet J, Di Mario C. Safety and effectiveness of coronary intravascular lithotripsy for treatment of severely calcified coronary stenoses: the disrupt CAD II study. *Circ Cardiovasc Interv* 2019;12:e008434.
- Ali ZA, Brinton TJ, Hill JM, Maehara A, Matsumura M, Karimi Galougahi K, Illindala U, Göteborg M, Whitbourn R, Van Mieghem N, Meredith IT, Di Mario C, Fajadet J. Optical coherence tomography characterization of coronary lithoplasty for treatment of calcified lesions: first description. *JACC Cardiovasc Imaging* 2017;10:897-906.
- Rawlins J, Din JN, Talwar S, O'Kane P. Coronary intervention with the excimer laser: review of the technology and outcome data. *Interv Cardiol Rev* 2016;11:27-32.
- Latib A, Takagi K, Chizzola G, Tobis J, Ambrosini V, Niccoli G, Sardella G, DiSalvo ME, Armigliato P, Valgimigli M, Tarsia G, Gabrielli G, Lazar L, Maffeo D, Colombo A. Excimer Laser LESion modification to expand non-dilatable stents: the ELLEMENT registry. *Cardiovasc Revascula Med* 2014;15:8-12.
- Mehran R, Mintz GS, Satler LF, Pichard AD, Kent KM, Bucher TA, Popma JJ, Leon MB. Treatment of in-stent restenosis with excimer laser coronary angioplasty: mechanisms and results compared with PTCA alone. *Circulation* 1997;96:2183-2189.