

Novel Approach for Midface Depression

Koji Yamamoto, DDS*
Kuniaki Fukushima, DDS†

Background: Although Le Fort type II, prosthesis detainment, and orthodontic treatment are considered for the management of midface retraction, they may be limited by their high cost, infection risk, and excessive amount of tooth movement. Therefore, the Point A-Koji method was devised as a novel treatment in patients with midface retraction.

Methods: This is a case report of a 26-year-old woman who presented with a feeling of depressed midface and protrusion of the mouth. Preoperatively, the position of the lip and line connecting the nasal apex and mental muscles (E-line) were normal, but the subnasale was located posteriorly. The patient had a narrow nasolabial angle of 74 degrees and the subnasale-Pog' to the upper lip of 6.5 mm. After insertion of a metallic-plate implant under the periosteum, the plate was screwed and fixed to the bone. The Point A-Koji method was used for treatment in this patient. This is characterized by the A-point anterior migration technique in which the periosteum of hard tissue A-point circumferential attachment was shifted anteriorly, thereby preventing the return of soft tissue.

Results: The following changes with respect to preoperative findings were noted 5 months postsurgery: facial convexity from 3.3 degrees to 7.6 degrees; nasolabial angle from 74 degrees to 90.2 degrees; true horizontal line from 50 degrees to 73 degrees; and subnasale-Pog' to the upper lip from 6.5 mm to 4.7 mm. This resulted in an improved midface retraction.

Conclusion: The Point A-Koji method may be an ideal method to improve the midface retraction in patients. (*Plast Reconstr Surg Glob Open* 2022;10:e4242; doi: 10.1097/GOX.0000000000004242; Published online 11 April 2022.)

INTRODUCTION

Orthodontic treatment among adults has recently gained attention, as many patients seeking orthodontic treatment aim to have a highly aesthetic, ideal, and transverse face. They obtain this information through dental surgeons, counseling, and social networking services in the field of cosmetic surgery.¹ This has increased their desire for tooth alignment, improvement of mouth protrusion, and an "aesthetic smile."² In particular, nasal base column prosthesis insertion may be performed to improve the nasolabial angle in cosmetic surgery.³ However, these may cause problems, such as prosthesis misalignment, infection risk, difficulty in laughing due to foreign body sensation, and risk of prosthetic bone resorption.⁴ Several attempts to improve the E-line and nasolabial angle with

orthodontic treatment alone have resulted in excessive tooth movement, which leads to prolonged treatment and burden on teeth.⁵ Thus, the disadvantage after orthodontic treatment is that the patient may appear older due to decreased tooth exposure. A more aesthetic transverse facial profile with consideration for proper teeth position can be acquired by including the Le Fort type II operation in the treatment plan; however, orthodontic treatment with reconstructive surgery may be expensive and time-consuming for patients.⁶⁻⁸ This case report describes an efficient, effective, and novel technique for obtaining desired aesthetics in a patient with depression of the midface.

METHODS

A 26-year-old woman diagnosed with misaligned dentition was transferred to our clinic after the start of her treatment in another clinic (Fig. 1). She had good general nutritional status and no significant medical and family history. Lateral photographs showed strong depression of the midface, base of the nasal column, and base of the ala (Fig. 2). The nasolabial angle was 74 degrees, which was narrower than the mean value of 87.86 degrees for Asians⁹ and 109 degrees for Whites.¹⁰ The subnasale (Sn)-Pog'

From the *Cozy Yamamoto Dental Clinic, Aichi Prefecture, Japan; and †Sasashima Cozy Dental Clinic, Aichi Prefecture, Japan.

Received for publication December 19, 2021; accepted February 8, 2022.

Copyright © 2022 The Authors. Published by Wolters Kluwer Health, Inc. on behalf of The American Society of Plastic Surgeons. This is an open-access article distributed under the terms of the Creative Commons Attribution-Non Commercial-No Derivatives License 4.0 (CCBY-NC-ND), where it is permissible to download and share the work provided it is properly cited. The work cannot be changed in any way or used commercially without permission from the journal.

DOI: 10.1097/GOX.0000000000004242

Disclosure: The authors have no financial interest to declare in relation to the content of this article.

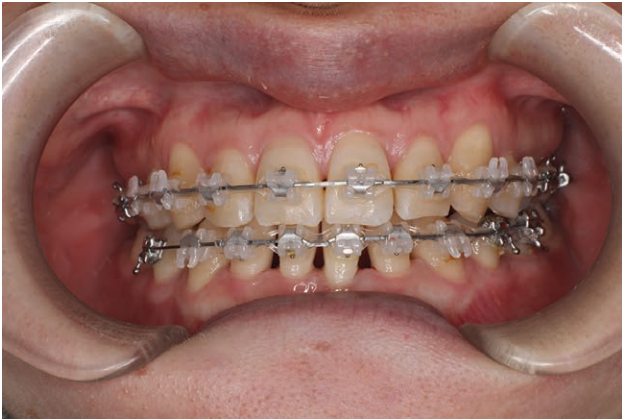

Fig. 1. Preoperative assessment: intraoral photograph.

to the upper lip of Legan-Burstone soft tissue analysis was 6.5mm, similar to the Japanese standard value of 6.5mm.¹¹ However, it was higher than the White standard value of 3.0mm¹¹ and suggested a diagnosis of protrusion of the mouth (Fig. 2, Table 1). Tweed's analysis showed that the SNA, SNAB, and ANB angles were 86.7degrees, 85.4degrees, and 1.3degrees, respectively, indicating a tendency toward mandibular protraction (Fig. 3). There was a tendency for skeletal class III with mesofacial recessive growth, and the teeth presented with Angle class I. Hence, the Point A-Koji method was devised to treat midface retraction. The point A-Koji method is a novel surgical method that shifts the soft tissue Sn point forward while preventing the backward movement of the soft tissue. It improves the facies by using an implant metal plate to support the periosteum around the hard tissue point A, which is the deepest point on the maxillary external linear line between the anterior nasal spine and the intermaxillary central incisor alveolar process crest.

Preoperatively, computed tomography imaging (Ray Japan α -Edge power, Tokyo, Japan) was performed. Thereafter, the jaw bone model was made using a three-dimensional printer (Form2; Formlabs Inc., Kyoto, Japan), and the implant mini plate (Stryker, Mich.), which served as a frame, was bent to match the bone surface form. The plate used for the surgery was made of titanium, and the thickness was 2mm for durability. Considering the restrictions regarding both the location of screwing and the strength of fixing, a plate with two holes was used. Surgical simulation and simple bending of the implant metal plates were performed using a jaw bone model. Patient consent was obtained for the off-label use of metal plates.

On the day of surgery, the patient had a good general condition and no nasal symptoms. Surgery was performed under local anesthesia using six doses of Aura Injection Dental Cartridge (Showa Pharmaceutical Co., Ltd., Aichi, Japan), with 1.8mL per dose. After incision and gingival mucosal dissection from the left and right side of the gum-buccal junction of the maxilla using blade no. 15, bone condition was confirmed to be good (Fig. 4A). Morphological modifications of the implant metal plates and modified bending were performed. It was confirmed that the nasolabial angle

Takeaways

Question: Although Le Fort type II, prosthesis detachment, and orthodontic treatment are considered for the management of midface retraction, they may be limited by their high cost, infection risk, and excessive amount of tooth movement. Is there a new technique that can solve these problems?

Findings: The Point A-Koji method was devised as a novel treatment for patients with midface retraction.

Meaning: The Point A-Koji method, characterized by the A-point forward transfer technique, is an ideal way to improve the midface retraction of patients.

was sufficiently increased by viewing the forward movement of the soft tissue Sn point from the outside of the mouth. Thereafter, the implant metal plate was bent again to match the bone surface. After metal plate bending, the bone was cut with a drill bur, two screws with a diameter of 2.0 mm and a length of 5.0 mm were embedded, and the implant metal plate was fixed to the bone surface (Fig. 4B). The position of the screw was set between the lower edge of the piriform aperture and the anterior teeth of the maxilla, which is the safest and secures the depth of the bone. Computed tomography was performed immediately after implantation, which confirmed that there was no penetration into the nasal cavity and no contact between the screw and the root of the implant (Fig. 4C, D). Suturing was performed using 6-0 Vicryl periosteal sutures and 5-0 silk gingival sutures (Fig. 4E). Antibiotics and analgesics were prescribed, and suture removal was done after 2 weeks. The clinical course was uneventful, with no infection of the wound. The requirements of the Helsinki Declaration were observed. The patient provided informed consent for all surgical procedures.

RESULTS

The comparison of pre- and postsurgery facial photographs showed an increase in the nasolabial angle and anterior migration of the soft tissue Sn point (Table 1). Moreover, symptoms of discomfort, such as pulling of the nose after prosthesis insertion, were not identified. The swelling at the operative site also receded in approximately 2 weeks. There were no abnormal findings on skull, panoramic, and lateral facial x-ray (Figs. 5, 6) 5 months after surgery.

Changes in lateral facial features and positional changes in the nasal apex (ie, pronasal) before surgery and 5 months after surgery are shown in Table 1. The following changes were observed on soft tissue analyses of the lateral facies: facial convexity from 3.3 degrees to 7.6 degrees; nasolabial angle from 74 degrees to 90.2 degrees; true horizontal line from 50 degrees to 73 degrees; and Sn-Pog' to upper lip from 6.5mm to 4.7mm. Serial movements indicated that surgery improved the aesthetics of the lateral view of the face. When the positional changes of the nasal apex (ie, pronasale) were examined on cephalometric

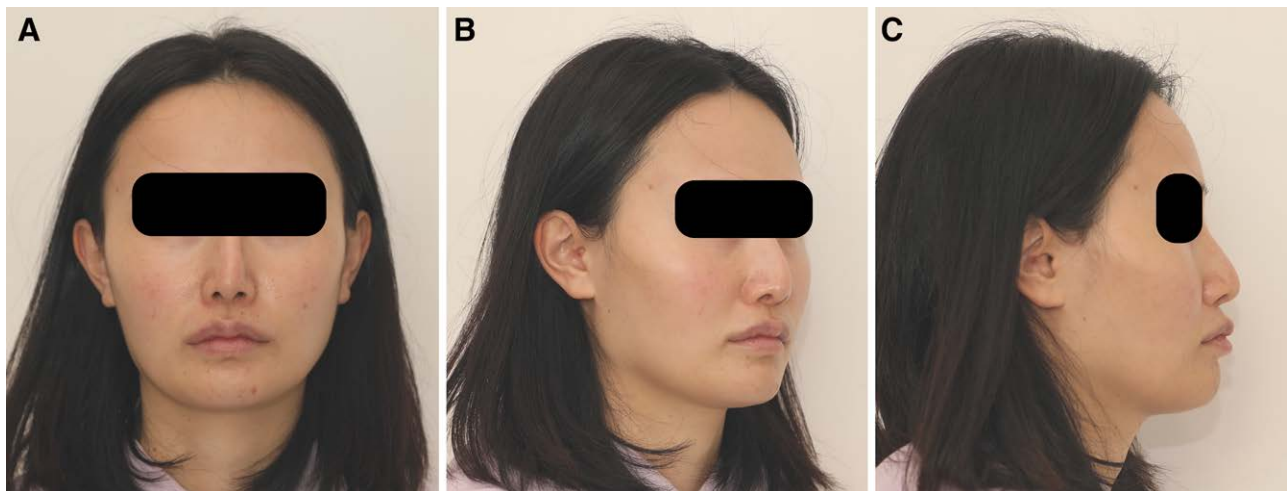

Fig. 2. Preoperative assessment: photographs of facial features. A, Frontal view. B, Three-quarter view. C, Lateral view.

Table 1. Changes in Major Items and their Means before and after Surgery

Analysis Items	Standard Values		Before Surgery	Five Months after Surgery
	Mean (Asian)	Mean (White)		
Facial convexity (glabella-Sn-Pog') (degrees)	7.6	14.79	3.3	7.6
Nasolabial angle (degrees)	87.86	109	74	90.2
THL (degrees)			50	73
Sn-Pog' to upper lip (mm)	6.5	3	6.5	4.7
Hard point A-soft Sn (mm)			10.5	14.5
Hard point A-nasal apex (pronasale) (mm)			25.8	29.1
N-Pog' line-nasal apex (pronasale) (mm)			24.8	26.1

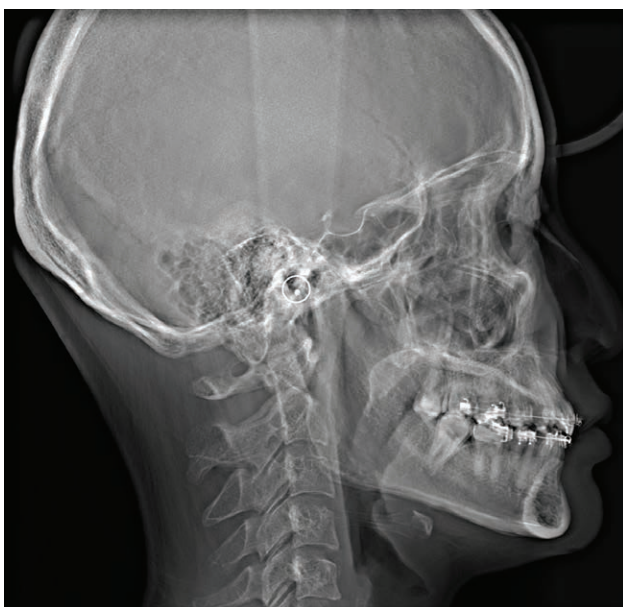

Fig. 3. Preoperative assessment: lateral cephalometric radiograph.

radiographs, hard point A to soft tissue Sn changed from 10.5 mm to 14.5 mm, hard point A to nasal apex (ie, pronasale) from 25.8 mm to 29.1 mm, and hard N-Pog' line to nasal apex (ie, pronasale) from 24.8 mm to 26.1 mm. Therefore, the nasal apex shifted anteriorly.

DISCUSSION

This case depicted a clear preoperative line-to-mouth positional relationship between the lip and E-line; however, there was a feeling of midface retraction and protrusion of the mouth, owing to the posterior location of the soft tissue Sn. Therefore, to achieve better aesthetic outcomes for the patient, repositioning the soft tissue Sn anteriorly using the Point A-Koji technique was attempted, as presented in our report, resulting in changes in the lateral view of the face.

Facial convexity is a key indicator of the stereoscopic appearance of the face. Japanese people often find stereoscopic faces more aesthetically pleasing, with a mean angle of 7.6 degrees for Asian people and 14.79 degrees for White people.^{9,10,12} The facial convexity angle was 3.3 degrees before the operation and 7.6 degrees after the operation. In this study, a better stereoacuity of the patient's face could be achieved. Another key indicator of an aesthetically acceptable lateral view of the face is the nasolabial angle, which is ideally 109 degrees and 105 degrees for White women and men, respectively.¹² The nasolabial angle of the female patient before the operation was 74 degrees and 90.2 degrees after the operation, suggesting that the ideal nasolabial angle was obtained by surgery. For midface retraction, the anterior positioning of the soft tissue Sn-point may improve the nasolabial angle while reducing the amount of tooth movement during orthodontic treatment. The angle of the upper white lip that forms the nasolabial angle between 79 degrees and 85 degrees is considered ideal for the true horizontal line when the patient is standing, wherein the soft tissue Sn-point is used as the origin.¹³ In the present case, the preoperative true horizontal line

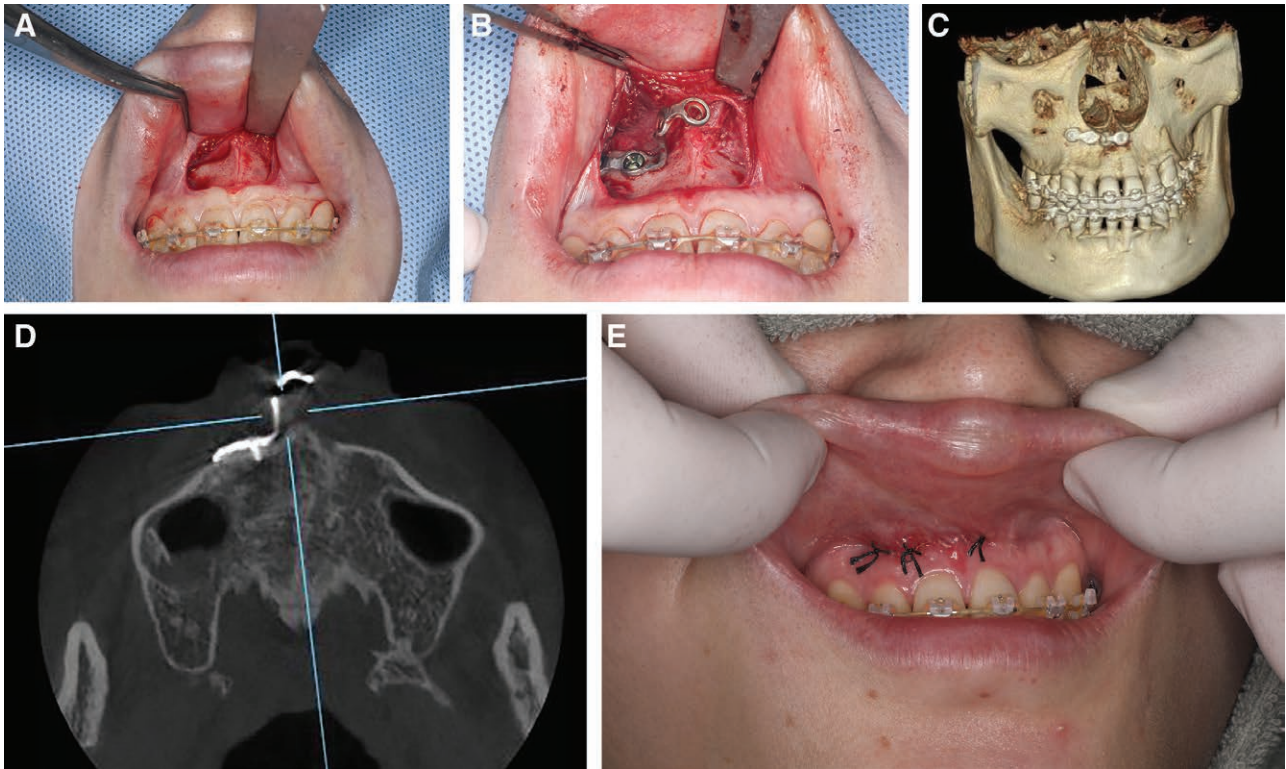


Fig. 4. Intraoperative photographs. A, Confirmed photograph of the bone surface after gingival detachment. B, Photograph showing plate fixation in the bone. C, Confirmatory computed tomography image of the location of the fixation screw and the root. D, Three-dimensional computed tomography image of the location of the fixation screw and the root. E, At the time of wound closure.

was 50 degrees, and it reached 73 degrees after surgery, which was a significant improvement despite the inability to reach the ideal value. The Sn-Pog' to the upper lip of Legan-Burstone soft tissue analyses is the key indicator of the sensation of protrusion of the oral cavity. For Japanese people, the tendency of protrusion is common. The Sn-Pog' to the upper lip is 6.5 mm in Japanese women and 6.3 mm in men, while for White people, the mean value is at 3.0 mm.¹¹ The patient's preoperative measurement was at 6.5 mm, and changed to 4.7 mm after the operation, suggesting that the feeling of mouth protrusion was relieved. It can be inferred that the changes in the above parameters were due to the forward shift of the Sn point using the Point A-Koji method.

Several methods (such as Le Fort II osteotomy of the jaw bone, prosthesis insertion around the piriform orifice, fat grafting, and hyaluronic acid injection treatment) were considered as approaches for improving the appearance of patients with midface retraction. However, satisfactory outcomes were not achieved, and several post-operative problems were reported with regard to these methods.^{7,14-17} In the case of fat grafting, the injected material tends to leak to the surroundings as the surgical site moves. Therefore, there is a problem in the stability of the long-term effect of surgery.¹⁸ Le Fort II osteotomy is used in patients with maxillary deformity presenting with mesofacial recessive growth. It improves the jaw-bite relationship and the sensation of depression around the

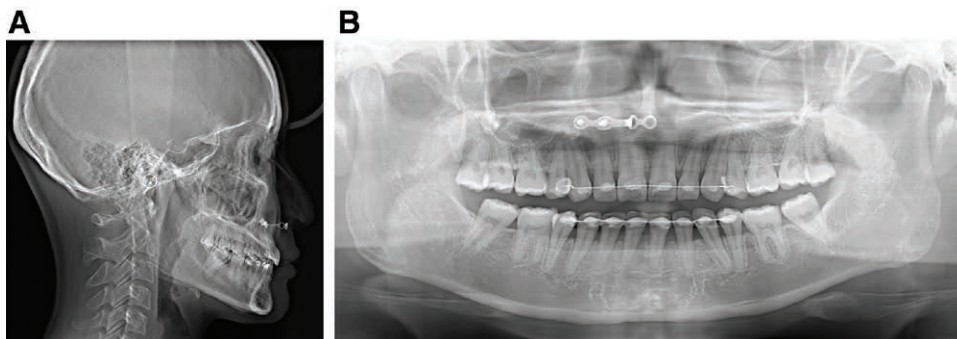


Fig. 5. Aesthetic outcomes 5 months after surgery. A, Lateral cephalometric radiograph. B, Panoramic radiograph.

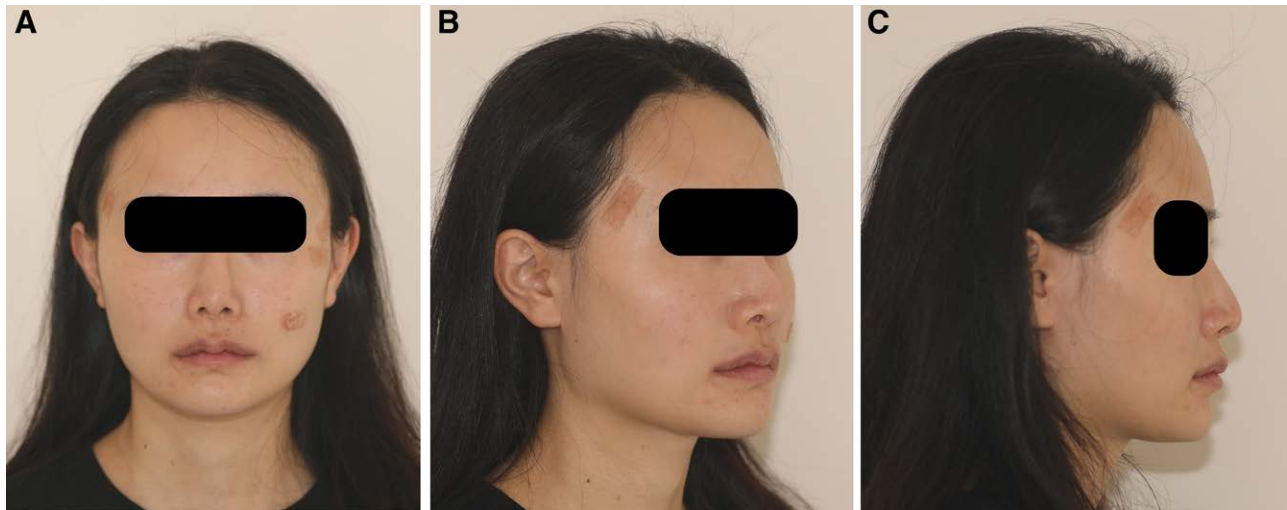

Fig. 6. Aesthetic outcomes 5 months after surgery: photographs of facial features. A, Frontal view. B, Three-quarter view. C, Lateral view.

nose; however, the procedure is limited by its invasive nature.^{6,8} Therefore, a new method involving the complete mouth combined with an endoscope was introduced. This method removes the possibility of leaving postoperative scars on the face; however, the invasiveness of the procedure remains a challenge.¹⁹ Silicone implantation has been associated with several postoperative bone resorptions and is not recommended due to the dental damage from bone resorption.⁴ The point A-Koji method appears to be superior than the conventional Le Fort type II and prosthesis insertion method, since it is relatively more affordable, less invasive, and has a lower risk of bone resorption. The plates and screws used in the surgery were made of titanium. Dental implants are a typical example of titanium used in biotherapy. Bone resorption does not occur unless it is under special circumstances such as bacterial infection.²⁰ In addition, when the titanium plate for fracture treatment or orthodontic treatment is removed at a later date, it was observed that bones were formed on the titanium plate.²¹ Since the plate used for surgery has a small contact area with the bone surface, it seems that blood flow was not impaired and therefore, bone resorption was unlikely to occur. Although the treatment was performed to reduce midface retraction, it was confirmed that the nasal apex was simultaneously shifted forward upon comparison of the cephalometric radiographs. The periosteum of the hard tissue A point moved forward. The N-Pog' line was noted to change 2.5mm anteriorly before and after surgery. This made E-line look more appealing.

In the future, studies with a larger number of cases, long-term postoperative follow-up, and postoperative stability are needed. Although this new method greatly considers the aesthetic improvement in the appearance of younger individuals, it may also benefit middle- and older-aged people in the improvement of the appearance of their oral cavity. However, further modifications and future studies should be conducted to explore the potential of this novel method.

CONCLUSIONS

The Point A-Koji method is a novel operative method performed in a patient who desires improvements in the aesthetics due to the depression of the midface and nose base. In this case, the soft tissue Sn was positioned anteriorly through the Point A-Koji method, and the lateral appearance of the face showed improvement.

Koji Yamamoto, DDS

Cozy Yamamoto Dental Clinic
108, Shinoda Yahara, Ama city
Aichi Prefecture, 490-1211
Japan

E-mail: article@a10.email

PATIENT CONSENT

The patient provided written consent for the use of her image.

REFERENCES

- Smorthit K, Cooper J. Social media influence. *BDJ Pract.* 2020;33:5.
- Tin-Oo MM, Saddki N, Hassan N. Factors influencing patient satisfaction with dental appearance and treatments they desire to improve aesthetics. *BMC Oral Health.* 2011;11:6.
- Jain S, Maru K, Shukla J, et al. Nasal prosthesis rehabilitation: a case report. *J Indian Prosthodont Soc.* 2011;11:265–269.
- Sugai T, Yoshizawa M, Ono Y, et al. A case of bone resorption following augmentation genioplasty with a silicone implant. *Japanese J Jaw Deform.* 2006;16:205–209.
- Watanabe F, Tsukada Kouichi OF. A clinical study on apical root resorption of maxillary incisors occurring during orthodontic treatment. *J Hokkaido Orthod Soc.* 1992;20:1–6.
- Reyneke JP, Widegrow AD. Nasomaxillary osteotomy for the correction of Binder's syndrome (nasomaxillary dysplasia). *Int J Adult Orthodon Orthognath Surg.* 1996;11:117–126.
- Bhat P, Cariappa K. Lefort-2 osteotomy for the treatment of nasomaxillary hypoplasia: A case report. *J Maxillofac Oral Surg.* 2009;8:390–393.
- Kawakami K, Kawakami E, Kanno T, et al. LeFort A case report of skeletal mandibular protrusion treated with intraoral LeFort II midfacial advancement. *Shikoku Dent Res.* 2009;22: 123–128.

9. Choi JY, Park JH, Javidnia H, et al. Effect of various facial angles and measurements on the ideal position of the nasal tip in the Asian patient population. *JAMA Facial Plast Surg.* 2013;15:417–421.
10. Al Taki A, Yaqoub S, Hassan M. Legan-burstone soft tissue profile values in a Circassian adult sample. *J Orthod Sci.* 2018;7:18.
11. Ioi H, Nakata S, Nakasima A, et al. Comparison of cephalometric norms between Japanese and Caucasian adults in antero-posterior and vertical dimension. *Eur J Orthod.* 2007;29:493–499.
12. Anić-Milosević S, Lapter-Varga M, Slaj M. Analysis of the soft tissue facial profile by means of angular measurements. *Eur J Orthod.* 2008;30:135–140.
13. Naini FB, Cobourne MT, McDonald F, et al. The aesthetic impact of upper lip inclination in orthodontics and orthognathic surgery. *Eur J Orthod.* 2015;37:81–86.
14. De Maio M, DeBouille K, Braz A, et al. Facial assessment and injection guide for botulinum toxin and injectable hyaluronic acid fillers: focus on the midface. *Plast Reconstr Surg.* 2017;140:540E–550E.
15. Clauser L, Zavan B, Galiè M, et al. Autologous fat transfer for facial augmentation: surgery and regeneration. *J Craniofac Surg.* 2019;30:682–685.
16. Matarasso A, Nikfarjam J, Abramowitz L. Incorporating minimally invasive procedures into an aesthetic surgery practice. *Clin Plast Surg.* 2016;43:449–457.
17. Quinzi V, Paskay LC, D'andrea N, et al. Evaluation of the nasolabial angle in orthodontic diagnosis: a systematic review. *Appl Sci.* 2021;11:1–18.
18. Molina-Burbano F, Smith JM, Ingargiola MJ, et al. Fat grafting to improve results of facelift: systematic review of safety and effectiveness of current treatment paradigms. *Aesthet Surg J.* 2021;41:1–12.
19. Hara S, Mitsugi M, Kanno T, et al. Endoscopically assisted intraoral modified Le Fort II type midfacial advancement using piezoelectric surgery and an intraoperative RED system. *J Oral Maxillofac Surg.* 2013;71:e93–e103.
20. Esposito M, Hirsch J, Lekholm U, et al. Differential diagnosis and treatment strategies for biologic complications and failing oral implants: a review of the literature. *Int J Oral Maxillofac Implants.* 1999;14:473–490.
21. Agnihotry A, Fedorowicz Z, Nasser M, et al. Resorbable versus titanium plates for orthognathic surgery. *Cochrane Database Syst Rev.* 2017;10:CD006204.