

## Short-term outcome of botulinum neurotoxin A injection with or without sodium hyaluronate in the treatment of infantile esotropia—a prospective interventional study

Nitika Pandey, Siddharth Agrawal, Rajat M Srivastava, Vinita Singh

**Purpose:** To compare the short-term outcome of botulinum neurotoxin A (BoNT-A) with or without sodium hyaluronate in the treatment of infantile esotropia (IE). **Methods:** In this tertiary care hospital-based prospective, interventional, non-randomized study on infants with IE below one year of age, 25 cases were enrolled in the sodium hyaluronate (SH) group to receive 2.5 U BoNT-A injection combined with SH in each medial rectus muscle (MR). Thirty patients were enrolled in the control group to receive 2.5 U BoNT-A injection with normal saline in each MR. The change in mean primary ocular deviation (POD) and complications were assessed at 2 weeks, 1 month, 3 months, and 6 months post injection. Mann–Whitney U test was used for non-parametric unpaired data. Chi-square test and Fisher's exact test were used to test for the strength of the association between the two categorical variables. **Results:** Satisfactory ocular alignment was achieved in 76% in SH group and 73% in the control group ( $P$  value = 0.80). While the change in mean POD was comparable (29.2 prism diopters [PD] vs 29.3 PD;  $P$  value = 0.65), the complication rates were significantly lesser in SH (16% vs 33.3%;  $P$  value = 0.14). **Conclusion:** BoNT-A combined with SH is equally effective with lesser complications as compared to botulinum toxin alone in the treatment of IE.

**Key words:** Botulinum toxin, infantile esotropia, sodium hyaluronate

Botulinum neurotoxin A (BoNT-A) has been recognized and accepted as both an adjunct and an alternative to strabismus surgery in infantile esotropia (IE).<sup>[1-3]</sup> However, there are two major complications of the treatment which may be dose-dependent: ptosis and induced vertical deviation.<sup>[4-7]</sup> Possibly due to the infiltration of toxin into the neighboring tissues, one can encounter flaccid paralysis in the surrounding muscles, which causes these complications in some cases. The correct placement of BoNT-A injection is needed to attain the best results and avoid such complications. It is thus generally injected using electromyographic (EMG) guidance, which is believed to help to locate the target muscle. However, the complication rate with EMG-guided injection has also been found to be high.<sup>[8]</sup> Thus, there is clearly a need for a revised technique of BoNT-A injection, which may reduce the risk of complications. One such novel technique has been used in our study of combining sodium hyaluronate (SH) with BoNT-A injection in patients with IE, which by its physical property decreases the diffusion of the toxin to the neighboring tissues thereby decreasing the complication rate.<sup>[9]</sup> This technique was first described in a Chinese study in 2013.<sup>[9]</sup> Ours is the first study to be conducted on the Indian population.

### Methods

This study was approved by the local clinical research ethical committee. Informed consent from the parents of the subjects

Department of Ophthalmology, King George's Medical University, Lucknow, Uttar Pradesh, India

**Correspondence to:** Dr. Siddharth Agrawal, King George's Medical University, Chowk, Lucknow - 226 003, Uttar Pradesh, India. E-mail: agrawalsiddharth@rediffmail.com

Received: 24-Aug-2019

Revision: 27-Dec-2019

Accepted: 22-Feb-2020

Published: 24-Jul-2020

was taken in each case after explaining the risks and benefits of the treatment. The procedures conformed to the tenets of the Declaration of Helsinki.

It was a tertiary care hospital-based prospective, interventional non-randomized study. The study period extended from September 1, 2017 to September 30, 2019.

The inclusion criteria were patients with IE  $\leq$ 1-year old in whom botulinum toxin can be used as an alternative for surgery. Table 1 shows the various indications of BoNT A in IE.<sup>[1,3,4,10,11]</sup> Patients with a history of previous surgery or botulinum toxin injection were excluded. Thus, indications in our study were (a), (b), and (c) of Table 1.

After explaining to the parents about the two methods of intervention, they were allowed to choose the group. Those opting for injection with SH formed the 'SH group' and those opting for conventional procedure formed the 'control group'. Patients in the SH group were treated with 0.15 ml injection of 2.5U BoNT-A combined with SH to each medial rectus muscle (MR). Patients in control were treated with 0.15 ml injection of 2.5 U BoNT-A combined with 0.9% normal saline to each MR. Preinjection examination included the estimation of primary ocular deviation (POD) (by Hirschberg or Krimsky

This is an open access journal, and articles are distributed under the terms of the Creative Commons Attribution-NonCommercial-ShareAlike 4.0 License, which allows others to remix, tweak, and build upon the work non-commercially, as long as appropriate credit is given and the new creations are licensed under the identical terms.

**For reprints contact:** WKHLRPMedknow\_reprints@wolterskluwer.com

**Cite this article as:** Pandey N, Agrawal S, Srivastava RM, Singh V. Short-term outcome of botulinum neurotoxin A injection with or without sodium hyaluronate in the treatment of infantile esotropia—a prospective interventional study. Indian J Ophthalmol 2020;68:1600-3.

Access this article online

Website:

www.ijo.in

DOI:

10.4103/ijo.IJO\_1552\_19

Quick Response Code:



test), assessment of ocular movements, anterior and posterior segment findings. The angle of deviation in each patient was assessed by a strabismologist masked to the patient's treatment group. In children with variable measurements, the largest recorded deviation was considered.

### Method of injecting the toxin

All injections were given by the same strabismus specialist who was blinded to the injection content and the patient's treatment group. The injections were given under short-acting general anesthesia with intubation (Sevoflurane without any muscle relaxant). The surgical field was prepared and injection was given transconjunctivally using 27-gauge needle into each MR by grasping the muscle with Graefe fixation forceps. Muscle belly was lifted up to avoid sclera puncture. The muscle was injected through conjunctiva at the bulge created at the site of the lift 15–20 mm from insertion.

Post injection mean change in POD, ocular movements, and complications were recorded at 2 weeks, 1 month, 3 months and 6 months. Percent change in deviation (preoperative deviation - postoperative deviation)/preoperative deviation  $\times$  100 at 6 months was recorded. The satisfactory ocular alignment was defined as deviation < 10 PD in primary position. Ptosis was graded on a scale of 0-3. P0- no ptosis, P1- mild ptosis with a reduction in palpebral fissure height of 2 mm, P2-moderate ptosis with a reduction of 2–3mm and P3-severe ptosis with reduction of >3 mm. Vertical deviation was recorded on a scale of 0-2. V1  $\leq$  10PD, V2 11-20 PD and V3  $\geq$  20 PD.<sup>[7,9]</sup> Other complications like subconjunctival hemorrhage were also recorded.

### Statistical analysis

Statistical Package for the Social Sciences (SPSS) software was used for statistical analysis. Mann-Whitney U-test was used for non-parametric unpaired data. Chi-square test and Fisher's exact test were used to test for the strength of the association between the two categorical variables. A *P* value < 0.05 was considered to be statistically significant.

## Results

The baseline clinical characteristics of the two groups were comparable as shown in Table 2. The study was done on 55 patients (25 in SH and 30 in controls). The mean age of presentation was 0.92  $\pm$  0.10 year in SH group and 0.91  $\pm$  0.15 year in the controls (*P*-value 0.70).

Comparing the mean POD (mean  $\pm$  SD; *P* value) during follow-up in both the groups (SH vs control), respectively were as follows: pre-injection deviation (33.8  $\pm$  5.2 vs 34.6  $\pm$  8.6; *P* value 0.6), after 2 weeks (10.2  $\pm$  6.9 vs 11.1  $\pm$  8.6; *P* value = 0.6), after 1 month (8.0  $\pm$  6.4 vs 8.4  $\pm$  6.6; *P* value 0.8), after 3 months (7.2  $\pm$  6.0 vs 7.8  $\pm$  5.8; *P* value = 0.7), and at the end of 6 months (4.6  $\pm$  6.4 vs 5.3  $\pm$  6.2; *P* value = 0.6). The mean change in POD in SH group was 29.6  $\pm$  7.6 PD and in controls was 28.8  $\pm$  5.8 PD (*P* value = 0.65). There was no statistically significant difference between the percent change in mean POD at the end of 6 months in the two groups (86.3% vs 84.6%; *P* value = 0.86).

Comparing the rate of complications, the SH group had a lesser rate of complications as compared to the control group 16% (*n* = 4) vs 33.3% (*n* = 10) and the difference was

**Table 1: Indications of BoNT A (Botulinum Toxin A) in Infantile Esotropia (IE)**

- Small-angle (<35 PD of deviation)<sup>[8,10]</sup>
- Angle variability, especially in infants with developmental delays or cerebral palsy<sup>[11]</sup>
- Parents unwilling for surgery
- Small-angle residual esotropia or consecutive exotropia<sup>[1,3,4]</sup>

**Table 2: Comparison of baseline characteristics of the two groups: SH vs control group**

Variable	SH <sup>†</sup> ( <i>n</i> =25)	Control <sup>‡</sup> ( <i>n</i> =30)	<i>P</i>
Age (in years)	0.92 $\pm$ 0.10	0.91 $\pm$ 0.15	0.70
Males (%)	56.0	50.0	0.66
Preinjection mean POD* in Prism diopters (PD)	33.8 $\pm$ 5.2	34.6 $\pm$ 8.6	0.68

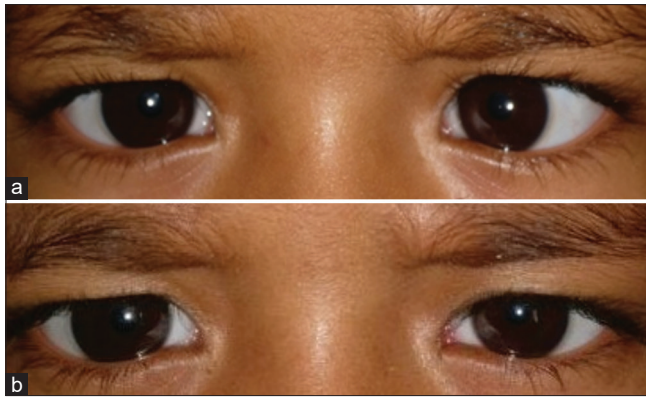
\*POD, Primary ocular deviation; <sup>†</sup>SH, botulinum toxin A with sodium hyaluronate group; <sup>‡</sup>Controls, botulinum toxin A group

statistically significant (*P*-value = 0.1). Three (12%) out of 25 patients in the SH group developed ptosis as compared to eight out of 30 (26.6%) patients in the controls. Of the eight patients who developed ptosis in the controls, five had mild ptosis (P1), two developed moderate ptosis (P2), and one had severe ptosis (P3) while three patients who developed ptosis in the SH group had ptosis of mild grade (P1). One (4%) patient in the SH group developed hypertropia of 10 PD (V1 grade) while two (6.6%) patients in controls developed hypertropia in one of the eyes. Out of them, one developed hypertropia of 12 PD (V1 grade) and one developed hypertropia of 20 PD (V2 grade). Amongst other complications, one patient in the control group had a subconjunctival hemorrhage. All complications were transient and had resolved by 3-month visit in both the groups.

At 6 months, there was no statistical difference between the groups. Satisfactory ocular alignment was obtained in 76% patients (*n* = 19) in SH group and 73% patients (*n* = 22) in the controls (*P*-value 0.80). After 6 months, out of the 14 patients with unsuccessful outcome, six underwent surgery, five received reinjection, and three did not return for subsequent follow up [Figs. 1 and 2].

## Discussion

BoNT-A is a useful tool in the management of IE. During the temporary span of its effect, it may help in strengthening binocularity, which may enable permanent motor alignment. Changes in neuromuscular junction have also been reported to facilitate long term stability of deviation.<sup>[1-3]</sup> It is reported that surgery may be altogether avoided in 45% to 75% patients after an average of about two injections.<sup>[10,12,13]</sup> Overcorrections rarely occur for more than a few weeks as the induced paralysis is reversible. The latter has an advantage in infants where measurements are often inaccurate.<sup>[1-3]</sup> However, despite the aforementioned therapeutic benefit, the use of BoNT-A injection frequently causes ptosis and vertical deviation.<sup>[4]</sup> These complications, although transient, are a cause of anxiety for the parents. They make the assessment of improvement difficult and may adversely affect the outcome by contributing to amblyopia.<sup>[4]</sup> Our study thus aims to revise the technique



**Figure 1:** Botulinum toxin A injection with Sodium Hyaluronate (SH) (a) Pre-injection deviation (b) Successful ocular alignment at 6 months

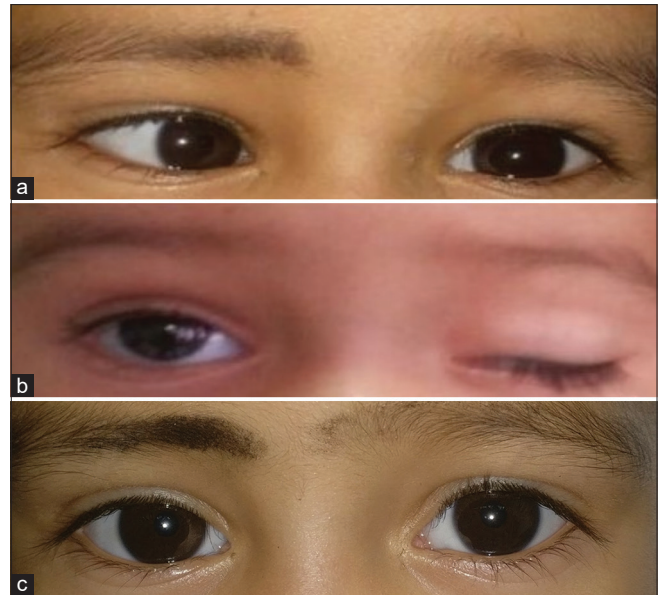of BoNT-A injection by combining it with SH, which has been shown previously as a safe and effective technique associated with a decreased rate of complications.<sup>[9]</sup>

In our study, the mean change in POD in SH group was  $29.6 \pm 7.6$  PD and  $28.8 \pm 5.8$  PD in controls similar to that obtained by Dayane C Issaho *et al.* in their meta-analysis of the use of botulinum toxin to treat IE where the mean change of the deviation after BoNT injection was 30.7 PD.<sup>[14]</sup> This observation reconfirms the utility of BoNT-A in deviations up to 35 PD.<sup>[15]</sup>

There are two major complications of botulinum toxin A treatment associated with flaccid paralysis of the other extraocular muscles: ptosis and induced vertical deviation, possibly due to infiltration of toxin into the neighboring tissues.<sup>[3,4]</sup> In our study, the rate of complication in the SH group was significantly lesser than in the controls (16% vs 33.3%; *P* value 0.1). The decreased rate of complications may be attributed to SH, which when combined with botulinum toxin decreases its rate of diffusion into the surrounding tissues.<sup>[9]</sup> SH being a cohesive viscoelastic when mixed with BoNT-A increases its viscosity and thus the bioavailability in the muscle being injected. It consequently decreases the chances of infiltration to the neighboring muscles. Hyaluronic acid is a naturally occurring polysaccharide. Besides the physicochemical properties which underlie its application as a viscoelastic tool in ophthalmological surgery, it has been demonstrated to have some *in vitro* anti-inflammatory activity.<sup>[15,16]</sup> It is bioabsorbable and its use in the extraocular muscles is therefore unlikely to have any side effects.

The study by Chen *et al.* being the only similar published work has been compared in Table 3. Besides having a different age group and ethnic population, we've used a simpler technique for the preparation of the injection. We used toxin to SH ratio of 1:2 against 1:3 used earlier. Chen *et al.* modified the dosage of the toxin according to the deviation, we, however, used the same amount of toxin in all patients as there is no clarity about titrating the dosage. Moreover, it is believed that the younger age of the patient and a smaller deviation are more related to the success of the injection rather than the dosage.<sup>[15]</sup> By keeping the dose constant we have eliminated the possibility of dose-dependent variation in complications.

The occurrence of ptosis in our study was 12% ( $n = 3$ ) in SH group and 26.6% ( $n = 8$ ) in controls against 2.2% ( $n = 1$ )



**Figure 2:** Botulinum toxin A injection alone (Control): (a) pre-injection deviation, (b) Severe ptosis 2 weeks post-botulinum toxin A injection, (c) Successful ocular alignment after 6 months

and 20.8% ( $n = 10$ ) respectively reported in the other study.<sup>[9]</sup> Ptosis encountered with the use of BoNT-A is found to be 1-53% in various studies and is usually mild.<sup>[4-6,7]</sup> While in SH group, one (4%) patient developed hypertropia, the controls (6%) patients with hypertropia. Vertical deviation reported by Chen *et al.* in similar groups was 2.1% ( $n = 1$ ) and 2.2% ( $n = 1$ ), respectively. Scott reported induced ptosis and/or vertical deviation in 15-20% of horizontal extraocular muscle injections.<sup>[17]</sup> The varying rates of vertical deviation may be attributed to the difficulty of diagnosing and measuring such deviations in infants. Hypertropia is commoner because the inferior rectus is closer to medial rectus compared to superior rectus (5.9 mm against 7.5 mm) and also probably because the needle is directed posteriorly and inferiorly while being injected.<sup>[12,18]</sup> The finding that none of the patients developed both vertical deviation and ptosis could indicate that the spread of the toxin inferiorly affects the inferior rectus, however, the superior spread affects the levator palpebrae superioris.

Nineteen (76%) patients in SH and 22 (73%) patients in control group had a satisfactory motor alignment at 6 months. Previous studies have also reported a similar or higher success rate with a single injection.<sup>[19]</sup> However, our study was not designed to comment on the long-term stability of alignment after a single injection of BoNT-A.

The small sample size of this study is because surgery still remains the gold standard for treatment of IE and BoNT-A is given only in specific conditions. Non-randomized nature of the study is also a limitation.

## Conclusion

The results of our study are convincing enough to advocate the use of SH in all patients undergoing BoNT-A injection for IE till studies with a larger sample size are conducted.



**Table 3: Comparing our study with the previous published study by J Chen *et al.*<sup>[9]</sup>**

Variables	Previous study by J Chen <i>et al.</i>	Our study
Study population	Chinese	Indian
Mean age of presentation	38.0±17.5 in SH* group, 35.8±20.7 in the controls (in months)	0.92±0.10 in SH group, 0.91±0.15 in the controls <sup>†</sup> (in years)
Sample size	47; 23 in SH group, 24 in controls	55; 25 in SH group 30 in controls
Methodology		
a) Reconstitution technique	100U toxin reconstituted to yield 0.05ml of toxin + SH in SH group and 0.03ml of toxin in controls	50U toxin reconstituted to yield 0.15ml of toxin + SH in SH group and 0.15ml of toxin controls.
b) BoNT A: SH	1:3	1:2
c) Dosage	2.5U for <30PD, 3.75U for >30PD	2.5U in all patients.
d) Mean Pre injection deviation	35.0±15.7 in SH group and 33.9±16.7 in controls	33.8±5.2 in SH group and 34.6±8.6 in controls
e) total injected volume	0.05ml in SH group, 0.03ml in controls.	0.15ml in both the groups
Results		
a) Successful motor alignment post injection (SH vs control group)	30.4% vs 37.5%.	76% vs 73%
b) Complication rate (SH vs control group)	Ptosis-2.2% vs 20.8% vertical deviation 2.1% vs 2.2%	Ptosis 12% vs 26.6% Vertical deviation 4 vs 6.6%

\*SH, Botulinum toxin A with sodium hyaluronate group; <sup>†</sup>Controls, Botulinum toxin A group alone

### Financial support and sponsorship

Nil.

### Conflicts of interest

There are no conflicts of interest.

### References

- Rowe FJ, Noonan CP. Botulinum toxin for the treatment of strabismus. *Cochrane Database Syst Rev* 2012;CD006499. doi: 10.1002/14651858.CD006499.pub3.
- Tejedor J, Rodríguez JM. Long-term outcome and predictor variables in the treatment of acquired esotropia with botulinum toxin. *Invest Ophthalmol Vis Sci* 2001;42:2542-6.
- Ripley L, Rowe FJ. Use of botulinum toxin in small-angle heterotropia and decompensating heterophoria: A review of the literature. *Strabismus* 2007;15:165-71.
- Şener EC, Sanaç AŞ. Efficacy and complications of dose increments of botulinum toxin-A in the treatment of horizontal comitant strabismus. *Eye* 2000;14:873.
- Horgan SE, Lee JP, Bunce C. The long-term use of botulinum toxin for adult strabismus. *J Pediatr Ophthalmol Strabismus* 1998;35:9-16.
- Osako M, Keltner JL. Botulinum a toxin (Oculinum®) in ophthalmology. *Surv Ophthalmol* 1991;36:28-46.
- Burns CL, Gammon JA, Gemmill MC. Ptosis associated with botulinum toxin treatment of strabismus and blepharospasm. *Ophthalmology* 1986;93:1621-7.
- Sanjari MS, Falavarjani KG, Kashkouli MB, Aghai GH, Nojomi M, Rostami H. Botulinum toxin injection with and without electromyographic assistance for treatment of abducens nerve palsy: A pilot study. *J Am Assoc Pediatr Ophthalmol Strabismus* 2008;12:259-62.
- Chen J, Deng D, Zhong H, Lin X, Kang Y, Wu H, Yan J, Mai G. Botulinum toxin injections combined with or without sodium hyaluronate in the absence of electromyography for the treatment of infantile esotropia: A pilot study. *Eye* 2013;27:382-6.
- de Alba Campomanes AG, Binenbaum G, Eguiarte GC. Comparison of botulinum toxin with surgery as primary treatment for infantile esotropia. *J AAPOS* 2010;14:111-6.
- Ameri A, Mirmohammadsadeghi A, Makateb A, Bazvand F, Hosseini S. Clinical outcomes of botulinum toxin injection in patients with cerebral palsy and esotropia. *Strabismus* 2015;23:8-13.
- Speeg-Schatz C, Burgun P, Gottenkiene S. To what extent may Botulinum toxin type A injections be an alternative choice to surgery in infantile esotropia? *Eur J Ophthalmol* 2017;27:285-8.
- Tejedor J, Rodríguez JM. Early retreatment of infantile esotropia: Comparison of reoperation and botulinum toxin. *Br J Ophthalmol* 1999;83:783-7.
- Issaho DC, de Souza Carvalho FR, Tabuse MK, Carrijo-Carvalho LC, de Freitas D. The use of botulinum toxin to treat infantile esotropia: A systematic review with meta-analysis. *Invest Ophthalmol Vis Sci* 2017;58:5468-76.
- Higashide T, Sugiyama K. Use of viscoelastic substance in ophthalmic surgery—focus on sodium hyaluronate. *Clin Ophthalmol* 2008;2:21.
- Benfield P, Goa KL. Hyaluronic acid: A review of its pharmacology and use as a surgical aid in ophthalmology and its therapeutic potential in joint disease and wound healing. *Drugs* 1994;47:536-66.
- Scott AB. Botulinum toxin injection of eye muscles to correct strabismus. *Trans Am Ophthalmol Soc* 1981;79:734.
- Apt L. An anatomical reevaluation of rectus muscle insertions. *Trans Am Ophthalmol Soc* 1980;78:365.
- McNeer KW, Tucker MG, Spencer RF. Botulinum toxin management of essential infantile esotropia in children. *Arch Ophthalmol* 1997;115:1411-8.