

Moulded Osteomyofascial Pedicled Split (MOPS) Craniotomy Flap in Reconstruction of Anterior Cranial Fossa Defects: Pilot Study of a Novel Technique

Abstract

Introduction: Anterior cranial fossa (ACF) defects still remains a reconstructive challenge to neurosurgeons due to the difficult location, inaccessibility, and unfavorable vascular anatomy. Usual reconstructive methods reported complications such as recurrent cerebrospinal fluid leak due to bone resorption and tissue breakdown. This is mainly due to the avascularity of the bone graft and inability to provide bony structural support for the skull base. An ideal reconstructive modality should provide a rigid bony support to prevent brain herniation as well as ensure a water tight barrier between sinonasal tract and intracranial compartment. **Methodology:** Hence, we thought of a novel technique of taking the outer table of the primary craniotomy flap with its intact myofascial pedicle and moulded it with multiple osteotomies (moulded osteomyofascial pedicled split (MOPS) craniotomy flap) to fit into uneven ACF defects. Advantages of our flap include (1) It is a pedicled vascularized bone flap. (2) It is taken from primary craniotomy flap; hence, no separate craniotomy is required. (3) The inner table is intact and leaves no secondary calvarial bone defect on the donor site. (4) Osteoplastic flap is moulded to fit into the defect, thus providing good contour. **Results:** MOPS flap was used in five patients with ACF defects due to varied etiologies such as encephalocele defect, frontal mucocele, skull base meningioma, and complex naso ethmoid fracture. Age of the patients included in the study varied from 21 to 60 years. Male:female ratio was 4:1. ACF defects were reconstructed using MOPS flap in all cases. There were no postoperative complications and 1-month postoperative computerized tomography scan showed no evidence of bone resorption with acceptable cosmesis. **Conclusion:** MOPS craniotomy flap provides a novel, easily mastered, and cost-effective technique with minimal complication in reconstruction of complex ACF defects with acceptable esthetic and functional outcome.

Keywords: Anterior cranial fossa, moulded, pedicled flap, reconstruction

Introduction

Anterior cranial fossa (ACF) defects still remain as a reconstructive challenge to neurosurgeons despite advances in surgical expertise and availability of various synthetic graft materials.^[1] This is due to the difficult anatomy, poor accessibility, and the unfavorable surrounding vascular anatomy.^[2] Reconstructive goals of ACF defects are (1) to ensure a watertight barrier between sinonasal tract and intracranial compartment and (2) to prevent herniation of brain through the defect by providing bony integrity and a strong durable structural support. Currently available options for reconstruction of such defects include free tensor fascia lata, pericranium, autologous free bone graft, etc. Tensor

fascia lata and pericranium have high rate of cerebrospinal fluid (CSF) leak due to lack of bony framework to provide a durable closure. Autologous-free bone grafts lead to bone resorption and thus breakthrough CSF leak.^[3] Uses of free fat and free muscle were also reported in literature; however, they have dismal long-term success rate. Temporalis-based vascularized split calvarial flap taken from the remote site requiring additional incisions and exposure were reported in literature; however, they have the disadvantage of leaving additional bony defect and scars at the harvest site.^[4] They are also placed as a rigid bone into the defect and hence lack adequate contouring in complex ACF defects.

Hence, we thought of a novel technique of moulded osteomyofascial pedicled

Vinu Venu Gopal,
Lekshmi S.
Bhooshan¹,
Alfred Michael,
Philip Issac,
Shaju Mathew,
Tinu Ravi Abraham,
P. K. Balakrishnan

Departments of Neurosurgery
and ¹Plastic Surgery,
Government Medical College,
Kottayam, Kerala, India

Address for correspondence:

Dr. Vinu Venu Gopal,
Associate Professor,
Department of Neurosurgery,
Government Medical College,
Kottayam, Kerala, India.
E-mail: vinoogopa@gmail.com

Access this article online

Website: www.asianjns.org

DOI: 10.4103/ajns.AJNS_23_17

Quick Response Code:



How to cite this article: Gopal VV, Bhooshan LS, Michael A, Issac P, Mathew S, Abraham TR, *et al.* Moulded osteomyofascial pedicled split (MOPS) craniotomy flap in reconstruction of anterior cranial fossa defects: Pilot study of a novel technique. Asian J Neurosurg 2018;13:1011-7.

This is an open access journal, and articles are distributed under the terms of the Creative Commons Attribution-NonCommercial-ShareAlike 4.0 License, which allows others to remix, tweak, and build upon the work non-commercially, as long as appropriate credit is given and the new creations are licensed under the identical terms.

For reprints contact: reprints@medknow.com

split craniotomy flap (MOPS) which have the following advantages: (1) It is a pedicled vascularized bone flap. (2) It is taken from primary craniotomy flap; hence, no separate craniotomy or incision is required for harvest. (3) The inner table is intact and hence there is no secondary calvarial bone defect on the donor site. (4) Osteoplastic flap is moulded by multiple osteotomies to fit into the defect and thus provide good contour and good cosmesis. (5) This procedure leaves no cutaneous scars elsewhere in the body other than primary operative site. (6) It is cost-effective. (7) It can be used in infective cases. (8) Can be used in patients requiring postoperative radiation.

Methodology

In our study, we retrospectively evaluated the use of this technique in reconstruction of five cases of ACF defects of varying etiologies. The cases selected were as follows: (1) encephalocele defect with CSF leak, (2) two cases of frontal mucocele eroding orbital roof, (3) medial sphenoid wing meningioma infiltrating skull base, and (4) posttraumatic complex nasoethmoid orbital roof fracture with CSF leak. All the cases were done in a single tertiary institution during the period from July 2016 to December 2016 by the primary investigator himself. Institutional review board approval was obtained for the study as well as for publication. Informed written consent was taken from all the patients after explaining the risk and benefits of the procedure. Written informed consent was also obtained regarding data publication in journal without revealing their identity.

Demonstration of surgical technique

All cases were done under general anesthesia after obtaining informed written consent. The patient was positioned supine with neck extended and head end

elevation [Figure 1a]. Classical bicoronal skin incision was put in all cases and subgaleal flap was raised up to supraorbital ridge. Craniotomy flap was marked. Depending on the size and side of ACF defect, the outer table of the ipsilateral primary craniotomy flap with its intact temporalis-based myofascial pedicle was planned [Figure 1b]. Two burr holes were placed in the line of craniotomy and using a craniotome the bone in between the burr holes were cut [Figure 1c]. Using drill with small drill bit, multiple holes were made in diploic space without breaking the inner table [Figure 1d]. The bone flap was then split through the diploic space using an osteotome, and outer table was detached without breaking the inner table [Figure 2a and b] with the intact temporalis-based myofascial pedicle [Figure 2b-d]. The myofascial pedicle was further elevated preserving the deep temporal arteries supplying the muscles [Figure 2b-d]. The split outer table was osteotomized into many pieces with special care to avoid injury to the pericranium [Figures 2c and 3a]. These osteotomies will help in moulding the bone flap to fit snugly into the ACF [Figure 3b]. The flap was then placed safely to the side, and the craniotomy for accessing the skull base defect was completed. The flap is taken to the ACF defect through the anterior frontal most burr hole without twist and kink [Figure 3c and d]. The composite flap was then placed in the ACF defect, and tissue glue is used to attach it strongly to skull base [Figure 3b]. The primary craniotomy flap with intact inner table is replaced so that there is no residual bony defect in the area of harvest [Figure 3d]. The donor area resurfaced with bone dust obtained during craniotomy burr hole, to achieve better cosmesis [Figure 3d] and skin flap sutured back. Schematic representation of the procedure is shown in [Figure 4a-e].

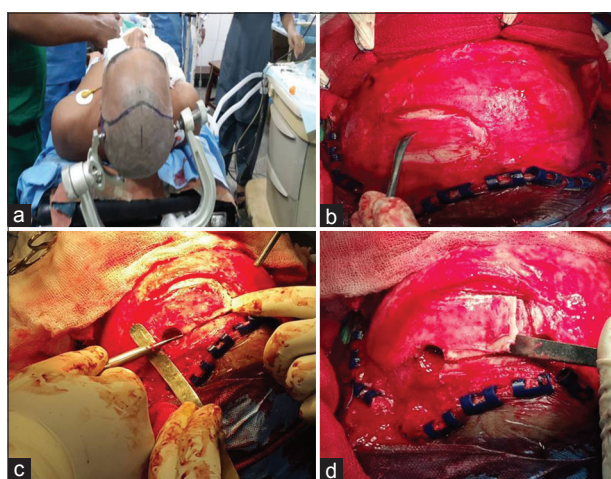


Figure 1: (a) Patient positioning. (b) Fashioning the adequate-sized moulded osteomyofascial pedicled split craniotomy flap with intact pericranium and myofascial pedicle. (c) Multiples holes are made in diploic space using drill without breaking inner table. (d) Flap was raised using osteotome

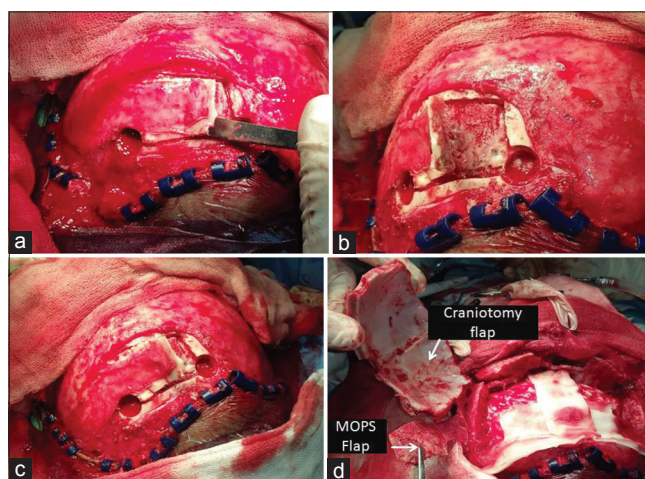


Figure 2: (a-c) Outer table is osteotomised and pedicle of moulded osteomyofascial pedicled split craniotomy flap lengthened to obtain sufficient arc of rotation. (d) Moulded osteomyofascial pedicled split craniotomy flap and craniotomy flap with pedicle shown separately

Representative cases

Case 1

A 26-year-old male presented with frontonasal encephalocele with CSF leak through the left nostril. Computerized tomography (CT) scan showed a large defect in cribriform plate and ethmoids [Figure 5a-c]. Ligation and repair of encephalocele [Figure 5d] was done, and ACF defect reconstructed using MOPS flap. There was no postoperative complication and 1-month postoperative CT showed new bone formation without any evidence of bone resorption

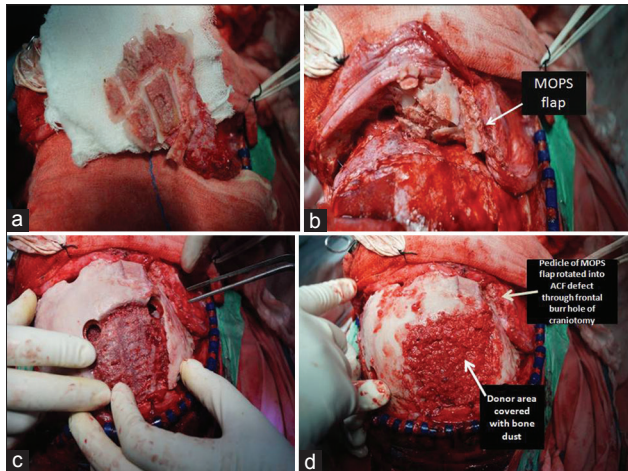


Figure 3: (a) "Split osteotomised" outer table bone flap with intact pericranium and wide myofascial pedicle. (b) moulded osteomyofascial pedicled split craniotomy flap rotated and placed to cover anterior cranial fossa defect. (c) Craniotomy flap replaced showing donor area. (d) Secondary defect resurfaced with bone dust obtained during craniotomy burr hole for better cosmesis. The pedicle of moulded osteomyofascial pedicled split craniotomy flap is rotated into anterior cranial fossa through key burr hole

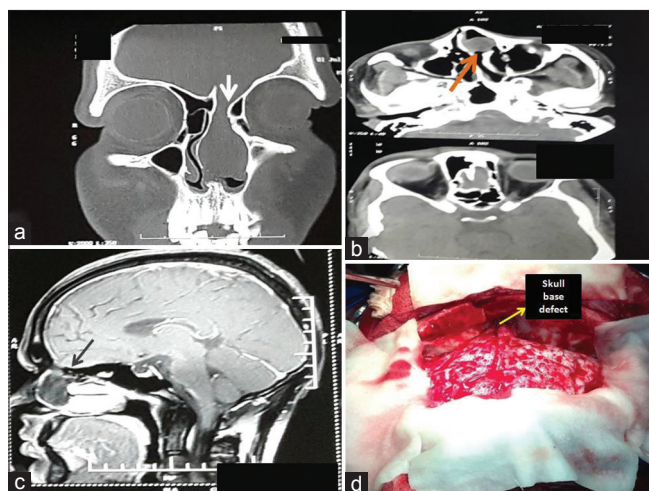


Figure 5: (a) Preoperative coronal computerized tomography showing defect in anterior cranial fossa with encephalocele. (b) Preoperative axial computerized tomography showing ethmoid defect with encephalocele (orange arrow). (c) Preoperative sagittal magnetic resonance imaging showing defect in orbital roof (thick black arrow indicates the defect). (d) Bifrontal craniotomy showing the anterior cranial fossa defect with traversing encephalocele sac

[Figure 6a1, a2, b1, b2, c1, c2]. Postoperative photograph showed good cosmesis [Figure 7a and b].

Case 2

A 24-year-old male presented with frontal mucocele. CT showed destruction of roof of orbit and destruction of inner table of frontal sinus and posterior ethmoids [Figure 8a and b]. Orbital roof reconstruction along

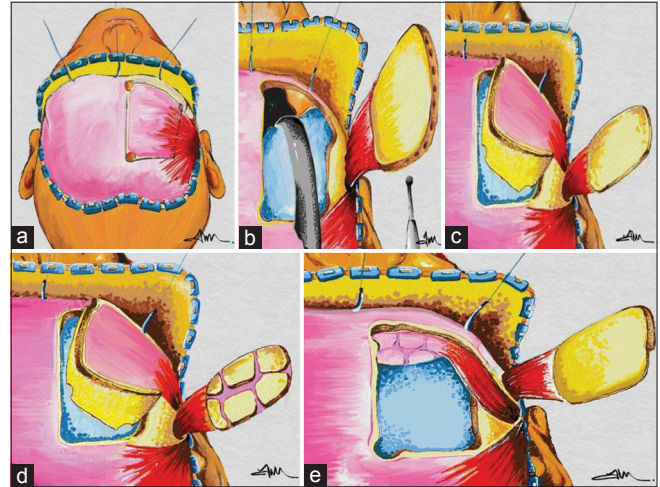

Figure 4: (a-e) Schematic representation of moulded osteomyofascial pedicled split craniotomy flap

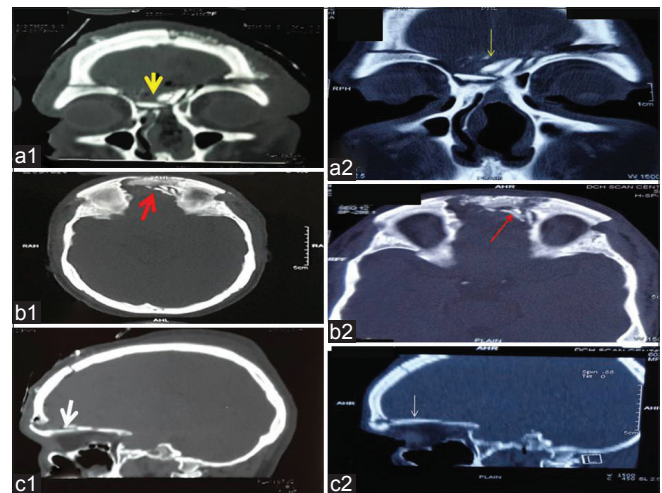


Figure 6: (a1) immediate postoperative coronal computerized tomography showing cribriform plate defect reconstructed with moulded osteomyofascial pedicled split craniotomy flap (thick yellow arrow showing the moulded osteomyofascial pedicled split craniotomy flap). (a2) One-month postoperative computerized tomography showing intact bone flap with new bone formation (thin yellow arrow). (b1) Immediate postoperative axial computerized tomography showing reconstructed anterior cranial fossa (thick red arrow indicates moulded osteomyofascial pedicled split craniotomy flap). (b2) One-month postoperative axial computerized tomography showing bone flap with new bone formation (thin red arrow shows new bone formation). (c1) Immediate postop sagittal computerized tomography showing reconstructed anterior cranial fossa with moulded osteomyofascial pedicled split craniotomy flap (thick white arrow shows moulded osteomyofascial pedicled split craniotomy flap). (c2) One month postoperative sagittal computerized tomography showing intact bone flap without osteolysis (thin white arrow shows moulded osteomyofascial pedicled split craniotomy flap)

with repair of inner table of frontal sinus done using our technique [Figure 8c]. One-month postoperative CT showed good bony support with new bone formation [Figure 9a1, a2, b1, b2, c1, c2].

Case 3

A 21-year-old male presented with posttraumatic optic neuropathy with CSF leak. CT showed fracture involving the frontal sinus, ethmoids, extending to sphenoid bone [Figure 10a1 and b1]. Craniotomy with optic nerve decompression and reconstruction of ACF done using MOPS flap. Postoperative CT showed good reconstruction of defect [Figure 10 a2, b2, c] with acceptable cosmesis.

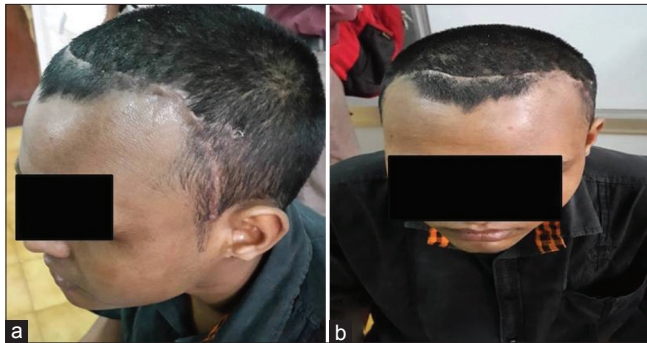

Figure 7: (a and b) Postoperative photograph showing good cosmetic outcome

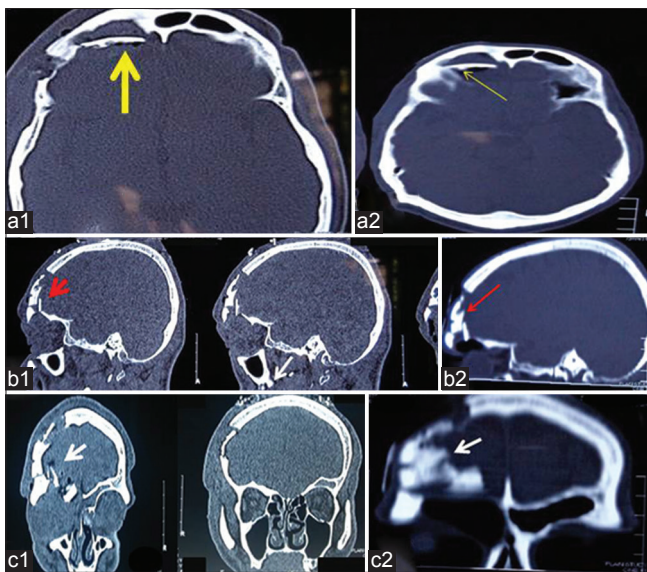


Figure 9: (a1) Immediate postoperative axial computerized tomography showing posterior wall of frontal sinus reconstructed with moulded osteomyofascial pedicled split craniotomy flap (thick yellow arrow showing the moulded osteomyofascial pedicled split craniotomy flap). (a2) One-month postoperative computerized tomography showing intact bone flap without osteolysis. (b1) Immediate postoperative sagittal computerized tomography showing reconstructed orbital roof and posterior frontal sinus wall (thick red arrow indicate moulded osteomyofascial pedicled split craniotomy flap). (b2) One month postoperative sagittal computerized tomography showing bone flap with no osteolysis (thin red arrow shows new bone formation). (c1) Immediate postoperative computerized tomography showing reconstructed orbital roof (thick white arrow showing moulded osteomyofascial pedicled split craniotomy flap). (c2) One month postoperative computerized tomography (thin white arrow showing new bone formation)

Case 4

A 41-year-old female presented with medial sphenoid wing meningioma infiltrating orbital roof and posterior ethmoids [Figure 11a-c]. Fronto-orbito-zygomatic osteotomy with reconstruction using MOPS flap was done [Figure 11d and e]. Postoperative period was uneventful, and the patient was discharged on day 7 with no complication. Postoperative CT showed good repair [Figure 12a and b] with acceptable cosmesis.

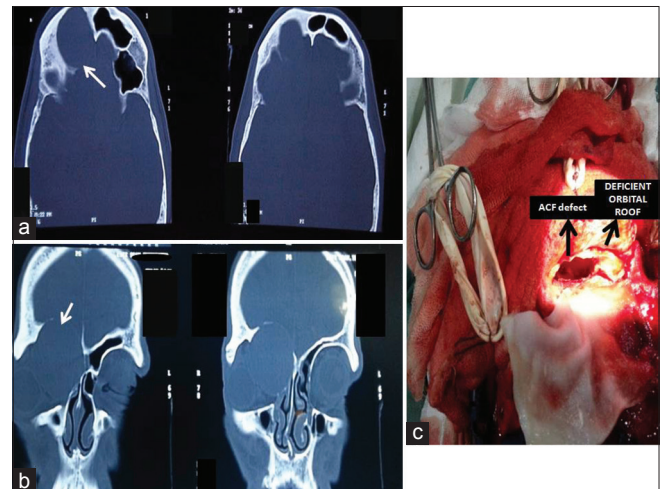


Figure 8: (a) Preoperative axial computerized tomography showing defect in posterior wall of right frontal sinus with mucocele. (b) Preoperative coronal computerized tomography showing defect in orbital roof. (c) Frontal craniotomy showing the deficient orbital roof and anterior cranial fossa defect

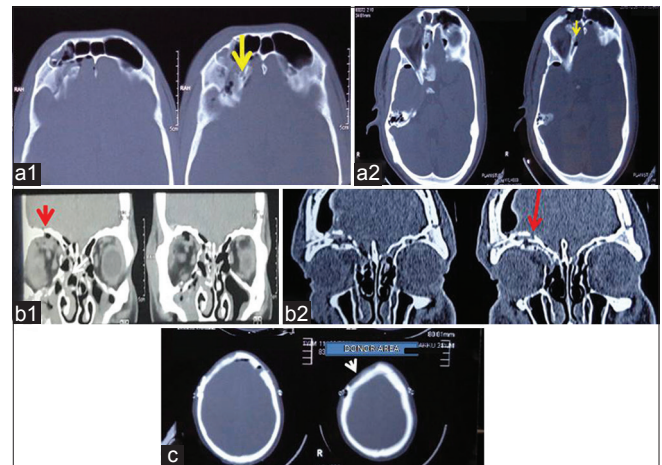


Figure 10: (a1) Preoperative axial computerized tomography showing anterior cranial fossa defect in patient who presented with traumatic cerebrospinal fluid rhinorrhea and optic nerve compression (thick yellow arrow showing fracture). (a2) Immediate postoperative axial computerized tomography showing good coverage of defect. (b1) Coronal computerized tomography showing the fracture of orbital roof. (b2) Immediate postoperative coronal computerized tomography showing good coverage of defect (thin red arrow showing moulded osteomyofascial pedicled split craniotomy flap). (c) Postoperative high axial computerized tomography showing the donor area with intact inner table

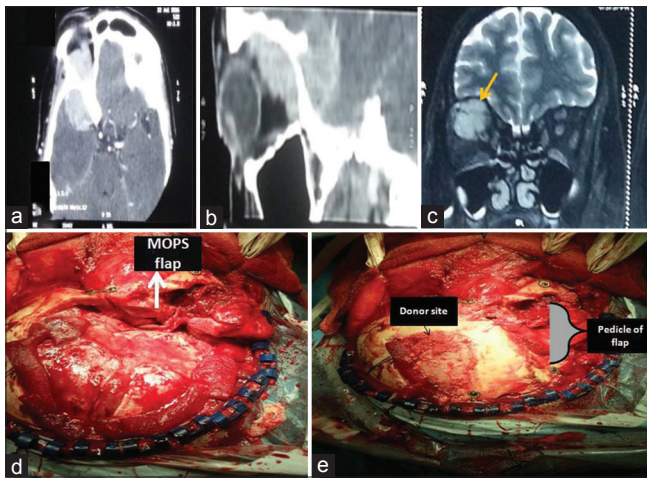


Figure 11: (a and b) Preoperative computerized tomography films showing the medial sphenoid wing meningioma destroying anterior skull base and orbital roof. (c) Preoperative coronal magnetic resonance imaging picture showing the orbital part of meningioma (orange arrow shows meningioma). (d) Intraoperative picture after Frontoorbito zygomatic craniotomy. (e) Bone flap replaced showing donor area. Moulded osteomyofascial pedicled split craniotomy flap is fashioned and seated to cover anterior cranial fossa defect. The flap is highlighted using grey bracket

Results

Age of the patients included in the study varied from 21 to 60 years (mean age 41.4 ± 17.8). Out of the five cases included in the study, 4 cases were males and 1 case female. One patient had an encephalocele (congenital), two patients had postinfectious etiology (one patient with frontal pyocele and the second frontal mucocele), one patient had meningioma, and one had complex nasoethmoid fracture. None of the patients had any comorbidities [Table 1]. The defect size was preoperatively assessed using CT, and an appropriate sized flap was planned. Dimension of the flap ranged from (3.5 x 3 cm) of bone and was further fashioned intraoperatively after assessing the true defect size following craniotomy and exposure. Lack of 3 dimensional reconstructive CT in our institution was a drawback. Mean operating time was 3 h and 30 min [Table 2]. Mean follow-up was 3.5 months. None of the cases had postoperative CSF leak and all had evidence of new bone formation without bone resorption and acceptable cosmesis.

Discussion

Anterior skull base reconstruction pose challenges due to difficult access, complex vascular anatomy, and local tissue quality. When there is a complex skull base defect, intracranial compartment communicates with exterior through the nasal cavity which may lead to life-threatening infections. This point towards the importance of ACF reconstruction. Limited options for reconstruction were the problem in the past. Reconstructive techniques have evolved over the past five to six decades to the latest vascularized-free tissue transfer.^[5] Initial reconstructive

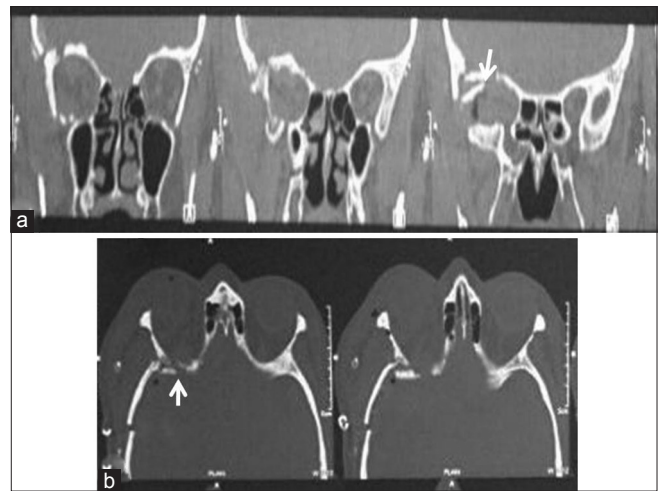


Figure 12: (a) Immediate postoperative computerized tomography coronal showing good coverage of orbital defect. (b) Postoperative axial computerized tomography showing moulded osteomyofascial pedicled split craniotomy flap covering anterior cranial fossa defect (white arrow showing moulded osteomyofascial pedicled split craniotomy flap covering the defect)

Table 1: The profile of patients included in the study

Cases	Age	Sex	Diagnosis	Follow-up
1	24	Male	Encephalocele	2 months
2	54	Male	Frontal pyocele	4 months
3	60	Male	Frontal mucocele	3 months
4	47	Female	Meningioma	3 months
5	21	Male	Traumatic	3 months

Table 2: The mean values of variables addressed in the study

Variables (mean values)	MOPS flap
Age (years)	41.4±17.8
Sex ratio (male:female)	4:1
Operating time (min)	212±40
Blood loss (ml)	850
Hospital stay (days)	5.8±1.3
Complications	0
Follow-up (months)	3±0.7

methods consisted of closure of defect with skin grafting. However, this technique had very high rate of postoperative CSF leak (71%). Techniques using local flaps such as glabellar flap, temporalis flap, and pericranial flap were tried. Even though these flaps are mouldable to the ACF beneath the supraorbital rim, the main limiting factor was inadequate tissue volume to support skull base. The long-term results were dismal due to tissue break down and CSF leak due to poor maintenance of vascularity. Reconstruction by free fascia lata grafts and free fat were described in literature.^[2] However, they carry high risk of failure in infected and previously irradiated sites. In 1970s, myocutaneous flap was introduced. Even though it provides adequate tissue bulk, the technique went into disrepute due to inadequate reach to skull base, necrosis of distal portion,

and detachment from primary site due to weight dragging the flap. None of the above methods provided a bony structural framework for supporting skull base to prevent brain herniating. The need for bony reconstruction made many Schuller *et al.*^[1] to provide rigid bony support using split rib supplemented with vascularized pericranial flap. Split calvarial free bone graft was popularized by Tessier in 1932.^[3] These free bone grafts lack inherent vascularity, and hence, they tend to absorb with time leading to CSF leak and infections.

Advances in bone implant technology made available exciting alloplastic materials such as titanium, hydroxyapatite, porous polyethylene for providing bony frame work. Synthetic material such as titanium and bone cements were also used.^[6,7] The problems of infection, implant extrusion made these options unsafe. Alloplastic implant may also does not allow natural vascularized tissue to grow and cover the defect.^[8-10]

Pedicled myocutaneous free flaps, free radial forearm, and free anterolateral thigh flap were described previously. However, use of free flaps is limited due to difficulties with recipient vessel availability, complex regional skull base anatomy, caliber, and maintenance of patency of vessels.^[11,12] In addition, donor site morbidity, two surgical fields, long operating time due to microvascular anastomosis made their use limited. In addition, these flaps did not provide adequate bony support.

Endoscopic nasal reconstruction of anterior skull base defects are being tried now but needs a lot of expertise in use of endoscope due to steep learning curve. Vascularized composite flaps with muscle bone and pericranium harvested from the adjacent area have been reported. However, this technique required additional incision and exposure.^[13-15] A composite flap consisting of reverse temporalis flap based on superficial temporal artery along with split calvarial graft from parietal bone was developed as an alternative.^[4] This technique had the disadvantage of distant donor site morbidity. They are also placed as a rigid bone into the defect and hence lack adequate contouring in complex ACF defects. Recently, a combination of reverse temporalis flap laid over a free split calvarial bone graft was developed.^[4] However, this was a limited study involving five patients and the question of survival of free split calvarial bone graft remains.

Hence, an ideal method of ACF reconstruction should (1) ensure watertight barrier between sinonasal tract and intracranial compartment (2) should be vascularized so as to avoid future bone resorption, (3) should be properly contoured to provide good esthesis, (4) should be autologous to prevent chance of extrusion and infection (5) should provide strong rigid bony support preventing brain herniation, (6) should be cost-effective (7) easy surgical technique and (8) should not require additional incision for exposure.

Our technique fulfills all the required criteria for an ideal reconstructive method in the following ways (1) the bone flap is harvested from the primary osteoplastic bone flap and hence require no additional incision or exposure, (2) the flap is a pedicled osteomyofascial flap with intact blood supply and hence provide a durable bony support, (3) the flap is contoured with multiple osteotomies and thus fit snugly into the defect and aid good contouring, (4) it provides rigid bony support separating intracranial compartment from the exterior, (5) the flap is autologous and hence reduced chance of extrusion or infection (6) cost-effective (7) does not require additional incisions or scars elsewhere in the body, (8) does not require tedious microsurgical procedure, and (9) can be used safely in infections and those requiring postoperative radiation.

Limitations to this technique are as follows (1) technical difficulties in splitting the outer table with intact periosteum, (2) more number of cases to be done with longterm follow-up for detecting complication of bone resorption, and (3) lack of randomized control trial with conventional method as control to document statistical significance of superiority of the new technique with conventional technique. Successful reconstruction was achieved in all cases with no serious complications.

Conclusion

MOPS craniotomy flap in reconstruction of ACF defect – a pilot study provides a novel, easily mastered, and cost-effective technique with minimal complication in reconstruction of complex ACF defects. The purpose of the article was to suggest a novel technique in skull base reconstruction that could provide results acceptable in terms of both functional and esthetic outcome. Although more cases with longer follow-up has to be done for precise results, we hope this technique has the advantage of reconstructing the ACF defect using the same craniotomy flap itself without creating any bony defect or scar elsewhere other than the primary craniotomy site. Thus, our procedure is a cost-effective method utilizing autologous vascularized bone for reconstruction of ACF defects with good functional and cosmetic outcome.

Acknowledgment

The authors specially thank their colleagues, in the Department of Neurosurgery and Plastic surgery, Medical College, Kottayam, for providing support and help in preparing the manuscript.

Financial support and sponsorship

Nil.

Conflicts of interest

There are no conflicts of interest.

References

- Schuller DE, Goodman JH, Miller CA. Reconstruction of the skull base. *Laryngoscope* 1984;94:1359-64.
- Clayman GL, DeMonte F, Jaffe DM, Schusterman MA, Weber RS, Miller MJ, *et al.* Outcome and complications of extended cranial-base resection requiring microvascular free-tissue transfer. *Arch Otolaryngol Head Neck Surg* 1995;121:1253-7.
- Tessier P. Autogenous bone grafts taken from the calvarium for facial and cranial applications. *Clin Plast Surg* 1982;9:531-8.
- Smith JE, Ducic Y, Adelson RT. Temporalis muscle flap for reconstruction of skull base defects. *Head Neck* 2010;32:199-203.
- Neligan PC, Mulholland S, Irish J, Gullane PJ, Boyd JB, Gentili F, *et al.* Flap selection in cranial base reconstruction. *Plast Reconstr Surg* 1996;98:1159-66.
- Tuusa SM, Peltola MJ, Tirri T, Lassila LV, Vallittu PK. Frontal bone defect repair with experimental glass-fiber-reinforced composite with bioactive glass granule coating. *J Biomed Mater Res B Appl Biomater* 2007;82:149-55.
- Mottaran R, Guarda-Nardini L, Fusetti S, Ferroneto G, Salar G. Reconstruction of a large post-traumatic cranial defect with a customized titanium plaque. *J Neurosurg Sci* 2004;48:143-7.
- Rocchi G, Caroli E, Belli E, Salvati M, Cimatti M, Delfini R, *et al.* Severe craniofacial fractures with frontobasal involvement and cerebrospinal fluid fistula: Indications for surgical repair. *Surg Neurol* 2005;63:559-63.
- Schmalbach CE, Webb DE, Weitzel EK. Anterior skull base reconstruction: A review of current techniques. *Curr Opin Otolaryngol Head Neck Surg* 2010;18:238-43.
- Scholsen M, Scholtes F, Collignon F, Robe P, Dubuisson A, Kaschten B, *et al.* Surgical management of anterior cranial base fractures with cerebrospinal fluid fistulae: A single-institution experience. *Neurosurgery* 2008;62:463-9.
- Califano J, Cordeiro PG, Disa JJ, Hidalgo DA, DuMornay W, Bilsky MH, *et al.* Anterior cranial base reconstruction using free tissue transfer: Changing trends. *Head Neck* 2003;25:89-96.
- Chiu ES, Kraus D, Bui DT, Mehrara BJ, Disa JJ, Bilsky M, *et al.* Anterior and middle cranial fossa skull base reconstruction using microvascular free tissue techniques: Surgical complications and functional outcomes. *Ann Plast Surg* 2008;60:514-20.
- Antonyshyn O, Colcleugh RG, Hurst LN, Anderson C. The temporalis myo-osseous flap: An experimental study. *Plast Reconstr Surg* 1986;77:406-15.
- Goel A. Vascularized osteomyoplastic flaps for skull base reconstruction. *Br J Neurosurg* 1994;8:79-82.
- Kim YO, Park BY. Reverse temporalis muscle flap: Treatment of large anterior cranial base defect with direct intracranial-nasopharyngeal communication. *Plast Reconstr Surg* 1995;96:576-84.