

# Full-Thickness Gluteus Medius Tears With or Without Concomitant Hip Arthroscopy

## Minimum 2-Year Outcomes Using an Open Approach and Contemporary Tendon Repair Techniques

David R. Maldonado,\* MD, Shawn Annin,\* MD, Jeffery W. Chen,<sup>†</sup> BA, Philip J. Rosinsky,\* MD, Jacob Shapira,\* MD, Ajay C. Lall,\*<sup>‡§</sup> MD, MS, and Benjamin G. Domb,\*<sup>‡§||</sup> MD

*Investigation performed at the American Hip Institute Research Foundation, Des Plaines, Illinois, USA*

**Background:** Gluteus medius (GM) tears are a well-established source of pain and disability. An open approach has been recognized with complete full-thickness and large GM tears, yet the current literature provides few reports on outcomes for this specific situation.

**Purpose:** To report and analyze minimum 2-year patient-reported outcomes (PROs) from patients who underwent open GM repair in the setting of a full-thickness tear with or without concomitant hip arthroscopy through use of contemporary tendon repair techniques.

**Study Design:** Case series; Level of evidence, 4.

**Methods:** Prospectively collected data were retrospectively reviewed for patients who underwent hip preservation surgery and total hip arthroplasty (THA) between April 2008 and May 2017. Patients were included in this study if they underwent open repair of GM full-thickness tears. The exclusion criteria were incomplete follow-up, workers' compensation status, repair regarding size and pattern of the GM, open repair of partial GM tear, open repair with allograft or autograft augmentation, and/or additional gluteus maximus transfer. Pre- and postoperative PROs for the modified Harris Hip Score (mHHS), Non-Arthritic Hip Score (NAHS), Hip Outcome Score Sport-Specific Subscale (HOS-SSS), and visual analog scale (VAS) score for pain and satisfaction were recorded. Statistical significance was set at  $P < .05$ .

**Results:** A total of 36 patients were included, of whom 12 received concomitant hip arthroscopy for intra-articular procedures. The mean  $\pm$  SD age, body mass index, and follow-up time were  $65.18 \pm 12.69$  years,  $28.97 \pm 4.95$  kg/m<sup>2</sup>, and  $40.8 \pm 26.19$  months, respectively. At minimum 2-year follow-up, the following outcome measures improved significantly: mHHS (from  $54.72 \pm 15.89$  to  $73.12 \pm 19.47$ ;  $P < .0001$ ), NAHS (from  $56.05 \pm 12.47$  to  $75.22 \pm 19.15$ ;  $P < .0001$ ); HOS-SSS (from  $20.30 \pm 20.21$  to  $44.23 \pm 35.85$ ;  $P < .0001$ ), and VAS (from  $4.95 \pm 2.70$  to  $2.67 \pm 2.81$ ;  $P < .0001$ ). There was 1 (2.8%) conversion to THA at 48 months after the index procedure.

**Conclusion:** Patients who underwent open repairs in the setting of full-thickness GM tears via contemporary tendon repair techniques, with or without concomitant hip arthroscopy, achieved favorable results in several PRO scores at minimum 2-year follow-up.

**Keywords:** gluteus medius; gluteus medius tear; outcomes; hip

Lateral hip pain, commonly referred to as greater trochanteric pain syndrome (GTPS),<sup>28</sup> is a prevalent and debilitating clinical complaint. Affecting women with a higher

incidence compared with men, GTPS has a peak incidence between the fourth and sixth decades of life.<sup>10</sup> This condition traditionally has been attributed to greater trochanteric bursitis. However, more recently, the literature on GTPS has shifted to abductor tendinopathy, as patients with GTPS have a higher incidence of gluteal tendinopathy (18%-50%) as opposed to bursitis (4%-46%).<sup>31,38,39</sup> In the

The Orthopaedic Journal of Sports Medicine, 8(7), 2325967120929330  
DOI: 10.1177/2325967120929330  
© The Author(s) 2020

This open-access article is published and distributed under the Creative Commons Attribution - NonCommercial - No Derivatives License (<https://creativecommons.org/licenses/by-nc-nd/4.0/>), which permits the noncommercial use, distribution, and reproduction of the article in any medium, provided the original author and source are credited. You may not alter, transform, or build upon this article without the permission of the Author(s). For article reuse guidelines, please visit SAGE's website at <http://www.sagepub.com/journals-permissions>.

past, abductor tendinopathy was often misdiagnosed or underdiagnosed; however, the use of magnetic resonance imaging (MRI) and other classic diagnostic imaging, such as ultrasound, has increased recognition of this condition.<sup>10-12,25</sup> Improved recognition combined with the aging population will likely result in an overall increased incidence of gluteal tendinopathy.

Most GTPS cases resolve through nonoperative treatment, with success rates greater than 90%.<sup>3,37</sup> These treatments include physical therapy, functional modifications, peritrochanteric cortisone injections, local anesthetic injections, and anti-inflammatory medications.<sup>22,29</sup> Biologic alternative treatments such as platelet-rich plasma injections have been proposed for partial gluteus medius (GM) tears; however, more research is needed to support the routine use of these treatments.<sup>20</sup> Clinical suspicion of abductor tendon tears should be raised when patients who were previously diagnosed as having trochanteric bursitis develop insidious lateral hip pain that is recalcitrant to nonoperative treatment.<sup>8</sup> A common complaint in patients with abductor tendinopathy or tendinitis is worsening pain with activity and lying on the affected side, especially at night.<sup>8</sup> Further, a Trendelenburg gait, pelvic tilt while standing on 1 leg, and reduced resisted abduction strength accompanied by pain on physical examination may suggest gluteal tendon dysfunction that necessitates surgical management.<sup>8,10</sup>

With the failure of nonoperative treatment, GM tendon tears are typically treated by either an open or an endoscopic surgical approach. Both techniques have been described in the literature with good and comparable patient outcomes.<sup>6,34,36</sup> Classically, the open surgical approach was predominantly used because it allows for full visualization of the footprint as well as accessibility and easy preparation of the bony surfaces for fixation of the tendon. Nevertheless, technological advancements have allowed for the steady increase in a minimally invasive endoscopic approach to GM repairs.<sup>7,15</sup> Depending on the size of the tear and retraction length of the tendon, either surgical approach may be indicated to optimize results.

The purpose of this study was to report and analyze minimum 2-year patient-reported outcomes (PROs) in patients who underwent open GM repair in the setting of full-thickness tears via contemporary tendon repair techniques,

with or without concomitant hip arthroscopy. We hypothesized that patients who undergo open GM repair with or without concomitant hip arthroscopy will have favorable postoperative outcomes at minimum 2-year follow-up.

## METHODS

### Patient Selection

Data for all patients who underwent hip preservation surgery and total hip arthroplasty (THA) by the senior surgeon (B.G.D.) between April 2008 and May 2017 were prospectively collected. Patients were included if they underwent open GM full-thickness tear repairs. Exclusion criteria were as follows: incomplete follow-up, workers' compensation status, arthroscopic GM repair regarding size or pattern of the tear,<sup>18</sup> open repair of partial GM tear, open repair with allograft or autograft augmentation, and/or additional gluteus maximus transfer. PROs were recorded for patients with minimum 2-year follow-up. These included the modified Harris Hip Score (mHHS), Non-Arthritic Hip Score (NAHS), Hip Outcome Score Sport-Specific Subscale (HOS-SSS), 12-item International Hip Outcome Tool (iHOT-12), and visual analog scale (VAS) score for pain and satisfaction. Full-thickness GM tears were defined as type 4 or 5 according to Lall et al.<sup>28</sup> Patient selection criteria are shown in Figure 1.

### Participation in the American Hip Institute Hip Preservation Registry

Although some patients in this study may have been analyzed in another study, the present study represented a unique analysis of a unique cohort. This study was approved by an institutional review board.

### Preoperative Physical Examination

All patients underwent preoperative physical examination that evaluated abnormal gait, defined as antalgic and/or Trendelenburg gait.<sup>8</sup> Tenderness around the greater trochanter was assessed bilaterally. While the patient was lying in the lateral position, abductor strength was assessed through extension of the hip and knee and internal rotation at the hip.

|| Address correspondence to Benjamin G. Domb, MD, 999 E Touhy Ave, Suite 450, Des Plaines, IL 60018, USA (email: DrDomb@americanhipinstitute.org).

\*American Hip Institute Research Foundation, Des Plaines, Illinois, USA.

†Vanderbilt University School of Medicine, Nashville, Tennessee, USA.

‡American Hip Institute, Des Plaines, Illinois, USA.

§AMITA Health St Alexius Medical Center, Hoffman Estates, Illinois, USA.

Revision submitted February 16, 2020; accepted February 26, 2020.

One or more of the authors has declared the following potential conflict of interest or source of funding: D.R.M. has received hospitality payments from Arthrex, Stryker, and Smith & Nephew. P.J.R. has received hospitality payments from Arthrex, Stryker, and Smith & Nephew. J.S. has received hospitality payments from Arthrex, Stryker, and Smith & Nephew. A.C.L. has received research support from Arthrex, Stryker, and Medacta; educational support from Medwest and Smith & Nephew; consulting fees from Arthrex and Graymont Medical; food and beverage from Smith & Nephew, Stryker, Zimmer Biomet, Arthrex; and travel and lodging from Stryker and Arthrex. B.G.D. has had ownership interests in Hinsdale Orthopaedics, the American Hip Institute, SCD#3, North Shore Surgical Suites, and Munster Specialty Surgery Center; has received research support from Arthrex, ATI, the Kauffman Foundation, Stryker, and Pacira Pharmaceuticals; has received consulting fees from Adventist Hinsdale Hospital, Arthrex, MAKO Surgical, Medacta, Pacira Pharmaceuticals, and Stryker; has received educational support from Arthrex, Breg, and Medwest; has received speaking fees from Arthrex and Pacira Pharmaceuticals; and receives royalties from Arthrex, DJO Global, MAKO Surgical, Stryker, and Orthomerica. AOSSM checks author disclosures against the Open Payments Database (OPD). AOSSM has not conducted an independent investigation on the OPD and disclaims any liability or responsibility relating thereto.

Ethical approval for this study was obtained from Advocate Health Care Institutional Review Board (ID No. AHC-5276).

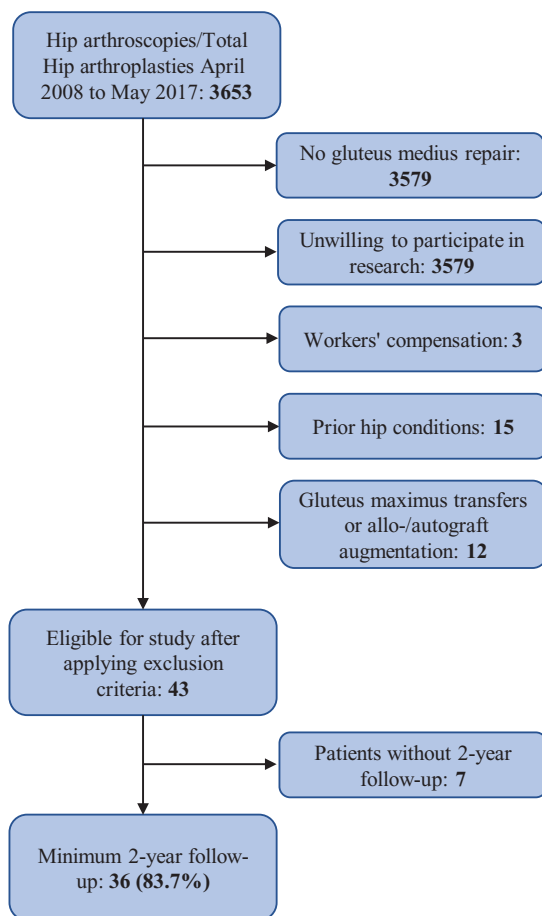


Figure 1. Patient selection criteria.

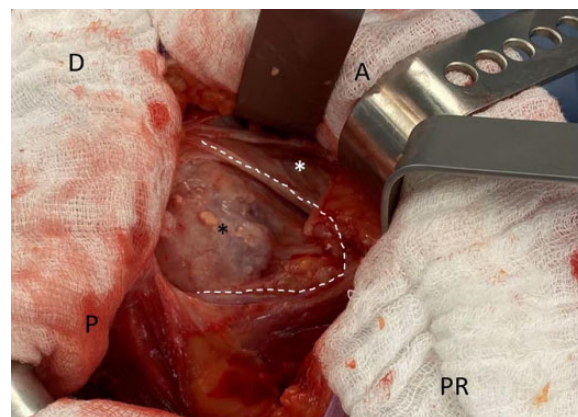


Figure 2. Retracted full-thickness gluteus medius tear. Left hip with patient positioned in the lateral decubitus position. A, anterior; D, distal; P, posterior; PR, proximal; black asterisk, greater trochanter; white asterisk, gluteus medius muscle; white dotted line, border of full-thickness gluteus medius tear.

and/or tenderness and abductor weakness that did not improve with nonsurgical management (rest, nonsteroidal anti-inflammatory drugs, and physical therapy) for at least 3 months, MRI findings of full-thickness gluteal tears, and the presence of substantial gluteal retraction. Assessment was thorough to ensure that the peritrochanteric space was the source of the pain.<sup>2</sup> In cases of additional intra-articular sources of pain, such as labral tears and femoroacetabular impingement (FAI), concomitant hip arthroscopy for intra-articular procedures (eg, labral repair, FAI correction) was indicated.

Surgical Technique

*Concomitant Hip Arthroscopy and Open GM Repair.* All concomitant hip arthroscopy and open GM repairs were performed with the patient in the supine position on a well-padded perineal post. Under traction and after hip joint venting,<sup>33</sup> the standard anterolateral, midanterior, and distal anterolateral accessory portals were used to perform intra-articular procedures.<sup>16,27</sup> Upon completion of intra-articular procedures, traction was released, and the 70° arthroscope was moved to the distal anterolateral accessory portal to assess the peritrochanteric space. If a full-thickness tear that was not amenable to an endoscopic repair was found after examination of the GM insertions (Figure 2), an open approach was undertaken without changing the patient’s position.<sup>24</sup> Open surgical approach was the same regardless of position of the patient (supine vs lateral decubitus).<sup>28</sup>

*Open GM Repair Without Intra-articular Hip Arthroscopic Procedures.* Patients with a source of pain exclusively at the peritrochanteric space received open GM repairs without the addition of hip arthroscopy. Patients were placed on the operating table in the lateral decubitus position. The incision was made over the Gibson interval and was carried through the subcutaneous tissues to identify the fascia lata, which was also incised in the

TABLE 1

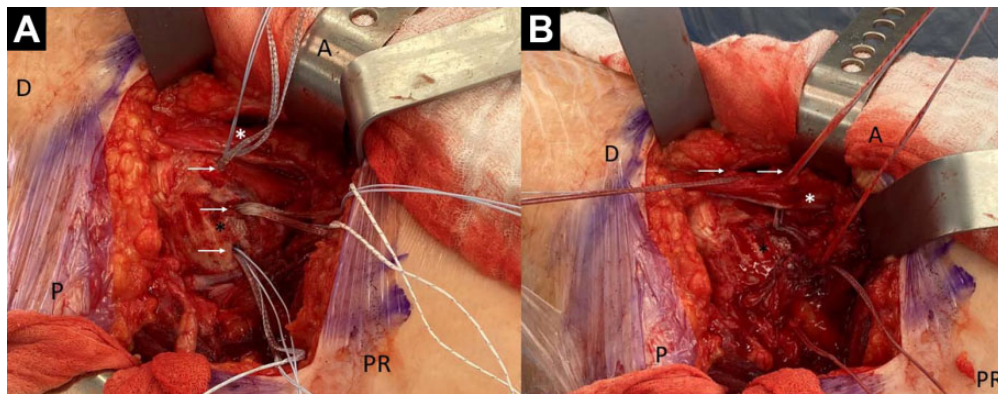
Medical Research Council Grading of Muscle Power

Grade	Interpretation
0	No movement
1	Only a trace or flicker of movement
2	Active movement with gravity eliminated
3	Active movement against gravity without resistance
4	Active movement against gravity with resistance
5	Normal power

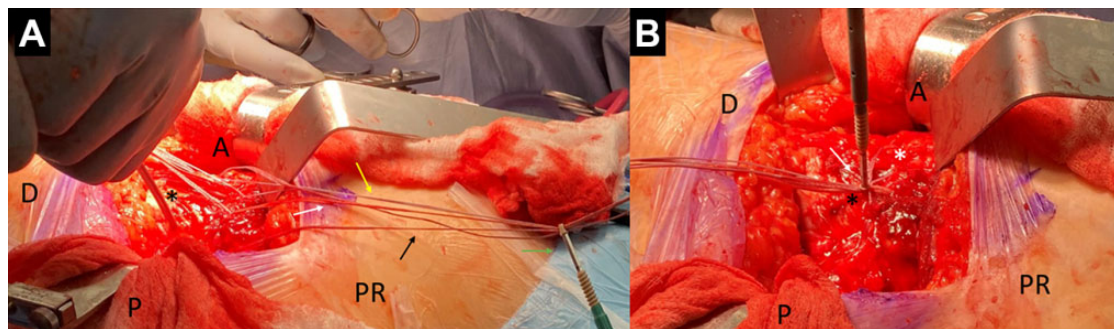
Routinely, the modified resisted internal rotation test was also used.<sup>42</sup> Hip strength was evaluated with the Medical Research Council grading scale from 0 (complete weakness) to 5 (full strength) (Table 1).<sup>19,40</sup> Care was taken during preoperative evaluation to confirm that the peritrochanteric space was an independent pain source, and ultrasound-guided diagnostic injections were used when necessary.<sup>2</sup> Patients suspected of having GM tears underwent further diagnostic MRI.<sup>24,30</sup>

Surgical Indications

Candidates for open GM repair were patients who had been evaluated preoperatively with peritrochanteric pain



**Figure 3.** Proximal row of the gluteus medius repair construct. Left hip with patient positioned in the lateral decubitus position. (A) Three knotless suture anchors have been placed for the medial row (white arrows). (B) Tapes from each knotless suture anchor (white arrows) are passed through the gluteus medius tendon. A, anterior; D, distal; P, posterior; PR, proximal; black asterisk, greater trochanter; white asterisk, gluteus medius muscle.



**Figure 4.** Lateral row of the gluteus medius repair construct. Left hip with patient positioned in the lateral decubitus position. (A) One pair of each previous anchor (anterior, yellow arrow; center, white arrow; posterior, black arrow) is passed through the knotless suture anchor (green arrow) to create a suture bridge construct. (B) The suture bridge construct is shown. A, anterior; D, distal; P, posterior; PR, proximal; black asterisk, greater trochanter; white asterisk, gluteus medius muscle.

Gibson interval between the tensor fascia lata and gluteus maximus.<sup>35</sup> The GM tendon was identified, and the tear pattern and tissue condition were assessed. To improve visualization, trochanteric bursa and/or nonviable tissues were debrided. Attention was taken to achieve as much tendon mobilization as possible by releasing any surrounding scar tissue, especially at the inferior tendon. The greater trochanter lateral facet was decorticated to create a bleeding bed of bone for healing.

**Repair Technique.** Once the GM tendon was exposed and mobilized and clear visualization was achieved, a double-row transosseous equivalent was constructed as follows: Proximal row fixation was performed with 2 or 3 knotless anchors (PEEK SwiveLock 5.5 mm; Arthrex), loaded with 2 pairs of FiberTape sutures (Arthrex) each placed in the proximal portion of the tendon footprint in the lateral facet (Figure 3A). The 4 limbs of the sutures from each anchor were passed through the tendon in a horizontal mattress fashion without tying (Figure 3B). For the distal row, 2 additional knotless anchors (PEEK SwiveLock 5.5 mm) were used and assembled with 1 pair of each previous anchor to create a suture bridge construct (Figure 4). This

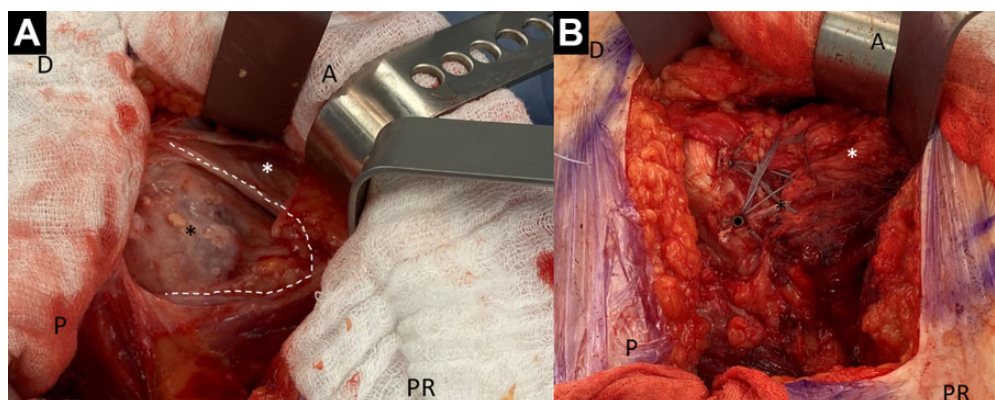
provides additional compression of the tendon against the bone in the footprint (Figure 5).<sup>14</sup>

### Rehabilitation

Postoperatively, patients who underwent full-thickness GM tear repair were instructed to use crutches with partial weightbearing (20 lb) while remaining in a low-profile abduction brace (DJO Global) for 8 weeks. Patients were instructed to avoid hip abduction, adduction, internal rotation, and external rotation while in the brace. After removal of the brace, patients were instructed to wean off crutches and begin physical therapy to regain strength and mobility.

### Patient-Reported Outcomes

Preoperative and minimum 2-year postoperative outcomes were evaluated with the mHHS, NAHS, HOS-SSS, iHOT-12, and VAS.<sup>21</sup> The VAS, which was used to evaluate pain and satisfaction, was recorded on a 10-point scale, with 10 being the highest level of each outcome (ie, 0, no pain; 10,



**Figure 5.** Before and after open full-thickness gluteus medius repair. Left hip with patient positioned in the lateral decubitus position. (A) Full-thickness gluteus medius tear. (B) Final double-row repair construct. A, anterior; D, distal; P, posterior; PR, proximal; black asterisk, greater trochanter; white asterisk, gluteus medius muscle; white dotted line, border of full-thickness gluteus medius tear.

highest pain; 0, lowest satisfaction; 10, highest satisfaction). The American Hip Institute Research began collecting iHOT-12 scores in 2014, and they were available for only a subset of patients. The proportions of patients who achieved the minimal clinically important difference (MCID) for mHHS and patient acceptable symptomatic state (PASS) for mHHS and iHOT-12 were also reported.<sup>23,26</sup> The questionnaires were completed either during a clinic appointment, through encrypted email, or by telephone. Any secondary arthroscopies, conversions to THA, or postoperative complications were recorded.

**Statistical Analysis**

Microsoft Excel was used to perform all analyses. The Shapiro-Wilks test was used to assess the parametricity of continuous outcomes, with  $P > .05$  indicating a normal distribution. A paired 2-tailed  $t$  test was then used to compare pre- versus postoperative outcomes. Statistical significance was considered as  $P < .05$ .

**RESULTS**

**Patient Demographics and Characteristics**

After all inclusion and exclusion criteria were applied, 36 patients were included in the study. Of the 36 patients, 24 patients underwent an open GM repair without any additional procedures whereas 12 patients received concomitant hip arthroscopy to address additional intra-articular pathologies. No patients underwent concomitant THA. A total of 4 patients had prior ipsilateral THAs, and 5 patients had prior ipsilateral hip arthroscopies. The mean age and body mass index were  $65.18 \pm 12.69$  years and  $28.97 \pm 4.95$  kg/m<sup>2</sup>, respectively. The mean follow-up time was  $40.8 \pm 26.19$  months (Table 2). No revision arthroscopies were performed. One patient converted to THA 48.2 months after the index procedure; that patient's outcomes were not included in the analysis of PROs.

**TABLE 2**  
Demographics of Patients With Full-Thickness Gluteus Medius Tears Receiving Open Repairs

Parameter	Data
Hips, n (%)	
Left	21 (58.3)
Right	15 (41.7)
Sex, n (%)	
Female	31 (86.1)
Male	5 (13.9)
Age at surgery, y, mean $\pm$ SD (median; range)	$65.18 \pm 12.69$ (68.4; 57.78-73.66)
Body mass index, kg/m <sup>2</sup> , mean $\pm$ SD (median; range)	$28.97 \pm 4.95$ (28.8; 26.41-31.17)
Follow-up time, mo, mean $\pm$ SD (median; range)	$40.8 \pm 26.19$ (28.35; 24.16-46.20)
Follow-up rate, %	100
Procedure type, n (%)	
Open	24 (66.7)
Arthroscopic and open	12 (33.3)
Future reoperations and endpoints, n (%)	
Arthroscopy/endoscopy	0 (0)
Conversion to total hip arthroplasty after gluteus medius repair	1 (2.8)

**Patient-Reported Outcomes**

All outcome measures showed significant improvements from the preoperative assessment to a minimum of 2 years postoperatively (Table 3 and Figure 6). The preoperative to postoperative outcomes were as follows: mHHS, from  $54.72 \pm 15.89$  to  $73.12 \pm 19.47$  ( $P < .0001$ ); NAHS, from  $56.05 \pm 12.47$  to  $75.22 \pm 19.15$  ( $P < .0001$ ); HOS-SSS, from  $20.30 \pm 20.21$  to  $44.23 \pm 35.85$  ( $P < .0001$ ); and VAS pain, from  $4.95 \pm 2.70$  to  $2.67 \pm 2.81$  ( $P < .0001$ ). The subset of patients for whom the iHOT-12 was reported (15/36) showed improvement from  $26.89 \pm 13.28$  preoperatively to  $60.31 \pm 25.39$  postoperatively ( $P < .001$ ). Of the 36 patients,

TABLE 3  
Preoperative and Minimum 2-Year Patient-Reported Outcomes Scores<sup>a</sup>

Outcome Measure	Preoperative	Minimum 2-Year	P Value
Modified Harris Hip Score	54.72 ± 15.89 (54.5) [39-64.25]	73.12 ± 19.47 (74) [58-90]	<.0001
Non-Arthritic Hip Score	56.05 ± 12.47 (55.13) [45-67.875]	75.22 ± 19.15 (73.75) [61.56-93.12]	<.0001
Hip Outcome Score Sport-Specific Subscale	20.30 ± 20.21 (15.28) [2.77-27.08]	44.23 ± 35.85 (33.33) [11.1-83.33]	<.0001
12-item International Hip Outcome Tool <sup>b</sup>	26.89 ± 13.28 (22.42) [16.89-33.31]	60.31 ± 25.39 (57.35) [40.20-79.72]	<.0001
Visual analog scale for pain <sup>c</sup>	4.95 ± 2.70 (5.35) [2.52-7.5]	2.67 ± 2.81 (2) [0-5]	<.0001
Visual analog scale for satisfaction <sup>c</sup>	—	7 ± 3.49 (8) [6-10]	

<sup>a</sup>Values are expressed as mean ± SD (median) [95% CI]. Boldface indicates statistically significant difference ( $P < .05$ ).

<sup>b</sup>Scores available for 15 patients.

<sup>c</sup>On a scale from 0 to 10, with 10 being maximum pain and maximum satisfaction.

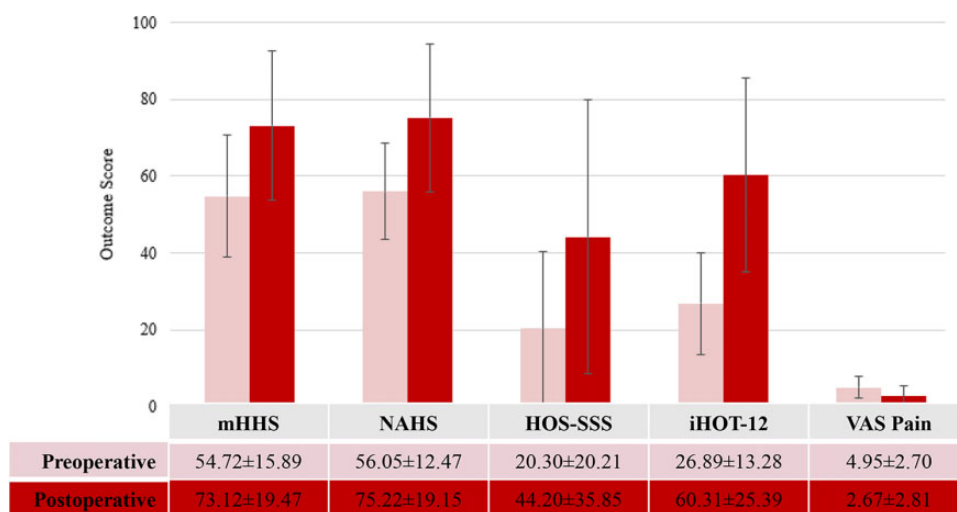


Figure 6. Patient-reported outcomes at baseline and minimum 2-year follow-up. All differences between pre- and postoperative scores were statistically significant ( $P < .0001$  for all). Error bars represent standard deviation. HOS-SSS, Hip Outcome Score Sport-Specific Subscale; iHOT-12, 12-item International Hip Outcome Tool; mHHS, modified Harris Hip Score; NAHS, Non-Arthritic Hip Score; VAS, visual analog scale.

TABLE 4  
Minimal Clinically Important Difference (MCID)  
and Patient Acceptable Symptomatic State (PASS)

Measure	n
Modified Harris Hip Score	
MCID ( $\geq 8$ )	
Achieved	17
Did not achieve	19
PASS ( $\geq 74$ )	
Achieved	25
Did not achieve	11
12-item International Hip Outcome Tool	
PASS ( $\geq 72$ )	
Achieved	15
Did not achieve	0

25 (69.4%) achieved the PASS and 17 (47.2%) achieved the MCID for mHHS. All 15 patients for whom the iHOT-12 was reported achieved PASS for the iHOT-12 (100%) (Table 4).

### Abductor Strength Test

Of the 36 patients examined, data were available for 35 patients who underwent preoperative and postoperative abduction strength tests, ranging from 3 to 6 months postoperatively. There were 7 patients who had a grade of 5 preoperatively and could not improve. Of the remaining 28 patients, 16 improved abductor strength scores by at least 1 grade, 5 patients remained at the same strength grade preoperatively to postoperatively, and 7 patients decreased in strength grade postoperatively. A significant improvement in pain was noted for this group overall ( $P = .029$ ), with 71.43% of patients experiencing no pain upon abductor strength testing, an increase from 45.71% preoperatively.

### DISCUSSION

In this ongoing study, full-thickness GM tears treated with an open approach and contemporary tendon repair techniques showed statistically significant improvement

with respect to 4 validated functional hip PROs and VAS pain scores at minimum 2-year follow-up. Of 36 patients, 25 (69.4%) achieved the PASS and 17 (47.2%) achieved the MCID for mHHS. All 15 patients for whom iHOT-12 scores were reported achieved PASS for the iHOT-12 (100%). Patient satisfaction, on average, was 7.0 out of 10. Of the 36 patients, 16 (44%) increased their strength by at least 1 grade on manual muscle testing, however, 7 patients had decreased abduction strength postoperatively. Moreover, 71.43% of patients experienced no pain upon abductor strength testing, an increase from 45.71% preoperatively. Pain on abductor strength testing decreased significantly from preoperatively to postoperatively ( $P = .029$ ).

The literature indicates that GM tears have been shown to contribute to chronic lateral hip pain to a greater extent than was previously known.<sup>9</sup> Technological advancement in diagnostic imaging studies and targeted physical examinations have led to the increased recognition and management of abductor pathology.<sup>24</sup> Despite this, GM tears are quite often missed, highlighting the difficulty of managing lateral hip pain.<sup>10,34</sup> Nonetheless, once tears are correctly identified, treatment of abductor tears often leads to positive results.<sup>7,34</sup>

Some studies have reported clinical improvement and favorable PROs after GM repair. In their retrospective study, Makridis et al<sup>32</sup> examined 67 patients who underwent open GM repair with the double-row technique at an average of 4.6 years of follow-up (range, 1-8 years). Those investigators found good clinical results in 85% of patients, as indicated by significantly improved symptoms and a disappearance of abnormal MRI findings that are suggestive of abductor tear pathology. However, the investigators noted 11 treatment failures, 4 of which entailed significant muscle atrophy. When assessing potential predictors of outcomes, Makridis et al found muscle atrophy to be a negative prognostic factor ( $P < .05$ ) and thus advocated caution in using this technique in patients with preoperative signs of muscle atrophy on MRI. Nonetheless, the investigators did not effectively report the type of GM tear treated, and it seems—based on the description provided—that mostly partial GM tears were included, which differs from the present investigation.

Walsh et al<sup>43</sup> conducted a study on 72 patients who underwent open GM tendon repair with nonabsorbable sutures in a vertical mattress configuration and bone tunnels; 67 of the patients were women, the average age was 62 years, and the minimum follow-up was 12 months. Outcomes were assessed with the Merle d'Aubergine–Postel hip scoring system.<sup>13</sup> Significant improvement was seen at 12-month follow-up, and 95% of patients had minimal or absent pain by 6 months postoperatively. Further, normal walking ability increased from 5% preoperatively to 78% by 6 months postoperatively. Nonetheless, only 7% of the original group described by Walsh et al had a full-thickness GM tear, whereas all patients in the current study had full-thickness GM tears. Our study showed similar improvement in outcome scores; however, in the Walsh et al study, approximately half of patients achieved the PASS and 69.4% of patients achieved the MCID for mHHS. Included among the patients in the current study who did

not reach PASS were the 7 patients who had a decreased abductor strength grade postoperatively. Because of the variability of GM pathology and the time at which patients are treated, the success of the procedure may be limited. Moreover, progression of GM muscle fiber deterioration may continue after repair. Nonetheless, although MCID and PASS represent clinically significant improvement, patients in the current study were ultimately satisfied with the procedure (VAS satisfaction score of 7).

With the advancement of minimally invasive techniques, the use of endoscopic GM repair has increased. Although literature on the outcomes of endoscopic gluteal repairs is limited to small series and short-term follow-up periods, the procedure has been shown to produce positive results.<sup>17,36</sup> Chandrasekaran et al<sup>6</sup> evaluated the outcomes of endoscopic GM repair along with correction of intra-articular pathology in 34 patients with minimum 2-year follow-up. Those investigators noted significant improvement in PRO scores and a high satisfaction rating of 8.5. Further, 58% of patients who had a gait deviation preoperatively regained normal gait. Voos et al<sup>41</sup> similarly reported on 10 patients after endoscopic GM repair and found that at an average of 25 months, all patients had resolution of lateral hip pain, and 9 patients who had weakness in hip abduction preoperatively regained full strength.

With both approaches showing clear benefit, choice of treatment of abductor tears may become challenging. Studies have compared open versus endoscopic repair of abductor tendon tendinopathy; however, the conclusions have been inconclusive. Although a more technically demanding procedure, endoscopic repair has been shown to provide good results, with decreased overall morbidity compared with open repair.<sup>7</sup> Chandrasekaran et al<sup>7</sup> performed a systematic review to compare the outcome of open versus endoscopic gluteal tendon repair. The review analyzed 3 studies reporting on 127 patients who underwent open procedures and 4 studies reporting on 40 patients who underwent endoscopic procedures. The cohorts had similar outcome scores and improvement in abduction strength, however the open techniques had a higher reported complication rate. More specifically, the combined re-tear incidence was 10 of 127 patients in the open cohort compared with 0 of 40 patients in the endoscopic repair cohort. This finding may be related to more severe tears requiring the open approach.<sup>1</sup>

The choice of modality for GM repairs should be determined based on the size of the tear and retraction length of the tendon, as well as surgeon preference and expertise, to optimize results. This recommendation is corroborated by Nawabi et al,<sup>34</sup> who retrospectively examined 27 patients who underwent repair of the GM tendon. The study included 9 patients (9 hips) with open repair and 18 patients (21 hips) with endoscopic repair. The investigators found large and significant improvements in PROs as well as similar clinical outcomes between the 2 groups. Of note, the surgical time for the open technique was significantly shorter than that for the endoscopic technique, and it was suggested that open techniques are preferred for patients who have no intra-articular pathology requiring hip arthroscopy or when the tears are large and retracted. The open technique seems to be much more suitable for these

larger tears because of its ability for full footprint exposure, release of the retracted tear, and conversion to salvage procedure such as gluteus maximus and tensor fascia lata transfer if needed.<sup>5</sup>

### Limitations

Limitations must be acknowledged for this ongoing study. First, this was a nonrandomized study without a control group. Second, data collection was performed in a prospective manner; nonetheless, this was a retrospective study, which introduces bias. Third, although this study is one of the largest case series of open management of full-thickness GM tears with minimum 2-year follow-up reported in current literature, the sample size was still small. Nonetheless, our sample was representative of the population of interest. Fourth, longer follow-up is required to demonstrate longevity of the results. Fifth, the inclusion of those patients who underwent GM repair with concomitant hip arthroscopy may act as a confounder on the overall effects of each procedure on patient outcomes.

### Strengths

The inclusion of multiple validated functional hip outcome scores is a strength of this case series study. Currently, this is one of the few studies to report PROs specifically for patients with open repair of full-thickness GM tear (1) with minimum 2-year follow-up and (2) using modern tendon repair techniques.<sup>4</sup>

### CONCLUSION

Patients who underwent open repairs, in the setting of full-thickness GM tears and with contemporary tendon repair techniques, achieved significantly improved results in several PRO scores at minimum 2-year follow-up.

### REFERENCES

- Alpaugh K, Chilelli BJ, Xu S, Martin SD. Outcomes after primary open or endoscopic abductor tendon repair in the hip: a systematic review of the literature. *Arthroscopy*. 2015;31(3):530-540.
- Bardowski EA, Byrd JWT. Ultrasound-guided intra-articular injection of the hip: the Nashville sound. *Arthrosc Tech*. 2019;8(4):e383-e388.
- Brooker AF. The surgical approach to refractory trochanteric bursitis. *Johns Hopkins Med J*. 1979;145(3):98-100.
- Byrd JWT. Gluteus medius repair with double-row fixation. *Arthrosc Tech*. 2013;2(3):e247-e250.
- Chandrasekaran S, Darwish N, Vemula SP, Lodhia P, Suarez-Ahedo C, Domb BG. Outcomes of gluteus maximus and tensor fascia lata transfer for primary deficiency of the abductors of the hip. *Hip Int*. 2017;27(6):567-572.
- Chandrasekaran S, Gui C, Hutchinson MR, Lodhia P, Suarez-Ahedo C, Domb BG. Outcomes of endoscopic gluteus medius repair: study of thirty-four patients with minimum two-year follow-up. *J Bone Joint Surg Am*. 2015;97(16):1340-1347.
- Chandrasekaran S, Lodhia P, Gui C, Vemula SP, Martin TJ, Domb BG. Outcomes of open versus endoscopic repair of abductor muscle tears of the hip: a systematic review. *Arthroscopy*. 2015;31(10):2057-2067.e2.
- Chandrasekaran S, Vemula SP, Gui C, Suarez-Ahedo C, Lodhia P, Domb BG. Clinical features that predict the need for operative intervention in gluteus medius tears. *Orthop J Sports Med*. 2015;3(2):2325967115571079.
- Chi AS, Long SS, Zoga AC, et al. Prevalence and pattern of gluteus medius and minimus tendon pathology and muscle atrophy in older individuals using MRI. *Skeletal Radiol*. 2015;44(12):1727-1733.
- Chung CB, Robertson JE, Cho GJ, Vaughan LM, Copp SN, Resnick D. Gluteus medius tendon tears and avulsive injuries in elderly women: imaging findings in six patients. *AJR Am J Roentgenol*. 1999;173(2):351-353.
- Connell DA, Bass C, Sykes CAJ, Young D, Edwards E. Sonographic evaluation of gluteus medius and minimus tendinopathy. *Eur Radiol*. 2003;13(6):1339-1347.
- Cvitancic O, Henzie G, Skezas N, Lyons J, Minter J. MRI diagnosis of tears of the hip abductor tendons (gluteus medius and gluteus minimus). *AJR Am J Roentgenol*. 2004;182(1):137-143.
- d'Aubigné RM, Postel M. The classic: functional results of hip arthroplasty with acrylic prosthesis. *Clin Orthop Relat Res*. 2009;467(1):7-27.
- Davies JF, Davies DM. Surgical technique for the repair of tears to the gluteus medius and minimus tendons of the hip. *JBJS Essent Surg Tech*. 2014;4(2):e11.
- Dishkin-Paset JG, Salata MJ, Gross CE, et al. A biomechanical comparison of repair techniques for complete gluteus medius tears. *Arthroscopy*. 2012;28(10):1410-1416.
- Domb B, Hanypsiak B, Botser I. Labral penetration rate in a consecutive series of 300 hip arthroscopies. *Am J Sports Med*. 2012;40(4):864-869.
- Domb BG, Botser I, Giordano BD. Outcomes of endoscopic gluteus medius repair with minimum 2-year follow-up. *Am J Sports Med*. 2013;41(5):988-997.
- Domb BG, Carreira DS. Endoscopic repair of full-thickness gluteus medius tears. *Arthrosc Tech*. 2013;2(2):e77-e81.
- Dyck PJ, Boes CJ, Mulder D, et al. History of standard scoring, notation, and summation of neuromuscular signs: a current survey and recommendation. *J Peripher Nerv Syst*. 2005;10(2):158-173.
- Fitzpatrick J, Bulsara M, O'Donnell J, McCrory P, Zheng M. The effectiveness of platelet-rich plasma injections in gluteal tendinopathy: a randomized, double-blind controlled trial comparing a single platelet-rich plasma injection with a single corticosteroid injection. *Am J Sports Med*. 2018;46(4):933-939.
- Griffin DR, Parsons N, Mohtadi NGH, Safran MR; Multicenter Arthroscopy of the Hip Outcomes Research Network. A short version of the International Hip Outcome Tool (iHOT-12) for use in routine clinical practice. *Arthroscopy*. 2012;28(5):611-616.
- Grimaldi A, Mellor R, Hodges P, Bennell K, Wajswelner H, Vicenzino B. Gluteal tendinopathy: a review of mechanisms, assessment and management. *Sports Med*. 2015;45(8):1107-1119.
- Harris JD, Brand JC, Cote MP, Faucett SC, Dhawan A. Research pearls: the significance of statistics and perils of pooling. Part 1: clinical versus statistical significance. *Arthroscopy*. 2017;33(6):1102-1112.
- Hartigan DE, Perets I, Walsh JP, Domb BG. Imaging of abductor tears: stepwise technique for accurate diagnosis. *Arthrosc Tech*. 2017;6(5):e1523-e1527.
- Kingzett-Taylor A, Tirman PF, Feller J, et al. Tendinosis and tears of gluteus medius and minimus muscles as a cause of hip pain: MR imaging findings. *AJR Am J Roentgenol*. 1999;173(4):1123-1126.
- Kivlan BR, Martin RL, Christoforetti JJ, et al. The patient acceptable symptomatic state of the 12-item International Hip Outcome Tool at 1-year follow-up of hip-preservation surgery. *Arthroscopy*. 2019;35(5):1457-1462.
- Lall AC, Saadat AA, Battaglia MR, Maldonado DR, Perets I, Domb BG. Perineal pressure during hip arthroscopy is reduced by use of Trendelenburg: a prospective study with randomized order of positioning. *Clin Orthop Relat Res*. 2019;477(8):1851-1857.



28. Lall AC, Schwarzman GR, Battaglia MR, Chen SL, Maldonado DR, Domb BG. Greater trochanteric pain syndrome: an intraoperative endoscopic classification system with pearls to surgical techniques and rehabilitation protocols. *Arthrosc Tech*. 2019;8(8):e889-e903.
29. Lequesne M, Mathieu P, Vuillemin-Bodaghi V, Bard H, Djian P. Gluteal tendinopathy in refractory greater trochanter pain syndrome: diagnostic value of two clinical tests. *Arthritis Rheum*. 2008;59(2):241-246.
30. Lindner D, Shohat N, Botser I, Agar G, Domb BG. Clinical presentation and imaging results of patients with symptomatic gluteus medius tears. *J Hip Preserv Surg*. 2015;2(3):310-315.
31. Long SS, Surrey DE, Nazarian LN. Sonography of greater trochanteric pain syndrome and the rarity of primary bursitis. *AJR Am J Roentgenol*. 2013;201(5):1083-1086.
32. Makridis KG, Lequesne M, Bard H, Djian P. Clinical and MRI results in 67 patients operated for gluteus medius and minimus tendon tears with a median follow-up of 4.6 years. *Orthop Traumatol Surg Res*. 2014;100(8):849-853.
33. Maldonado DR, Chen JW, Walker-Santiago R, et al. Forget the greater trochanter! Hip joint access with the 12 o'clock portal in hip arthroscopy. *Arthrosc Tech*. 2019;8(6):e575-e584.
34. Nawabi DH, Wentzel C, Ranawat AS, Bedi A, Kelly BT. A comparison of open and endoscopic repair of full-thickness tears of the gluteus medius tendon at a minimum of 2 years follow-up. *Orthop J Sports Med*. 2015;3(7 suppl 2):2325967115S00088.
35. Nissen KI. The Judet arthroplasty of the hip via Gibson's lateral approach. *Postgrad Med J*. 1952;28(321):412-423.
36. Perets I, Mansor Y, Yuen LC, Chen AW, Chaharbakshi EO, Domb BG. Endoscopic gluteus medius repair with concomitant arthroscopy for labral tears: a case series with minimum 5-year outcomes. *Arthroscopy*. 2017;33(12):2159-2167.
37. Pretell J, Ortega J, García-Rayó R, Resines C. Distal fascia lata lengthening: an alternative surgical technique for recalcitrant trochanteric bursitis. *Int Orthop*. 2009;33(5):1223-1227.
38. Ramírez J, Pomés I, Sobrino-Guijarro B, Pomés J, Sanmartí R, Cañete JD. Ultrasound evaluation of greater trochanter pain syndrome in patients with spondyloarthritis: are there any specific features? *Rheumatol Int*. 2014;34(7):947-952.
39. Redmond JM, Chen AW, Domb BG. Greater trochanteric pain syndrome. *J Am Acad Orthop Surg*. 2016;24(4):231-240.
40. Vanhoutte EK, Faber CG, van Nes SI, et al. Modifying the Medical Research Council grading system through Rasch analyses. *Brain*. 2012;135(5):1639-1649.
41. Voos JE, Shindle MK, Pruett A, Asnis PD, Kelly BT. Endoscopic repair of gluteus medius tendon tears of the hip. *Am J Sports Med*. 2009;37(4):743-747.
42. Walker-Santiago R, Ortiz-Declét V, Maldonado DR, Wojnowski NM, Domb BG. The modified resisted internal rotation test for detection of gluteal tendon tears. *Arthrosc Tech*. 2019;8(3):e331-e334.
43. Walsh MJ, Walton JR, Walsh NA. Surgical repair of the gluteal tendons: a report of 72 cases. *J Arthroplasty*. 2011;26(8):1514-1519.