

Surgical and radiological outcomes after posterior vertebral column resection according to the surgeon's experience

Byoung Hun Lee, MD^a, Seung-Jae Hyun, MD, PhD^{a,*}, Sanghyun Han, MD^a, Ki-Jeong Kim, MD, PhD^a, Tae-Ahn Jahng, MD, PhD^a, Yongjung J. Kim, MD^b, Hyun-Jib Kim, MD, PhD^a

Abstract

The purpose of this study was to estimate and analyze the radiological, surgical, and clinical results of posterior vertebral column resection (PVCR) according to the surgeon's experience. Although PVCR has been recognized as the most powerful surgical technique to correct severe spinal deformity, PVCR is a technically demanding procedure with a high complication rate. A retrospective review of the chart and radiographic data of 34 consecutive patients who received PVCR was carried out. According to the time period, the former and latter 17 patients were divided into group 1 and group 2, respectively. Patients' demographics, surgical, radiological/clinical outcomes, and complications were compared between the groups. The demographic data of the patients had no significant difference between the groups. The surgical time (492.5 ± 164.8 vs 350.5 ± 133.9 minutes, $P = .010$), estimated blood loss (1294.1 ± 711.9 vs 974.1 ± 905.9 mL, $P = .045$), and length of hospital stay (22.8 ± 12.9 vs 13.4 ± 3.9 days, $P = .017$) were significantly reduced in group 2. The correction of the PVCR site ($40.5^\circ \pm 13.3^\circ$ vs $41.2^\circ \pm 23.7^\circ$, $P = .909$), sagittal vertical axis (SVA, 81.9 ± 7.2 mm vs 77.9 ± 102.0 mm, $P = .904$) were not different between the groups. The total number of complications (22 vs 10, $P = .031$) and patients having complications (13 vs 7, $P = .039$) were lower in group 2. Additional surgery was significantly lower in group 2 (13 vs 3, $P = .007$). The clinical outcomes by revised Scoliosis Research Society-22 (SRS-22r) questionnaire were not different between the groups. Our series revealed that the complications after PVCR may reduce from 17 cases and surgical outcomes might be stabilized by 29 cases.

Abbreviations: CUSUM = cumulative sum, EBL = estimated blood loss volume, LL = lumbar lordosis, PVCR = posterior vertebral column resection, RBC = red blood cell, SRS-22r = revised Scoliosis Research Society-22, SVA = sagittal vertical axis, VCR = vertebral column resection.

Keywords: complication, experience, learning curve, posterior vertebral column resection

1. Introduction

The severe spinal deformity is a disease which has a huge effect on general health and cosmetic appearance. In most cases, corrective surgeries are inevitable for the treatment of the disease. The surgical goals are to achieve a coronal and sagittal balance, to stop the deformity progression, and to improve dissatisfaction of self-image.^[1] The vertebral column resection (VCR) has been

used as the powerful surgical technique to get spinal balance and deformity correction for severe spinal deformities.^[2,3] The conventional VCR procedure was performed with the anterior and posterior approach. However, the combined anterior and posterior VCR (PVCR) is a challenging technique for both the surgeons and patients because of having a high risk of major complications.^[1,4,5] To alleviate the difficulty of conventional VCR, Suk et al firstly reported the posterior only VCR, and several researchers published successful results of the PVCR.^[6-8] Although PVCR is a surgically demanding procedure with a high potential neurological complication, it has been recognized as a reasonable and powerful method when performed adequately with intraoperative neurophysiologic monitoring by an experienced surgeon.^[9] However, the inexperienced surgeons need to understand the learning curve of the challenging procedure, PVCR. In previous literatures, there were not a few reports about the learning curve for various spine surgeries.^[10-13] The learning curve of PVCR according to the surgeon's experience has not been previously investigated. The purpose of this study was to analyze the radiologic, surgical, and clinical results of PVCR according to a surgeon's experience and estimate learning curve of PVCR.

2. Materials and methods

This study was approved by the institutional review board of our institution. A retrospective review of the chart and radiographic

Editor: Danny Chu.

The authors have no funding and conflicts of interest to disclose.

^a Department of Neurosurgery, Spine Center, Seoul National University Bundang Hospital, Seoul National University College of Medicine, Seongnam, Republic of Korea, ^b Department of Orthopaedic Surgery, Spine Service, Columbia University College of Physicians and Surgeons, NY, USA.

* Correspondence: Seung-Jae Hyun, Department of Neurosurgery, Spine Center, Seoul National University Bundang Hospital, Seoul National University College of Medicine, 82, Gumi-ro 173 Beon-Gil, Bundang, Seongnam, 463-707 Gyeonggi, Republic of Korea (e-mail: hyunsj@snu.ac.kr).

Copyright © 2018 the Author(s). Published by Wolters Kluwer Health, Inc. This is an open access article distributed under the terms of the Creative Commons Attribution-Non Commercial License 4.0 (CCBY-NC), where it is permissible to download, share, remix, transform, and buildup the work provided it is properly cited. The work cannot be used commercially without permission from the journal.

Medicine (2018) 97:34(e11660)

Received: 19 February 2018 / Accepted: 3 July 2018

<http://dx.doi.org/10.1097/MD.00000000000011660>

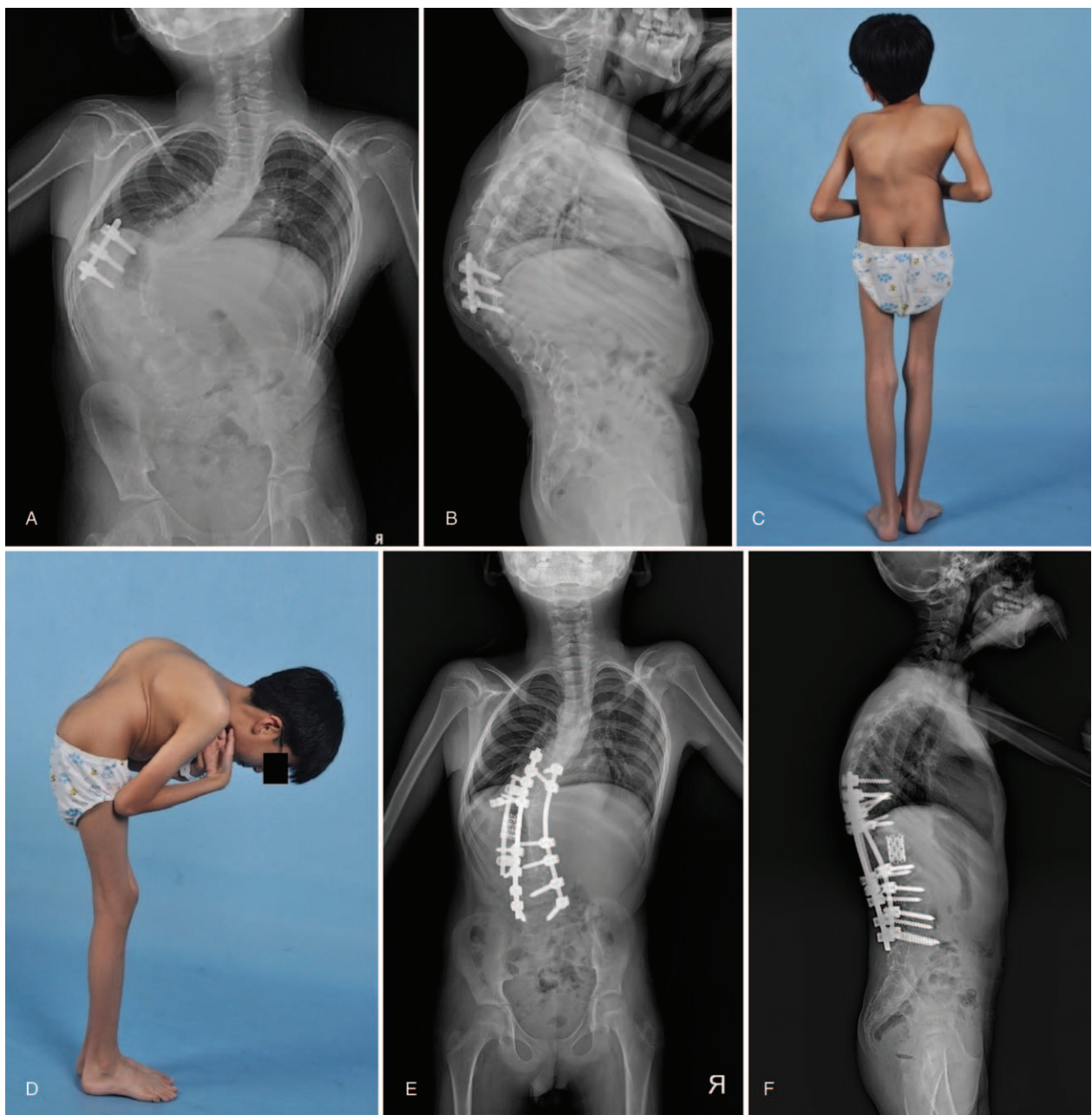


Figure 1. An 11-year-old boy with prior arthrodesis at T11-L1 has severe kyphoscoliosis of more than 100° at preoperative radiographs (A and B) and the left side rib hump at preoperative clinical pictures (C and D). The patient had the operation of posterior vertebral column resection (PVCR) at T11-L1 and posterior arthrodesis from T8 to L5 with multiple rods construct. The coronal and sagittal alignment well corrected on the radiographs (E and F) and clinical pictures (G and H) 6 months after surgery.

data of 34 consecutive patients who underwent PVCR by a single spine surgeon in a single academic institution between December 2010 and October 2016 was performed. All patients received informed written consent about the surgical procedure. The inclusion criteria were a severe fixed deformity, sharp angular deformities, and 3-dimensional multiplanar deformities such as postfusion flat back deformity, posttraumatic kyphosis, post-tuberculosis kyphosis, and congenital kyphoscoliosis. Those who met any of spinal infection, tumor, and a combined anterior-posterior VCR surgery were excluded. Since the index surgeon had performed the PVCR for the first time, the former and latter 17 patients were divided into 2 cohorts (group 1, $n=17$ and

group 2, $n=17$, respectively). To reduce the bias due to differences in the number of control groups, the groups were divided into 2 with the same number. The change point was confirmed by cumulative sum (CUSUM) analysis of total number. Comparative analysis between the groups was performed regarding demographic, operative, radiological, and clinical outcomes. The postfusion flat back deformity ($n=16$), posttraumatic kyphosis ($n=8$), posttuberculosis kyphosis ($n=7$), and congenital kyphoscoliosis ($n=3$) (Fig. 1) were enrolled in this study. The patients included 23 females and 11 males with a median age of 61.2 ± 20.8 years (range, 6–82 years). Their average follow-up period was a mean 25.4 ± 13.0 months

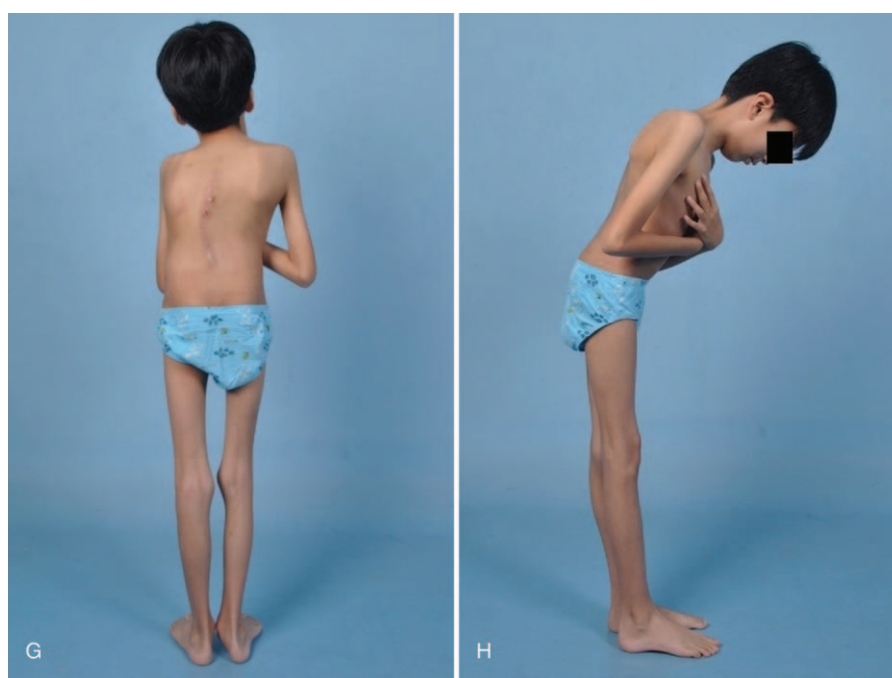


Figure 1. (Continued)

(range, 9–78 months) after surgery. Eighteen patients had received prior spinal operation. The total PVCR segments were 46 levels, which included 22 levels of thoracic vertebrae and 24 levels of lumbar vertebrae. The average fused vertebrae were 9.3 ± 3.9 (range, 4–17) (Table 1).

2.1. Radiological analysis

The radiological evaluation was made pre-operative, immediately after surgery, and at the most recent follow-up by long-cassette (14×36 inches) posterior–anterior and lateral standing plain radiographs. The Cobb angle on the radiographs was measured for angular parameter change. The radiographic assessment included a sagittal vertical axis (SVA), coronal angle (main curve), thoracic kyphosis, lumbar lordosis (LL), and kyphotic angle of PVCR levels. The horizontal distance from the posterior–superior corner of S1 endplate to the C7 plumb line on standing whole spine lateral radiographs was used for SVA. The coronal angle is a magnitude of main curve on PVCR site that measured by the Cobb method. Thoracic kyphosis is determined the angle from the superior endplate of T5 to the inferior endplate of T12. LL has defined the angle between the superior endplate of L1 and the superior endplate of S1. The kyphosis angle of PVCR levels was measured from the superior endplate of the first upper vertebra at the PVCR to the inferior endplate of the first lower vertebra at the PVCR.

2.2. Clinical evaluation

The demographic data as age, gender, prior operation, PVCR segment, and fused segment number were collected from retrospective chart review of the patients. The operative data including surgical time, estimated blood loss volume (EBL), the volume of transfused red blood cell (RBC), and length of hospital stay were investigated. According to onset time, the complications

were separated into 3 categories (intraoperative, perioperative <2 weeks and late-onset ≥ 2 weeks). The clinical outcomes were measured by revised Scoliosis Research Society-22 (SRS-22r) questionnaire that regularly surveyed (preoperative, 6 weeks after surgery, 1 year, 2 years, and so forth). After obtaining these data, the comparison was made between the 2 groups.

2.3. Statistical analysis

Statistical analysis was carried out with SPSS Statistics 22.0 (IBM Corp, Armonk, NY). Student *t* test was used to estimate the change of radiologic data by comparison of the Cobb angle before and after surgery. The Mann–Whitney *U* test was selected for the analysis of different categorical variables. The operative data were analyzed to assess the effect of the chronology of the

Table 1

Demographic data.

	All patients (n=34)	Group 1 (n=17)	Group 2 (n=17)	P
Age, yr	61.2 ± 20.8	61.4 ± 19.3	60.9 ± 22.7	.949
Male/female	11/23	5/11	6/12	.714
Etiology of deformity				.180
Postfusion flatback deformity	16	9	7	
Posttraumatic kyphosis	8	4	4	
Posttuberculosis kyphosis	7	2	5	
Congenital kyphoscoliosis	3	2	1	
Prior operation, (%)	18 (52.9%)	10 (58.8%)	8 (47.1%)	.169
Number of fused segment	9.3 ± 3.9	9.7 ± 3.7	8.9 ± 4.1	.542
Number of PVCR segment	46	19	27	.179
Thoracic	22	8	14	
Lumbar	24	11	13	

PVCR = posterior vertebral column resection.

Table 2
Radiographic data.

	All patients	Group 1 (n=17)	Group 2 (n=17)	P
Pelvic incidence, °	52.1 ± 11.3	55.1 ± 12.3	49.1 ± 9.5	.123
Thoracic kyphosis, °				
Preoperative	26.1 ± 28.5	32.9 ± 26.3	19.3 ± 29.8	.168
Postoperative	28.8 ± 16.6	34.1 ± 19.8	26.9 ± 20.6	.521
Ultimate follow-up	33.1 ± 19.4	34.1 ± 19.9	32.1 ± 19.4	.771
Correction	17.5 ± 15.2	20.8 ± 11.8	14.1 ± 17.7	.208
Loss of correction	-7.9 ± 7.5	-9.4 ± 9.0	-6.5 ± 5.5	.255
Lumbar lordosis, °				
Preoperative	-20.6 ± 39.2	-27.4 ± 30.4	-13.8 ± 46.3	.317
Postoperative	-45.1 ± 24.7	-52.3 ± 17.0	-37.8 ± 29.2	.086
Ultimate follow-up	-38.2 ± 28.5	-45.2 ± 22.2	-31.1 ± 32.8	.153
Correction	33.1 ± 27.4	32.1 ± 26.8	34.2 ± 28.7	.833
Loss of correction	-7.6 ± 8.9	-5.2 ± 5.1	-9.9 ± 11.3	.124
Sagittal vertical axis, mm				
Preoperative	102.3 ± 87.8	97.6 ± 80.5	107.0 ± 96.7	.760
Postoperative	23.8 ± 46.5	15.7 ± 51.3	31.9 ± 41.3	.317
Ultimate follow-up	48.6 ± 57.8	37.2 ± 41.9	59.9 ± 69.6	.258
Correction	79.9 ± 93.5	81.9 ± 87.2	77.9 ± 102.0	.904
Loss of correction	-20.3 ± 43.8	-15.3 ± 31.4	-25.3 ± 54.1	.519
Coronal angle, °				
Preoperative	14.4 ± 19.8	17.7 ± 26.8	11.1 ± 7.8	.060
Postoperative	3.2 ± 7.2	4.5 ± 10.0	1.9 ± 1.3	.074
Ultimate follow-up	3.8 ± 10.6	5.6 ± 14.9	1.9 ± 1.5	.066
Correction	11.2 ± 13.9	13.2 ± 18.4	9.1 ± 7.2	.062
Loss of correction	-0.7 ± 3.6	-1.3 ± 5.0	-0.1 ± 1.1	.129
Angle at the PVCR site, °				
Preoperative	40.8 ± 30.2	38.9 ± 27.8	42.7 ± 33.2	.715
Postoperative	-0.0 ± 29.3	-1.5 ± 22.9	1.4 ± 35.2	.769
Ultimate follow-up	3.1 ± 29.6	0.3 ± 20.8	5.8 ± 36.9	.600
Correction	40.9 ± 18.9	40.5 ± 13.3	41.2 ± 23.7	.909
Loss of correction	-3.1 ± 3.0	-2.9 ± 2.8	-3.3 ± 6.3	.428

PVCR=posterior vertebral column resection.

PVCR with linear regression analysis and CUSUM. The *P*-value <0.05 considered as the statistical significance.

3. Results

The demographic data of patients such as age, sex, etiology of deformity, number of fused segments, number of PVCR segment, and prior operation was not significantly different between the 2 groups (Table 1). The proportion of patients having prior spine surgery was 58.8% in group 1 and 47.1% in group 2, respectively (*P* = .169). A number of PVCR segment was 19 in group 1 and 27 in group 2, respectively (*P* = .179). Although there was no significant difference between the groups, patients of multilevel PVCR was more frequent in the group 2 (2 vs 4, *P* = .375). There was no difference in the number of fused segments between the groups. (9.7 ± 3.7 vs 8.9 ± 4.1, *P* = .542).

3.1. Radiological results

There was no significant difference of radiological parameters between the groups. The average correction angle of PVCR site was 40.5° ± 13.3° and 41.2° ± 23.7° in group 1 and group 2, respectively. However, the difference has no statistical significance (*P* = .909). The amount of correction of SVA (group 1: 81.9 ± 7.2 and group 2: 77.9 ± 102.0 mm, *P* = .904) and LL (32.1° ± 26.8° vs 34.2° ± 28.7°, *P* = .833) was not difference between the

Table 3
Operative characteristics.

	All Patients (n=34)	Group 1 (n=17)	Group 2 (n=17)	P
Surgical time, min	421.5 ± 164.5	492.5 ± 164.8	350.5 ± 133.9	.010*
Estimated blood loss, mL	1134.1 ± 818.5	1294.1 ± 711.9	974.1 ± 905.9	.045*
Volume of transfused RBC, mL	1081.7 ± 1097.8	1278.7 ± 1167.4	884.7 ± 1019.9	.220
Length of hospital stay, d	17.9 ± 10.9	22.8 ± 12.9	13.4 ± 3.9	.017*

RBC=red blood cell.
*Means statistical significance.

groups. There showed no significant differences in correction of coronal angle between the groups (13.2 ± 18.4 vs 9.1 ± 7.2, *P* = .062) (Table 2).

3.2. Surgical results

The average surgical time was significantly diminished from 492.5 ± 164.8 to 350.5 ± 133.9 minutes (*P* = .010) in group 2. Similarly, EBL significantly decreased from 1294.1 ± 711.9 to 974.1 ± 905.9 mL (*P* = .045) and volume of transfused RBC also decreased from 1278.7 ± 1167.4 to 884.7 ± 1019.9 mL (*P* = .220) in group 2. The length of hospital stay was significantly shorter in group 2 (13.4 ± 3.9 days) than in group 1 (22.8 ± 12.9 days, *P* = .017). The surgical outcomes are presented in Table 3.

3.3. Clinical results

The clinical outcomes by SRS-22r questionnaire significantly improved from 2.5 ± 0.8 to 3.3 ± 0.8 at the final follow-up (*P* = .000). In each group, the SRS-22r score was increased after surgery (group 1: from 2.4 ± 0.9 to 3.1 ± 0.8, *P* = .076, group 2: from 2.6 ± 0.8 to 3.7 ± 0.3, *P* = .027). However, the SRS-22r score was not different the groups (preoperative: 2.4 ± 0.9 vs 2.6 ± 0.8, *P* = .798, ultimate follow-up: 3.1 ± 0.8 vs 3.7 ± 0.3, *P* = .117, group 1 vs group 2, respectively) (Table 4).

3.4. Complications

Twelve (35.3%) out of the 34 patients experienced 16 additional operations owing to surgery-related complications. In group 1, there were significantly more reoperation cases compared to group 2 (13 vs 3, *P* = .007). A total of 32 complications occurred in 20 (58.8%) patients. Among them, 2 patients (5.9%) experienced transient neurological deficit after PVCR. Total number of complications was significantly lower in group 2 (22 vs 10, *P* = .031). The complications were divided into the 3 parts

Table 4
Summary of clinical outcomes.

	All patients	Group 1 (n=17)	Group 2 (n=17)	P
SRS-22r scores				
Preoperative	2.5 ± 0.8	2.4 ± 0.9	2.6 ± 0.8	.798
Ultimate follow-up	3.3 ± 0.8	3.1 ± 0.8	3.7 ± 0.3	.117

A higher score implies less pathology, and a lower score implies more pathology. SRS-22r=revised Scoliosis Research Society-22.

Table 5
Summary of complications.

	All patients	Group 1 (n=17)	Group 2 (n=17)	P
No of patients	20 (58.8%)	13 (76.5%)	7 (41.2%)	.039*
No of complications				
Intraoperative	4	1	3	.633
Perioperative (<2 wk)	17	13	4	.029*
Late-onset (≥2 wk)	11	8	3	.071
Total	32	22	10	.031*
Additional operation	16	13	3	.007*

No means number.
* Means statistical significance.

according to the time of onset. In particular, perioperative ($P=.029$) and late-onset ($P=.071$) complications reduced in group 2 (Table 5).

3.4.1. Intraoperative complications. There were 4 cases of intraoperative complication (1 and 3 cases in group 1 and group 2, respectively). The 1 excessive bleeding (>3000 mL) case during

surgery was occurred in each group. Two dura tear cases were presented in group 2 which underwent primary closure without additional leakage of cerebrospinal fluid.

3.4.2. Perioperative complications. The 17 cases of complication occurred in the perioperative period (13 and 4 cases in group 1 and 2, respectively). Two patients had transient neurological deficits after surgery in group 1. There were 3 patients of wound dehiscence (2 cases in group 1 and 1 case in group 2). Screw malposition (2 cases) and neural compression by the bone fragment occurred in group 1. One case of delayed cerebrospinal fluid leakage, pneumonia, and delirium was reported in each group. A patient experienced deterioration of pre-existing cervical myelopathy after PVCR surgery. The urinary tract infection and fecal incontinence were presented in group 1.

3.4.3. Late-onset complications. There were 11 cases of complication in the late-onset group (8 cases in group 1 and 3 cases in group 2). Five cases suffered a compression fracture of the adjacent segment during the follow-up. Among them, 3 developed at upper instrumented vertebra and the remaining 2 at lower instrumented vertebra. Two cases of superficial surgical site

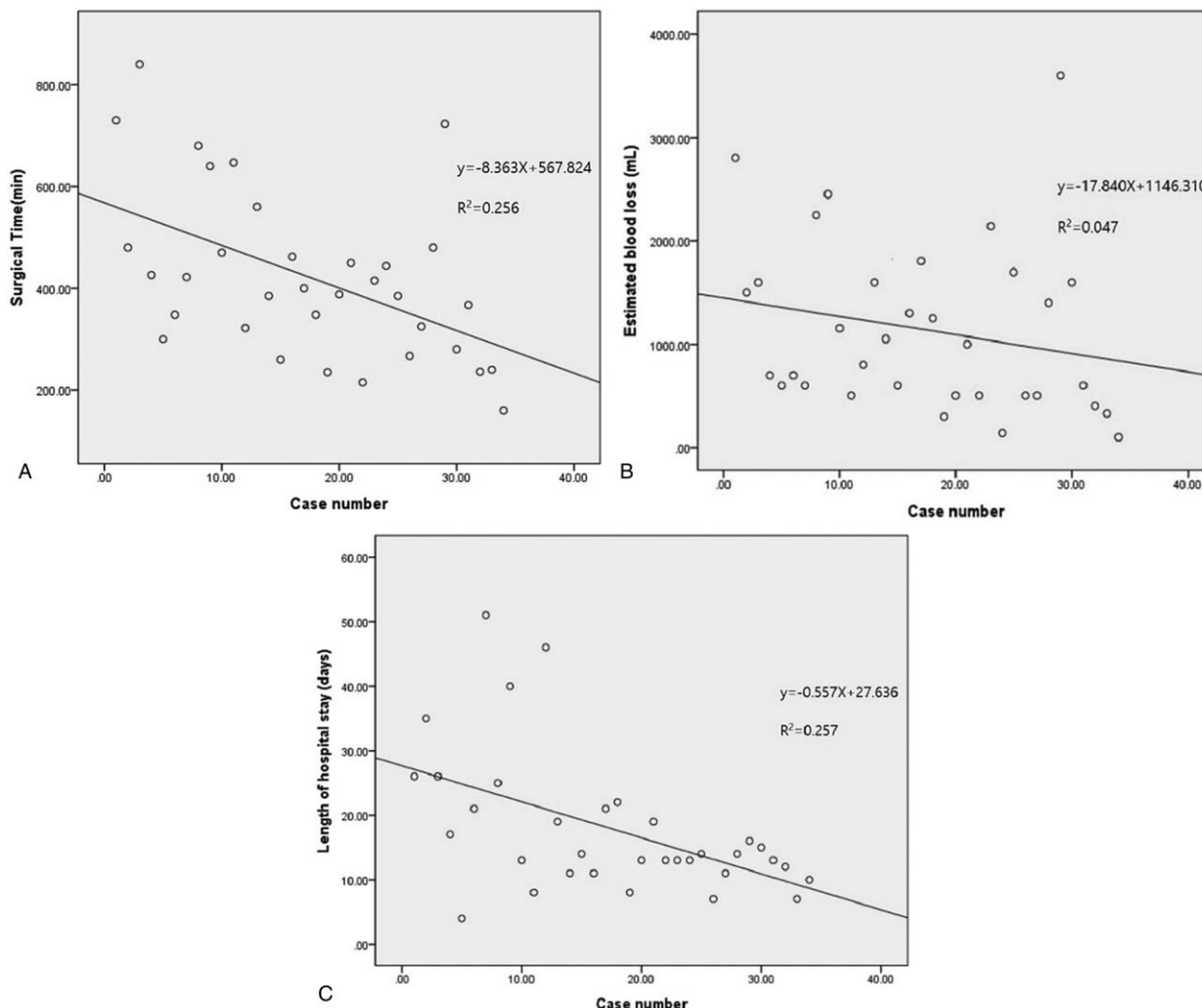


Figure 2. (A) The learning curve shows the correlation between the surgical time (minutes) and surgeon's experience. (B) The estimated blood loss (mL), (C) the length of hospital stay (days).

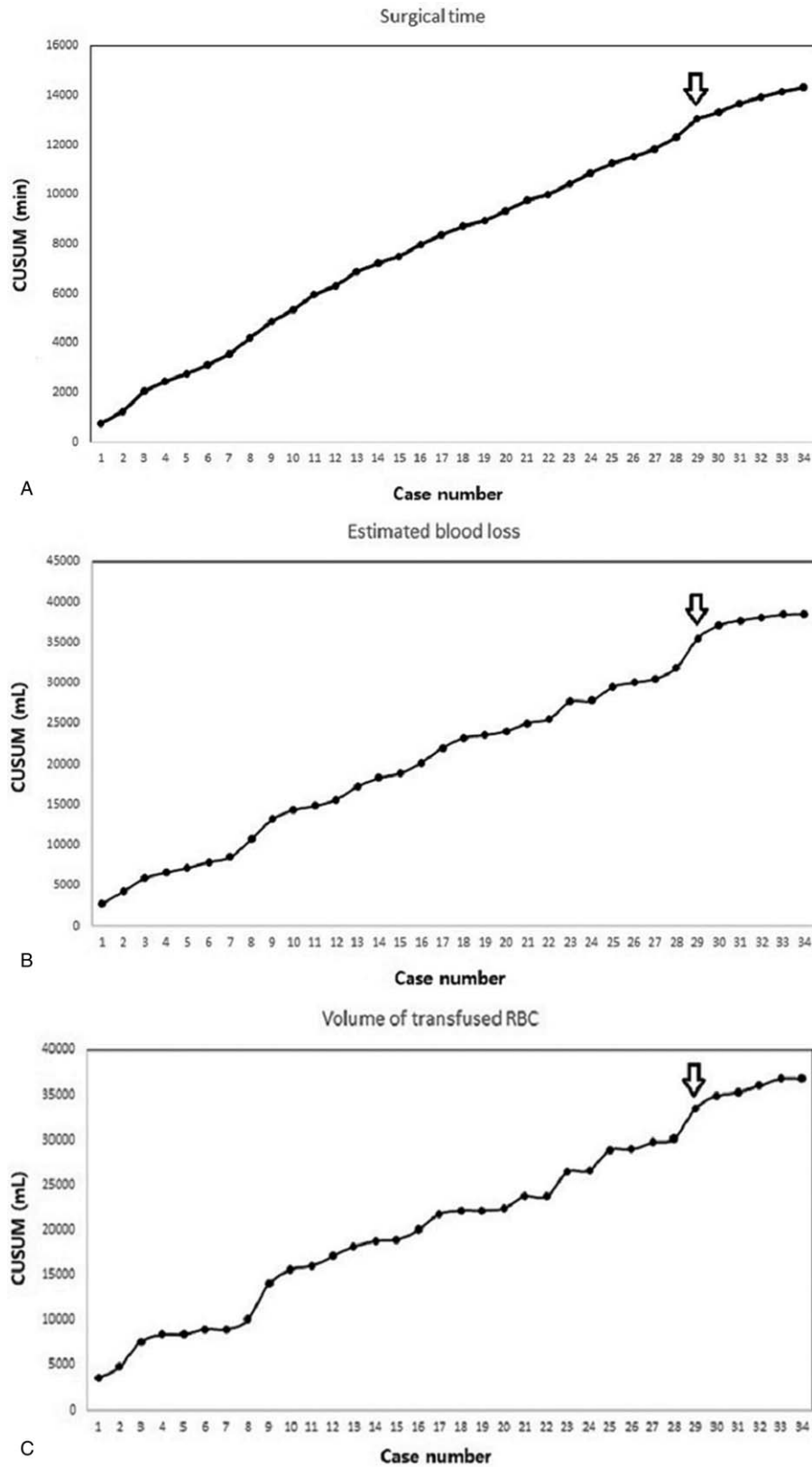


Figure 3. The learning curve analysis with CUSUM shows the plateau change (arrow) in the 29th patient at (A) surgical time, (B) EBL, and (C) volume of transfused RBC. CUSUM=cumulative sum, EBL=estimated blood loss volume, RBC=red blood cell.

infection were identified in group 1. There was each 1 case of proximal junctional kyphosis and distal junctional kyphosis. Remnant curve progression developed as thoracic decompensation in a patient who had a connective tissue disease of Loeys-Dietz syndrome.

3.5. Learning curve

Based on the surgeon's surgical experience, the 34 patients were retrospectively reviewed to assess learning curve over time. Surgical time, EBL, and length of hospital stay were inverse relationships by the number of cases accumulated (Fig. 2). The surgical time ($P=.010$), EBL ($P=.045$), and length of hospital stay ($P=.017$) showed significant negative correlation with surgeon's experience. The CUSUM revealed a plateau status between the overall case and clinical outcome by the 29th patient in terms of surgical time, EBL, and volume of transfused RBC (Fig. 3).

4. Discussion

There are several reports focused on learning curve of various spinal surgery that endoscopic surgery, minimally invasive surgery, transforaminal interbody fusion, and anterior cervical discectomy and fusion.^[10,12-14] However, the learning curve of PVCR has not been demonstrated in previous literatures. In this study, we divided 34 consecutive patients who received PVCR into 2 groups by surgeon's experience and performed a comparative analysis between the groups to assess learning curve. There was a significant decrease in surgical time, EBL, and length of hospital stay in the latter group compared to the earlier group. The surgical time, EBL, and length of hospital stay were decreased by 28.8% (142.0 minutes), 24.7% (320.0 mL), and 41.2% (9.4 days), respectively. There is an inverse correlation between clinical outcomes (surgical time, EBL, and hospital stay) and case number. Ahn et al described the reduction of surgical time and hospital stay were attained as a surgeon's experience increase in minimally invasive surgery.^[10] In several literatures, the reduction of EBL is also a factor in determining the learning curve.^[11,15,16] Moreover, the volume of transfused RBC were decreased by 30.8% (394.0 mL) in the current study. However, the difference was not statistically significant in our study. There were some cases with a large amount of transfusion in each group, and the standard deviation between the results was increased. For this reason, it is considered that there is no statistical difference of transfusion between the initial and latter period, even though the mean value of the transfusion was reduced according to the increase of experience. We tried to confirm the point to plateau the surgical outcomes by clinical cumulative result analysis. This is thought to be the time point when the surgeon enters the stage of stabilizing the surgical outcome in the learning curve. Previous researcher explained the learning curve of microendoscopic lumbar discectomy through the operative time, blood loss, and prevalence of complications.^[17] The incidence of complications after VCR was reported from 40% to 67%.^[18,19] In the present study, the overall complication rate was 58.8% (20 of 34 patients), and prevalence of transient neurological complication was 5.9% (2 of 34 patients). Previous investigators reported that the incidence of neurological problem was from 1.2% to 17.1%.^[8,20-23] In our series, the neurological complication occurred only in group 1, which followed unexpected additional operation in all of the cases. In group 1, the additional operation was significantly more

than group 2 (13 and 3 cases, $P=.007$). In the subgroup analysis, the perioperative complications were significantly lower and late-onset complications showed a decreasing trend in group 2. Concordant to our findings, Choi et al reported that the surgical complications are reduced as experience increases in pedicle subtraction osteotomy surgery.^[11] In both groups, the clinical outcomes were significantly improved after PVCR by the SRS-22r questionnaire. However, there was no difference between the groups. It suggests that there is no superiority in the clinical outcome as the case number increases.^[15,16]

The corrected value of PVCR, LL, coronal angle, and SVA had no significant difference in the radiological results. We suggest that PVCR can achieve the desired angle compared to other corrective technique because PVCR removes the 3 columns of the vertebral body and adjacent intervertebral discs. Therefore, the desired angle could be obtained in the earlier and latter period, which seems to be no difference between the groups. The reduction in complications, decrease of surgical time, EBL, and shortening of hospital stay in group 2 indicates that PVCR was performed more safely as experience gained. Although the PVCR was the most powerful method for the correction of severe deformity, the technical difficulties were enormous and the risks were high. It should be cautiously carried out by the highly experienced spine surgeons. Therefore, it is important to recognize learning curve of PVCR in spine surgeon. According to our study, we suggest that a spine surgeon can consider reasonable results that complications are reduced after 17 surgical cases, and can recognize stabilization of the surgical outcomes by 29 cases. In our study, the possible limitation was the retrospective nature of this study. Second, there is a limit to generalize, because of the PVCR carried out by a single surgeon at a single institution. Third, the relatively small number of enrolled cases was another weakness. In the learning curve according to time, we were able to observe changes in the plateau, but more cases are needed to see clear trends. There may also be a selection bias due to a small case number. Fourth, there is also a lack of objective assessment of whether the surgeon grows if the complication is reduced to some extent. To overcome these issues in the future, a prospective multicenter study of a large sample is needed. However, it is meaningful that we tried to establish objective criteria about how many cases should be undergone to perform PVCR surgery safely.

5. Conclusions

The PVCR is still a surgically demanding procedure with a high risk of complications. The surgical complications are reduced as experience increases. As the case accumulated, the spine surgeon could perform PVCR more safely. Our series revealed that the complications after PVCR may reduce from 17 cases and surgical outcomes might be stabilized by 29 cases.

Acknowledgments

The manuscript submitted does not contain information about the medical device(s)/drug(s).

Author contributions

Conceptualization: Seung-Jae Hyun.
Data curation: Byoung Hun Lee.
Formal analysis: Byoung Hun Lee.
Investigation: Byoung Hun Lee.

Methodology: Byoung Hun Lee.

Supervision: Seung-Jae Hyun, Sanghyun Han, Ki-Jeong Kim, Tae-Ahn Jahng, Yongjung J. Kim, Hyun-Jib Kim.

Writing – original draft: Byoung Hun Lee.

Writing – review & editing: Seung-Jae Hyun.

References

- [1] Yang C, Zheng Z, Liu H, et al. Posterior vertebral column resection in spinal deformity: a systematic review. *Eur Spine J* 2016;25:2368–75.
- [2] Herbert DJ-J. Vertebral osteotomy: technique, indications, and results. *JBJS* 1948;30:680–9.
- [3] Leatherman K, Dickson R. Two-stage corrective surgery for congenital deformities of the spine. *J Bone Joint Surg Br* 1979;61:324–8.
- [4] Boachie-Adjei O, Bradford DS. Vertebral column resection and arthrodesis for complex spinal deformities. *J Spinal Disord* 1991;4:193–202.
- [5] Bradford DS, Tribus CB. Vertebral column resection for the treatment of rigid coronal decompensation. *Spine (Phila Pa 1976)* 1997;22:1590–9.
- [6] Lenke LG, Sides BA, Koester LA, et al. Vertebral column resection for the treatment of severe spinal deformity. *Clin Orthop Relat Res* 2010;468:687–99.
- [7] Ozturk C, Alanay A, Ganiyusufoglu K, et al. Short-term X-ray results of posterior vertebral column resection in severe congenital kyphosis, scoliosis, and kyphoscoliosis. *Spine (Phila Pa 1976)* 2012;37:1054–7.
- [8] Suk S-I, Kim J-H, Kim W-J, et al. Posterior vertebral column resection for severe spinal deformities. *Spine (Phila Pa 1976)* 2002;27:2374–82.
- [9] Enercan M, Ozturk C, Kahraman S, et al. Osteotomies/spinal column resections in adult deformity. *Eur Spine J* 2013;22:254–64.
- [10] Ahn J, Iqbal A, Manning BT, et al. Minimally invasive lumbar decompression—the surgical learning curve. *Spine J* 2016;16:909–16.
- [11] Choi HY, Hyun S-J, Kim K-J, et al. Surgical and radiographic outcomes after pedicle subtraction osteotomy according to surgeon's experience. *Spine (Phila Pa 1976)* 2017;42:E795–801.
- [12] Lee JC, Jang H-D, Shin B-J. Learning curve and clinical outcomes of minimally invasive transforaminal lumbar interbody fusion: our experience in 86 consecutive cases. *Spine (Phila Pa 1976)* 2012;37:1548–57.
- [13] Nandyala SV, Fineberg SJ, Pelton M, et al. Minimally invasive transforaminal lumbar interbody fusion: one surgeon's learning curve. *Spine J* 2014;14:1460–5.
- [14] Ahn S-S, Kim S-H, Kim D-W. Learning curve of percutaneous endoscopic lumbar discectomy based on the period (early vs. late) and technique (in-and-out vs. in-and-out-and-in): a retrospective comparative study. *J Korean Neurosurg Soc* 2015;58:539–46.
- [15] Mayo BC, Massel DH, Bohl DD, et al. Anterior cervical discectomy and fusion: the surgical learning curve. *Spine* 2016;41:1580–5.
- [16] Ryu K, Suh S, Kim H, et al. Quantitative analysis of a spinal surgeon's learning curve for scoliosis surgery. *Bone Joint J* 2016;98:679–85.
- [17] Wang B, Lü G, Patel AA, et al. An evaluation of the learning curve for a complex surgical technique: the full endoscopic interlaminar approach for lumbar disc herniations. *Spine J* 2011;11:122–30.
- [18] Hassanzadeh H, Jain A, El Dafrawy MH, et al. Three-column osteotomies in the treatment of spinal deformity in adult patients 60 years old and older: outcome and complications. *Spine (Phila Pa 1976)* 2013;38:726–31.
- [19] Xie J, Wang Y, Zhao Z, et al. Posterior vertebral column resection for correction of rigid spinal deformity curves greater than 100. *J Neurosurg Spine* 2012;17:540–51.
- [20] Hamzaoglu A, Alanay A, Ozturk C, et al. Posterior vertebral column resection in severe spinal deformities: a total of 102 cases. *Spine (Phila Pa 1976)* 2011;36:E340–4.
- [21] Lenke LG, Newton PO, Sucato DJ, et al. Complications after 147 consecutive vertebral column resections for severe pediatric spinal deformity: a multicenter analysis. *Spine (Phila Pa 1976)* 2013;38:119–32.
- [22] Suk S-I, Chung E-R, Kim J-H, et al. Posterior vertebral column resection for severe rigid scoliosis. *Spine (Phila Pa 1976)* 2005;30:1682–7.
- [23] Zhang B-B, Zhang T, Tao H-R, et al. Neurological complications of thoracic posterior vertebral column resection for severe congenital spinal deformities. *Eur Spine J* 2017;26:1871–7.