

# Endoscopic partial closure followed by adequate drainage for treating delayed perforation caused by duodenal endoscopic submucosal dissection

## A case report

Liansong Ye, MD<sup>a</sup>, Yiping Wang, MD<sup>b</sup>, Wenxiu Hou, MM<sup>c</sup>, Chuncheng Wu, MD<sup>a</sup>, Xianglei Yuan, MM<sup>a</sup>, Naveed Khan, MM<sup>a</sup>, Bing Hu, MD<sup>a,\*</sup>

### Abstract

**Rationale:** Delayed perforation of duodenal endoscopic submucosal dissection (ESD) was reported to be up to 14.3%. High invasive surgery remains the main treatment for delayed duodenal perforation.

**Patient concerns:** A 56-year-old woman presented with abdominal pain and fever at 1st day after ESD for treating a large laterally spreading tumor in the second part of duodenum.

**Diagnosis:** Emergent abdominal computed tomography revealed the presence of duodenal perforation.

**Interventions:** Endoscopic purse-string technique was used to partially close the large mucosal defect. Percutaneous endoscopic gastrostomy was conducted for gastric drainage and proximal drainage of the wound. A nasointestinal decompression tube was placed for distal drainage of the wound.

**Outcomes:** No further symptoms were noted after 5 days. Both upper gastrointestinal series and endoscopy confirmed the healing of the wound.

**Lessons:** Partial closure of the mucosal defect followed by adequate drainage can be selected as a preferred choice for management of delayed duodenal perforation. It may also serve as an alternative for prevention of delayed perforation when complete closure of the mucosal defect is technically difficult or impossible.

**Abbreviations:** CT = computed tomography, ER = endoscopic resection, ESD = endoscopic submucosal dissection, PEG = percutaneous endoscopic gastrostomy.

**Keywords:** delayed perforation, drainage, duodenal endoscopic submucosal dissection, percutaneous endoscopic gastrostomy, suture

## 1. Introduction

Recently, duodenal endoscopic resection (ER) including endoscopic mucosal resection and endoscopic submucosal dissection (ESD) is one of the main methods for management of superficial

lesions, which avoids the high invasive pancreaticoduodenectomy. Despite ER is micro-invasive, complications like delayed perforation could occur, especially in ESD cases.<sup>[1-3]</sup> Previous studies suggested that complete closure of the mucosal defect helps to prevent delayed perforation,<sup>[1,4]</sup> however, it could be technically impossible in some cases with large mucosal defect.<sup>[1]</sup> Partial closure helps to narrow the defect, but without improvement in reducing delayed complications.<sup>[1]</sup> Herein, we reported a case of delayed perforation of ESD in the second part of duodenum, in which endoscopic partial closure followed by adequate drainage was successful for wound healing. This technique may also serve as an alternative for prevention of delayed perforation in selected patients.

## 2. Case presentation

Our case report is a retrospective and descriptive analysis. Informed written consent was obtained from the patient for publication of this case report and accompanying images.

A 56-year-old woman underwent ESD for management of a large laterally spreading tumor in the opposite duodenal wall of papilla, that involved about 3 quarters of the circumference (Fig. 1A). With the help of magnetic bead-traction (Fig. 1B), a method developed to facilitate ESD,<sup>[5,6]</sup> the procedure went

Editor: N/A.

Funding support was provided by the National Natural Science Foundation of China (81570472).

All authors disclose no conflicts relevant to this article.

<sup>a</sup> Department of Gastroenterology, West China Hospital, Sichuan University, Chengdu, Sichuan, <sup>b</sup> Department of Gastroenterology, Affiliated Cixi Hospital, Wenzhou Medical University, Ningbo, Zhejiang, <sup>c</sup> Department of Nuclear Medicine, West China Hospital, Sichuan University, Chengdu, Sichuan, China.

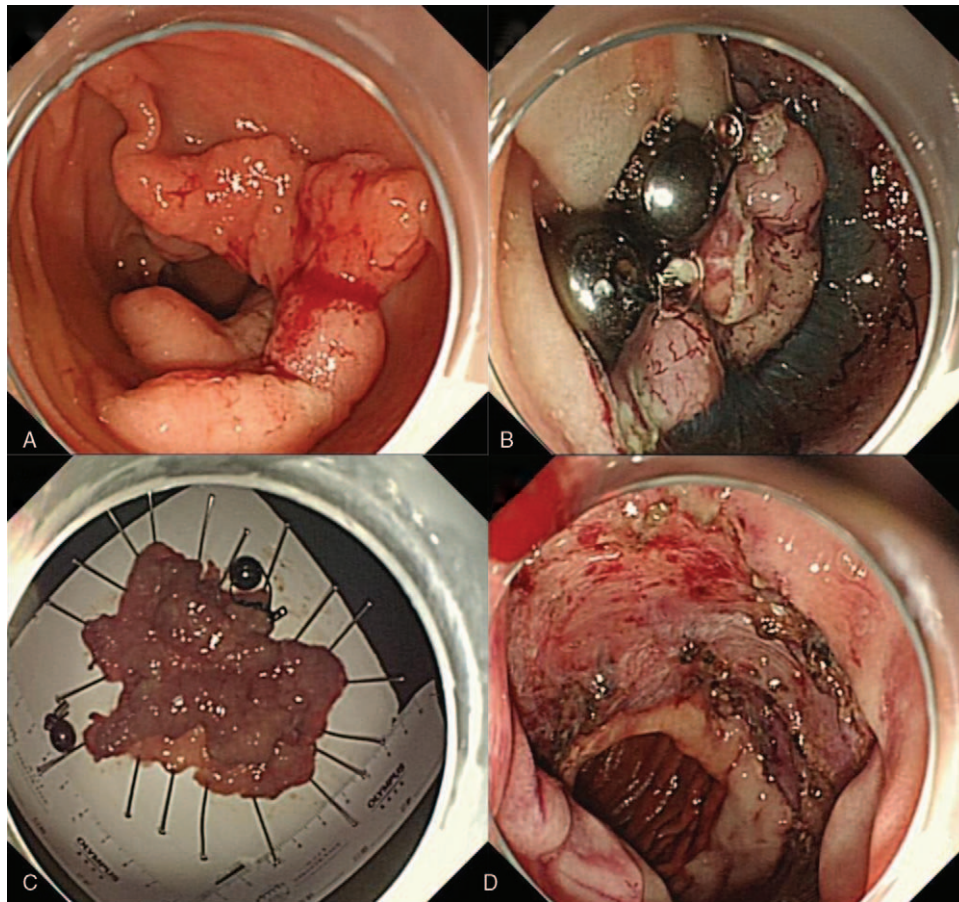
\* Correspondence: Bing Hu, No. 37 Guo Xue Alley, Wu Hou District, Chengdu City, Sichuan Province 610041, China (e-mail: hubingnj@163.com).

Copyright © 2019 the Author(s). Published by Wolters Kluwer Health, Inc. This is an open access article distributed under the terms of the Creative Commons Attribution-Non Commercial License 4.0 (CCBY-NC), where it is permissible to download, share, remix, transform, and buildup the work provided it is properly cited. The work cannot be used commercially without permission from the journal.

Medicine (2019) 98:22(e15883)

Received: 4 January 2019 / Received in final form: 22 April 2019 / Accepted: 9 May 2019

<http://dx.doi.org/10.1097/MD.00000000000015883>



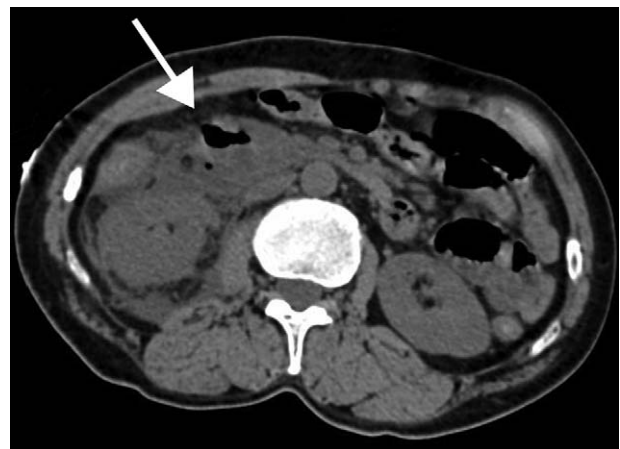**Figure 1.** (A) The large laterally spreading tumor located in the second part of duodenum. (B) The submucosal layer and cutting line were clearly exposed after application of 2 magnetic bead systems. (C) En bloc resection of the tumor was achieved. (D) The mucosal defect was left without closure.

smoothly and en bloc resection of the large tumor was achieved finally (Fig. 1C). Because of the difficulty in closing the large mucosal defect and no obvious damage to muscularis during the procedure, the mucosal defect was left without closure (Fig. 1D). Pathologic results demonstrated that the tumor of intramucosal carcinoma was resected curatively.

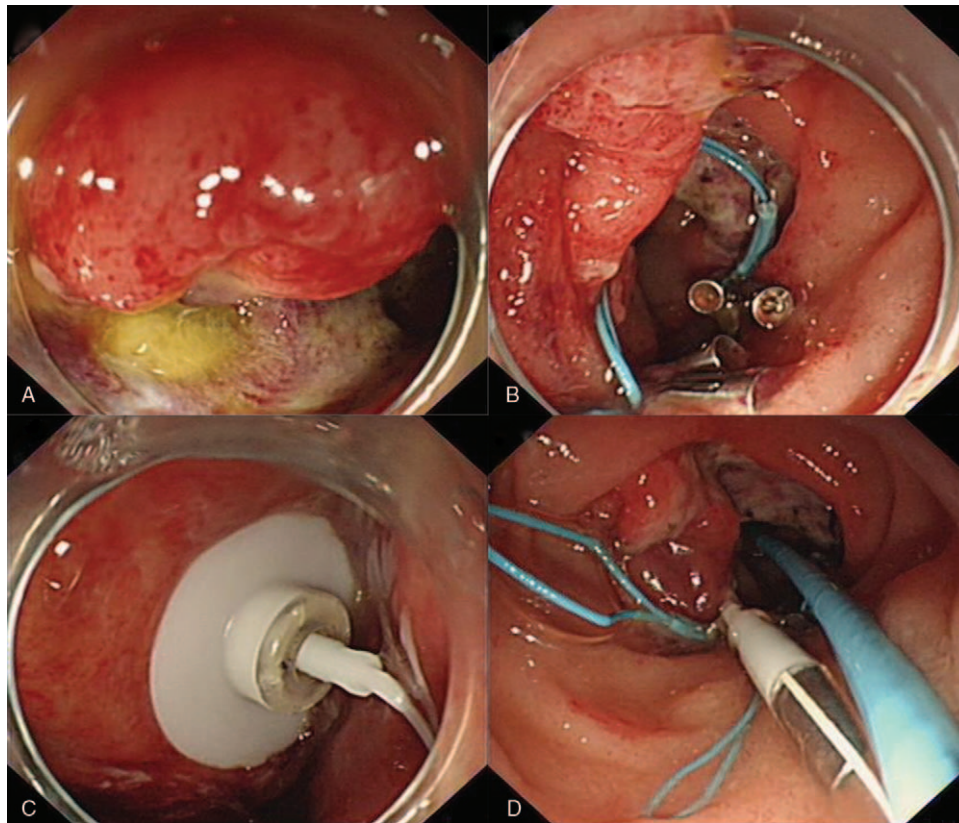
Unfortunately, the patient complained significant abdominal pain and fever (38.9°C) at postoperative day 1. Physical examination showed entire abdominal tender with guarding and rebound tenderness. Liver dullness was also absent. Laboratory tests revealed elevated white blood cell counts ( $11.88 \times 10^9/L$ , normal value:  $4-10 \times 10^9/L$ ) and c-creative protein level (53 g/L, normal value: <5 g/L). Emergent abdominal computed tomography (CT) confirmed the presence of abdominal inflammation and duodenal perforation in the anterior wall (Fig. 2). Thus, a delayed perforation of duodenal ESD was diagnosed.

Considering the high invasive nature of surgery, the patient preferred to receive endoscopic repair and conservative treatments. Underwritten informed consent of patient and her families, we performed endoscopic intervention for her. A minor perforation was found in the mucosal defect of ESD (Fig. 3A). Purse-string suture with 2 Nylon rings and several endoclips was initially used to close the perforation and reduce the mucosal defect (Fig. 3B). To minimize the digestion of digestive juices to the partially closed wound, we performed a percutaneous

endoscopic gastrostomy (PEG) (Fig. 3C) for gastric decompression and drainage (by connecting a negative pressure drainage bag), and proximal duodenal drainage (by inserting a jejunal tube through the PEG to the proximal end of the wound); we also placed a nasointestinal decompression tube (the commonly used



**Figure 2.** CT imaging of the duodenal perforation in the anterior wall (arrow). CT=computed tomography.



**Figure 3.** (A) A minor perforation was noted in the mucosal defect. (B) Partial closure of the mucosal defect was achieved using purse-string technique. (C) PEG was conducted for gastric drainage and proximal duodenal drainage. (D) Proximal duodenal drainage was achieved by a jejunal tube through the PEG, while distal duodenal drainage was achieved by placement a commonly used nasobiliary tube. PEG=percutaneous endoscopic gastrostomy.

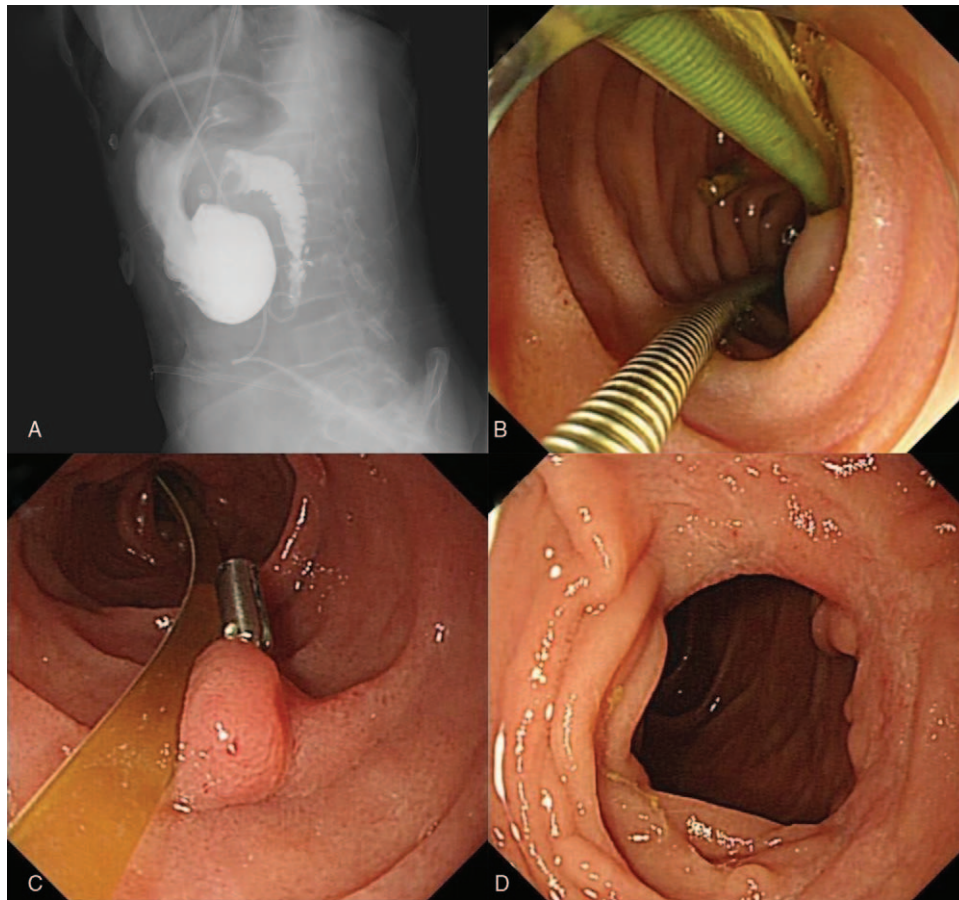
nasobiliary tube) in the distal end of the wound for drainage of regurgitated digestive juices (Fig. 3D). Intravenous antibiotics, proton pump inhibitor, somatostatin, and parenteral nutrition were given following the procedure.

No further symptoms were noted after 5 days. Upper gastrointestinal series was performed at 7th day, showing no leakage of contrast agent (Fig. 4A). Upper endoscopy was also performed to send the jejunal tube to distal duodenum for enteral nutrition (Fig. 4B). The patient began to eat at 15th day, and was discharged at postoperative day 23. Recheck upper endoscopies at postoperative month 2 and 4 confirmed complete healing of the wound (Fig. 4C/D). There were no obvious duodenal stricture or tumor recurrence.

### 3. Discussion

Delayed perforation of duodenal ESD was reported to be up to 14.3%, much higher than that of colorectal ESD (0.4%–0.7%).<sup>[7]</sup> One of the possible mechanisms of delayed duodenal perforation was the exposure of iatrogenic ulcer to the digestive juice<sup>[1,4,7]</sup>; this may also explain why higher incidence of delayed perforation was noted in distal duodenum.<sup>[8]</sup> Peritonitis, retroperitonitis or retroperitoneal abscess can be presented.<sup>[7]</sup> Delayed perforation of duodenal ESD is a clinical emergency, immediate CT for full assessment is needed. Sometimes, high-invasive surgical intervention is required.<sup>[2,8]</sup> Notably, with or without surgery, longer hospital stay is frequently needed once delayed perforation of duodenal ESD occurred.<sup>[2,8]</sup>

It was reported that prophylactic closure of the mucosal defect after ESD could prevent delayed complications.<sup>[1,4]</sup> Although many closure techniques have been reported, like through-the-scope clip,<sup>[9]</sup> over-the-scope clip system,<sup>[10]</sup> overstitch system,<sup>[11]</sup> purse-string suturing,<sup>[12]</sup> string clip suturing,<sup>[4]</sup> and band ligation,<sup>[13]</sup> complete closure of the wound still remains a problem in lesions with larger occupied circumference.<sup>[1]</sup> In the present case, the lesion involved more than half of the circumference, thus complete closure of the wound was technically difficult. Since no obvious muscularis injury or perforation was noted, we left the mucosal defect without attempt of closure. Unfortunately, delayed perforation was complicated, which could be attributed to the digestion of the muscularis by direct exposure to digestive juices in the duodenum. Partial closure of the mucosal defect is usually used to prevent delayed complications in other parts of gastrointestinal tract, however, the recent study did not support its role in duodenal ESD.<sup>[1]</sup> We previously reported the use of double PEGs for treating a refractory duodenal fistula,<sup>[14]</sup> in which adequate drainage of digestive juices was achieved, reducing the digestion to surrounding tissue and allowing spontaneous healing of the fistula. Therefore, we carried out effective drainage (gastric drainage, proximal drainage of the wound, and distal drainage of the wound) after partial closure of the wound for the delayed perforation. The hospital stay of this patient (23 days) was significantly reduced compared with former studies (28–81 days after conservative management and 32–41 days after surgery).<sup>[2,8]</sup> Such good outcome of our case revealed that partial



**Figure 4.** (A) No leakage of contrast agent was noted on upper gastrointestinal series after 7 d. (B) The jejunal tube was sent to distal duodenum for enteral nutrition. (C) Upper endoscopy at postoperative month 2 showed complete healing of the wound and a remnant endoclip. (D) Upper endoscopy at postoperative month 4 revealed no obvious stricture in the distal duodenum.

closure with adequate drainage can be used for management of delayed perforation of duodenal ESD. This method may also serve as an alternative for preventing delayed perforation when complete closure of the wound is technically difficult or impossible.

In conclusion, endoscopic partial closure followed by adequate drainage can be used to treat delayed perforation after large duodenal ESD. It may also serve as an effective method for prevention of delayed perforation in select patients.

### Author contributions

**Supervision:** Bing Hu.

**Writing – original draft:** Liansong Ye, Wenxiu Hou, Xianglei Yuan.

**Writing – review and editing:** Yiping Wang, Chuncheng Wu, Naveed Khan, Bing Hu.

### References

- [1] Kato M, Ochiai Y, Fukuhara S, et al. Clinical impact of closure of the mucosal defect after duodenal endoscopic submucosal dissection. *Gastrointest Endosc* 2019;89:87–93.
- [2] Yahagi N, Kato M, Ochiai Y, et al. Outcomes of endoscopic resection for superficial duodenal epithelial neoplasia. *Gastrointest Endosc* 2018;88:676–82.
- [3] Bourke MJ. Endoscopic resection in the duodenum: current limitations and future directions. *Endoscopy* 2013;45:127–32.
- [4] Nishizawa T, Akimoto T, Uraoka T, et al. Endoscopic string clip suturing method: a prospective pilot study (with video). *Gastrointest Endosc* 2018;87:1074–8.
- [5] Bethge J, Ye L, Ellrichmann M, et al. Advanced endoscopic submucosal dissection with magnetic bead-assisted traction based on gravity for a flat colorectal neoplasm with severe fibrosis. *Endoscopy* 2018;50:824–5.
- [6] Guo LJ, Ye L, Huang ZY, et al. Magnetic beads-assisted endoscopic submucosal dissection of duodenal heterotopic gastric mucosa with fibrosis. *Endoscopy* 2019;51:E113–5.
- [7] Fujihara S, Mori H, Kobara H, et al. Management of a large mucosal defect after duodenal endoscopic resection. *World J Gastroenterol* 2016;22:6595–609.
- [8] Inoue T, Uedo N, Yamashina T, et al. Delayed perforation: a hazardous complication of endoscopic resection for non-ampullary duodenal neoplasm. *Dig Endosc* 2014;26:220–7.
- [9] Wu C, Khan N, Yuan X, et al. Duodenal perforation caused by iron bar. *Am J Gastroenterol* 2018;113:1429.
- [10] von Renteln D, Rudolph HU, Schmidt A, et al. Endoscopic closure of duodenal perforations by using an over-the-scope clip: a randomized, controlled porcine study. *Gastrointest Endosc* 2010;71:131–8.
- [11] Muniraj T, Aslanian HR. The use of OverStitch TM for the treatment of intestinal perforation, fistulas and leaks 2017;6:151–6.
- [12] Li Q, Ji J, Wang F, et al. ERCP-induced duodenal perforation successfully treated with endoscopic purse-string suture: a case report. *Oncotarget* 2015;6:17847–50.
- [13] Li Y, Han Z, Zhang W, et al. Successful closure of lateral duodenal perforation by endoscopic band ligation after endoscopic clipping failure. *Am J Gastroenterol* 2014;109:293–5.
- [14] Zeng QS, Wen ZH, Wang QM, et al. Double percutaneous endoscopic gastrostomies for a refractory duodenal fistula. *Gastrointest Endosc* 2018;88:190–2.