

Case Report

Iridotrabecular and Iridocorneal Contact Changes after Cataract Surgery and Endothelial Keratoplasty in Bilateral Iridoschisis

Takashi Omoto^a Chisato Agata^{a, b} Reina Akiyama^{a, c} Kohdai Kitamoto^a
Tetsuya Toyono^a Junko Yoshida^{a, d} Satoru Yamagami^{a, e}
Tomohiko Usui^{a, d} Takashi Miyai^a

^aDepartment of Ophthalmology, University of Tokyo Graduate School of Medicine, Tokyo, Japan; ^bTokyo Teishin Hospital, Tokyo, Japan; ^cJR Tokyo General Hospital, Tokyo, Japan; ^dDepartment of Ophthalmology, International University of Health and Welfare, Chiba, Japan; ^eDepartment of Visual Sciences, Nihon University School of Medicine, Tokyo, Japan

Keywords

Iridoschisis · Corneal oedema · Anterior segment optical coherence tomography · Descemet stripping automated endothelial keratoplasty

Abstract

We report a case of bilateral iridoschisis with corneal oedema and a quantitative evaluation of the changes in iridotrabecular and iridocorneal contact before and after cataract surgery and after Descemet stripping automated endothelial keratoplasty (DSAEK). A 76-year-old woman with iridoschisis and cataracts, previously managed with laser iridotomy, experienced progressive vision loss. The preoperative iridotrabecular contact (ITC) index measured by anterior segment optical coherence tomography was 23.6% in the right eye and 24.4% in the left eye. Preoperative corneal oedema in the right eye was more severe than that in the left eye. Cataract surgery, followed by DSAEK, was performed in the right eye and subsequently in the left eye. Her visual acuity improved postoperatively, and the corneal oedema of both eyes was treated successfully. Moreover, the ITC index improved in both eyes, to 4.7 and 6.9% after cataract surgery and to 0 and 0% after DSAEK in the right and left eyes, respectively. Staged cataract surgery and DSAEK were effective for endothelial decompensation caused by iridoschisis. Additionally, we confirm that iridotrabecular and iridocorneal contacts improved after both surgical procedures not only after cataract surgery but also after DSAEK. This case report showed the clinical usefulness of the ITC index in the detection of changes after different surgical procedures.

© 2021 The Author(s).
Published by S. Karger AG, Basel

Correspondence to:
Takashi Miyai, tmiy-tky@umin.ac.jp

Introduction

Iridoschisis is a rare condition causing iris degeneration in which the iris stroma is cleaved into the anterior and posterior layers [1, 2]. Angle closure glaucoma is a common complication of iridoschisis, and a low rate of corneal endothelial decompensation has also been reported [3]. The separated anterior layer of the iris floats in the anterior chamber and contacts the corneal endothelium, which can induce corneal endothelial decompensation and oedema. Several reports have shown that corneal oedema with iridoschisis can be successfully managed with keratoplasty, including penetrating keratoplasty [4], non-Descemet stripping endothelial keratoplasty [5], or Descemet membrane endothelial keratoplasty [6].

Due to the recent advances in imaging technology, anterior segment optical coherence tomography (AS-OCT) is now being widely used to examine the anterior region of the eye. The SS-2000 and CASIA2 (Tomey, Nagoya, Japan) is a Fourier-domain AS-OCT device, which enables us to not only evaluate the contact of the peripheral iris with the trabecular meshwork or corneal endothelium but also quantitatively assess the prevalence and amount of iridotrabecular contact (ITC), which is evaluated as the ITC index [7] (Fig. 1). ITC represents both appositional and adhesive attachment of the peripheral iris and trabecular meshwork [7]. The ITC index is considered useful for monitoring the course of treatment of iridoschisis.

Since quantitative changes in the angle of iridoschisis with corneal oedema have not been investigated using the ITC index of AS-OCT, we report a case of bilateral iridoschisis with

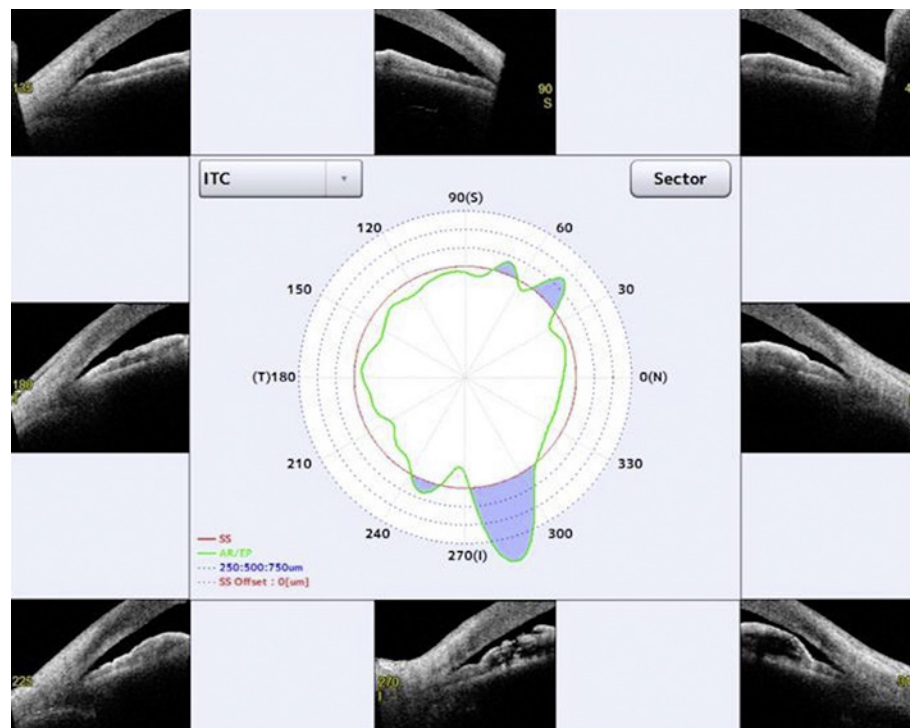


Fig. 1. A representative image for the ITC index measurement with AS-OCT, SS-2000, and CASIA2 (Tomey, Aichi, Japan) (an image of the preoperative right eye). ITC, iridotrabecular contact; AS-OCT, anterior segment optical coherence tomography; SS, scleral spur; AR, angle recess; EP, end point, which is set as the end point of iridocorneal contact; 250:500:750 μm : points from scleral spur at a distance of 250:500:750 μm ; SS offset: distance from the reference point for determining open or ITC to scleral spur. The ITC index is calculated as the sum of the angle of the blue area indicating iridocorneal contact/ the angle of total measured area (360°) $\times 100$ (%).

quantitative changes in ITC before and after cataract surgery and after Descemet stripping automated endothelial keratoplasty (DSAEK).

Case Report

A 76-year-old woman was referred to our hospital from one of our associated hospitals for a 1-month history of worsening vision and corneal oedema in the right eye. She had undergone laser iridotomy (LI) in both eyes at another hospital 9 months ago. She experienced progressive vision loss since a month before the referral.

Her initial best-corrected visual acuity (BCVA) was 20/600 in the right eye and 20/30 in the left. Intraocular pressure was 10 mm Hg in both the eyes. Slit lamp examination revealed iridoschisis in both eyes. Corneal stromal oedema and Descemet's fold were more severe in the right eye than in the left (Fig. 2a). LI holes and moderate nuclear cataract were observed in both eyes. Endothelial cell density was 1,197 cells/mm² in the left eye and immeasurable in the right. Iridoschisis was observed prominently in the inferior region of both eyes; the ITC index in the right and left eye was 23.6 and 24.4%, respectively.

Cataract surgery, followed by DSAEK, was planned for the right eye. Uncomplicated cataract surgery was performed with phacoemulsification and intraocular lens implantation. A twin light chandelier endoilluminator was used during surgery to support visibility [8, 9]; no other specialized techniques were performed besides routine cataract surgery. The ITC index in the right eye after cataract surgery was 4.7%. Subsequently, DSAEK was performed 2 weeks after cataract surgery using a pre-cut imported donor, with the pull-through technique using a Busin glide (Moria, Antony, France) and forceps (Moria USA, Doylestown, PA, USA), through a 5-mm temporal corneal incision with Descemet stripping after peripheral iridotomy. The patient's corneal oedema was treated and the BCVA at the third postoperative month was 20/25 (Fig. 2b). The ITC index was 0 after DSAEK.

Corneal oedema of the left eye progressed, and the BCVA worsened to 20/50 1 year after surgery of the right eye (Fig. 2c). Therefore, the same surgeries were planned for the left. Cataract surgery for the left eye was performed without an endoilluminator because the stromal oedema in the left eye was not as severe as it was in the right eye. The ITC index became 6.9% after cataract surgery. Subsequently, the DSAEK was performed 1 month after cataract surgery. Her corneal oedema was treated, and the BCVA at the second postoperative month was 20/25 (Fig. 2d). Her ITC index was 0 after DSAEK. The AS-OCT images throughout the surgeries are shown in Figure 3. The changes in the ITC index are summarized in Table 1.

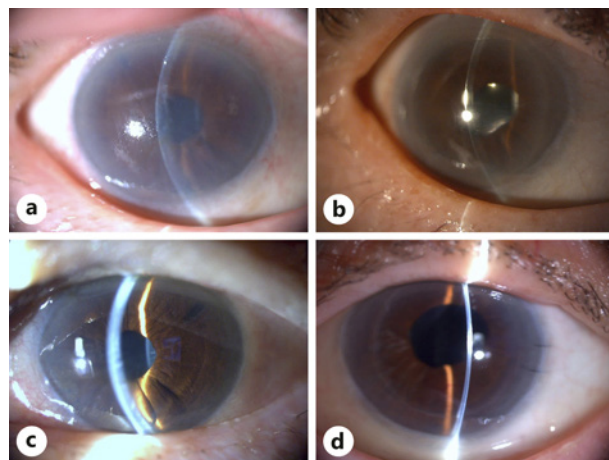


Fig. 2. Slit lamp examination photographs of the right eye preoperatively (a) and postoperatively (b) and those of the left eye preoperatively (c) and postoperatively (d).

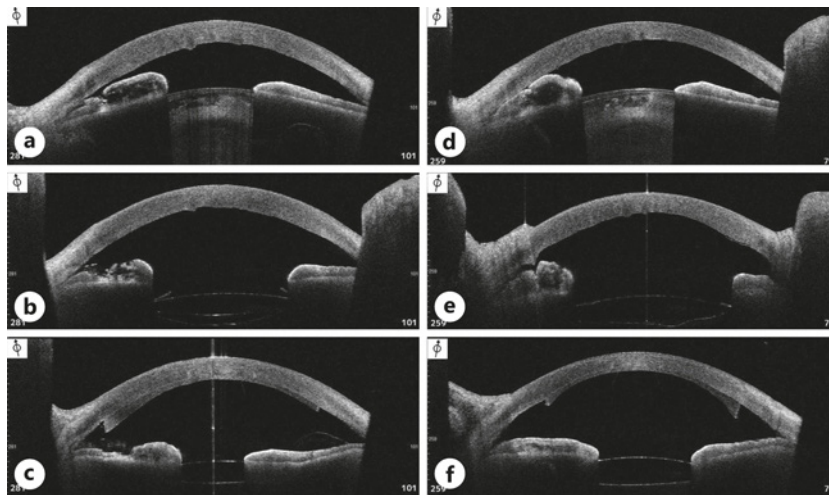


Fig. 3. Changes in the AS-OCT images before and after the cataract surgery, and after Descemet stripping endothelial keratoplasty. All images of each eye [right eye: preoperative (a), postoperative (b), and after DSAEK (c); left eye: preoperative (d), postoperative (e), and after DSAEK (f)] are acquired for the same slice thickness at which the iridocorneal contact is most severe. AS-OCT, anterior segment optical coherence tomography; DSAEK, Descemet stripping automated endothelial keratoplasty.

Table 1. Changes in the ITC index before and after cataract surgery and after Descemet stripping endothelial keratoplasty

	Before cataract surgery, %	After cataract surgery, %	After DSAEK, %
Right eye	23.6	4.7	0
Left eye	24.4	6.9	0

ITC, iridotrabeular contact; DSAEK, Descemet stripping automated endothelial keratoplasty.

Discussion

In this case report of a patient with bilateral iridoschisis, the cataract and corneal oedema were successfully treated by staged cataract surgery and DSAEK, as reported previously [5]. For this patient, LI was performed 9 months before the first visit to another hospital. LI can induce corneal decompensation and bullous keratopathy [10, 11]. The mean duration from argon LI to bullous keratopathy has been reported to be 6.9–7.4 years [10, 11]. In the current case, LI might have caused corneal decompensation to some extent but was not the main cause of bilateral iridoschisis because of the short period from LI to bullous keratopathy. LI has been reported to reduce the average ITC index from 71.52 to 35.31% in patients with primary angle closure (PAC), suspected of PAC, and PAC glaucoma [12]. In the current case, the ITC index before cataract surgery was 23.6% in the right eye and 24.4% in the left. Since LI was conducted at another hospital, we could not evaluate the original ITC index before LI, which we assume to be much higher.

In addition, the ITC index improved after both surgical procedures, primarily after cataract surgery. Selvan et al. [13] previously evaluated the change in the ITC index with cataract surgery in patients with PAC hypertension; cataract surgery reduced the average ITC index from 52 to 19%. Since cataract surgery can improve both ITC and iridocorneal contact, it could be a potential prophylactic treatment for patients with iridoschisis and corneal endothelial impairment. Interestingly, in addition to cataract surgery, DSAEK reduced the ITC

index to 0 in both eyes. Air tamponade in the anterior chamber during surgery may have dissociated the ITC and iridocorneal contact.

Our group previously reported the usefulness of the ITC index for quantitative evaluation of patients after penetrating keratoplasty [7]. Notably, ITC indicates “contact” which includes not only the peripheral anterior synechiae but also the appositional closure. Therefore, the values of the ITC index may vary according to the pupil status of patients.

Using AS-OCT to measure the ITC index has another merit regarding evaluation of the angle. If the cornea is too oedematous, gonioscopy may not work, but this technique allows for evaluation of the angle even for the patients with corneal oedema or opacity.

To avoid corneal endothelial decompensation, not only the specular microscopic assessment of corneal endothelium but also the ITC or iridocorneal attachment should be evaluated by AS-OCT. Cataract surgery should be performed early when these contacts, accompanied by reduction in corneal endothelial cell density, are recognized in patients.

Since this is a retrospective case report, we recommend including more cases in future studies to make the results generalizable. However, iridoschisis with a corneal oedema is very rare; therefore, this case is worth reporting.

In conclusion, staged cataract surgery and DSAEK were successfully performed for treating corneal oedema caused by iridoschisis. We could evaluate the change caused by the surgical procedures with the ITC index. The ITC index was reduced after both surgical procedures but primarily after cataract surgery. This case report shows the clinical usefulness of the ITC index for measuring the detailed changes from different surgical procedures.

Statement of Ethics

This retrospective case study was approved by the research Ethics Committee of the Graduate School of Medicine and Faculty of Medicine at the University of Tokyo. All procedures conducted in this study adhered to the tenets of the Declaration of Helsinki. Written informed consent for publication was obtained from the patient.

Conflict of Interest Statement

The authors have no conflicts of interest to declare.

Funding Sources

This work is supported by JSPS KAKENHI grant number 18K16947 (T.M.).

Author Contributions

T.O. and T.M. contributed to the design of the work, data analysis, and drafting the manuscript. C.A. and R.A. contributed to the interpretation of the data. K.K., T.T., J.Y., T.U., and S.Y. contributed to the data acquisition and supervision of the study. All authors contributed to the final approval of the version published.

References

- 1 Schmitt A. Ablösung des vorderen irisblattes. *Augenh Klin Mbl.* 1922;68:214–5.
- 2 Loewenstein A, Foster J. Iridoschisis with multiple rupture of stromal threads. *Br J Ophthalmol.* 1945;29(6):277–82.
- 3 Chen Y, Qian Y, Lu P. Iridoschisis: a case report and literature review. *BMC Ophthalmol.* 2017;17(1):24.
- 4 Srinivasan S, Batterbury M, Hiscott P. Bullous keratopathy and corneal decompensation secondary to iridoschisis: a clinicopathological report. *Cornea.* 2005;24(7):867–9.
- 5 Minezaki T, Hattori T, Nakagawa H, Kumakura S, Goto H. Non-Descemet's stripping automated endothelial keratoplasty for bullous keratopathy secondary to iridoschisis. *Clin Ophthalmol.* 2013;7:1353–5.
- 6 Greenwald MF, Niles PI, Johnson AT, Vislisis JM, Greiner MA. Descemet membrane endothelial keratoplasty for corneal decompensation due to iridoschisis. *Am J Ophthalmol Case Rep.* 2018;9:34–7.
- 7 Fukuda R, Usui T, Tomidokoro A, Mishima K, Matagi N, Miyai T, et al. Noninvasive observations of peripheral angle in eyes after penetrating keratoplasty using anterior segment fourier-domain optical coherence tomography. *Cornea.* 2012;31(3):259–63.
- 8 Eckardt C. Twin lights: a new chandelier illumination for bimanual surgery. *Retina.* 2003;23(6):893–4.
- 9 Bilgin S, Kayikcioglu O. Chandelier retroillumination-assisted cataract surgery during vitrectomy. *Eye.* 2016;30(8):1123–5.
- 10 Ang LP, Higashihara H, Sotozono C, Shanmuganathan VA, Dua H, Tan DT, et al. Argon laser iridotomy-induced bullous keratopathy a growing problem in Japan. *Br J Ophthalmol.* 2007;91(12):1613–5.
- 11 Shimazaki J, Uchino Y, Tsubota K. Late irreversible corneal oedema after laser iridotomy. *Br J Ophthalmol.* 2009;93(1):125–6.
- 12 Cho HK, Ahn D, Kee C. Evaluation of circumferential angle closure using iridotrabecular contact index after laser iridotomy by swept-source optical coherence tomography. *Acta Ophthalmol.* 2017;95(3):e190–6.
- 13 Selvan H, Angmo D, Tomar AS, Yadav S, Sharma A, Dada T. Changes in intraocular pressure and angle status after phacoemulsification in primary angle closure hypertension. *J Glaucoma.* 2019;28(2):105–10.