

An innovative technique for root coverage using pedicled buccal fat pad

CHITRA AGARWAL, GAYATHRI G. V¹, DHOOM SINGH MEHTA¹

Abstract

Various etiological factors are associated with gingival recession which may be anatomical, physiologic, or pathologic factors. Several root coverage procedures have been described to manage the gingival recession. However, it has been found that root coverage procedures in Miller's Class III and IV gingival recession have a poor prognosis with current techniques. A newer predictable technique, pedicled buccal fat pad (PBFP) has been introduced in cases of severe gingival recession. The buccal fat pad (BFP) is a specialized capsulated fat tissue that has the property of maintaining its volume and structure over a long period of time. It can also serve as a well vascularized, readily obtainable local flap for reconstructive purposes and increasing the dimensions of keratinized mucosa. The aim of this case report is to establish a new technique for root coverage using pedicled BFP in Miller Class IV recession on the maxillary right first molar.

Keywords: Buccal fat pad, gingival recession, root coverage

Introduction

The ultimate aim of periodontal plastic surgery is the coverage of gingival recession which may lead to patient esthetic problem, root caries, or dentinal hypersensitivity, or when it hampers proper plaque removal.^[1]

Various surgical techniques have been proposed for the correction of dental root exposition like free soft tissue grafts, pedicle soft tissue grafts, guided tissue regeneration (GTR), or bilaminar techniques. It has been reported that pedicle grafts results in predictable root coverage.^[2]

The buccal fat pad (BFP) has been used for reconstruction of oral defects and had shown great success in all of the previous studies owing to its physical and biological properties. The advantages of pedicled buccal fat pad (PBFP) include anatomically favorable location, the ease and minimal dissection with which it can be harvested and mobilized,

excellent blood supply, simplicity, versatility, low rate of complications, minimal to no donor site morbidity.^[3]

The aim of this case report is to establish a new technique for root coverage using PBFP in Miller Class IV recession on the maxillary right first molar.

Case Report

A male patient aged 45 years old reported to the outpatient department of Periodontics with the chief complain of bleeding gums during brushing. On clinical examination, generalized inflammation of gingiva and Class IV gingival recession was present in relation to mesiobuccal root of tooth 16 [Figure 1]. Periodontal pocket depth of 8-10 mm was present on the mesial aspect of 16 while on distal aspect, 4-5 mm pocket depth and palatally it was 2 mm only. The tooth was vital and was not mobile. Grade II furcation involvement was present on mesial and buccal aspect of the tooth. Considering that the tooth was asymptomatic, non mobile, presence of adequate bone support, and patient's willingness to save the tooth, it was decided to cover the gingival recession present in relation to mesiobuccal root of the right first maxillary molar using PBFP graft and regenerate the bone on mesial and buccal aspect of the tooth using allogenic bone graft material (Bio-oss®).

Patient signed written informed consent was taken prior to the procedure. The initial plaque control program was completed, including oral hygiene instructions.

Surgical procedure

After adequate local anesthesia, the recipient site preparation was started by giving internal bevel incision to remove the pocket lining and adjacent granulomatous tissue. Flap was raised and thorough debridement of the roots and furcation defects was done.

Department of Periodontics, Jodhpur Dental College General Hospital, Jodhpur, Rajasthan, ¹Department of Periodontics, Bapuji Dental College and Hospital, Davangere, Karnataka, India

Correspondence: Dr. Chitra Agarwal,
Shri Balaji Dental Hospital, Near Electricity Office, Fort Road,
Nagori Gate Circle, Jodhpur - 342 001, Rajasthan, India.
E-mail: chitra_090282@yahoo.com

Access this article online	
Quick Response Code:	Website: www.contempclindent.org
	DOI: 10.4103/0976-237X.137963

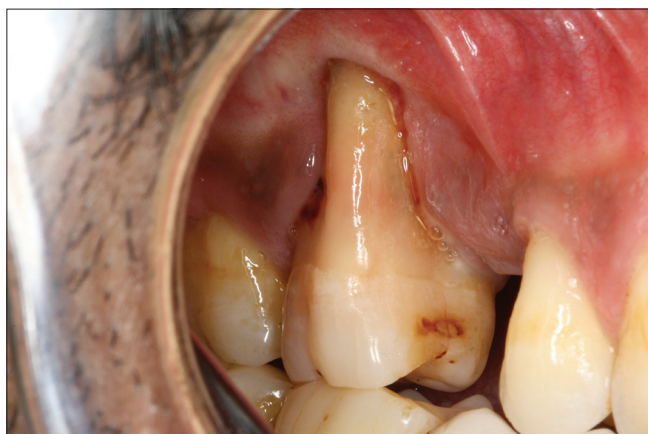

Figure 1: Preoperative photograph showing recession in relation to maxillary right 1st molar

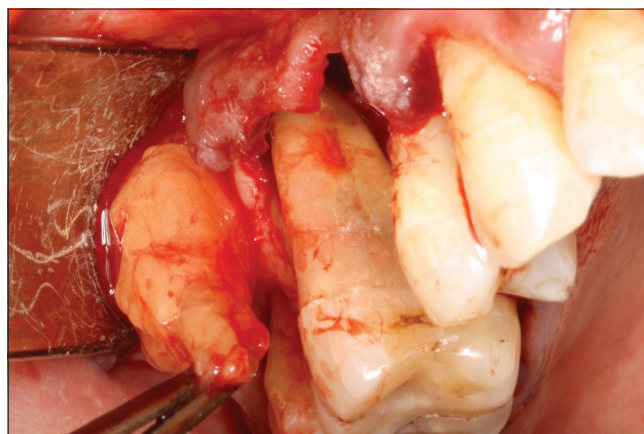


Figure 2: Buccal fat pad flap mobilized

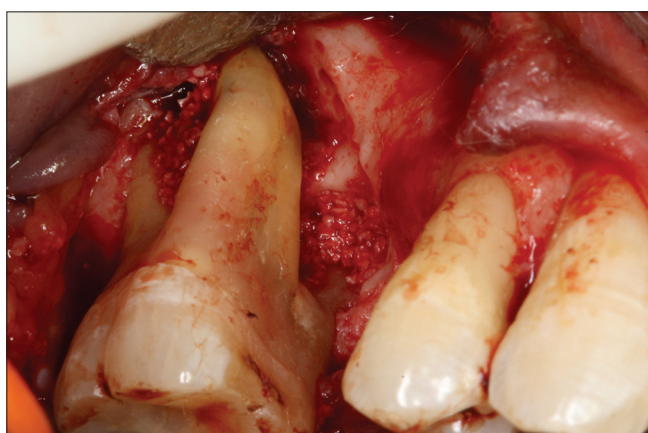

Figure 3: Bio-oss® bone graft material placed

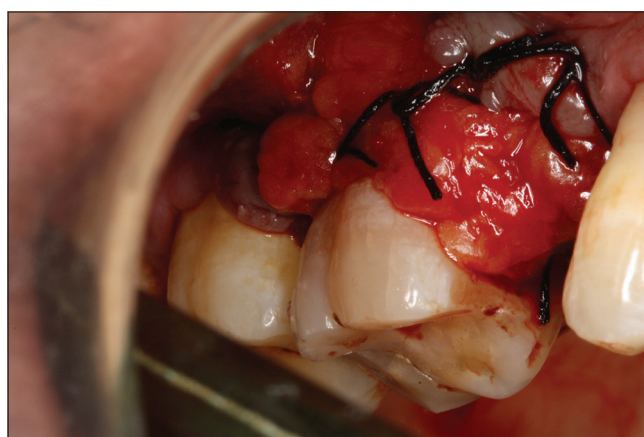

Figure 4: Buccal fat pad flap sutured in place

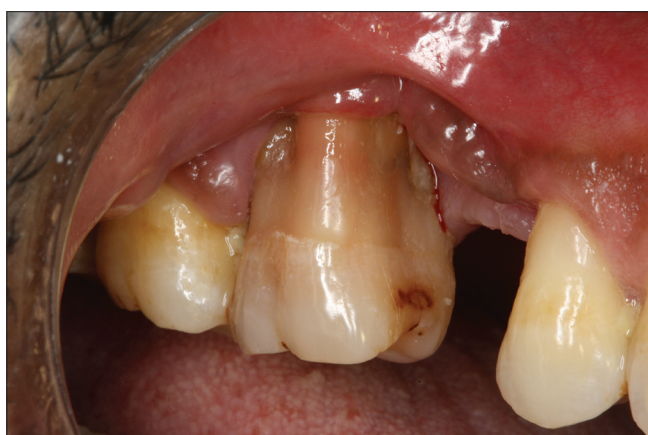

Figure 5: Postoperative photograph showing partial coverage of the gingival recession

A 2-cm horizontal incision was made at the base of the buccal flap that extended backward from above the upper second molar tooth and access to the PBFP was allowed. Blunt dissection was made through the buccinator and loose surrounding fascia which allowed the PBFP to be exposed into the mouth. The buccal extension and the body of the

BFP were gently mobilized by blunt dissection, taking care not to disrupt the delicate capsule and vascular plexus and to preserve as wide a base as possible [Figure 2]. Allogenic bone graft (Bio-oss®) was placed in relation to mesial aspect of the tooth and in furcation area [Figure 3]. The PBFP could be easily spread over the maxillary roots as far anteriorly as the canine tooth region. The vascularized flap was secured and immobilized to the buccal surface of the upper first molar tooth and sutured to the mucosal edges, ensuring that it was not under tension [Figure 4]. The patient was given post operative instructions and medications. Amoxicillin (500 mg three times a day for 5 days) and ibuprofen (three times a day for 5 days) were prescribed. Continuous rinsing with 0.12% chlorhexidine solution twice daily for 6 weeks was prescribed. The patient was advised to refrain from retracting the lips and cheeks and to avoid brushing or flossing in the grafted area for 6 weeks.

Results

Postoperative healing was uneventful. The patient was evaluated and sutures were removed on the 14th postoperative day. The patient was seen for follow-up every week for

the next 8 weeks and at 24th week [Figure 5]. The clinical attachment gain was found to be 4 mm which results in partial root coverage. Epithelialization of the BFP was completed after 4 weeks with formation of keratinized mucosa.

Discussion

Reconstruction of the gingiva has become an integral part of periodontal practice. Various techniques have been proposed for root coverage. Several procedures are required to reconstruct large volume soft tissue defects with subepithelial connective tissue graft.^[4] Free gingival graft results in poor color match.^[1] Both free soft tissue grafts requires two surgical sites^[5] and their survival depends completely on circulation at the recipient site.^[6] Pedicle grafts such as lateral pedicle flaps are limited by their length and thickness in the donor site, with chances of recession at the donor site.^[6] Coronally positioned flap requires keratinized gingiva and used to cover shallow recessions.^[7] These surgical techniques were not suitable for sites with severe gingival recession. In addition, gingival recessions treated with different pedicle graft surgical procedures healed by a long junctional epithelium with a limited amount of bone and cementum formation.^[8]

PBFP can be used for root-coverage procedure in severe gingival recession defects especially in the posterior maxilla. In this case report, by using this technique, clinical attachment gain of 4 mm was achieved, which was similar to that seen by El Haddad *et al.*^[9]

The PBFP has been used successfully for reconstruction of the buccal mucosa, palatal mucosa, covering the surface of bone grafts, closure of oronasal fistulas, and posttraumatic reconstruction in the maxillary region.^[10] Pedicled fat pad takes an axial graft pattern when removed from its usual place and results in accelerated wound healing because of rich vascular supply by branches of many arteries.^[11] Samman *et al.*^[12] had shown histological evidence of wound healing in 2-3 week. The fat cells are completely replaced with relatively acellular fibrous tissue and covered by stratified squamous epithelium. Covering BFP with buccal flap is beneficial only when BFP is stretched excessively or is perforated. In this case report, epithelialization of the pedicled BFP was observed after the second week with complete epithelialization in 4-6 weeks. The flap becomes easily accessible through the single incision used for creating surgical defect, thereby obviating the necessity of an alternative donor site and its ensuing morbidity.^[13] The rich vascularity of the pedicled graft ensures its vitality and resistance to infections in contrast to a free soft tissue grafts. It has been found that the stem cells are present in the PBFP that help in periodontal regeneration.^[14]

No complications were reported. Limited stretching of the pedicled flap to preserve its vascularity and partial root coverage in present case report are the disadvantages associated with the PBFP. It may not be suitable for more anterior teeth such as the central and lateral incisors, and it could not be used for defects in the mandibular teeth as a pedicled flap.

It can be concluded that the technique is a novel approach for covering severe gingival defects and further studies are necessary to support the finding.

References

1. Camargo PM, Melnick PR, Kenney EB. The use of free gingival grafts for aesthetic purposes. *Periodontol* 2000 2001;27:72-96.
2. Wennström JL. Mucogingival surgery. In: Lang NP, Karring T, editors. *Proceedings of the 1st European Workshop on Periodontology*. London: Quintessence Publishing Co. Ltd.; 1994. p. 193-209.
3. Singh J, Prasad K, Lalitha RM, Ranganath K. Buccal pad of fat and its applications in oral and maxillofacial surgery: A review of published literature (February) 2004 to (July) 2009. *Oral Surg Oral Med Oral Pathol Oral Radiol Endod* 2010;110:698-705.
4. Langer B, Calagna LJ. The subepithelial connective tissue graft. A new approach to the enhancement of anterior cosmetics. *Int J Periodontics Restorative Dent* 1982;2:22-33.
5. Henderson RD, Greenwell H, Drisko C, Regennitter FJ, Lamb JW, Mehlbauer MJ *et al.* Predictable multiple site root coverage using an acellular dermal matrix allograft. *J Periodontol* 2001;72:571-82.
6. Nevins M, Cappetta E. An overview of mucogingival surgery to cover the exposed root surface. In: Nevins M, Mellonig J, editors. *Periodontal Therapy: Clinical Approaches and Evidence of Success*. Hanover Park: Quintessence Publishing; 1998. p. 339-54.
7. Miller PD Jr. Root coverage grafting for regeneration and aesthetics. *Periodontol* 2000 1993;1:118-27.
8. Caffesse RG, Kon S, Castelli WA, Nasjlets CE. Revascularization following the lateral sliding flaps procedure. *J Periodontol* 1984;55:352-8.
9. El Haddad SA, Abd El Razzak MY, El Shall M. Use of pedicled buccal fat pad in root coverage of severe gingival recession defect. *J Periodontol* 2008;9:1271-9.
10. Hao SP. Reconstruction of oral defects with the pedicled buccal fat pad flap. *Otolaryngol Head Neck Surg* 2000;122:863-7.
11. Tideman H, Bosanquet A, Scott J. Use of the buccal fat pad as a pedicled graft. *J Oral Maxillofac Surg* 1986;44:435-40.
12. Samman N, Cheung LK, Tideman H. The buccal fat pad in oral reconstruction. *Int J Oral Maxillofac Surg* 1993;22:2-6.
13. el-Hakim IE, el-Fakharanay AM. The use of the pedicled buccal fat pad (BFP) and palatal rotating flaps in closure of orofacial communication and palatal defects. *J Laryngol Otol* 1999;113:834-8.
14. Pyo SW, Park JW, Lee IK, Kim CH. Differentiation of adult stem cell derived from buccal fat pad into osteoblast. *J Korean Assoc Oral Maxillofac Surg* 2006;32:524-9.

How to cite this article: Agarwal C, Gayathri GV, Mehta DS. An innovative technique for root coverage using pedicled buccal fat pad. *Contemp Clin Dent* 2014;5:386-8.

Source of Support: Nil. **Conflict of Interest:** None declared.