

Case Report

Impacted Palatal Canines and Diode Laser Surgery: A Case Report

Marina Consuelo Vitale,¹ Maria Gloria Nardi,² Matteo Pellegrini ,² Francesco Spadari,^{3,4} Federica Pulicari,^{3,4} Roberto Alcozer,¹ Martina Minardi,¹ Maria Francesca Sfondrini,¹ Karin Bertino,¹ and Andrea Scribante ¹

¹Unit of Orthodontics and Pediatric Dentistry, Section of Dentistry, Department of Clinical, Surgical, Diagnostic and Pediatric Sciences, University of Pavia, Pavia 27100, Italy

²Section of Dentistry, Department of Clinical, Surgical, Diagnostic and Pediatric Sciences, University of Pavia, Pavia 27100, Italy

³Maxillo-Facial and Odontostomatology Unit, Fondazione IRCCS Cà Granda Ospedale Maggiore Policlinico, Milan 20122, Italy

⁴Department of Biomedical, Surgical and Dental Sciences, University of Milan, Via Della Commenda 10, Milan 20122, Italy

Correspondence should be addressed to Andrea Scribante; andrea.scribante@unipv.it

Received 13 April 2022; Accepted 27 August 2022; Published 6 October 2022

Academic Editor: Giuseppe Alessandro Scardina

Copyright © 2022 Marina Consuelo Vitale et al. This is an open access article distributed under the Creative Commons Attribution License, which permits unrestricted use, distribution, and reproduction in any medium, provided the original work is properly cited.

Introduction. Maxillary canine is the most frequent dental element that could likely remain impacted in the bone structure, with a percentage between 1 and 5%. This study presents a case report using a diode laser for surgical-orthodontics disinclusion of a palatal mucosal impacted permanent left upper canine (2.3) and the simultaneous application of an orthodontic bracket. **Methods.** After cementation of the trans-palatal bar to the upper first molars with a hook for orthodontic traction, local anaesthesia with articaine was performed, followed by surgical operculectomy using a diode laser (810 nm wavelength, continuous wave mode with a power output of 3 W, and a 0.4 mm diameter optical fiber), and the orthodontic bracket with a passive metal looped ligature was applied. Subsequently, active elastic traction was applied on 2.3 and the upper arch was bonded for the application of a series of orthodontic wires, lace-back, and metal ligatures. A progressive reactivation of the elastic traction and extraction of 6.3 was necessary to translate the canine into the correct arch position. **Results.** Diode laser surgical-orthodontic disinclusion of impacted upper canine was performed successively, resulting in a dry surgical field ideal for orthodontic bracket adhesion. No pain and no swelling have been reported from the patient. The orthodontic treatment allowed the canine to be moved to the correct position in the arch. **Conclusions.** This case showed that the diode laser is a valid alternative for the surgical-orthodontic disinclusion of an included tooth element.

1. Introduction

After the third molar, maxillary canine is the most frequent dental element that could likely remain impacted in the bone structure, with a percentage between 1 and 5%, depending on the patient. It is more common in females than in males, with a ratio of 2 : 1, and only 8% of patients are bilateral [1]. Impaction of the maxillary canine has a ratio of 10 : 1 to mandibular canine and 85% of the upper impaction are palatal [2].

Numerous etiological factors are associated with impacted canines and, according to the literature, they can

be classified as localized, systemic, and genetic (Table 1) [3–9].

It is essential to make an early diagnosis of the impacted canine to plan the treatment of this dental anomaly in advance and to properly replace this tooth in the arch as soon as possible, considering the importance of canine guidance role in the occlusion and consequently in the correct body posture. [10]. Early diagnosis of canine displacement in relation to the surrounding structures is mainly based on radiographic examination: in Panoramic X-ray more mesial is located in the canine crown, further likelihood of canine eruption is reduced [11].

TABLE 1: Etiologic factors associated with impacted canines.

Localized [3, 4]				
Loss of arch space	Trauma	Ankylosis	Root dilacerations	Supernumerary teeth
Cyst or neoplasm	Reconstructive surgery for cleft lip/palate repair	Thickened overlying bone or soft tissue	Missing adjacent lateral incisor	Variation in root size of the lateral incisor
Variation in timing of lateral incisor root formation		Over-retained primary canine or early loss of the primary canine		Idiopathic factors
Systemic [5]				
Endocrine disorders		Febrile illness		Irradiation
Genetic [5-9]				
Gardner syndrome	Cleidocranial dysostosis	Yunis-Varon syndrome	Malposed tooth germ	Presence of an alveolar cleft

The choice of treatment in the patient with an impacted canine changes with the age, oral health, and etiologic factors [3, 12]: monitoring of the impacted element, in the absence of clinical problems [13], extraction of the deciduous element, if the impacted permanent canine is close to eruption [3], extraction of the deciduous tooth and simultaneous uncovering of the permanent tooth with the application of an orthodontic appliance to increase the space in the arch, and allowing the physiological eruption of the canine [13]. In some cases, it is possible to perform dental reimplantation, when the orthodontic treatment turns out to be too complex, unsuccessful, or not accepted by the patient [13].

At the end of growth, surgical-orthodontic treatment is the only choice to align teeth in the dental arch; alternatively, it is possible to extract the impacted element with subsequent prosthetic or implant-prosthetic treatment [3].

Laser is the acronym of light amplification by stimulated emission of radiation, and it represents a new technology introduced in Dentistry by Theodore Harold Maiman in 1960, but only in 1989, Nd:YAG laser and CO₂ laser were commercially available in the dental market [14]. The light emitted is monochromatic, collimated, and coherent [15]. The essential elements of a laser device are a sounding box in which an active medium is stimulated by a pumping process in a population inversion and in a suitable geometry of the optical feedback elements. Depending on the active medium (gas, liquid, or solid), laser radiation could be in the ultraviolet, visible, or in infrared section of the electrophotometer spectrum [16].

Different authors described laser efficacy in the treatment of oral pathologies, carrying out studies on photodynamic therapy [17, 18] and surgical procedures [19, 20]. Laser provides an excellent alternative to conventional surgical techniques for soft tissue [21]. Many authors described the use of laser in surgical treatments, such as gingivectomy, labial, lingual frenectomies, and fiberotomy [22]. Furthermore, laser can prevent aphthae and cold sores, ablate benign and irritant tissue excess, correct lip, and tongue bands [23]. Laser can also be used in endodontics to remove bacteria from infected teeth [24]. Laser plays an important role in the treatment of periodontal disease: it can modulate many inflammatory pathways, improves wound healing by

stimulating fibroblast proliferation, it has a positive biomodulatory effect on bone healing, it performs an antimicrobial activity, and could be a reliable adjunctive agent to mechanical debridement in the non-surgical treatment of periodontal disease [25]. Additionally, it is also used to treat dentin hypersensitivity [26]. Laser can also be useful in dental bleaching: studies have shown how it can accelerate the release of free radicals within the bleaching gel to decrease the duration of the treatment [27]. Some authors described how low-level laser therapy and photodynamic therapy after scaling and root planning can improve the therapeutic outcomes in patients affected by chronic periodontitis [28]. In the literature the role of laser in cavity preparation, carious removal, and pulp therapy is also discussed [29]. Meanwhile, laser, safe and effective technology, has become widely used in dentistry. The potential advantages include less or no bleeding during the surgical procedure, reduction, or elimination of the need for local anaesthesia, reduced post-operative pain, and less patient anxiety [30].

Finally, laser can be applied in orthodontics to etch enamel prior to adhesive application and orthodontic brackets [31] and can reduce pain following band application on maxillary first molars for orthodontic treatment [32]. Photobiomodulation (or low-level laser therapy) with laser or LED can also be used to reduce pain intensity during and following lower third molar extraction and to improve symptoms related to Burning Mouth Syndrome through a reduction of the capillary diameter [33, 34].

Since there are few studies assessing laser application's advantages in surgical-orthodontics disinclusion of an impacted canine, the aim of the present study is to present a case report using a diode laser for the disinclusion of an impacted permanent left upper canine (2.3) and the simultaneous application of an orthodontic bracket.

2. Case Report

2.1. Diagnosis and Etiology. A 17.5-year-old female patient was referred to the Unit of Orthodontics and Paediatric Dentistry from the Unit of Oral Surgery of the Department of Clinical, Surgical, Diagnostic, and Paediatric Sciences of the University of Pavia. In the past, she had a root canal treatment on upper central incisors after dental trauma.

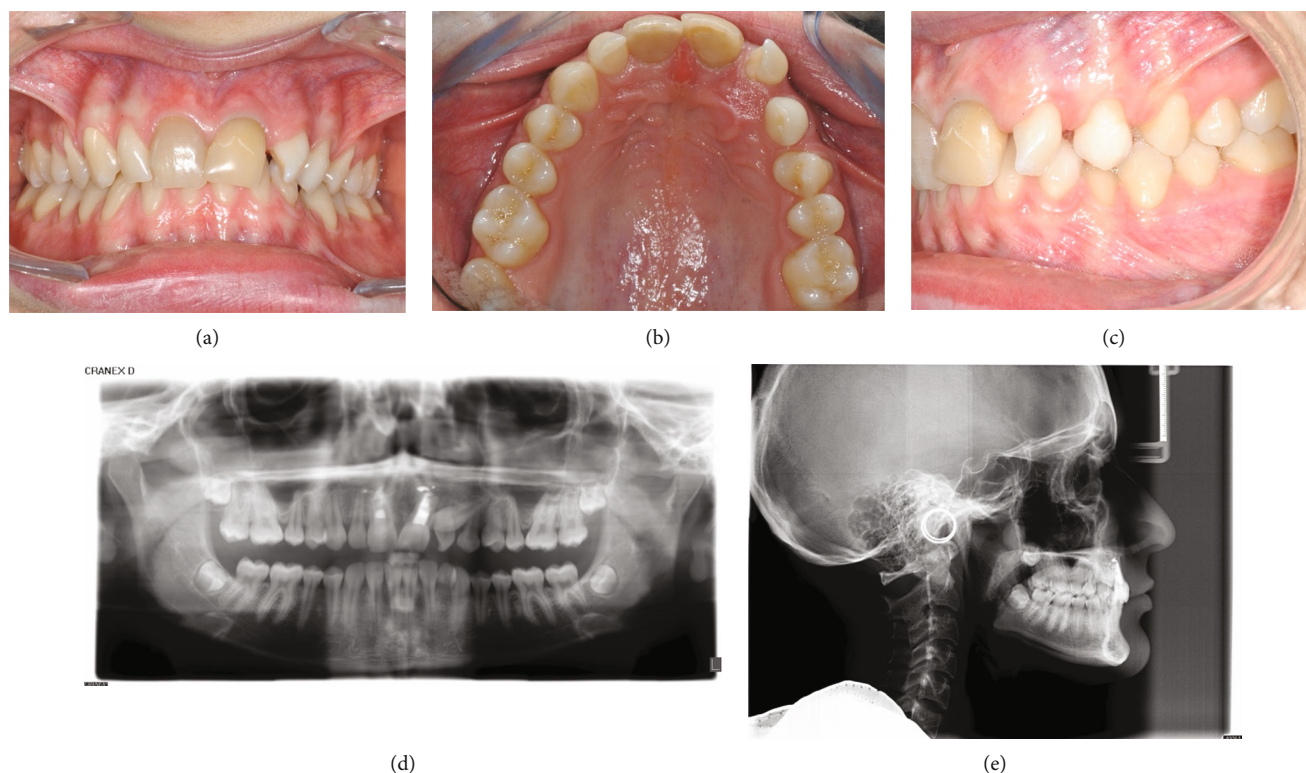


FIGURE 1: (a–c) Pretreatment intraoral and (d and e) radiographical recordings.

The patient showed facial symmetry, competent lips, and normal facial height. Upper and lower dental midlines coincided. Fox plane was not completely parallel to the interpupillary line. Panoramic and lateral cephalometric radiographs were taken (Figures 1(d) and 1(e); Cranex® D, Soredex®, Tuusula, Finland): the panoramic radiograph showed the presence of third molars' germs, lower deciduous canines' persistence, and upper left canine's impaction without apparent left maxillary incisors' radicular resorption.

Cephalometric analysis was performed (DeltaDent, version 2.3, Outside Format, Paullo, Italy): class I skeletal with bimaxillary protrusion (ANB 1.2°, SNA 87°, SNB 85.8°, and Wits index—1.4 mm), hypodivergency, and anterior remaining growth were shown.

The facial profile was normal, the facial angle was slightly increased (171.3°), while the nasolabial angle was slightly decreased (93.3°). Upper incisors were correctly inclined, in fact, the angle formed by the upper incisor's longitudinal axis and bisplanal plane (Sna-Snp) measured 107.9°, whereas lower incisors were retroclined, considering that the angle formed by the lower incisor's longitudinal axis and mandibular plane (Go-Gn) measured 87.8°. Intraoral pictures (Figures 1(a)–1(c); taken with Nikon Digital Camera D3500, Nikon Corporation, Tokyo, Japan) showed coincident dental midlines, deep bite, conservative treatments on upper central incisors, and upper lateral incisors' malposition. Overjet measured 0 mm, while overbite measured 4 mm. The patient presented class I molar and class I canine on the right with upper central incisors discolouration. On the left, the patient showed class I molar, while canine clas-

sification was not possible. Lower deciduous canines were still present, left maxillary lateral incisors were rotated and many diastemas could be found. The morphology of the upper arch was correct, the retroincisive papilla was hypertrophic, and the first upper maxillary molars were rotated. The lower arch showed a correct morphology as well, lower left canine was lingually inclined. There was no dentoalveolar discrepancy. Bolton's analysis was appropriate, considering that the impacted canine was the same size as the contralateral teeth and excluding the lower left canine. Furthermore, clinical recordings highlighted normal Periodontal Screening and Recording and slight mobility on upper central incisors, multiple gingival recessions in the upper and lower posterior jaws and good oral hygiene.

Clinical and radiological recordings led to the diagnosis of the upper left canine's palatal impaction and surgical exposure of the impacted tooth was planned for subsequent orthodontic traction. The impacted canine provided a "sector 2" position with an α angle, formed by the tooth's midline and long axis, of approximately 80° and a short distance from the alveolar ridge [35].

2.2. Treatment Objectives. The aim of the treatment is surgical operculectomy of the mucosal tissue overlying the left upper permanent canine (2.3) in palatal mucosal impaction, with good surgical haemostasis, allowing intra-operative adhesion of the orthodontic bracket, thus exerting a more rapid onset of orthodontic traction. The extraction of the deciduous canine (6.3) is necessary to allow the permanent canine to be moved into the dental arch after the disinclusion has been completed.

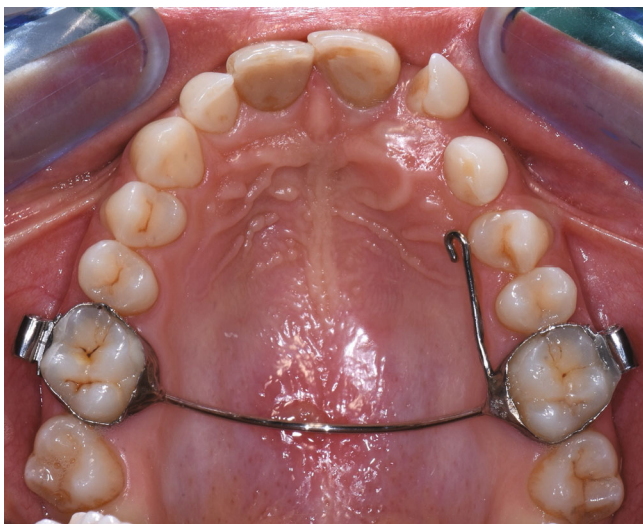


FIGURE 2: Intraoral photo with the TPB cemented to the first molars and the orthodontic traction hook welded.

2.3. Treatment Alternatives. The first possible alternative is a surgical treatment with lasers of various wavelengths: 10,600 nm (CO₂ laser), 2940 nm (Er:YAG laser), and 1064 nm (Nd:YAG laser).

Another possible alternative is the use of the electric scalpel, which presents different risks associated with its use, including burns due to the use of high-frequency current, fire risks due to the presence of combustible liquids or gases in the room where it is used, and electrical risks due to the radiated power, which may disturb any equipment applied to the patient [36].

The last alternative is a conventional surgical approach using a cold-blade scalpel, with the consequent risks of intra- and post-operative bleeding and the impossibility of maintaining a dry surgical field, essential to ensure proper adhesion of the orthodontic bracket, the need to apply sutures, potential difficulties in wound healing, and increased post-operative pain [37].

2.4. Treatment Progress. Written informed consent was obtained from the patient's parents to proceed with the surgical-orthodontic procedure of canine disclusion. An upper silicone impression (Elite HD+ Putty Soft, Zhermack S.p.A., Badia Polesine, Italy) was made and sent to the dental technician for fabrication of a trans-palatal bar (TPB) with a hook for orthodontic traction of 2.3 impacted. After the use of orthodontic separators (Loose S Modules S2, 3M Company, St. Paul, MN, USA), the TPB was cemented to the upper first permanent molars (3M™ Unitek™ Multi-Cure Glass Ionomer Band Cement, 3M Company, St. Paul, MN, USA) and cement was light-cured (Starlight Pro, Power Output 1400 mW/cm², Mectron S.p.A., Carasco, Italy; Figure 2). The patient and all staff wore protective glasses to prevent eye damage [38]. After local anaesthesia (Septanest, articaine hydrochloride 4% with adrenaline 1/100,000), a diode laser (Fotona XD-2, Fotona d.o.o., Ljubljana, Slovenia) was used to perform surgical operculectomy, being an element in superficial palatal impaction, with the following parameters

[39]: 810 nm wavelength, continuous wave mode with a power output of 3 W and a 0.4 mm diameter optical fiber (Figures 3(a) and 3(b)). Figure 4 shows how the surgical incision did not cause intra-operative bleeding, thus creating an ideal condition for the adhesion of the orthodontic bracket. No pain and no swelling have been reported from the patient.

The bonding protocol used is as follows [40]: etching of the enamel with 35% phosphoric acid applied for 20–30 seconds and rinsing for an equivalent time. Drying using aspiration to obtain the chalky white appearance of the enamel. Application of light cure adhesive (3M™ Transbond™ PLUS Color Change Adhesive, 3M Company, St. Paul, MN, USA) on the enamel and on the intrados of the orthodontic bracket using a Microbrush® (Microbrush International, Algonquin, IL, USA). Positioning of the orthodontic bracket (3M Unitek APC™ II Victory Series™, 3M Company, St. Paul, MN, USA) and application of continuous pressure for a light curing time of twice 20 seconds under constant suction (Starlight Pro, Power Output 1400 mW/cm², Mectron S.p.A.). Immediate traction with an elastic connection to the wire: if an error has been made in the bonding protocol, the orthodontic bracket is immediately taken off and a new bonding procedure is begun.

The orthodontic bracket was placed with a passive metal looped ligature, secured with composite (Figure 5). No sutures and no additional analgesic or antibiotic were recommended, thanks to the photo-bio-stimulating effect (LLLT) of laser [41]. The patient was discharged with necessary postoperative instructions for maintenance of good oral hygiene and keeping the area clean.

The patient was visited with a follow-up of 2 weeks, twice, and monthly thereafter. After 2 weeks, active elastic traction on 2.3 has been applied and one month after surgery the upper arch was bonded through Straight-Wire MBT™ technique with a 0.14" NiTi arch-wire (3M™ Unitek™ Nitinol Classic Archwire, 3M Company, St. Paul, MN, USA), performing a mesial lace-back 1.2–2.2 and metal ligation on 2.2 with preformed ligature wire 0.10" (K4210-25, Leone S.p.A. Ortodonzia e Implantologia, Sesto Fiorentino, Italy; Figure 6).

Subsequently, the canine was gradually translated into the correct position in the dental arch by progressive reactivations of elastic traction with elastic cotton threads (Leone, Sesto Fiorentino, Italy), lace-back 1.2–2.2, and metal ligatures on 2.2 and 2.4 with preformed ligature wire 0.10" (K4210-25, Leone); in addition, a super elastic NiTi arch-wire (0.12") upper arch has been used (3M™ Unitek™ Nitinol Classic Archwire, 3M Company).

Table 2 shows the procedures checklist of surgical-orthodontic disclusion of the left upper canine (2.3) in palatal mucosal impaction and its orthodontic translation in the upper arch.

The patient is still undergoing orthodontic treatment to finalize therapy for closing diastema between 2.2 and 2.3.

2.5. Treatment Results. After excision, the patient had no signs of respiratory distress, and no feeding difficulty was reported from the parents. After 2 weeks and 1 month

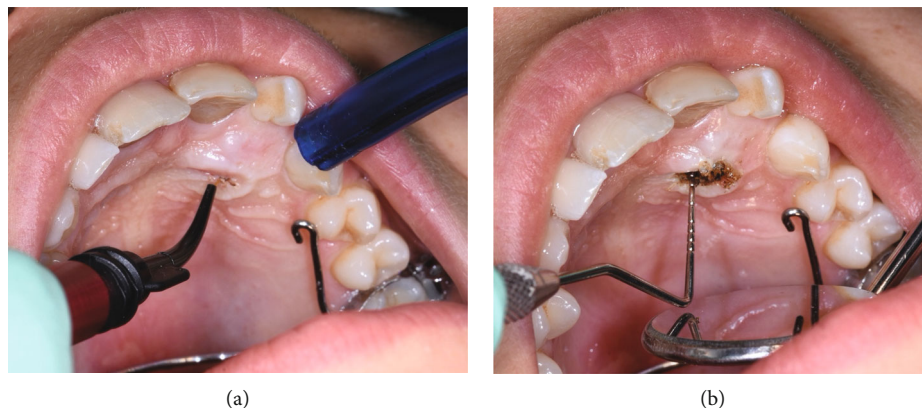


FIGURE 3: (a and b) Intraoral photo during surgical procedure.

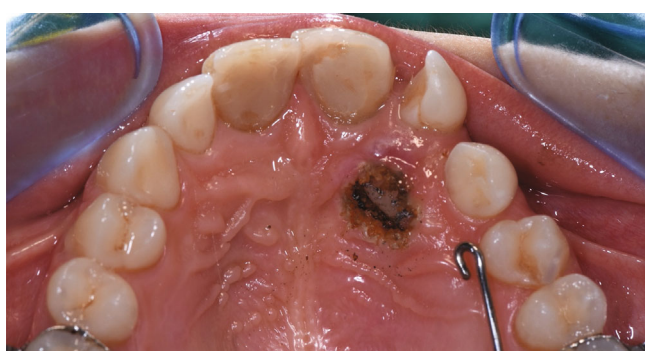

FIGURE 4: Surgical incision after laser surgery.

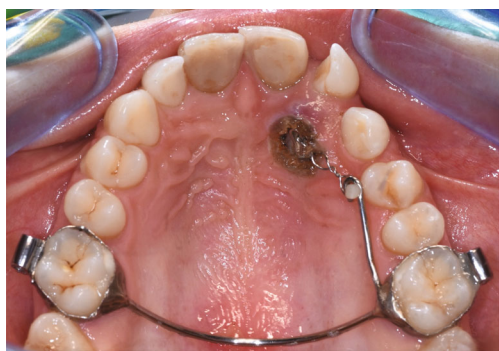


FIGURE 5: Orthodontic bracket positioned after surgical operculectomy, with a passive metal looped ligature and secured with composite.

follow-up, the intraoral wound healed without complications and no signs of infection (Figure 6); 3 months after surgery, the position of the upper canine can be appreciated and thanks to the orthodontic traction applied (Figure 7); 12 months after surgery, the upper canine 2.3, once included, is positioned at the level of the dental arch but a diastema remains between 2.2 and 2.3, for which orthodontic finalization is necessary to close it (Figures 8(a)–8(d)).

2.6. Discussion. This case report described surgical disinclusion of a left upper canine using a diode laser, followed by orthodontic treatment to translate the impacted canine into the dental arch, highlighting some advantages, such as no

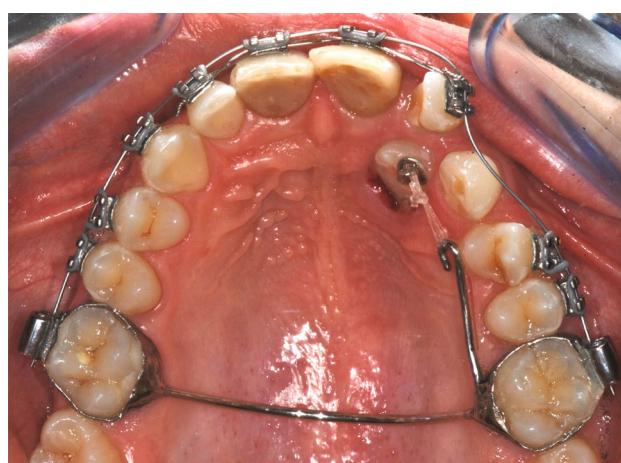


FIGURE 6: Intraoral photo 1 month after surgery with active elastic traction on 2.3 and upper arch bonded.

intra-operative bleeding, thus providing orthodontic bracket adhesion, no sutures, and no post-operative pain or swelling.

In the literature, there are several articles in which laser technology has been used in the surgical management of impacted teeth; however, to our knowledge, no case reports have not yet been presented in literature where an 810 nm wavelength diode laser has been used to perform surgical operculectomy of the palatal impacted canines with a subsequent intra-operative application of the orthodontic bracket. A previous clinical study showed the application of a 980 nm wavelength diode laser for surgical operculectomy of a palatal included left upper canine, preventing bleeding and need for sutures, reducing pain, and allowing placement of orthodontic brackets [42]. A recent case report showed a surgical operculectomy of both impacted upper permanent canines through a CO₂ laser, postponing orthodontic bracket placement to a later date and highlighting many advantages, such as no bleeding, no need for sutures, relative ease, and speed of the procedure, reduced or no postoperative symptoms, antimicrobial activity, and rapid wound healing [43]. A case series study showed a combination of two laser (Nd:YAG and Er:YAG) for the surgical treatment of a left upper canine in osteo-mucosal impaction. Er:YAG was used for hard

TABLE 2: Procedures checklist of surgical-orthodontic disinclusion of the left upper canine (2.3) in palatal mucosal impaction and its orthodontic translation in the upper arch.

1. Diagnosis of palatal mucosal impaction of the left upper canine (2.3) by clinical and radiological recordings.
 2. Definition of treatment objectives: surgical-orthodontic disinclusion of impacted 2.3 by diode laser and its orthodontic translation in the arch after extraction of 6.3.
 3. Obtaining informed consent from the patient's parents to proceed with surgical-orthodontic disinclusion.
 4. Performing an upper silicone impression for the fabrication of a trans-palatal bar (TPB) with a hook for orthodontic traction of 2.3 impacted.
 5. After application of the orthodontic separators, cementing and light-curing the TPB on the upper first permanent molars.
 6. Wearing safety glasses and performing local anaesthesia.
 7. Performing a diode laser surgical operculectomy with the following parameters: 810 nm wavelength, continuous wave mode with a power output of 3 W, and a 0.4 mm diameter optical fiber.
 8. Adhesion of the orthodontic bracket to achieve orthodontic traction.
 9. Etching of the enamel with 35% phosphoric acid applied for 20–30 seconds and rinsing for an equivalent time.
 10. Drying using aspiration to obtain the chalky white appearance of the enamel.
 11. Application of light cure adhesive on the enamel and on orthodontic bracket baseplate using a Microbrush®.
 12. Positioning of the orthodontic bracket and application of continuous pressure for a light curing time of twice 20 seconds under constant suction.
 13. Immediate traction with an elastic connected to the wire: if an error has been made in the bonding protocol, the orthodontic bracket is immediately taken off and a new bonding procedure is begun.
 14. Placement of the orthodontic bracket with a passive metal looped ligature, secured with composite.
 15. Discharge the patient with necessary postoperative instructions for maintenance of good oral hygiene and keeping the area clean.
 16. See the patient 2 weeks after surgery, twice, and monthly thereafter.
- Application of active elastic traction on 2.3 after 2 weeks and upper arch bonding one month after surgery through Straight-Wire MBT™ technique with a 0.14" NiTi arch-wire, performing a mesial lace-back 1.2–2.2 and metal ligation on 2.2.
17. Progressive translation of the canine into the correct position in the dental arch through reactivations of elastic traction with elastic cotton threads, lace-back 1.2–2.2, metal ligatures on 2.2 and 2.4 and super elastic NiTi (0.12) upper arch.

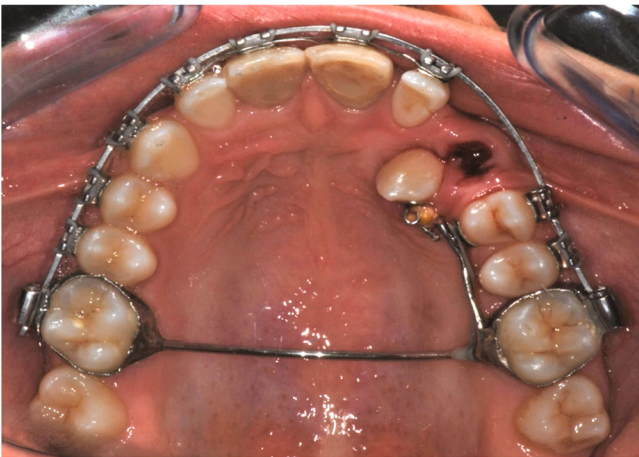


FIGURE 7: Position of 2.3 after 3 months of orthodontic traction and the extraction of deciduous 6.3.

tissue while Nd:YAG for soft tissue. Er:YAG does not show a haemostatic effect, therefore the surgical field was coagulated with Nd:YAG, ensuring bracket adhesion to enamel, and also reducing or avoiding the need for anaesthesia and reducing post-operative pain [44].

In addition, numerous studies in the literature showed the positive effect of the laser on soft tissue, leading to no post-operative pain, no discomfort, no post-operative bleed-

ing, and optimal healing by second intention through the formation of a thin, aesthetically excellent scar. In fact, patients rate the procedure as well tolerable and acceptable [45–47].

A brief review of the dosimetry and techniques used in previous clinical studies is reported in Table 3.

Studies in the literature point to some important disadvantages in the use of the other surgical alternatives, which contributed to the choice of using the diode laser. Specifically, the use of the CO₂ laser results in thermal damage and a stress effect on soft tissue cells, evident through the presence of elongated cells with fusiform nuclei devoid of nucleoli (therefore inactive), depletion of glycogen, and a reduction in the expression of immunocytochemical markers of intracellular proteins, nuclear cell cycle proliferation, and apoptosis [49]. This cellular damage is also determined following the use of the Er:YAG laser; however, it is significantly reduced, highlighting the possibility of faster healing [49, 50]. An important disadvantage of this laser, considering the importance of having a dry operating field to be able to apply the orthodontic bracket, is the absence of a coagulating effect [49, 50]. Obviously, the same disadvantage is represented using a cold-blade scalpel [37]. The Nd:YAG laser has an unsatisfactory analgesic effect and, consequently, local anaesthesia is required and the fibrous tissue is not easily removed [51]. Finally, the electrosurgical scalpel presents numerous disadvantages and risks associated with its use, from risk of burns, due to the use of

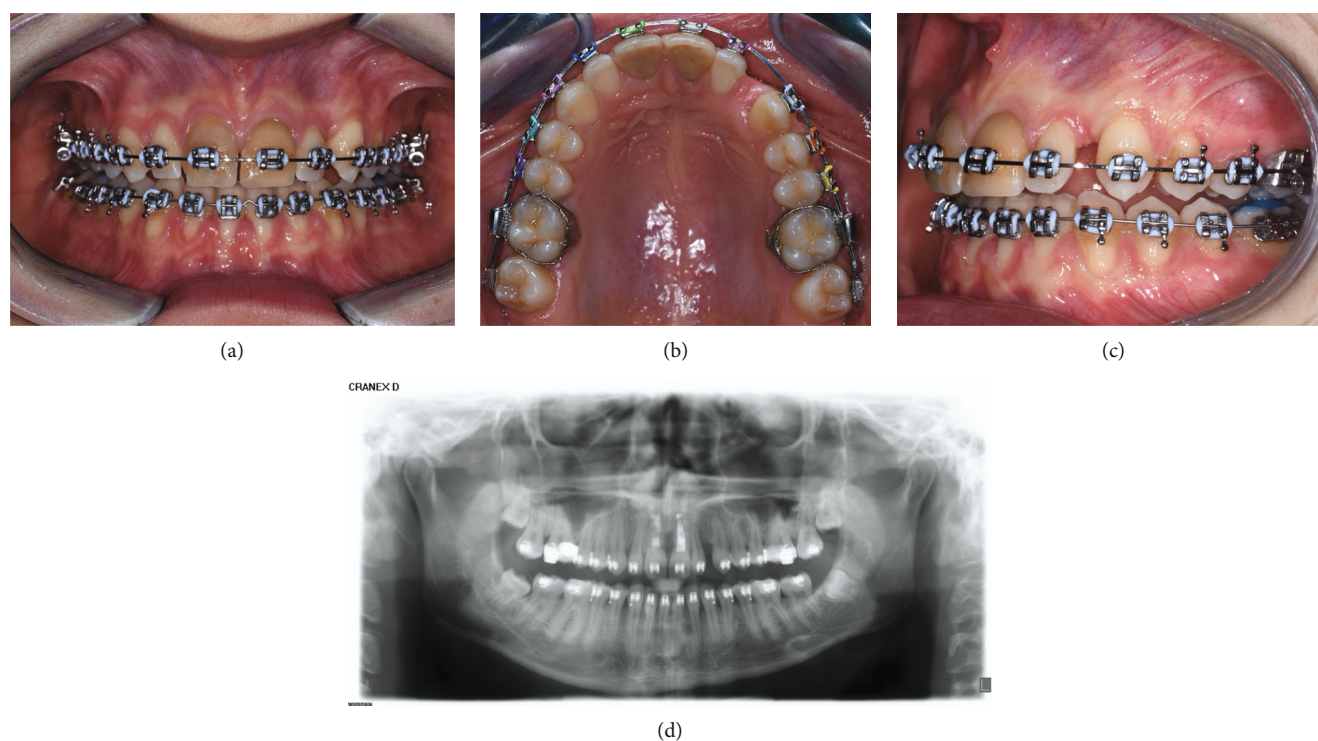


FIGURE 8: (a–c) Intraoral photo and (d) panoramic radiograph 12 month after surgical-orthodontics disinclusion. Upper canine 2.3, once included, is positioned in the dental arch.

TABLE 3: Brief review of the dosimetry and techniques used in previous clinical reports.

Authors	Laser	Mode	Power setting	Wavelength (nm)
Migliario et al. [42, 48]	Diode	Pulsed (20 s)	1.5 W	980
Impellizzeri et al. [43]	CO ₂	Superpulsed (80 Hz)	4.5 W	10,600
Fornaini et al. [44]	Nd:YAG	Superpulsed (40 Hz)	4 W	1064
	Er:YAG	Medium-short pulse (10 Hz)	300 mJ	2940
Olivi et al. [45]	Er:YAG	Superpulsed (300 μ s)	2.25–3 W	2940
Kato and Wijeyeweera [46]	CO ₂	Continuous	3 W or 4 W	10,600
Ramkumar et al. [47]	Diode	Continuous	1.5 W	940

high-frequency current, to a fire risk, due to the presence of combustible liquids or gases in the room where it is used, in an electrical risk, due to the radiated power that can disturb various medical devices applied to the patient. Furthermore, it has been shown, from a histological, histochemical, and immunocytochemical point of view, that the epithelial damage due to the use of electrocautery is higher than the epithelial damage induced using the CO₂ laser, delaying the healing of the surgical wound more [36, 52].

This study has some limitations. First, this is a case report with a short-term follow-up. More cases with long-term follow-up are needed to prove the success of this technique. Finally, we can also consider a limitation: laser equipment can involve a high investment and require a learning curve to achieve an optimal result. Based on these observations, several clinical trials are needed to evaluate the advantages and disadvantages of different laser and electrosurgery in surgical disinclusion of impacted teeth.

3. Conclusion

This case report shows how an 810 nm diode laser can be used during orthodontic treatment for dental exposure without causing post-operative pain and swelling and how it allows maintaining a dry field in order to apply an orthodontic bracket during the operation.

Data Availability

The authors confirm that the data supporting the findings of this study are available within the article.

Consent

A written informed consent was obtained from all patients before the commencement of the study.

Conflicts of Interest

The authors declare that they have no conflicts of interest.

Authors' Contributions

MCV: conceptualization, supervision, data curation, formal analysis, investigation, methodology, and project administration. MFS: conceptualization, project administration, and supervision. MGN writing—original draft. MP: writing—original draft. SF: methodology. FP: methodology. RA: investigation. MM: investigation. KB: investigation. AS: conceptualization, supervision, and writing—review and editing.

References

- [1] A. R. Chapokas, K. Almas, and G. P. Schincaglia, "The impacted maxillary canine: a proposed classification for surgical exposure," *Oral Surgery, Oral Medicine, Oral Pathology and Oral Radiology*, vol. 113, no. 2, pp. 222–228, 2012.
- [2] Y. Brorsson and J. Naoumova, "Delayed diagnosis of displaced and impacted canines—a prospective longitudinal study," *Acta Odontologica Scandinavica*, vol. 78, no. 3, pp. 165–172, 2020.
- [3] M. M. Bedoya and J. H. Park, "A review of the diagnosis and management of impacted maxillary canines," *The Journal of the American Dental Association*, vol. 140, no. 12, pp. 1485–1493, 2009.
- [4] A. K. Sajjani, "Permanent maxillary canines – review of eruption pattern and local etiological factors leading to impaction," *Journal of Investigative and Clinical Dentistry*, vol. 6, no. 1, pp. 1–7, 2015.
- [5] A. Becker and S. Chaushu, "Etiology of maxillary canine impaction: a review," *American Journal of Orthodontics and Dentofacial Orthopedics*, vol. 148, no. 4, pp. 557–567, 2015.
- [6] M. de Oliveira Ribas, W. D. Martins, M. H. de Sousa et al., "Oral and maxillofacial manifestations of familial adenomatous polyposis (Gardner's syndrome): a report of two cases," *The Journal of Contemporary Dental Practice*, vol. 10, no. 1, pp. 82–90, 2009.
- [7] G. R. Bayar, K. Ortakoglu, and M. Sencimen, "Multiple impacted teeth: report of 3 cases," *European Journal of Dentistry*, vol. 2, no. 1, pp. 73–78, 2008.
- [8] P. M. Campeau, G. M. Lenk, J. T. Lu et al., "Yunis–Varon syndrome is caused by mutations in FIG4, encoding a phosphoinositide phosphatase," *American Journal of Human Genetics*, vol. 92, no. 5, pp. 781–791, 2013.
- [9] C. L. Antunes, A. M. Aranha, M. C. Bandeca et al., "Eruption of impacted teeth in cleft lip and palate patients following alveolar bone graft," *The Journal of Contemporary Dental Practice*, vol. 19, no. 9, pp. 1072–1075, 2018.
- [10] S. Sambataro, S. Bocchieri, G. Cervino et al., "Correlations between malocclusion and postural anomalies in children with mixed dentition," *Journal of Functional Morphology Kinesiology*, vol. 4, no. 3, p. 45, 2019.
- [11] A. Alqerban, A. S. Storms, M. Voet, S. Fieuws, and G. Willems, "Early prediction of maxillary canine impaction," *Dentomaxillofacial Radiology*, vol. 45, no. 3, p. 20150232, 2016.
- [12] R. M. Cruz, "Orthodontic traction of impacted canines: concepts and clinical application," *Dental Press Journal of Orthodontics*, vol. 24, no. 1, pp. 74–87, 2019.
- [13] I. Izadikhah, D. Cao, Z. Zhao, and B. Yan, "Different management approaches in impacted maxillary canines: an overview on current trends and literature," *The Journal of Contemporary Dental Practice*, vol. 21, no. 3, pp. 326–336, 2020.
- [14] J. Hecht, "A short history of laser development," *Applied Optics*, vol. 49, no. 25, pp. F99–F122, 2010.
- [15] V. Heiskanen and M. R. Hamblin, "Correction: photobiomodulation: lasers vs. light emitting diodes?," *Photochemical & Photobiological Sciences*, vol. 18, no. 1, p. 259, 2019.
- [16] L. C. Martens, "Laser physics and a review of laser applications in dentistry for children," *European Archives of Paediatric Dentistry*, vol. 12, no. 2, pp. 61–67, 2011.
- [17] A. Romano, D. di Stasio, D. Lauritano et al., "Topical photodynamic therapy in the treatment of benign oral mucosal lesions: a systematic review," *Journal of Oral Pathology & Medicine*, vol. 50, no. 7, pp. 639–648, 2021.
- [18] A. Romano, D. di Stasio, E. Gentile, M. Petruzzi, R. Serpico, and A. Lucchese, "The potential role of photodynamic therapy in oral premalignant and malignant lesions: a systematic review," *Journal of Oral Pathology & Medicine*, vol. 50, no. 4, pp. 333–344, 2021.
- [19] R. Hanna and S. Parker, "The advantages of carbon dioxide laser applications in paediatric oral surgery. A prospective cohort study," *Lasers in Medical Science*, vol. 31, no. 8, pp. 1527–1536, 2016.
- [20] J. H. Ahn, S. Power, and E. Thickett, "Application of the diode laser for soft-tissue surgery in orthodontics: case series," *Journal of Orthodontics*, vol. 48, no. 1, pp. 82–87, 2021.
- [21] S. Nammour, "Laser dentistry, current advantages, and limits," *Photomedicine and Laser Surgery*, vol. 30, no. 1, pp. 1–4, 2012.
- [22] E. F. Sant'Anna, M. T. Araújo, L. I. Nojima, A. C. Cunha, B. L. Silveira, and M. Marquezan, "High-intensity laser application in Orthodontics," *Journal of Orthodontics*, vol. 22, no. 6, pp. 99–109, 2017.
- [23] E. Sutter, B. Giacomelli-Hiestand, M. Rücker, and S. Valdec, "CO₂ laser application in stomatology," *Swiss Dental Journal*, vol. 129, no. 3, pp. 214–215, 2019.
- [24] Y. Saydjari, T. Kuypers, and N. Gutknecht, "Laser application in dentistry: irradiation effects of Nd:YAG 1064 nm and diode 810 nm and 980 nm in infected root canals—a literature overview," *BioMed Research International*, vol. 2016, 10 pages, 2016.
- [25] A. Scribante, S. Gallo, M. Pascadopoli et al., "Management of periodontal disease with adjunctive therapy with ozone and photobiomodulation (PBM): a randomized clinical trial," *Photonics*, vol. 9, no. 3, p. 138, 2022.
- [26] C. de Paula Eduardo, P. M. de Freitas, M. Esteves-Oliveira et al., "Laser phototherapy in the treatment of periodontal disease. A review," *Lasers in Medical Science*, vol. 25, no. 6, pp. 781–792, 2010.
- [27] R. Fekrazad, S. Alimazandarani, K. A. Kalthori, H. Assadian, and S. M. Mirmohammadi, "Comparison of laser and power bleaching techniques in tooth color change," *Journal of Clinical and Experimental Dentistry*, vol. 9, no. 4, pp. e511–e515, 2017.
- [28] K. K. Gandhi, R. Pavaskar, E. G. Cappetta, and H. J. Drew, "Effectiveness of adjunctive use of low-level laser therapy and photodynamic therapy after scaling and root planing in patients with chronic periodontitis," *The International Journal of Periodontics & Restorative Dentistry*, vol. 39, no. 6, pp. 837–843, 2019.

- [29] G. Olivi, M. D. Genovese, and C. Caprioglio, "Evidence-based dentistry on laser paediatric dentistry: review and outlook," *European Journal of Paediatric Dentistry*, vol. 10, no. 1, pp. 29–40, 2009.
- [30] D. Ortega-Concepcion, J. Cano-Duran, J. Peña-Cardelles, V. Paredes-Rodriguez, J. Gonzalez-Serrano, and J. Lopez-Quiles, "The application of diode laser in the treatment of oral soft tissues lesions. A literature review," *Dentistry*, vol. 9, no. 7, pp. e925–e928, 2017.
- [31] M. F. Sfondrini, G. Calderoni, M. C. Vitale, P. Gandini, and A. Scribante, "Is laser conditioning a valid alternative to conventional etching for aesthetic brackets?," *European Journal of Paediatric Dentistry*, vol. 19, no. 1, pp. 61–66, 2018.
- [32] M. F. Sfondrini, M. C. Vitale, A. L. B. Pinheiro et al., "Photobiomodulation and pain reduction in patients requiring orthodontic band application: randomized clinical trial," *BioMed Research International*, vol. 2020, 2020.
- [33] S. Tortorici, P. Messina, and G. A. Scardina, "Effectiveness of low-level laser therapy on pain intensity after lower third molar extraction," *International Journal of Clinical Dentistry*, vol. 12, no. 4, pp. 357–367, 2019.
- [34] G. A. Scardina, S. Casella, G. Bilello, and P. Messina, "Photobiomodulation therapy in the management of burning mouth syndrome: morphological variations in the capillary bed," *Dentistry Journal*, vol. 8, no. 3, p. 99, 2020.
- [35] D. E. S. Malik, M. Fida, and R. H. Sukhia, "Correlation between radiographic parameters for the prediction of palatally impacted maxillary canines," *Journal of Orthodontics*, vol. 46, no. 1, pp. 6–13, 2019.
- [36] S. L. Soon and C. V. Washington, "Electrosurgery, electrocoagulation, electrofulguration, electrodesiccation, electrosection, electrocautery," in *Surgery of the Skin*, J. K. Robinson, C. W. Hanke, and D. M. Siegel, Eds., vol. 9pp. 177–190, Elsevier, New York, 2nd edition edition, 2010.
- [37] D. O. Eyarefe, D. I. Kuforiji, T. A. Jarikre, and B. O. Emikpe, "Enhanced electroscalpel incisional wound healing potential of honey in Wistar rats," *International Journal of Veterinary Science and Medicine*, vol. 5, no. 2, pp. 128–134, 2017.
- [38] C. Sweeney, "Laser safety in dentistry," *General Dentistry*, vol. 56, no. 7, pp. 653–659, 2008.
- [39] N. Akbulut, E. S. Kursun, M. K. Tumer, K. Kamburoglu, and U. Gulsen, "Is the 810-nm diode laser the best choice in oral soft tissue therapy?," *European Journal of Dentistry*, vol. 7, no. 2, pp. 207–211, 2013.
- [40] M. F. Sfondrini, V. Cacciafesta, A. Scribante, M. De Angelis, and C. Klersy, "Effect of blood contamination on shear bond strength of brackets bonded with conventional and self-etching primers," *American Journal of Orthodontics and Dentofacial Orthopedics*, vol. 125, no. 3, pp. 357–360, 2004.
- [41] R. A. Musstaf, D. F. L. Jenkins, and A. N. Jha, "Assessing the impact of low level laser therapy (LLL) on biological systems: a review," *International Journal of Radiation Biology*, vol. 95, no. 2, pp. 120–143, 2019.
- [42] M. Migliario, M. Rizzi, A. G. Lucchina, and F. Renò, "Diode laser clinical efficacy and mini-invasivity in surgical exposure of impacted teeth," *Journal of Craniofacial Surgery*, vol. 27, no. 8, pp. e779–e784, 2016.
- [43] A. Impellizzeri, M. Horodynski, E. Serritella et al., "Uncovering and autonomous eruption of palatally impacted canines—a case report," *Dentistry Journal*, vol. 9, no. 6, p. 66, 2021.
- [44] C. Fornaini, E. Merigo, P. Vescovi, G. Lagori, and J. Rocca, "Use of laser in orthodontics: applications and perspectives," *Laser Therapy*, vol. 22, no. 2, pp. 115–124, 2013.
- [45] M. Olivi, M. D. Genovese, and G. Olivi, "Laser labial frenectomy: a simplified and predictable technique. Retrospective clinical study," *European Journal of Paediatric Dentistry*, vol. 19, no. 1, pp. 56–60, 2018.
- [46] J. Kato and R. L. Wijeyeweera, "The effect of CO₂ laser irradiation on oral soft tissue problems in children in Sri Lanka," *Photomedicine and Laser Surgery*, vol. 25, no. 4, pp. 264–268, 2007.
- [47] S. Ramkumar, L. Ramkumar, N. Malathi, and R. Suganya, "Excision of mucocele using diode laser in lower lip," *Case Reports in Dentistry*, vol. 2016, 4 pages, 2016.
- [48] M. Migliario, L. A. Greco, V. Rocchetti, and F. Renò, "Laser surgical approach to impacted maxillary incisors: case series and brief review," *European Review for Medical and Pharmaceutical Sciences*, vol. 23, no. 22, pp. 9691–9696, 2019.
- [49] D. Zaffe, M. C. Vitale, A. Martignone, F. Scarpelli, and A. R. Botticelli, "Morphological, histochemical, and immunocytochemical study of CO₂ and Er:YAG laser effect on oral soft tissues," *Photomedicine and Laser Surgery*, vol. 22, no. 3, pp. 185–189, 2004.
- [50] G. L. Sfasciotti, F. Zara, I. Voza, V. Carocci, G. Ierardo, and A. Polimeni, "Diode versus CO₂ laser therapy in the treatment of high labial frenulum attachment: a pilot randomized, double-blinded clinical trial," *International Journal of Environmental Research and Public Health*, vol. 17, no. 21, p. 7708, 2020.
- [51] I. Giovannacci, G. Mergoni, M. Meleti et al., "Postoperative discomfort in oral soft tissue surgery: a comparative perspective evaluation of Nd:YAG laser, quantum molecular resonance scalpel and cold blade," *Minerva Stomatologica*, vol. 64, no. 1, pp. 9–20, 2015.
- [52] M. C. Vitale, A. R. Botticelli, D. Zaffe et al., "CO₂ laser biopsies of oral mucosa: an immunocytological and histological comparative study," *Lasers in Dentistry VII*, vol. 4249, pp. 139–144, 2001.