

## Inherited paediatric neurometabolic disorders, can brain magnetic resonance imaging predict?

Ali Al Orf, MBBS, JBR, Khawaja B. Waheed, MBBS, FCPS, Elsayed M. Ali, MBBS, FRCPI, Abdulrahim K. Muhammad, MBBS, MRCPC, Faisal M. Al Zabrani, MBBS, KFUF, Saad A. Seth, MBBS, FCPS, Nawaf N. Al Jubair, MBBS, SB-RAD, Hassan S. Harisi, GCSE, BSc, Zechariah J. Arulanantham, MSc, PhD.

### ABSTRACT

**الأهداف:** لتقييم القدرة التشخيصية للتصوير بالرنين المغناطيسي (MRI) في الكشف عن الاضطرابات العصبية الاستقلابية الموروثة.

**المنهجية:** أجريت هذه الدراسة الاسترجاعية في قسم الأشعة في مستشفى الظهران خلال الفترة من يناير 2013م إلى يناير 2020م. قمنا بتقييم صور التصوير بالرنين المغناطيسي لأطفال (أقل من 5 سنوات) الذين تمت إحالتهم إلى طب أعصاب الأطفال للاشتباه السريري في تأخر النمو العصبي والتمثيل الغذائي. تم استبعاد حالات إقفار الفترة المحيطة بالولادة وصددمات الولادة المعروفة. تضمنت معايير التصوير ما يلي: (i) شذوذ إشارة المادة البيضاء المتناظرة الثنائية، (ii) تقبيد الانتشار الذي يؤثر على النوى الرمادية العميقة الثنائية مع أو بدون مشاركة جذع الدماغ، (iii) ضمور الدماغ أو الوذمة مع إشارة غير طبيعية للمادة البيضاء، (iv) الكشف الطيفي المميز بالرنين المغناطيسي. كان وجود أي من هذه النتائج يعتبر إيجابياً لمرض الاستقلاب العصبي. قام اثنان من أخصائي الأشعة العصبية بتفسير التصوير بالرنين المغناطيسي باتفاق كبير بين المراقبين. تم تأكيد التشخيصات على الفحص البيوكيميائي / الاستقلابي والاختبارات الجينية. استخدم جدول طوارئ 2x2 للنتائج واستخدم اختبار مربع كاي لتحديد الارتباط.

**النتائج:** من أصل 133 حالة، وجد أن 72 (49 ذكور، 90% AR) يعانون من اضطرابات استقلابية عصبية. تم حساب الحساسية والنوعية والقيم التنبؤية الإيجابية والسلبية على أنها 81.94% فترة الثقة (71.11-90.02)، 67.21% فترة الثقة (54.00-78.69)، و74.68% فترة الثقة (66.96-81.1) و75.93% فترة الثقة (65.16-84.17) على التوالي. تم العثور على نتائج مهمة (القيمة الاحتمالية = 0.0001).

**الخلاصة:** يمكن أن يساعد التصوير بالرنين المغناطيسي للدماغ في التنبؤ باضطرابات التمثيل الغذائي العصبية الموروثة مع الأخذ في الاعتبار بعض النتائج.

**Objectives:** To evaluate diagnostic capability of brain magnetic resonance imaging (MRI) in detection of inherited neurometabolic disorders.

**Methods:** This retrospective observational study was performed in Radiology Department at our Hospital in Dhahran, from January 2013 to January 2020. We evaluated brain MRIs of children (under 5) who were referred to pediatric neurology for clinical suspicion of neuro-developmental delay and metabolic disease. Known perinatal ischemia and birth trauma cases were excluded. Imaging criteria included: (i) bilateral symmetric white matter signal abnormality, (ii) diffusion restriction affecting bilateral deep grey nuclei with or without brainstem involvement, (iii) brain atrophy or edema with abnormal white matter signal, (iv) characteristic MR spectroscopic finding. Presence of any one of these findings was considered positive for neurometabolic disease. Two neuroradiologists interpreted MRIs with substantial interobserver agreement. Diagnoses were confirmed on biochemical/ metabolic screening and genetic testing. A 2 x 2 contingency table was used for results. Chi square test was used to determine association.

**Results:** Out of 133 cases, 72 (49 males, 90% AR) were found to have neurometabolic disorders. Sensitivity, specificity, positive and negative predictive values were calculated as 81.94% (CI, 71.11-90.02), 67.21% (CI, 54.00-78.69), 74.68% (CI, 66.96-81.11) and 75.93% (CI, 65.16-84.17) respectively. Findings were found significant ( $p$ -value=0.0001).

**Conclusion:** Brain MRI can help to predict inherited neurometabolic disorders considering certain findings.

*Neurosciences 2020; Vol. 25 (5): 392-398*  
*doi: 10.17712/nsj.2020.5.20200072*

From the Department of Radiology Department (Al Orf, Waheed, Al Zabrani, Al Jubair, Harisi), from the Department of Paediatric Neurology (Ali, Mubammad, Seth), King Fahad Military Medical Complex, Deanship of Post-graduate and Research (VDPR) (Arulanantham), Dhahran, Kingdom of Saudi Arabia

Received 13th May 2020. Accepted 15th July 2020.

Address correspondence and reprint request to: Dr. Khawaja B. Waheed, Department of Radiology, Dhahran, Kingdom of Saudi Arabia.  
E-mail: khawaja@kfmmc.med.sa  
ORCID ID: <https://orcid.org/0000-0001-6340-3139>

Metabolic diseases can be either inherited (inborn errors of metabolism) or acquired. Inborn errors of metabolism (IEMs) that primarily affect the central nervous system are referred to as neurometabolic diseases, and usually occur in neonates and infants.<sup>1</sup> These diseases involve genetic defects that result in certain enzyme deficiency leading to deficiency of essential metabolite or toxic accumulation of others with specific biochemical and molecular abnormalities. Clinical presentations may be confusing and potentially lead to delay in diagnosis and treatment.<sup>2</sup> Overall incidence of this group of disorders may vary from region to region, being much higher in communities with consanguineous marriages, ranging from 1.2 to 2 per 100,000 live births.<sup>3</sup> Most exhibit autosomal recessive (AR) mode of inheritance. Neurometabolic disorders can be classified by various methods based on clinical and biochemical characteristics, area of brain involvement, or cellular organelle.<sup>4</sup> Imaging based classification includes leukodystrophy (primary involvement of white matter due to genetic abnormality), leukoencephalopathy (secondary involvement of white matter either due to genetic or acquired systemic disorder), poliodystrophy (predominant involvement of grey matter), and pandydytroph (mixed involvement of both white and grey matter).<sup>5</sup> Central nervous system white matter is usually affected,<sup>6</sup> and can result from various pathologic process like delayed myelination (myelin maturation delayed for expected age), hypomyelination (scarcity of myelin or arrest in myelination process), dysmyelination (deposition of abnormally composed fragile myelin), demyelination (secondary loss of myelin that may have been previously normal) and myelinopathy (vacuolating due to deranged brain iron and water hemostasis).

Magnetic resonance imaging is the modality of choice for evaluation of neurometabolic disorders.<sup>7</sup> Analyzing pattern recognition in MR imaging and clinical clues help to narrow the differential, tailor subsequent laboratory (targeted metabolomics) or genetic investigations (either requiring single gene testing or broad-spectrum genetic testing i.e., whole exome sequencing/ WES).<sup>4</sup> The MRI can be helpful in diagnostic workup of various diseases and may be decisive for early management even before arrival of costly and time-consuming biochemical or genetic testing results.<sup>8</sup> We therefore sought to highlight ability of MRI in predicting diagnoses of inherited

neurometabolic disorders in neonates and young children considering certain MRI findings.

**Methods.** A retrospective observational study was performed in Radiology Department at our Hospital in Dhahran, evaluating MR brain imaging data of children (under 5 years of ages) with clinical suspicion of neurodevelopmental delay and metabolic disease, either consulted for or referred to pediatric neurology between January 2013 to January 2020 (a period of 7 years). Children with prior histories of perinatal ischemia or stroke, hypoxic-ischemic encephalopathy (HIE), birth trauma or accident, or known systemic diseases (congenital heart disease, renal failure, autoimmune disorders) were excluded.

Clinical information was obtained from patients' files/ charts using Hospital Information System (HIS) and MR imaging findings were retrieved from Radiology Information System/ Picture Archiving and Communication System (RIS/ PACS). Research protocol was approved from the Hospital Ethic Committee and need for informed written consents was waived off considering retrospective study and non-disclosure of patients' information. The study was conducted in accordance with the Helsinki Declaration. All information was kept strictly confidential. Literature review was performed through electronic search (Google Scholar, PubMed).

All MRI brain scans were performed on a 1.5 T machine, and routine imaging included T1W (T1-Weighted) axial (Ax.) and sagittal (Sag.) Fast Spin Echo (FSE) sequences, Ax. T2WI (T2-Weighted Imaging), Ax. FLAIR (Fluid Attenuation and Inversion Recovery), DWI (Diffusion Weighted Imaging) and ADC (Apparent Diffusion Coefficient), SWAN (Susceptibility Weighted imaging), postcontrast T1WI (where needed), and (single voxel) MRSI (Magnetic Resonance Spectroscopic Imaging) where possible. Oral sedation was given in majority of children for the MRIs. Only few children with concomitant respiratory failures or difficult airways, and children with skeletal deformities were given general anesthesia.

Imaging criteria suggestive of neurometabolic

**Table 1 -** MRI findings in neurometabolic disorders.

MRI findings	Neurometabolic Disorder (Metabolic & Genetic testing)		Total
	Positive	Negative	
Positive	59 (74.7)	20 (25.3)	79 (100)
Negative	13 (24.1)	41 (75.9)	54 (100)
Total	72 (54.1)	61 (45.9)	133 (100)

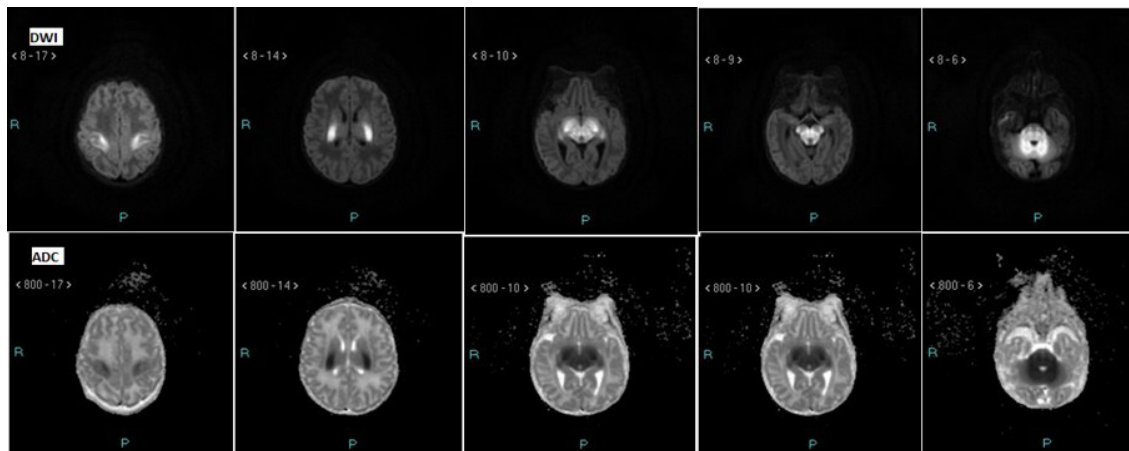
Chi square = 33.09, *p*-value=0.0001

**Disclosure.** Authors have no conflict of interests, and the work was not supported or funded by any drug company.

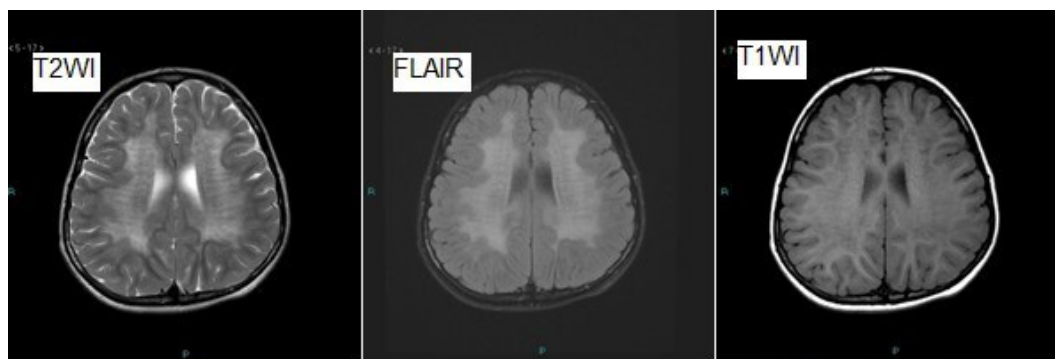
diseases on MRIs included: (i) bilateral symmetric confluent abnormal white matter (subcortical, centrum semiovale, or periventricular) signal intensity as seen on T2 and FLAIR (with or without diffusion restriction, blood foci or cystic changes), (ii) altered signal or diffusion restriction affecting bilateral deep grey nuclei (basal ganglia, thalami, dentate, fastigial nuclei, substantia nigra, red nuclei) with or without brainstem involvement, (iii) brain tissue volume loss or edema with abnormal white matter signal intensity, (iv) characteristic MR spectroscopic finding (if available and conclusive). Presence of any one of these findings was considered positive for neurometabolic diseases. Two experienced neuro-radiologists, who were unknown to biochemical or genetic results, evaluated the MRI findings with substantial inter-observer agreement (Cohen's Kappa, 0.81). Initial or first imaging findings, if found abnormal, were considered ample for diagnoses. However, in few cases of equivocal MRIs of

children under one year, follow up MRIs preferably at 12 and 24-month interval respectively were assessed to document abnormal, delayed, or arrested myelination.

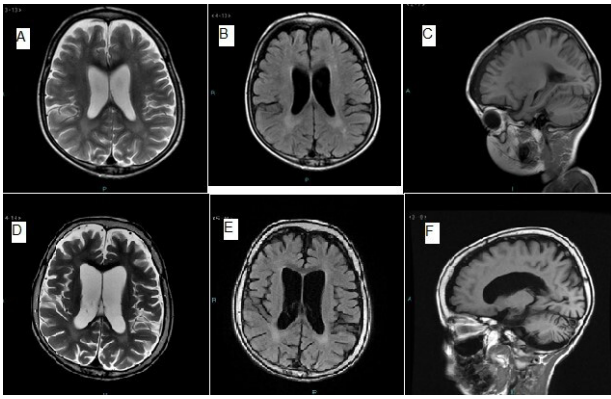
Diagnoses were confirmed on biochemical (metabolic) screening and genetic testing (WES, Whole Exome Sequencing) that were considered gold standard. Brain MRI was considered 'positive' and 'negative' for presence and absence of positive findings, respectively. Outcomes of brain MRI findings were categorized as TP (True Positive; MRI correctly diagnosed neurometabolic disorder), TN (True Negative; MRI correctly diagnosed absence of neurometabolic disorder), FP (False Positive; MRI incorrectly diagnosed neurometabolic disorder) and FN (False Negative; MRI incorrectly diagnosed absence of neurometabolic disorder). A 2 x 2 contingency table was used to represent the outcomes. All data of patients, including MRI brain studies and final diagnoses, was collected, and analyzed on Statistical Package for Social Sciences (SPSS, version



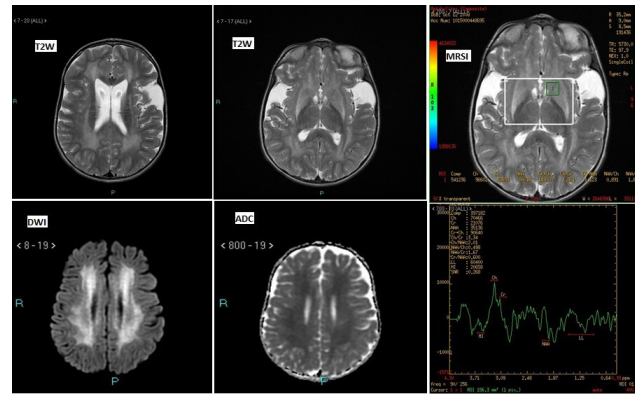
**Figure 1** - Selected brain MRI images of Maple Syrup Urine Disease (MSUD) demonstrating diffusion restriction along bilateral perirolandic white matter, posterior limb internal capsule, thalami, brainstem, and cerebellum as evident by abnormal high (bright or white) signal on DWI (upper row) and low (dark or black) signal on ADC (bottom row).



**Figure 2** - A case of Metachromatic Leukodystrophy (MLD) with MR images showing low T1, high T2 and FLAIR periventricular white matter signal abnormality (tigroid appearance), attributed to both widened perivascular spaces and abnormal white matter.



**Figure 3** - A case of Neuronal Ceroid Lipofuscinosis (NCL), with upper row images A (axial T2WI), B (Axial FLAIR) and C (Sagittal T1WI) and similar sequence images in down row 1.5 years apart, showing interval progressive loss of brain tissue and prominent cerebellar atrophy, besides abnormal high signal of periventricular white matter.



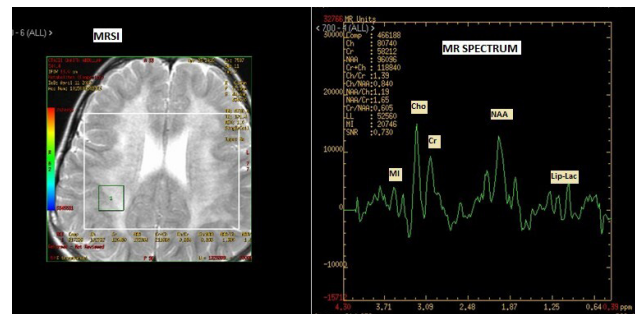
**Figure 4** - Selected MRI images in child with Glutaric aciduria showing abnormal T2W periventricular high signal (upper row left corner image) with relatively smaller basal ganglia and widened sylvian fissures and anterior temporal pole extra-axial CSF spaces (upper row middle image), diffusion restriction along periventricular white matter (bottom row left corner and middle images). MR spectroscopic imaging (MRSI) with region of interest (at left basal ganglia as shown in upper row right corner image) and peaks of metabolites (decreased NAA/Cr, increased lactate) in spectroscopic image (bottom row right corner image).

22). Sensitivity, specificity, positive predictive value (PPV) and negative predictive value (NPV) for MRI were determined, and confidence intervals (C.I) documented. Chi-square test was used, and P-value was calculated. A *p*-value less than 0.05 was considered significant.

**Results.** Out of 133 cases (95 males, 38 females), 72 (49 males, 23 females) were found to have neurometabolic disorders on metabolic and genetic screening. Most of these cases were autosomal recessive ( $n=65$  cases, 90.2%), while 3 were X-linked and 4 showed autosomal dominant (AD) inheritance.

Frequency of various categories of diagnosed neurometabolic disorders were as follows: 24 cases of protein metabolism (11 organic acidurias, 8 urea cycle defects, 5 aminoacidopathies including MSUD, phenylketonuria, and homocystinuria), 9 cases of carbohydrate metabolism (G6PD, galactosemia), 4 cases of fatty acid oxidation, 9 cases of peroxisomal disorders (Zellweger, Adrenoleukodystrophy), 1 case of cholesterol metabolism (Niemann-Pick), 20 cases of lysosomal disorders (Tay-Sachs, Mucopolysaccharidoses/ MPS, metachromatic leukodystrophy/ MLD, neuronal ceroid lipofuscinosis/ NCL), 2 cases of mitochondrial disorders (Leighs syndrome), and 3 cases under miscellaneous group (purine and pyrimidine metabolism). Few of the inherited metabolic disorders, though not primarily neurometabolic, like G6PD, galactosemia and Niemann-Pick were also considered due to their profound central nervous system manifestations.

Diagnoses of disorders of protein metabolism (organic acidurias, urea cycle defects, aminoacidopathies), fatty acid disorders, peroxisomal and lysosomal disorders



**Figure 5** - MR spectroscopic imaging (left image) in a case of Metachromatic Leukodystrophy (MLD) showing reduced NAA, increased Cho/Cr ratio and lip-lactate peaks in MR spectroscopic image (right image).

were established on biochemical/ metabolic screening. However, genetic testing further confirmed diagnoses for lysosomal, mitochondrial and miscellaneous disorders.

Outcomes of MRI findings were documented under 2 x 2 contingency table (Table 1).

Out of 133 cases, 72 were found to have neurometabolic disorders. Sensitivity, specificity, positive and negative predictive values were calculated as 81.94% (CI, 71.11-90.02), 67.21% (CI, 54.00-78.69), 74.68% (CI, 66.96-81.11) and 75.93% (CI, 65.16-84.17) respectively. Findings were found significant ( $p$ -value=0.0001).

Electroencephalogram (EEG) findings were seen abnormal in 31 out of 72 positive cases of neurometabolic

**Table 2 -** The MRI pattern and specific imaging findings in neurometabolic diseases and other inherited metabolic disorders with profound CNS manifestations.

Neurometabolic Disorders & other Inherited Metabolic disorders (with profound CNS manifestations)		Inheritance	Brain Magnetic Resonance Imaging Findings	Magnetic Resonance Spectroscopy
Disorders of Protein metabolism	Organic aciduria (glutaric aciduria)	AR	Bilateral basal ganglia lesions with restricted diffusion during acute encephalopathy, cerebral dysgenesis (enlarged Sylvian fissures, wide CSF spaces anterior to the temporal poles), macrocephaly	Decreased N-acetyl-aspartate (NAA)/ creatine (Cr) ratio, lactate peak within basal ganglia acutely
	Urea cycle defect (Citrullinemia)	AR	White matter edema as result of hyperammonemia, basal ganglia involvement	Prominent increase of glutamine/ glutamate and lipid/lactate complexes, decrease of NAA
	Aminoacidopathy (MSUD)	AR	Vacuolating myelinopathy (intramyelinic edema), edematous lesions with restricted diffusion in the peri-rolandic white matter, posterior limb of the internal capsules, cerebral peduncles, brainstem, deep cerebellar white matter, and globi pallidi	Decreased N-acetylaspartate, methyl resonances of branched amino acids at 0.9–1.0 ppm, and lactate in acute metabolic decompensation
Carbohydrate metabolism	Galactosemia	AR	Diffuse edema, diffusion restriction	Galactitol (Gal-ol) doublet peak at 3.7 parts per million
	G6PD deficiency	X-linked	Symmetrical lesions in bilateral globus pallidus, hyperintense on T2/FLAIR	Kernicterus; increased levels of glutamine and glutamate along with decreased levels of choline and N-acetyl-aspartate
Fatty Acid Oxidation Disorder	Carnitine deficiency, Acyl-Coenzyme Dehydrogenase Deficiency, glutaric aciduria type 2	AR	Underdeveloped frontal and temporal lobes with enlarged sylvian fissures, delayed myelination, Multifocal parenchymal and intraventricular hemorrhages as well as white matter signal intensity changes	Normal N-acetylaspartate and an increased choline-creatine ratio
Peroxisomal disorders	Adrenoleukodystrophy (ALD)	X-linked	Deep white matter in the parieto-occipital lobes and splenium of the corpus callosum, cortical and subcortical U-fiber sparing, enhancement in 50%	Neuronal loss manifested by a decrease in the NAA peak and an elevation in the lactate peak
	Zellweger Syndrome	AR	Ventricular enlargement, abnormal gyration patterns (pachygyria; especially medial gyri around peri-rolandic regions, polymicrogyria; laterally), cerebral periventricular pseudocysts	Nonspecific reduction of N-acetylaspartate with lipid accumulation
Lysosomal disorders	Mucopolysaccharidosis	AR (except Hunter, MP-II; X-linked)	Enlarged perivascular spaces (“cribriform” or “spindle-like”), white matter lesions, hydrocephalus, cortical atrophy, ‘honeycomb-like’ appearance in the basal ganglia and thalami	Decreased N-acetylaspartate, total choline and glutamate in the white matter, and an elevation of myo-inositol, glucose-aminoglycans (GAG) peak at 3.7 ppm (higher than myoinositol)
	Metachromatic Leucodystrophy (MLD)	AR	Bilateral symmetrical abnormal high SI on T2 and FLAIR images in the deep periventricular white matter, with sparing of the subcortical U fibers and peripheral “tigroid” or “leopard pattern” of dysmyelination	Reduced N-acetyl aspartate (NAA), increased myoinositol, increased lactate
	Krabbe disease (Globoid cell Leucodystrophy)	AR	High signal involving periventricular white matter, centrum semiovale and deep grey matter, sparing of subcortical U-fibres	Markedly reduced NAA, Abnormally high Cho/Cr ratio
Mitochondrial Disorders	Neuronal Ceroid Lipofuscinosis (NCL)	AR	Generalized brain atrophy and hyperintense white matter changes	Reduced NAA, elevated lipids
	Leigh Syndrome	AR, X-linked	Symmetrical hyperintense lesions in the basal ganglia and/or brain stem on T2-weighted MR images	Elevated choline, occasionally elevated lactate, reduced NAA
Disorders of purine and pyrimidine metabolism	Lesch-Nyhan disease	X-linked	Decreased cerebral volume with a predilection for white matter, cortical and/or brainstem atrophy	Decreased metabolites, especially N-acetylaspartate and glutamate/glutamine, only in the prefrontal cortex

disorders and 15 out of 61 negative cases ( $p=0.03$ ).

Specific MRI findings and patterns of involvement of brain parenchyma with characteristic MR spectroscopic imaging (MRSI) were seen in different cases of our study (Table 2).

**Discussion.** Magnetic resonance imaging is the modality of choice for evaluation of neurometabolic disorders. Although imaging appearances may overlap and often vary with stage and age of presentation.<sup>7</sup> However, many of such disorders demonstrate specific MRI abnormalities.<sup>9</sup> We therefore devised certain set of imaging findings that could help in predicting such challenging group of disorders.<sup>3,8</sup> Based on our imaging criteria, we found a high sensitivity of MRI (around 80%) in prediction of inherited neurometabolic disorders with a high negative predictive value (of 76%). Our study was based on the rationale that recognizing specific pattern of abnormality on MRI can aid the radiologists in narrowing differential and even suggesting specific diagnosis, thereby reducing length of diagnostic process and a timely management for a treatable disorder. Timing of any therapeutic intervention is of strategic importance considering limited regenerative capacity of the brain.<sup>4</sup> By adopting our selected imaging criteria, we were able to suggest metabolic diseases like glutaric aciduria, MSUD (Figure 1), adrenoleukodystrophies, urea cycle defects, MLD (Figure 2), and NCL (Figure 3).

Although MR spectroscopic imaging was not available in every case, however, when available and characteristic (Figure 4&5), such information also helped in suggesting such disorder.

We observed several false positive cases ( $n=20$ ) that were attributed to other diagnoses mimicking IEM<sup>10</sup> including (not known or unclear history of) HIE (5 cases), kernicterus/ bilirubin encephalopathy (5 cases), neonatal hypoglycemia (3 cases), toxic encephalopathy (3 cases), and perinatal infection (4 cases). Many acquired conditions like periventricular leukoencephalopathy, inflammatory or infectious diseases, acquired metabolic disorders with nutritional deficiencies can also present with similar findings.<sup>7</sup> For e.g., nonketotic hyperglycemia, primary lactic acidosis, Krabbe disease, and MSUD may have similar MR findings as those of hypoxic ischemic encephalopathy.<sup>5,7</sup>

Lack of perinatal ischemia and a delayed manifestation should raise suspicion of possible metabolic disorder. Similarly, any metabolic disease with brain atrophy and subdural hemorrhage may mimic NAI (non-accidental injury) or child abuse. Therefore, combining clinical and laboratory data when available with the imaging features is important. Utilization of DWI, and MRSI may help to narrow the diagnoses.<sup>3,10</sup> Serial imaging can

also help to differentiate IEM mimickers that tend to remain stable or improve on follow up imaging, unlike IEM that typically are progressive.

False negative cases ( $n=13$ ) encountered in our study were because of presence of certain non-specific MRI findings (like unilateral involvement, calcification, cortical grey matter involvement or malformation) that were not included in our imaging criteria for detection of neurometabolic disorders. White matter is commonly involved in neurometabolic disorders, either primarily or because of Wallerian degeneration.<sup>11</sup> However, certain metabolic disorders can present with grey matter abnormality or cortical malformation. Although conventional MR sequences including T1, T2W and FLAIR help to detect adequate or abnormal/delayed myelination process particularly under 2 years of ages. However, these can be supplemented with microstructural data as assessed by diffusion weighted imaging (DWI) and metabolic data (biochemical signatures) from proton MR spectroscopy.<sup>12</sup>

The DWI may demonstrate early parenchymal lesions and helps to differentiate different types of edema. Vasogenic edema is commonly seen in acute metabolic decompensation (prominent in urea cycle defects), while cytotoxic edema may be seen in non-ischemic conditions (during metabolic crisis in organic acidemias and vacuolating myelinopathy). Similarly, certain metabolite information as assessed by MR spectroscopy like glycine in non-ketotic hyperglycinemia, branched chain amino acids in maple syrup urine disease, and N-acetylaspartate in Canavan disease help to specify the diagnoses as encountered in our study as well. However, we could not get MRSI in every patient as it required radiologists' active participation in selection of cases (for whom MRSI might be indicated or helpful), careful selection of image and correct placement of region of interest (ROI) for adequate information, all of these would not have been possible or expected in each case for such retrospective study. Moreover, sometimes prolonged imaging time and sedation, and unexpected patient's movements may limit additional time consuming MRSI.<sup>13</sup>

Diagnoses of IEM remain challenging for both clinicians and radiologists. However, clinical information and age at presentation are helpful in suspecting such diseases. Patients with more profound enzyme defects tend to have earlier clinical presentation (also termed devastating metabolic diseases), acute encephalopathy and life-threatening metabolic decompensation, whereas late-onset disorders may have more manageable disease course with better outcome. We found more abnormal EEGs in MRI positive cases emphasizing importance of this investigation in evaluation of such patients. Though

we did not specifically observe certain EEG patterns (like burst suppression pattern or hypsarrhythmia patterns) that could suggest presence of metabolic disorders as indicated in some local studies.<sup>14,15</sup>

We consider single center, small sample-size and retrospective study to be few of our study limitations. Also, although brain MRI remains a valuable tool to document pertinent changes that can help in guiding further biochemical or genetic testing,<sup>16</sup> and even suggesting diagnoses. However, imaging patterns may overlap and sometimes remain non-specific or inconclusive. False positive and false negative results in our study also highlight imaging pitfalls in diagnoses. A methodical approach is therefore warranted,<sup>17</sup> and imaging pattern recognition by radiologists may help to narrow or suggest diagnoses.<sup>18</sup> It should be noted that our study only predicted neurometabolic disorders based on certain MRI features. However, final diagnoses need to be established on clinical grounds, biochemical or metabolic screening and genetic testing. Individual MRI features might not help in labelling diagnoses no matter how much characteristic pattern may be seen e.g., vacuolating myelinopathy can be seen in MSUD (an organic acidemia), citrullinemia (a urea cycle disorder), non-ketotic hyperglycemia, and even in HIE (hypoxic-ischemic injury). Widened sylvian fissures and CSF spaces may be seen in both glutaric aciduria and even NAI (non-accidental injury). Clinical, biochemical/ metabolic screening and genetic testing may still be needed to establish diagnoses. Vigilance on part of clinicians, and deep understanding of imaging by the radiologists are needed to ensure timely diagnoses for such demanding group of neurometabolic disorders at an earlier stage, for which limited treatment and management options are available<sup>19</sup> despite current advanced genetic testing.<sup>20</sup>

In conclusion, magnetic resonance imaging of the brain can help to suggest inherited neurometabolic disorders (inborn errors of metabolism) considering certain specific findings.

**Acknowledgment.** *We would like to thank our senior colleague, Dr. Mohammad Zia Ul Hassan, for reviewing the images for clarity and correctness.*

## References

1. Magnetic Resonance Spectroscopy Features. *Curr Med Imaging Rev* 2019; 15: 255-268.
2. Vernon HJ. Inborn Errors of Metabolism: Advances in Diagnosis and Therapy. *JAMA Pediatr* 2015; 169: 778-782.
3. Yoon HJ, Kim JH, Jeon TY, Yoo SY, Eo H. Devastating metabolic brain disorders of newborns and young infants. *Radiographics* 2014; 34: 1257-1272.
4. Lim YT, Mankad K, Kinali M, Tan AP. Neuroimaging Spectrum of Inherited Neurotransmitter Disorders. *Neuropediatrics* 2020; 51: 6-21.
5. Patay Z, Blaser SI, Poretti A, Huisman TA. Neurometabolic diseases of childhood. *Pediatr Radiol* 2015; 45: S473-S484.
6. Datar R, Prasad AN, Tay KY, Rupa CA, Ohorodnyk P, Miller M, et al. Magnetic resonance imaging in the diagnosis of white matter signal abnormalities. *Neuroradiol J* 2018; 31: 362-371.
7. Willemsen MA, Harting I, Wevers RA. Neurometabolic disorders: Five new things. *Neurol Clin Pract* 2016; 6: 348-357.
8. van der Knaap MS, Schiffmann R, Mochel F, Wolf NI. Diagnosis, prognosis, and treatment of leukodystrophies. *Lancet Neurol* 2019; 18: 962-972.
9. Parikh S, Bernard G, Leventer RJ, van der Knaap MS, van Hove J, Pizzino A, et al; GLIA Consortium. A clinical approach to the diagnosis of patients with leukodystrophies and genetic leukoencephalopathies. *Mol Genet Metab* 2015; 114: 501-515.
10. Fukao T, Nakamura K. Advances in inborn errors of metabolism. *J Hum Genet* 2019; 64: 65.
11. Mankad K, Talenti G, Tan AP, Gonçalves FG, Robles C, Kan EYL, et al. Neurometabolic Disorders of the Newborn. *Top Magn Reson Imaging* 2018; 27: 179-196.
12. Saudubray JM, Garcia-Cazorla A. Inborn Errors of Metabolism Overview: Pathophysiology, Manifestations, Evaluation, and Management. *Pediatr Clin North Am* 2018; 65: 179-208.
13. Barkovich MJ, Li Y, Desikan RS, Barkovich AJ, Xu D. Challenges in pediatric neuroimaging. *Neuroimage* 2019; 185: 793-801.
14. Mohamed S, El Melegy EM, Talaat I, Hosny A, Abu-Amro KK. Neurometabolic Disorders-Related Early Childhood Epilepsy: A Single-Center Experience in Saudi Arabia. *Pediatr Neonatol* 2015; 56: 393-401.
15. Alrifai MT, AlShaya MA, Abulaban A, Alfadhel M. Hereditary neurometabolic causes of infantile spasms in 80 children presenting to a tertiary care center. *Pediatr Neurol* 2014; 51: 390-397.
16. Tarailo-Graovac M, Shyr C, Ross CJ, Horvath GA, Salvarinova R, Ye XC, et al. Exome Sequencing and the Management of Neurometabolic Disorders. *N Engl J Med* 2016; 374: 2246-2255.
17. BoAli AY, Alfadhel M, Tabarki B. Neurometabolic disorders and congenital malformations of the central nervous system. *Neurosciences (Riyadh)* 2018; 23: 97-103.
18. Radke J, Stenzel W, Goebel HH. Neurometabolic and neurodegenerative diseases in children. *Handb Clin Neurol* 2017; 145: 133-146.
19. Paik K, Lines MA, Chakraborty P, Khangura SD, Latocki M, Al-Hertani W, et al.; Canadian Inherited Metabolic Diseases Research Network. Health Care for Mitochondrial Disorders in Canada: A Survey of Physicians. *Can J Neurol Sci* 2019; 46: 717-726.
20. Poletti V, Biffi A. Gene-Based Approaches to Inherited Neurometabolic Diseases. *Hum Gene Ther* 2019; 30: 1222-1235.