

## Resolution of Severe Macular Edema in Adult Coats' Disease with Intravitreal Triamcinolone and Bevacizumab Injection

Jong-Hwa Jun, MD, Yu-Cheol Kim, MD, Kwang-Soo Kim, MD

Department of Ophthalmology, School of Medicine, Dongsan Medical Center, Keimyung University, Daegu, Korea

A 47 year old male patient visited our hospital with the chief complaint of deterioration of the visual acuity in the left eye. The fundus examination revealed thick hard exudates, multiple aneurysms and telangiectasias of the retinal vessels in the posterior pole. Fluorescein angiography demonstrated massive leakage over an area of the aneurysms. Optical coherence tomography (Stratus OCT; Zeiss-Humphrey, Dublin, CA) revealed diffuse and marked thickening of the retina. Laser photocoagulation was performed under the diagnosis of Coats' disease. However, the treatment could not be performed satisfactorily. On the first and 6th weeks, an intravitreal injection of bevacizumab and triamcinolone acetonide was administered, and laser photocoagulation was again attempted. The effectiveness of each agent on retinal edema was evaluated at the follow-up performed at 1, 2, 5, 7, 10 weeks and 6 months after the injection. At one week after the intravitreal bevacizumab injection, there was no improvement. An intravitreal injection of triamcinolone acetonide was performed 6 weeks after the initial diagnosis, which resulted in a reduction in the thickness of the macular edema. Therefore, laser photocoagulation was performed sufficiently on telangiectasias. The follow-up at 6 months showed a relative increase in the macular edema, but there was reduced leakage from the telangiectasias compared with the previous angiograph.

*Korean J Ophthalmol* 2008;22:190-193 © 2008 by the Korean Ophthalmological Society.

**Key Words:** Adult Coats' disease, Bevacizumab, Macular edema, Triamcinolone acetonide

Coats' disease typically induces idiopathic retinal telangiectasias in all components of the retinal vasculature. In addition, it induces significant lipid deposition due to the non-perfusion of the capillary blood vessels, aneurysm formation, and subretinal exudation. Adult cases of Coats' disease are often asymptomatic, or the visual acuity at the initial diagnosis is better than in pediatric patients. Leukocoria is absent at the time of diagnosis, and the extent of exudation and retinal detachment tends to be mild.<sup>1</sup> Treatment is performed according to the Shields classification.<sup>2</sup> The occlusion of the dilated blood vessels is treated by cryotherapy and laser photocoagulation for stage 1-3A. Surgical retinal reattachment is performed for most cases of stage 3B. Enucleation is indicated for stage 4 patients. In this adult Coats' disease patient, bevacizumab and triamcinolone acetonide were injected into the vitreous in an attempt to resolve the severe macular edema in the

submacular area and to facilitate laser photocoagulation on retinal telangiectasias. This procedure has not been reported previously in Korea.

### Case Report

A 47 year old male patient visited our hospital with the chief complaint of acute progressive deterioration of the visual acuity of his left eye that had begun 2 months earlier. No specific findings were detected in his prior history. The total cholesterol, component ratio of triglycerides, HDL-cholesterol and LDL-cholesterol were within the normal range. At the initial examination, the corrected visual acuity of his right and left eye was 1.0 and 0.02, respectively. The intraocular pressure of the right and left eye, measured using a non-contact tonometer, was 19 mmHg and 16 mmHg, respectively. The slit lamp examination revealed no specific special findings in the anterior segment and no rubeosis. The bilateral fundus examination showed normal findings in his right eye, and thick macular edema in the posterior pole in his left (Fig. 1A). Fluorescein angiography revealed profuse leakage with capillary dropout and a club shape that diffused to the blood vessels in the vicinity of the posterior pole (Fig. 1B). OCT showed that the retina thickness had thickened noticeably to 1,187  $\mu\text{m}$  as a result of macular edema (Fig. 1C). Focal laser photocoagulation was attempted in the

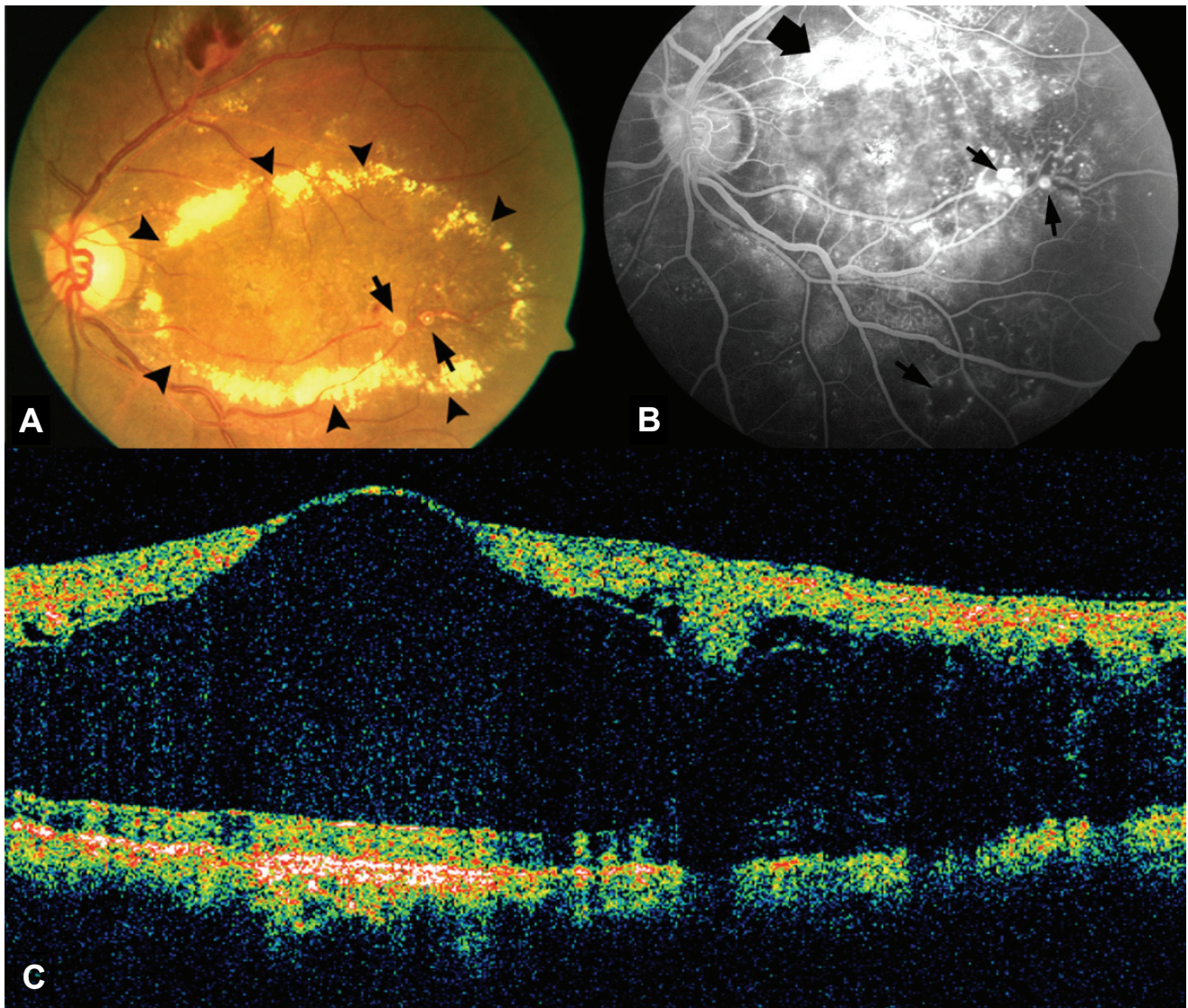
Received: September 10, 2007 Accepted: July 29, 2008

Reprint requests to Yu-Cheol Kim, MD, Department of Ophthalmology, School of Medicine, Keimyung University, 194 Dongsan-dong, Jung-gu, Daegu 700-712, Korea, Tel: 82-53-250-7702, 8026, Fax: 82-53-250-7705, E-mail: eyedr@dreamwiz.com

\* A summary of this paper was presented as a poster at the 97th Spring Meeting of Korean Ophthalmology Society, April 2007, Pusan, Korea

dilated vessel area but it was difficult to perform satisfactorily because of the thick retinal edema. The OCT taken 1 week after his first visit did not show any improvement of the macular edema. Therefore, bevacizumab (Avastin™, 25 mg/ml, 4 ml, Roche, USA) 1.25 mg (0.5 ml) was injected into the vitreal cavity in order to subside the retinal edema and facilitate focal laser photocoagulation on the telangiectatic vessels. Additional focal laser photocoagulation was then performed. However, OCT taken at 3 week visit after the injection showed that the macular thickness had barely changed. On the 6th week after treatment, an intravitreal injection of triamcinolone acetonide (Triamcinolone inj®, 40 mg/ml, 5 ml, Dongkwang pharma,

Korea) 4 mg (0.1 ml) was performed to resolve the retinal edema for focal laser photocoagulation. One week after the triamcinolone acetonide injection, the visual acuity was 0.02 and showed no improvement. However, there was a noticeable reabsorption of the macular edema. At the 2<sup>nd</sup> week after the injection, the foveal structures began to recover. After 5 weeks, the retinal thickness had decreased to 244 μm (Fig. 2C). The visual acuity improved slightly to 0.04, and additional focal laser photocoagulation could be performed easily and satisfactorily with the absorption of the retinal edema. Repeated focal laser photocoagulation was performed at each visit until 10 weeks after injection, and the retinal edema remained stable. At 6 months, the OCT showed

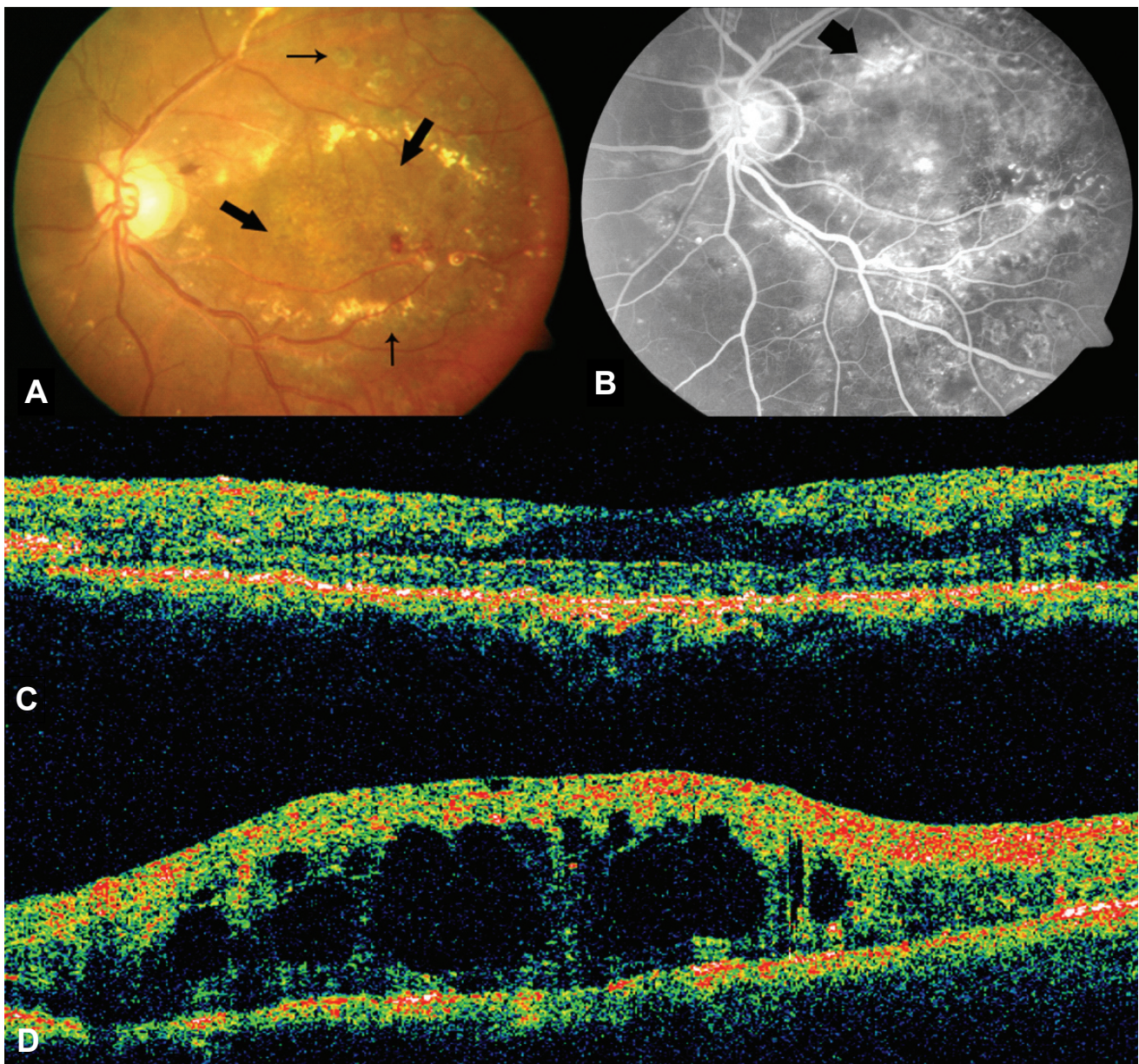


**Fig. 1.** Pretreatment findings at initial diagnosis. (A) Color fundus photograph of the left eye at initial examination showing diffuse macular edema, thick hard exudates (arrow heads) and multiple vascular telangiectasias (arrows) in the temporal retina. (B) Fluorescein angiography at initial examination shows vascular telangiectasis, areas of nonperfusion, and aneurismal dilation of retinal vessels with leakage of dye (small arrows). Diffuse leakage from telangiectatic vessels at major vascular arcades (large arrow). (C) Optical coherence tomogram shows a serous retinal detachment in the macula, and marked retinal swelling in the fovea. The retinal thickness at the central fovea is 1187 μm.

that the macular edema had increased to 680  $\mu\text{m}$  (Fig. 2D). However, on color fundus photography, thick circinate hard exudates was much absorbed (Fig. 2A) and, fluorescein angiography revealed a significant decrease in leakage from telangiectatic vessels compared with that performed at the time of the initial diagnosis (Fig. 2B). Consequently, repeated injection of triamcinolone acetonide and repeated aggressive laser photocoagulation was planned in order to prevent further progression.

### Discussion

Coats' disease develops primarily in young children under the age of 5 years with relatively few reports of adult cases. According to several studies, the progression of Coats' disease is relatively slow in older children or adults, and it shows indolent clinical features.<sup>1-5</sup> In adult cases, the mean age at the time of diagnosis is approximately 50 years with a male preponderance.<sup>1</sup> In the laboratory examination,



**Fig. 2.** Posttreatment findings. (A) At 6 weeks after triam-cinolone injection, macular edema recurred slightly, but thick hard exudates have been absorbed nearly totally at posterior pole (large arrows). focal laser photocoagulation scars were seen at temporal side of posterior pole (small arrows). And they are appropriate and sufficient. (B) Fluorescein angiography at 6 months after intravitreal triamcinolone injection, clinically significant macular edema was still remaining but leakage from telangiectatic vessels was much decreased, compared with angiography at initial diagnosis (large arrow). (C) 5th week after the intravitreal triamcinolone acetonide injection optical coherence tomogram shows decreased macular thickness and the reabsorption of serous retinal detachment. The retinal thickness at the central fovea is 244  $\mu\text{m}$ . (D) At 6 months, the OCT showed that the macular edema had increased to 680  $\mu\text{m}$ .

hyperlipidemia is frequently encountered as an accompanying condition. However, in this case, the lipid profile was within the normal range. Similar to children, the fundus examination shows arteriovenous dilation of the non-perfusion area of the capillary beds as well as subretinal lipid exudate and macular edema in the vicinity. Moreover, the involved blood vessel area is closer to the macular area than that observed in typical Coats' disease. In addition, there is less lipid exudate, and the retinal hemorrhage can be observed more often in the vicinity of the greatly dilated blood vessels.<sup>1,5</sup>

The treatment and prognosis of Coats' disease are influenced by the submacular exudates and the extent of retinal detachment. Focal laser photocoagulation or cryotherapy to the dilated blood vessels is the primary treatment for cases without exudative retinal detachment or mild. Drainage of the subretinal fluid, scleral buckling, pars plana vitrectomy can be applied in cases with severe exudative retinal detachment.<sup>2, 6-8</sup> However, in Coats' patients, the application of focal laser photocoagulation to the leakage area is limited in most cases due to the profuse retinal edema caused by leakage over a wide area. Moreover, the retinal detachment may persist despite surgical treatments in some cases with extravascular fluid pooling in the outer layers over a wide area. Therefore, several treatment strategies have been attempted. Sun et al.<sup>9</sup> reported a case of a stage 4 pediatric patient who was unresponsive to scleral buckling and SRF drainage. The patient was treated with an intravitreal injection of anti-VEGF. After injecting the anti-VEGF agent, pegaptanib sodium, the elevated VEGF levels had decreased markedly and the exudative retinal detachment had improved. However, in our case, there was no improvement of the exudative lesion after the intravitreal bevacizumab injection. Such a result was obtained because the exudative retinal detachment in Sun's case was the increase in vascular permeability caused by the secondarily elevated VEGF due to retinal ischemia. Our case it was Stage 2A according to the Shields classification. In addition, the ischemic area was not wide and there was only a slight increase in level of VEGF. Therefore, it is not surprising that no noticeable improvement was observed after the bevacizumab injection. This means that the increase in vascular permeability in Coats' disease is induced primarily by morphological problems, and an elevated VEGF level could increase the permeability secondarily with the progression of the disease due to advanced retinal ischemia. Consequently, the therapeutic reaction differs according to the change in pathophysiology during disease progression.

Jarin et al.<sup>10</sup> reported that an intravitreal injection of triamcinolone acetonide was effective in an adult Coats' patient who was unresponsive to conventional laser photocoagulation due to the presence of severe macular edema. The microcirculation of the retinal blood vessels and edema were stabilized by triamcinolone because it has been shown

to be effective against microangiopathy of which Coats' disease is a chronic form.<sup>11</sup> However, in previous report, Jonas et al.<sup>12</sup> reported two patient with Coats' like features that was unresponsive to intravitreal triamcinolone. The results of our case are similar to Jarin's case. Moreover, in Coats' disease, macular edema develops as a result of leakage due to destruction of the blood-retinal barrier through the loss of vascular endothelial cells and adjacent cells induced by causes yet to be determined. Hence, in addition to VEGF, other cytokines are believed to be involved. Therefore, it is believed that triamcinolone acetonide injected into the the intravitreal cavity suppressed a variety of cytokines and induced some short term improvement in macular edema.

Overall, Coats' disease with severe retinal edema can be treated accurately and satisfactorily by laser photocoagulation on the targeted leakage area after absorbing the retinal edema through a triamcinolone acetonide injection. In addition, it is believed that the partial retinal edema that remained after photocoagulation can be improved with an intravitreal injection of triamcinolone acetonide. However, statistical analysis of the effectiveness of the adjunct treatment based on a larger number of cases will be needed.

## References

1. Smithen LM, Brown GC, Brucker AJ, et al. Coats' disease diagnosed in adulthood. *Ophthalmol* 2005;112:1072-78.
2. Shields JA, Shields CL, Honavar SG, et al. Classification and management of Coats disease: the 2000 Proctor Lecture. *Am J Ophthalmol* 2001;131:572-83.
3. Jones JH, Kroll AJ, Lou PL, Ryan EA. Coats' disease. *Int Ophthalmol Clin* 2001;41:189-98.
4. Shields JA, Shields CL. Review: Coats disease. The 2001 LuEsther T. Mertz Lecture. *Retina* 2002;22:80-91.
5. Shields JA, Shields CL, Honavar SG, Demirci H. Clinical variations and complications of Coats disease in 150 cases. The 2000 Sanford Gifford Memorial Lecture. *Am J Ophthalmol* 2001;131:561-71.
6. Couvillion SS, Margolis R, Mavroffjides E, et al. Laser treatment of Coats' disease. *J Pediatr Ophthalmol Strabismus* 2005;42:367-8.
7. Adam RS, Kertes PJ, Lam WC. Observations on the management of Coats' disease: less is more. *Br J Ophthalmol* 2007;91:303-6.
8. Patelli F, Zumbo G, Fasolino G, et al. Treatment and outcome of exudative retinal detachment in Coats disease: a case report. *Semin Ophthalmol* 2004;19:117-8.
9. Sun Y, Jain A, Moshfeghi DM. Elevated vascular endothelial growth factor levels in Coats disease: rapid response to pegaptanib sodium. *Graefes Arch Clin Exp Ophthalmol* 2007;45:1387-9.
10. Jarin RR, Teoh SCB, Lim TH. Resolution of severe macular oedema in adult Coat's syndrome with high-dose intravitreal triamcinolone acetonide. *Eye* 2006;20:163-5.
11. Tripathi R, Ashton N. Electron microscopical study of Coat's disease. *Br J Ophthalmol* 1971;55:289-301.
12. Jonas J. Intravitreal triamcinolone acetonide as treatment for extensive exudative retinal detachment. *Br J Ophthalmol* 2004;88:587-8.